



# All-inside Arthroscopic Meniscal Repair Technique Using a Midbody Accessory Portal

S. Tal Hendrix, M.D., Adam Kwapisz, M.D., Ph.D., and Douglas J. Wyland, M.D.

---

**Abstract:** Treatment of symptomatic meniscal tears continues to evolve as we improve our understanding of the biomechanical role of the meniscus and its long-term importance to the health of the knee joint. Suture repair of meniscal tears is challenging, yet the incidence of repairs among our colleagues continues to rise as we aim to preserve meniscal tissue. Many elements of performing a repair are tedious and difficult, including proper meniscal preparation, reduction, mattress suture placement, and fixation. The tear pattern and location present another layer of difficulty. The most widely used all-inside repair devices are harpoon-style devices and present their own challenges in using them without causing harm to the meniscus and surrounding cartilage. In this article, we describe a simple all-inside meniscal repair technique to improve the reproducibility and reliability of meniscal repairs using an accessory midbody meniscal portal and a surgical probe. This ensures proper placement of mattress sutures in a reduced meniscus, with a reduced risk of collateral injury to the meniscus and articular cartilage. Furthermore, this surgical technique is adaptable to any meniscal fixation method to the medial or lateral meniscus.

---

The meniscus serves as a critical structure for load distribution and contact pressure dissipation across the articular cartilage surface in the knee. Furthermore, the meniscus serves a secondary role in knee stability. A functional meniscus is essential for normal knee kinematics and joint reactive force distribution. Our understanding continues to improve, with recent literature describing the vital role the meniscal cartilage plays in the biomechanics and function of the knee.<sup>1-4</sup> Several studies have shown that with radial tears or loss of meniscal continuity, the biomechanics and joint reactive forces are markedly increased and the distribution of load resembles that of a total

meniscectomy.<sup>5,6</sup> Other studies have shown similar findings regarding joint reactive forces, an increased incidence of meniscal extrusion, and subsequent development of osteoarthritis and chondral damage.<sup>1,2</sup> With this increased understanding of the function and importance of the meniscus, there has been a resultant increased focus on meniscal preservation and repair. We developed a technique out of necessity so that we could reproducibly use the current meniscal repair devices to produce the most satisfactory repairs achievable. The purpose of this article is to describe a simple adjunctive technique for meniscal repair using a midbody accessory portal and probe. We believe implementing this accessory portal allows for improved meniscal preparation, reduction, and reproducible placement of vertical mattress sutures especially with all-inside harpoon-style devices, thus optimizing the meniscal healing potential and decreasing the risk of postoperative failure.

Historically, the arthroscopic meniscectomy has been the most commonly performed orthopaedic procedure in the United States. Several studies have evaluated the biomechanics of the knee after a meniscectomy. LaPrade et al.<sup>3</sup> showed that in radial meniscal tears, there is a resultant increase in joint reactive forces. These tears increase the contact area on the condyle and lead to changes in the joint reactive force distribution.<sup>3,5,6</sup> In addition, repair of these tears restores meniscal functionality and normalizes the joint reactive forces.<sup>3</sup>

---

*From Steadman Hawkins Clinic of the Carolinas (S.T.H., A.K., D.J.W.); and The Hawkins Foundation (S.T.H., A.K., D.J.W.), Greenville, South Carolina, U.S.A.; and Clinic of Orthopedics and Pediatric Orthopedics, Medical University of Lodz (A.K.), Łódź, Poland.*

*The authors report the following potential conflict of interest or source of funding: D.J.W. receives support from Arthrex, Arthrosurface, Zimmer. Full ICMJE author disclosure forms are available for this article online, as supplementary material.*

*Received March 31, 2017; accepted July 6, 2017.*

*Address correspondence to Douglas J. Wyland, M.D., Steadman Hawkins Clinic of the Carolinas, 200 Patwood Dr, Ste C100, Greenville, SC 29615, U.S.A. E-mail: [dwyland@ghs.org](mailto:dwyland@ghs.org)*

*© 2017 by the Arthroscopy Association of North America. Published by Elsevier. This is an open access article under the CC BY-NC-ND license (<http://creativecommons.org/licenses/by-nc-nd/4.0/>).*

*2212-6287/17475*

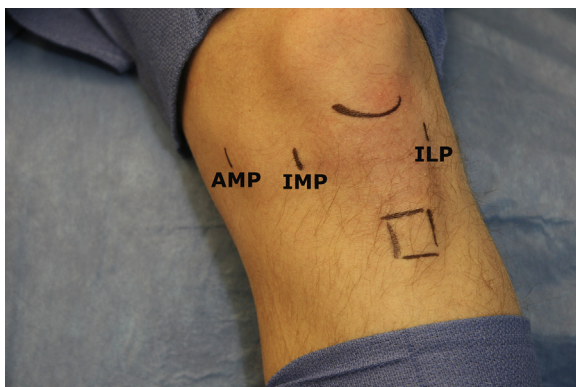
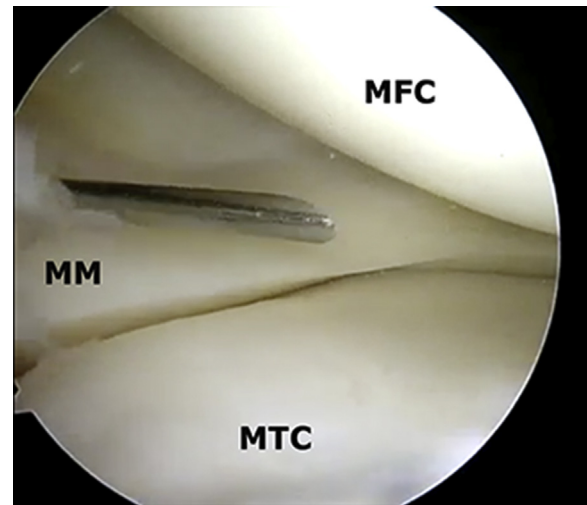
*<http://dx.doi.org/10.1016/j.eats.2017.07.005>*

**Table 1.** Pearls and Pitfalls of All-inside Meniscal Repair Using Accessory Midbody Meniscal Portal

Pearls	
Allows for directed vertical mattress suture configuration tangential to repair tissue	
Ensures accurate meniscal reduction	
Has decreased risk of pull-through during knot tightening	
Allows for undersurface vertical or horizontal mattress suture	
Helps maintain tissue reduction against vector needed to tighten knot	
Pitfalls	
Requires additional portal	
Has risk of iatrogenic injury to meniscus and chondral surfaces during portal establishment	

Several studies have evaluated long-term results of meniscal repair versus meniscectomy in terms of patient outcome scores and radiographic incidence of osteoarthritis (OA). Stein et al.<sup>7</sup> compared long-term outcomes of medial meniscal tears treated with meniscectomy versus repair in a matched cohort and found that 80% of patients in the repair group showed no radiographic progression to OA whereas only 40% in the meniscectomy group showed a lack of radiographic progression to OA. In addition, the repair group showed increased subjective patient outcome scores and return to sport as compared with the meniscectomy group. Badlani et al.<sup>1</sup> showed that meniscal extrusion and the size of the meniscal tear were predictive of the development of osteoarthrosis. Moreover, in a large systematic review of 91 studies, Brophy and colleagues<sup>8</sup> reported that patients who underwent repairs had increases in subjective outcome scores, but the repair group also showed an increase in the reoperation rate compared with the meniscectomy group.

Many techniques of meniscal repair have been described. The traditional gold-standard repair has been an inside-out vertical mattress suture configuration. However, with advances in technique and instrumentation, all-inside techniques now show similar strength

**Fig 1.** A left knee showing standard portal locations with the accessory medial portal (AMP). (ILP, inferolateral portal; IMP, inferomedial portal.)**Fig 2.** A left knee shown from the inferolateral viewing portal. The accessory medial portal is established by an outside-in needle localization method. It is important to have proper placement just superior to the anterior horn of the medial meniscus and a perpendicular entrance angle and trajectory to expose and assess the meniscus. (MFC, medial femoral condyle; MM, medial meniscus; MTC, medial tibial condyle.)

and clinical outcomes.<sup>9,10</sup> All-inside repairs remain technically difficult, and the large-bore harpoon-style devices have the potential to create tissue damage and iatrogenic chondral injury if not used properly.<sup>9</sup> This can be especially true with difficult fixation angles and poor meniscal stabilization. If not at a nearly perpendicular angle to the tissue, these devices can skive across the meniscal tissue and damage not only the meniscus but also the surrounding chondral surfaces.

Our meniscal repair technique was developed to avoid the pitfalls of using the all-inside technique with harpoon-style meniscal repair devices. This technique will significantly improve the accuracy and control of placement of the repair device while also stabilizing the meniscal tissue to improve the meniscal reduction, decrease the risk of iatrogenic injury, and allow for precisely placed vertical mattress suture configurations in difficult-to-reach locations (Table 1).

## Technique

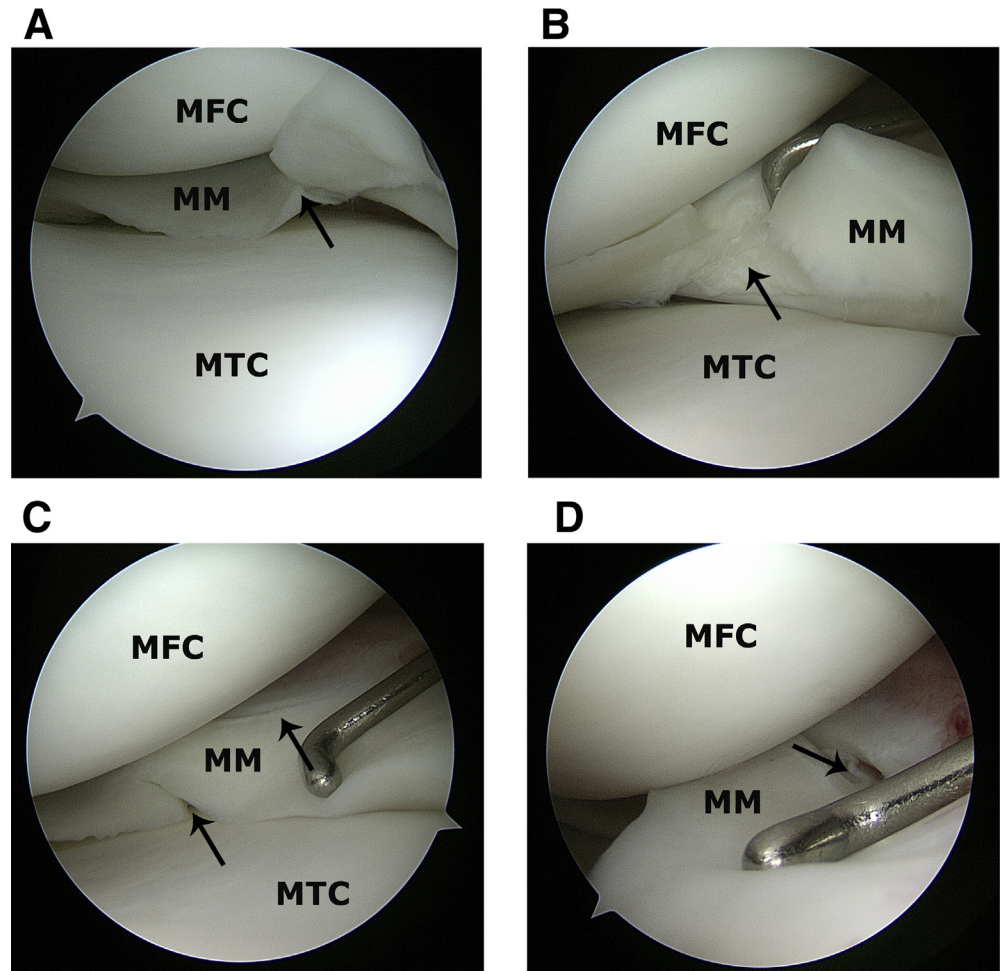
### Patient Position and Setup

Our standard meniscal repair is performed with the patient in the supine position with a lateral knee post. Representative aspects of our surgical technique can be found in Video 1.

### Portals

Standard inferomedial and inferolateral portals are established in the normal fashion and are shown in Figure 1. It is important to have well-placed initial

**Fig 3.** (A-D) A left knee viewed from the inferolateral portal. The probe is used through both the inferomedial and accessory medial portals to fully characterize the meniscal tear, tissue quality, reducibility, and reparability. The arrows indicate a medial meniscal lesion. (MFC, medial femoral condyle; MM, medial meniscus; MTC, medial tibial condyle.)

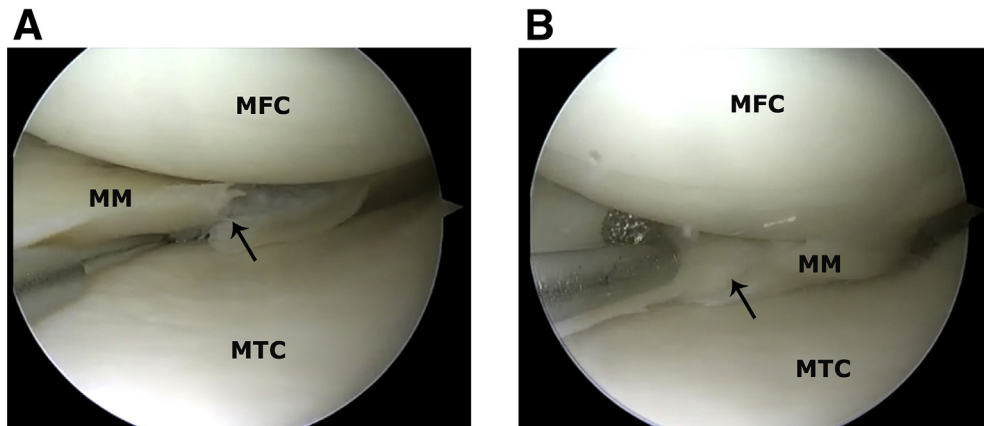


portals to allow for the best visualization and avoid the Hoffa fat pad. The first viewing portal is made with the knee in near full extension at the intersection of a line tangential to the lateral border of the patella and a line tangential to the inferior pole of the patella. It is important to establish the anterior portals in near full extension to help avoid violation of the fat pad. Once the portal is established, a comprehensive diagnostic arthroscopic assessment is performed. The location of the medial portal is case dependent and determined by the anticipated pathology and intervention.

For a medial meniscal repair, the anteromedial portal is made just superior to the anterior horn of the medial meniscus and just medial to the Hoffa fat pad. This is accomplished with needle localization and an outside-in technique (Fig 2). In the setting of an isolated lateral meniscal tear, the anteromedial portal is made just medial to the fat pad but at least 1 cm superior to the anterior horn of the medial meniscus to allow access and mobility over the tibial eminence. A surgical probe is used to evaluate the size, location, and character of the meniscal tear and the meniscal tissue, and a decision is made regarding meniscal repair (Fig 3). The

key accessory portals are then created. The accessory medial portal (AMP) is made in the position of repair (knee valgus loaded against post in near extension) by first locating the correct position with a spinal needle. This is carried out further medially and just anterior to the midbody meniscus. A small vertical portal is created with a No. 11 scalpel with the sharp side directed away from the meniscal tissue on entry into the knee joint. The preparation instrumentation is introduced through the AMP to prepare the tear interface with a small curved shaver and rasp, and trephination with a bent spinal needle then creates an excellent bleeding response (Fig 4). Next, the surgical probe is introduced through the AMP. All repair devices are introduced through the standard first anteromedial portal for the posterior-horn portion of the repair. As the repair continues anteriorly to the midbody portion, the arthroscope is moved to the standard anteromedial portal and the repair devices are placed through the anterolateral portal.

In the setting of a lateral meniscal repair, the accessory lateral portal (ALP) is made with needle localization with the knee in a figure-of-4 position. The ALP is



**Fig 4.** A left knee showing a complex medial meniscal tear viewed from the inferolateral portal. (A) The repair site undergoes trephination to create bleeding channels and increase healing potential at the repair. Often, a low-pressure and low-flow environment will confirm a bleeding bed adequate for repair. The arrow indicates a medial meniscal tear. (B) A rasp or mechanical shaver can be used to abrade the capsular margin and the meniscal repair site to increase healing potential. Care is taken to only debride nonviable tissue and prepare existing tissue for repair. The arrow indicates a medial meniscal tear. (MFC, medial femoral condyle; MM, medial meniscus; MTC, medial tibial condyle.)

placed at the joint line just superior to the meniscal tissue at the junction of the anterior horn and midbody anterolateral meniscus. A small portal is created with a No. 11 scalpel. Preparation of the meniscal tear interval is completed as previously described through the anteromedial portal. Next, the probe is introduced into the ALP, and the repair is completed from the higher anteromedial portal or from the lateral portal.

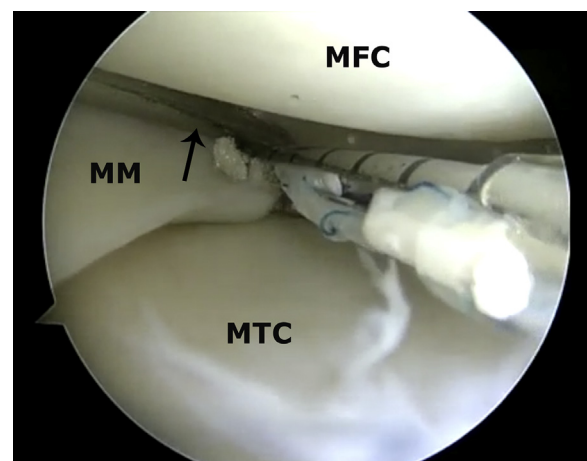
#### All-inside Meniscal Repair

After preparation of the repair site, the surgical probe is introduced through the accessory portal and remains there for the duration of fixation. The repair device (Fast-Fix 360 All-Inside Meniscal Repair System; Smith & Nephew, Andover, MA) is introduced through the anterior portal and is directed to the site of fixation. The surgical probe acts as a guide with the elbow of the probe providing a cradle to direct the instrument to the correct position at the repair site (Fig 5). Once in position, the probe can be used to manipulate the meniscal tissue and allow for perpendicular entry of the large-bore repair device. Once the meniscus is provisionally penetrated, the probe acts to reduce the meniscus to its origin. After deployment of the first anchor, the probe again guides the tip of the device around the condyle to a vertical position to allow for either a superior-surface or undersurface vertical mattress suture (Fig 6). Next, the second anchor is deployed, and the suture is tightened. The next step can be critical in the setting of questionable or thin meniscal tissue. The probe is used inside the adjustable loop of the vertical mattress suture to protect the suture from cutting through the meniscal tissue during tightening (Fig 7). Finally, fixation is secured and the suture is cut. The meniscus is sutured posteriorly to anteriorly

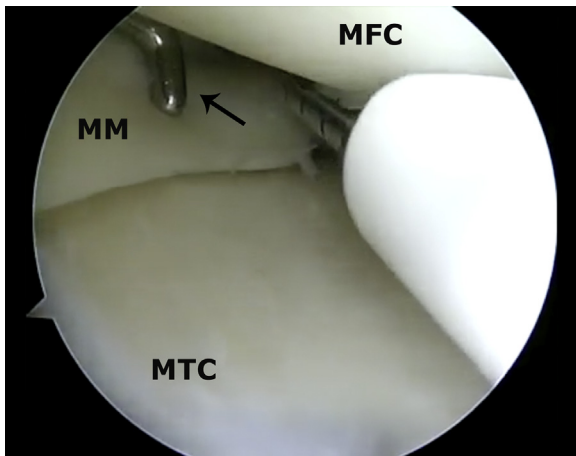
with sequential superior and undersurface mattress sutures to re-create the normal station of the meniscus and re-establish the meniscal founce sign (Fig 8).

#### Discussion

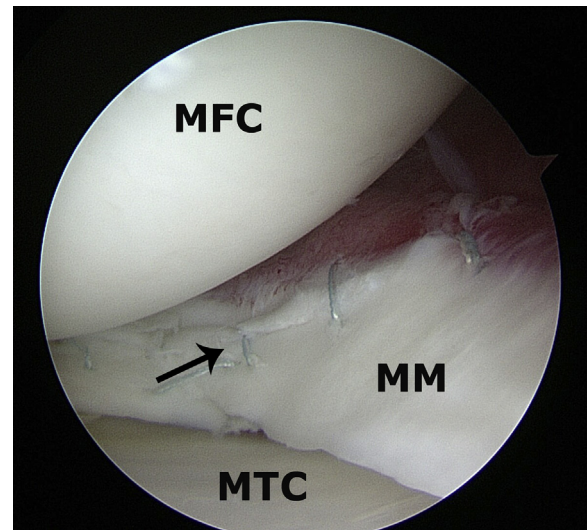
The described technique offers a reproducible, reliable method to approach meniscal repair for both the medial and lateral meniscus. With a better understanding of the chondroprotective properties of a functional meniscus, as well as the consequences of meniscal tissue deficiency or dysfunction, we have seen large



**Fig 5.** A left knee shown from the inferolateral viewing portal. The surgical probe (arrow) is used as a guide, and the elbow of the probe will help cradle the fixation device into the correct position. This allows for a true perpendicular entrance into the meniscal tissue with a low risk of skiving or causing iatrogenic chondral injury. (MFC, medial femoral condyle; MM, medial meniscus; MTC, medial tibial condyle.)

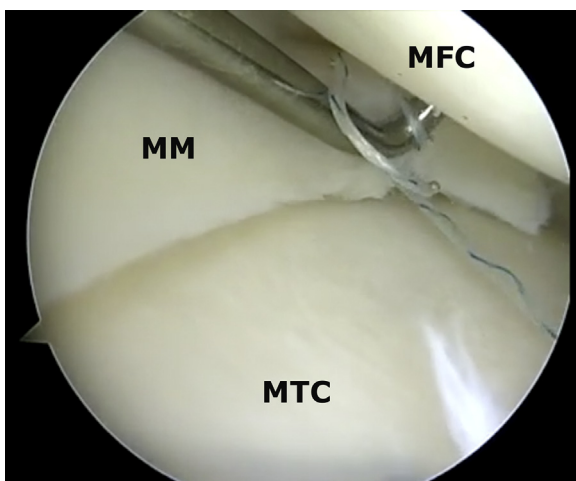


**Fig 6.** A left knee shown from the inferolateral viewing portal. The surgical probe (arrow) acts as a reduction tool to reduce the meniscus and hold it in position during deployment of the device. The surgical probe is used as a guide, and the elbow of the probe will help cradle the fixation device into the correct position. This allows for a true perpendicular entrance into the meniscal tissue with a low risk of skiving or causing iatrogenic chondral injury. (MFC, medial femoral condyle; MM, medial meniscus; MTC, medial tibial condyle.)



**Fig 8.** A left knee viewed from the inferolateral viewing portal after a medial meniscal repair (arrow) using the described technique with vertical mattress sutures to the superior and undersurface of the tear. (MFC, medial femoral condyle; MM, medial meniscus; MTC, medial tibial condyle.)

increases in the numbers of meniscal repairs performed in the United States. In a recent study, Abrams et al.<sup>11</sup> showed a 100% increase in the incidence of meniscal repairs over a study period of 2005 to 2011. In addition, this study showed an overall failure rate in meniscal repairs requiring subsequent meniscectomy of 9.8% in an isolated population and 8.2% with concomitant anterior cruciate ligament reconstruction. These were most commonly performed in young active male



**Fig 7.** A left knee shown from the inferolateral viewing portal. The surgical probe is placed inside the sliding loop to minimize friction and cut-through across the meniscal tissue plane during tightening of the suture. (MFC, medial femoral condyle; MM, medial meniscus; MTC, medial tibial condyle.)

patients. Historically, meniscal repair has been performed in young active individuals in an effort to protect the articular cartilage and provide longevity to the survival of the joint. Several recent studies have looked at an expanded role of meniscal repairs in older patients. Noyes and Barber-Westin<sup>12</sup> investigated tears extending into the avascular zone of the meniscus in patients aged 40 years or older and showed 87% with no symptoms after meniscal repair at 33 months' follow-up. Moreover, Barrett et al.<sup>13</sup> showed good to excellent clinical results in 86.5% of patients aged 40 years or older undergoing meniscal repair. Steadman et al.<sup>14</sup> looked at long-term follow-up (minimum, 10 years) of meniscal repairs in a population aged 40 years or older and compared this with meniscal repairs performed in a younger population. The failure rate at 10 years was 5.5% in the younger group and 5.3% in the older group. There were no differences in patient outcome scores.

Recently, Feeley et al.<sup>15</sup> looked at the health economic profile and cost-effectiveness of meniscal repair versus meniscectomy. An interesting finding of this study was that in the absence of degenerative chondromalacia, meniscal repair was cost-effective up to age 70 years when compared with meniscectomy. Feeley et al. concluded that, on the basis of an age-specific per-patient cost and projection of quality-adjusted life-years, if 10% of current meniscectomies instead were repaired, over a 30-year period, payers would save \$43 million annually. Meniscal repairs have shown better subjective patient outcomes, low failure rates, and chondroprotective properties over long-term follow-up

in patients with a wide range of ages and activity levels. Because we expect the incidence of meniscal repairs to continue to increase, the described surgical technique will allow for a reliable, reproducible repair and will better equip the surgeon for a difficult repair with a decrease in associated iatrogenic injuries or meniscal malreductions.

## References

1. Badlani JT, Borrero C, Golla S, Harner CD, Irrgang JJ. The effects of meniscus injury on the development of knee osteoarthritis: Data from the osteoarthritis initiative. *Am J Sports Med* 2013;41:1238-1244.
2. Pena E, Calvo B, Martinez MA, Palanca D, Doblare M. Finite element analysis of the effect of meniscal tears and meniscectomies on human knee biomechanics. *Clin Biomech (Bristol, Avon)* 2005;20:498-507.
3. LaPrade CM, Jansson KS, Dornan G, Smith SD, Wijdicks CA, LaPrade RF. Altered tibiofemoral contact mechanics due to lateral meniscus posterior horn root avulsions and radial tears can be restored with in situ pull-out suture repairs. *J Bone Joint Surg Am* 2014;96:471-479.
4. Bedi A, Kelly NH, Baad M, et al. Dynamic contact mechanics of the medial meniscus as a function of radial tear, repair, and partial meniscectomy. *J Bone Joint Surg Am* 2010;92:1398-1408.
5. Ode GE, Van Thiel GS, McArthur SA, et al. Effects of serial sectioning and repair of radial tears in the lateral meniscus. *Am J Sports Med* 2012;40:1863-1870.
6. Lee SJ, Aadalen KJ, Malaviya P, et al. Tibiofemoral contact mechanics after serial medial meniscectomies in the human cadaveric knee. *Am J Sports Med* 2006;34:1334-1344.
7. Stein T, Mehling AP, Welsch F, von Eisenhart-Rothe R, Jager A. Long-term outcome after arthroscopic meniscal repair versus arthroscopic partial meniscectomy for traumatic meniscal tears. *Am J Sports Med* 2010;38:1542-1548.
8. Paxton ES, Stock MV, Brophy RH. Meniscal repair versus partial meniscectomy: A systematic review comparing reoperation rates and clinical outcomes. *Arthroscopy* 2011;27:1275-1288.
9. Turman KA, Diduch DR, Miller MD. All-inside meniscal repair. *Sports Health* 2009;1:438-444.
10. Bogunovic L, Kruse LM, Haas AK, Huston LJ, Wright RW. Outcome of all-inside second-generation meniscal repair: Minimum five-year follow-up. *J Bone Joint Surg Am* 2014;96:1303-1307.
11. Abrams GD, Frank RM, Gupta AK, Harris JD, McCormick FM, Cole BJ. Trends in meniscus repair and meniscectomy in the United States, 2005-2011. *Am J Sports Med* 2013;41:2333-2339.
12. Noyes FR, Barber-Westin SD. Arthroscopic repair of meniscus tears extending into the avascular zone with or without anterior cruciate ligament reconstruction in patients 40 years of age and older. *Arthroscopy* 2000;16:822-829.
13. Barrett GR, Field MH, Treacy SH, Ruff CG. Clinical results of meniscus repair in patients 40 years and older. *Arthroscopy* 1998;14:824-829.
14. Steadman JR, Matheny LM, Singleton SB, et al. Meniscus suture repair: Minimum 10-year outcomes in patients younger than 40 years compared with patients 40 and older. *Am J Sports Med* 2015;43:2222-2227.
15. Feeley BT, Liu S, Garner AM, Zhang AL, Pietzsch JB. The cost-effectiveness of meniscal repair versus partial meniscectomy: A model-based projection for the United States. *Knee* 2016;23:674-680.