

# Low Regional Homogeneity of Intrinsic Cerebellar Activity in Ankle Instability: An Externally Validated rs-fMRI Study

XIAO'AO XUE<sup>1</sup>, RONG LU<sup>2</sup>, DI ZANG<sup>3</sup>, HONG LI<sup>1</sup>, HUI ZHANG<sup>4</sup>, HANLIN XU<sup>1</sup>, QIANRU LI<sup>1</sup>, TENGJIA MA<sup>1</sup>, WEIJUN TANG<sup>2</sup>, SHUANG CHEN<sup>2</sup>, HE WANG<sup>4,5,6</sup>, and YINGHUI HUA<sup>1,7</sup>

<sup>1</sup>Department of Sports Medicine, Huashan Hospital, Fudan University, Shanghai, CHINA; <sup>2</sup>Department of Radiology, Huashan Hospital, Fudan University, Shanghai, CHINA; <sup>3</sup>Department of Neurosurgery, Huashan Hospital, Fudan University, Shanghai, CHINA; <sup>4</sup>Institute of Science and Technology for Brain-Inspired Intelligence, Fudan University, Shanghai, CHINA; <sup>5</sup>Human Phenome Institute, Fudan University, Shanghai, CHINA; <sup>6</sup>Key Laboratory of Computational Neuroscience and Brain-Inspired Intelligence (Fudan University), Ministry of Education, Shanghai, CHINA; and <sup>7</sup>Yiwu Research Institute, Fudan University, Yiwu, CHINA

## ABSTRACT

XUE, X., R. LU, D. ZANG, H. LI, H. ZHANG, H. XU, Q. LI, T. MA, W. TANG, S. CHEN, H. WANG, and Y. HUA. Low Regional Homogeneity of Intrinsic Cerebellar Activity in Ankle Instability: An Externally Validated rs-fMRI Study. *Med. Sci. Sports Exerc.*, Vol. 54, No. 12, pp. 2037–2044, 2022. **Purpose:** Joint deafferentation after post-ankle sprain ligament healing can disrupt sensory input from the ankle and induce maladaptive neuroplasticity, especially in the cerebellum. This study aimed to determine whether the regional homogeneity of intrinsic cerebellar activity differs between patients with ankle instability and healthy controls without a history of ankle injury. **Methods:** The current study used a primary data set of 18 patients and 22 healthy controls and an external UK Biobank data set of 16 patients with ankle instability and 69 healthy controls for a cross-database, cross-sectional investigation. All participants underwent resting-state functional magnetic resonance imaging to calculate their regional homogeneity (ReHo) value. Between-group comparisons of the sensorimotor-related subregions of the cerebellum were first performed in the primary data set to identify low cerebellar ReHo in patients with multiple comparison corrections, and the surviving subregions were then externally validated in the UK Biobank data set. Correlation analyses between the ReHo values and clinical features were also performed. **Results:** The ReHo value of cerebellar lobule VIIIb was significantly lower in the ankle instability group than in the controls ( $0.170 \pm 0.016$  vs  $0.184 \pm 0.019$  in the primary data set,  $0.157 \pm 0.026$  vs  $0.180 \pm 0.042$  in the UK Biobank data set). The ReHo values of this subregion showed a significant positive correlation with the Cumberland Ankle Instability Tool scores in the ankle instability group ( $r = 0.553$ ,  $P$ -corrected = 0.0348). **Conclusions:** Patients with ankle instability had lower intraregional coherence in cerebellar lobule VIIIb than that of controls, which was also positively correlated with the intensity of self-reported ankle instability. **Key Words:** ANKLE INJURIES, MAGNETIC RESONANCE IMAGING, NEURONAL PLASTICITY, CEREBELLUM

Address for correspondence: Yinghui Hua, M.D., Ph.D., Department of Sports Medicine, Huashan Hospital, 12 Wulumuqi Middle Road, Shanghai 200040, China; E-mail: hua\_cosm@aliyun.com.

X. X. and R. L. contributed equally to this study as co-first authors.

Y. H., H. W., and S. C. contributed equally to this study as co-senior authors. Submitted for publication March 2022.

Accepted for publication June 2022.

Supplemental digital content is available for this article. Direct URL citations appear in the printed text and are provided in the HTML and PDF versions of this article on the journal's Web site ([www.acsm-msse.org](http://www.acsm-msse.org)).

0195-9131/22/5412-2037/0

MEDICINE & SCIENCE IN SPORTS & EXERCISE®

Copyright © 2022 The Author(s). Published by Wolters Kluwer Health, Inc. on behalf of the American College of Sports Medicine. This is an open-access article distributed under the terms of the Creative Commons Attribution-Non Commercial-No Derivatives License 4.0 (CCBY-NC-ND), where it is permissible to download and share the work provided it is properly cited. The work cannot be changed in any way or used commercially without permission from the journal.

DOI: 10.1249/MSS.0000000000002998

Ankle sprain is one of the most frequently reported sports injuries in both the general population and among competitive athletes (1,2). Despite being commonly viewed as a musculoskeletal disorder with minor consequences, approximately 40% of initial injuries are followed by subsequent reinjuries, residual symptoms (e.g., self-reported “feeling of instability”), and even early onset of posttraumatic osteoarthritis (3). Various therapeutic strategies, including external support, exercise therapy, and restabilization surgery, are used to restore ankle stability, but their effectiveness is not well defined (4,5). Recent mainstream opinions have also suggested that the symptoms of ankle instability (i.e., functional instability) are not simply parallel with joint laxity (i.e., mechanical instability) (1). Therefore, a better understanding of the pathological mechanisms underlying ankle instability is important for both clinicians and patients to develop targeted treatments.

In 1965, Freeman et al. (6) introduced a comprehensive theory of ankle instability, identifying traumatic damage to the afferent nerve fibers and corresponding joint deafferentation as

the cause of stabilization failure. Subsequently, there has been general recognition of the role of neural factors in the chronic course and pathological characteristics of ankle instability (7,8). Disruption of proprioceptors, inflammatory cascade, and persistent effusion within the injured joints have a chronic effect on articular sensory input to the central nervous system (CNS), which culminates in prolonged maladaptive neuroplasticity and leads to bilateral sensorimotor deficits after unilateral sprains (7,8). In the CNS, deficits of the cerebellum were thought to be associated with ankle instability in the latest magnetic resonance imaging (MRI) studies. In 2019, Terada et al. (9) utilized diffusion tensor imaging to observe impaired structural integrity in the superior cerebellar peduncle in patients with a history of ankle sprains. Subsequently, Xue et al. (10) characterized lower gray matter volumes in the cerebellar vermis in patients with ankle instability using three-dimensional structural imaging. However, functional evidence of maladaptive neuroplasticity in the cerebellum is lacking in existing studies on ankle instability (8).

Resting-state functional MRI (rs-fMRI) is a clinically practical method for assessing intrinsic blood oxygen level-dependent signals in the CNS (8). Although measured in the static condition, the functional features derived from the intrinsic cerebellar activity are supposed to predict dynamic sensorimotor behaviors (i.e., brain-behavior correlation analyses), which might provide insight into the pathological mechanisms of ankle instability (11,12). Among the numerous rs-fMRI parameters, regional homogeneity (ReHo), which represents the coherence of scanned neural activity, is one of the most reliable and frequently used measurements (13,14). In contrast to distant connectivity methods that explore the association between different regions, ReHo might be able to determine whether the cerebellum is a key region with abnormally organized neurons involved in ankle instability (13,14). Recently, Shen et al. (15) also investigated the ReHo of patients with ankle instability, but only the cerebral

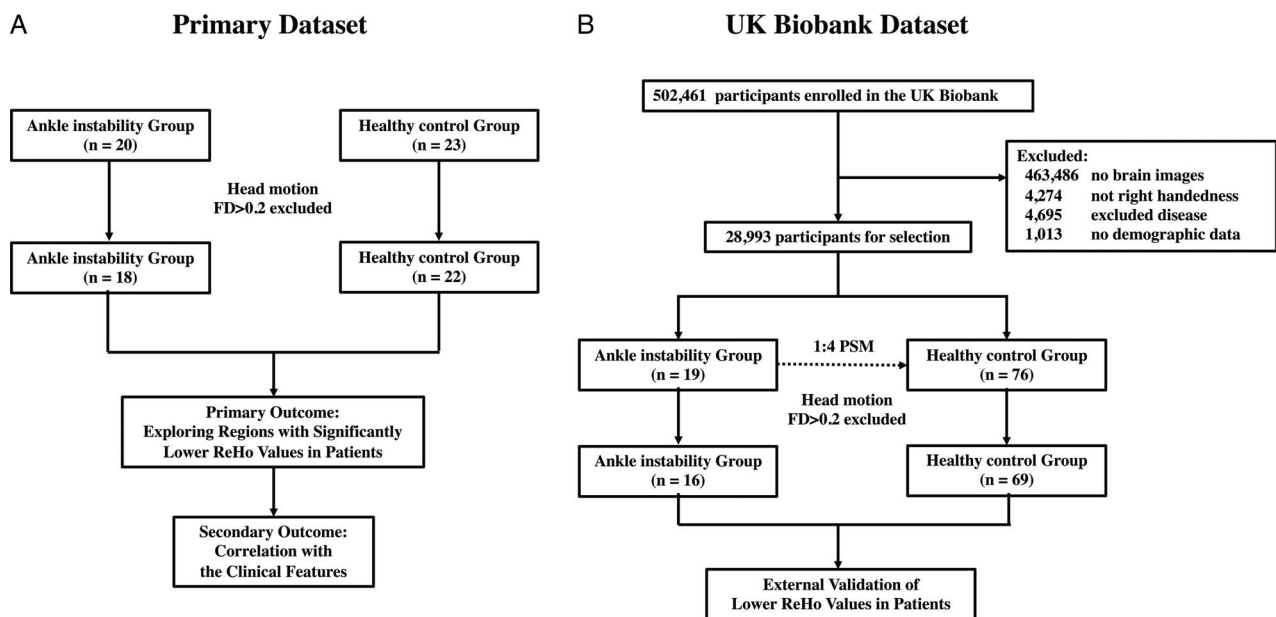
cortex was studied, and the cerebellum was ignored. Because poor functional coherence was supposed to be maladaptive, we speculated that low cerebellar ReHo values could be observed in ankle instability, which might be a necessary addition to previous structural evidence to improve our understanding of maladaptive neuroplasticity in ankle instability (16).

Therefore, the primary purpose of the current study was to determine whether the ReHo of intrinsic cerebellar activity differs between patients with ankle instability and healthy controls without a history of ankle injury. The secondary purpose was to determine the correlation between low ReHo values and serious clinical features of ankle instability. We hypothesized that patients with ankle instability would have lower cerebellar ReHo values than those of controls, which would also be positively correlated with the severity of ankle instability (e.g., higher self-reported feeling of instability intensity, lower activity level, worse pain, or longer chronicity of ankle instability).

## MATERIALS AND METHODS

### Study Design

The current study applied a cross-sectional design with cross-database validation, including a primary data set from Huashan Hospital and an external data set from the UK Biobank (17). The use of the primary data set and all research protocols was approved by the Institutional Review Committee of Huashan Hospital (No. 2016-413). All participants provided written informed consent before enrolling. Ethical approval for the use of the UK Biobank data set was approved by the Northwest Multi-Centre Research Ethics Committee, and the present research has been prospectively registered online (No. 62721). This study followed the Strengthened Reporting of Observational Studies in Epidemiology Statement, and the flow diagram of the study design is presented in Figure 1 (18).



**FIGURE 1**—Flow chart of the participant selections and study design of the primary dataset (A) and the UK Biobank data set (B). FD, frame-wise displacement; PSM, propensity score matching.

## Participants

In the primary data set, we recruited 43 participants, including 20 patients with unilateral ankle instability from our department of sports medicine and 23 healthy controls without any history of ankle injury from the local community. Exclusion criteria for both groups included a) a history of cardiovascular, neurological, infectious, autoimmune, or other major medical illnesses or traumas; b) a history of joint instability beyond the ankle; and c) not being right-footed, defined by the preferred limb to kick a ball. All patients in the primary data set have a) experienced at least one significant ankle sprain resulting in pain, swelling, and at least 1 d's interruption of desired physical activity; b) functional instability: experienced at least two episodes of their ankle "giving way" in the past 6 months or at least two occurrences of sprains to the same ankle or Cumberland Ankle Instability Tool (CAIT) scores <24; and c) mechanical instability: had been diagnosed with impaired lateral ankle ligaments through physical examination and MRI assessment (5). It should be noted that we did not set the duration from the initial sprain to scanning as a criterion to explore the correlation between neural outcomes and the full pathological process of ankle instability, which made our inclusion broader than that recommended by the International Ankle Consortium (3).

To validate our primary outcome of low cerebellar ReHo in ankle instability, we applied an external data set from the UK Biobank, which is a nationwide population-based data set (with a cohort of 502,461 individuals). First, individuals who a) did not have brain imaging data, b) were not labeled as right-handed (no footedness accessible), c) met the aforementioned exclusion criteria of the primary data set, or d) did not have complete demographic data (age, sex, body mass index (BMI), or ethnic background) were excluded. Participants with a medical history of an ankle instability-related diagnosis (instability, dislocation, recurrent injury, or ligament disorder) before scanning were enrolled in the ankle instability group. Notably, the patients in this data set were more general than those in the primary data set in representing the ankle instability population because the existence of functional instability was not recorded. Finally, propensity score matching was performed to match the healthy controls with the most similar age, sex, BMI, and ethnic background to the patients at a ratio of 1:4 (19). Diagnoses of excluded diseases and joint instability were based on the 10 labels of the *International Classification of Diseases, Tenth Revision (ICD-10)*, with criteria reviewed and decided by three experienced specialists (orthopedist, neurologist, and radiologist). The detailed *ICD-10* criteria are presented in Supplemental Appendix A (see Supplemental Digital Content 1, <http://links.lww.com/MSS/C667>).

## Data Acquisition

**Demographic and clinical features.** In the primary data set, a single investigator screened the medical history of the participants and collected their demographic and clinical features before scanning, including age, sex, BMI, ethnic background, the duration of ankle instability (from the initial

sprain to scanning), 100-mm visual analog scale (VAS) for pain, Tegner Activity Rating Scale for sports level, and CAIT for the self-reported feeling of instability intensity and the injured side (3). For the UK Biobank data set, all participants completed a series of computer-based questionnaires followed by face-to-face interviews with trained investigators (age, sex, BMI, ethnic background), and health-related outcomes (*ICD-10* diagnoses and the corresponding admission dates) were recorded during hospital inpatient admissions.

**fMRI data acquisition and analysis.** An investigator blinded to the group assignment performed the scanning of the primary data set. A 3.0T Siemens Magnetom Verio scanner equipped with an eight-channel head coil was used. During scanning, foam padding and headphones were used to limit head motion and reduce scanner noise, respectively. The subjects were instructed to hold still, keep their eyes closed but not fall asleep, and avoid thinking of anything in particular. For structural three-dimensional T1 imaging, we used a fast spoil gradient recall sequence as follows: matrix size,  $256 \times 256$ ;  $1.0\text{-mm}^3$  isotropic voxels; slice gap, 0 mm; repetition time, 2300 ms; echo time, 2.98 ms; flip angle,  $9^\circ$ ; field of view,  $256 \times 256\text{ mm}^2$ ; and slice thickness, 1.0 mm. For functional imaging, we used a T2\*-weighted echo-planar image sequence as follows: matrix size,  $64 \times 64$ ;  $4.0\text{-mm}^3$  isotropic voxels; slice gap, 0 mm; repetition time, 2210 ms; echo time, 30 ms; flip angle,  $90^\circ$ ; field of view,  $224 \times 224\text{ mm}^2$ ; slice thickness, 4.0 mm; number of acquisitions, 200; and ascending interleaved slice acquisition of 40 axial slices. Detailed neuroimaging data acquisition protocols for the UK Biobank data set are available online ([https://biobank.ctsu.ox.ac.uk/crystal/crystal/docs/brain\\_mri.pdf](https://biobank.ctsu.ox.ac.uk/crystal/crystal/docs/brain_mri.pdf)).

All preprocessing steps were performed using the Data Preprocessing Assistant for Resting-State fMRI (DPARSFA) version 5.2, based on Resting-State Statistical Parametric Mapping version 12 (SPM12; Department of Cognitive Neurology, London, UK) in MATLAB version R2018b (MathWorks Inc., Natick, MA) (20). The same processing procedures were performed for both data sets. Image preprocessing was performed as follows: a) the first 10 time points of functional images were removed for signal equilibration; b) slice-time correction that referred to the middle slice of each run was applied to correct for the different acquisition times of each slice; c) interscan head motion was corrected by realigning the functional images to the middle image and the mean functional image was produced after realignment; d) structural images were co-registered to the mean functional image by rigid body transformation using their mutual information; e) unified segmentation was used to segment the co-registered structural images into gray matter, white matter, and cerebrospinal fluid; f) nuisance covariates, including linear trend, Friston 24 head motion parameters, white matter signal, and cerebrospinal fluid signal, were regressed out from the functional images; g) based on the Diffeomorphic Anatomical Registration Through Exponentiated Lie algebra tool, segmented images were used to compute transformation parameters, and then functional images were normalized from the individual native space to the standardized Montreal Neurological Institute

space; h) functional images were resampled to  $3 \times 3 \times 3 \text{ mm}^3$  because of the original definition of ReHo (14); i) linear trends of the time series were removed by detrending; and j) band-pass temporal filter (0.01–0.1 Hz) was applied (20). Participants with a mean frame-wise displacement of head motion larger than 0.2 mm were excluded (21). Individual spatial ReHo maps were calculated based on Kendall's coefficient concordance, which measures the similarity of the time series of a single voxel to its nearest 27 neighbors, and then forms a map for each subject (14). Spatial smoothing was performed for each ReHo map with a Gaussian kernel of  $4 \times 4 \times 4\text{-mm}^3$  full width at half maximum to increase the signal-to-noise ratio (20).

Then, region of interest (ROI) analysis was performed by extracting the averaged ReHo values of all included voxels in each ROI (22). Regarding the selection of ROIs, we focused on the sensorimotor-related subregions of the anterior lobule (V) and posterior lobules with the vermis (VIIIa and VIIIb) according to the functional topography of the cerebellum (23–25). To verify the bilateral effects of ankle injuries and symmetric ReHo values in the cerebellar lobules, we performed two-tailed paired *t*-tests for the ipsilateral and contralateral lobules in the ankle instability group and the left/right lobules in the control group (1,26). No significant between-side differences were observed in our data set ( $P > 0.05$ , see Supplemental Appendix B, Supplemental Digital Content 2, <http://links.lww.com/MSS/C668>); thus, the left and right lobules were merged into bilateral lobules. Based on the probabilistic cerebellar atlas, five cerebellar ReHo outcomes were extracted for further analysis, including lobules V, VIIIa, and VIIIb, and vermis VIIIa, and VIIIb (Fig. 2) (22).

### Statistical Analysis

Statistical analyses were performed using GraphPad Prism, version 9.0. (GraphPad Software, San Diego, CA). Descriptive statistics were calculated as the mean  $\pm$  SD or median (interquartile range). The use of parametric or nonparametric tests for the numerical variables followed normality tests using the Kolmogorov–Smirnov *Z* test. In this study, the duration of ankle instability and the scores of the clinical questionnaires (CAIT, VAS, and Tegner) were nonnormally distributed, whereas age, BMI, and cerebellar ReHo values were normally distributed

( $P > 0.05$ ). Subsequently, two-tailed  $\chi^2$  tests, Mann–Whitney *U* tests, and independent two-sample *t*-tests were applied to examine the equivalence of demographic variables between the groups. As the primary outcome, one-tailed independent two-sample *t*-tests were used to determine the lower ReHo values of the five cerebellar ROIs in patients compared with those of controls. Cohen's *d* effect sizes with 90% confidence intervals (CIs) were calculated for the magnitude of between-group differences, with the absolute values of *d* classified as small (0.2–0.5), moderate (0.5–0.8), or large ( $>0.80$ ) effect sizes of lower ReHo values in patients (27). Bonferroni correction was also performed on the *P* values of the five comparisons to obtain the corrected *P* values, and the ROIs that survived in the correction were focused on in the following analyses (28). External validation was performed in the UK Biobank data set using one-tailed independent two-sample *t*-tests. Regarding the secondary outcome, based on our directional hypothesis that lower cerebellar ReHo values were positively correlated with the severity of ankle instability, one-tailed Spearman correlations with Bonferroni corrections were performed between the ReHo value and CAIT scores, Tegner scores, VAS, or the duration since the initial sprain within the patient group.

### RESULTS

**Demographic and clinical features.** A total of 43 participants volunteered for inclusion in the primary data set, of whom 2 patients and 1 control were excluded because of head motion. A total of 18 patients (5 women; age,  $30.00 \pm 6.74$  yr) and 22 controls (4 women; age,  $27.50 \pm 6.05$  yr) were finally enrolled. Eleven patients injured their left ankle, and seven injured their right ankle. Among the 502,461 participants in the UK Biobank data set, only 19 patients with ankle instability and 76 matched healthy controls met the selection criteria. Of those, 3 patients and 7 controls were removed because of head motion, leaving 16 patients (11 women; age,  $61.00 \pm 10.27$  yr) and 69 controls (50 women; age,  $60.86 \pm 7.24$  yr). The detailed selection steps are illustrated in Figure 1. The groups did not differ significantly in terms of sex, age, BMI, or ethnic background in either data set ( $P > 0.05$ ). Significantly lower CAIT, higher VAS, and lower Tegner scores were found in patients than in controls in the primary data set ( $P < 0.05$ ). The duration of

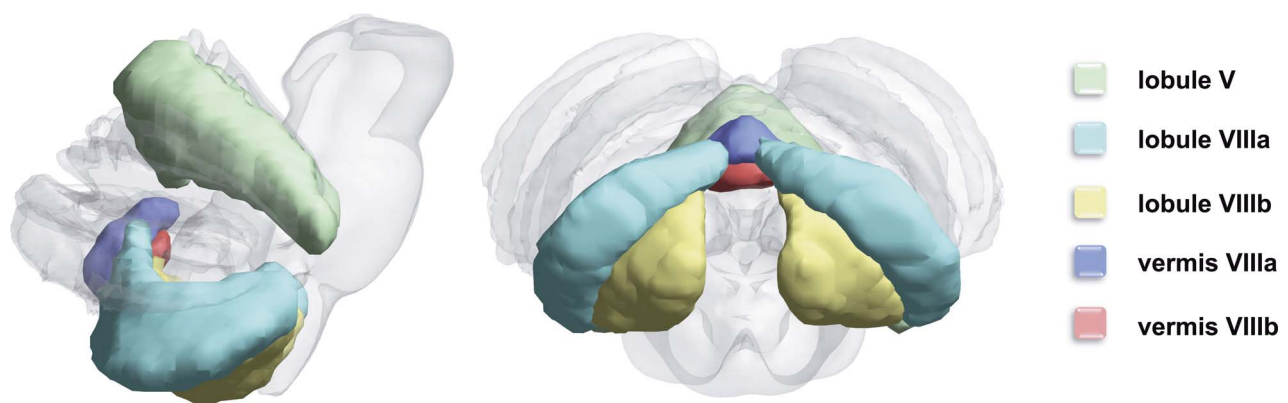


FIGURE 2—Visualization of the included sensorimotor-related cerebellar subregions by lateral (*left*) and upward (*right*) views.

TABLE 1. Between-group comparison of ReHo values in the sensorimotor-related subregions of cerebellum in the primary data set.

Regions of Interest	Ankle Instability (n = 18)	Healthy Control (n = 22)	Cohen's <i>d</i> Effect Size (90% CIs)	<i>P</i> Value (Uncorrected)	<i>P</i> Value (Corrected)
Bilateral V	0.225 ± 0.025	0.241 ± 0.035	-0.520 (-1.051 to 0.012)	0.0505	0.2526
Bilateral VIIIa	0.175 ± 0.017	0.185 ± 0.018	-0.566 (-1.100 to -0.033)	0.0392	0.1959
Bilateral VIIIb	0.170 ± 0.016	0.184 ± 0.019	-0.780 (-1.324 to -0.237)	0.0096	0.0480*
Vermis VIIIa	0.212 ± 0.033	0.235 ± 0.042	-0.608 (-1.143 to -0.073)	0.0281	0.1407
Vermis VIIIb	0.215 ± 0.040	0.242 ± 0.049	-0.577 (-1.111 to -0.043)	0.0347	0.1737

\*Significant lower ReHo values in patients when compared with controls (one-tailed two-sample *t*-test with Bonferroni correction).

ankle instability was 11.00 (7.00–36.00) months in the primary data set, and the time gap between diagnosis and scanning was 82.68 (43.85–191.71) months in the UK Biobank data set. Tables showing the detailed demographic and clinical features are presented in Supplemental Appendix C (see Supplemental Digital Content 3, <http://links.lww.com/MSS/C669>).

**Region-wise ReHo comparisons and correlations.**

Among the five pairs of comparisons in the primary data set, only the cerebellar lobule VIIIb survived the Bonferroni correction, which indicated significantly lower ReHo values in the ankle instability group than in the controls with a moderate effect size (Cohen's *d* = -0.780; 90% CI, -1.324 to -0.237; *P*-corrected = 0.0480; Table 1). Validated by the external UK Biobank data set, significantly lower ReHo values of lobule VIIIb in patients than in controls were also observed, with a moderate effect size (Cohen's *d* = -0.583; 90% CI, -1.134 to -0.031; *P* = 0.0207; Fig. 3a). Among the four correlation analyses, the only significant correlation between the ReHo values of lobule VIIIb and clinical features was the association between lower cerebellar ReHo and higher instability intensity (lower CAIT scores) in the ankle instability group (*r* = 0.553, *P*-corrected = 0.0348; Fig. 4).

**DISCUSSION**

The most important finding of this study was that the ReHo values within the bilateral cerebellar lobule VIIIb were lower in patients with ankle instability than in healthy controls, and these values correlated with the intensity of self-reported ankle instability among patients. In addition, this between-group difference in cerebellar lobule VIIIb was externally validated using the UK Biobank data set.

The cerebellum (“little brain” in Latin) is the main structure of the vertebrate hindbrain, containing approximately 50% of all brain neurons, and is involved in numerous vital functions, including sensorimotor control, spatial, cognitive, and language functions (24). Cerebellar lobule VIII forms part of the posterior cerebellar lobe, receives information from the cerebral sensorimotor cortices, and serves as part of the secondary motor representation (23,29,30). A meta-analysis of functional topography suggested that both cerebellar lobules VIIIa and VIIIb are recruited for motor activation, whereas somatosensory tasks only activate VIIIb (24). Motor somatotopy maps also showed that the cerebellar lobule VIIIb best overlaps with foot-related regions of movement (31,32). Moreover, the degeneration of lobule VIIIb leads to motor deficits in aging individuals and patients with cerebellar disorders. A study by Terada et al. demonstrated that impaired white matter ascending from the cerebellar lobules was associated with postural deficits after ankle sprains (9,33,34). As a result, we suggest that our functional localization of cerebellar lobule VIIIb is consistent with the abundant evidence of sensorimotor deficits in patients with ankle instability (35–37).

**Relationships between low cerebellar ReHo and ankle instability.**

The lower intraregional coherence of local neuronal activity observed during the current study indicates that cerebellar lobule VIIIb neurons worked incongruously in patients with ankle instability. Although measured in the resting state, we speculated that the lower cerebellar coherence might also hint at deficits in cerebellar functions in dynamic conditions. For example, if more coherence of the cerebellum is needed to stabilize the ankle when running than when resting, it might also be more challenging for patients with worse

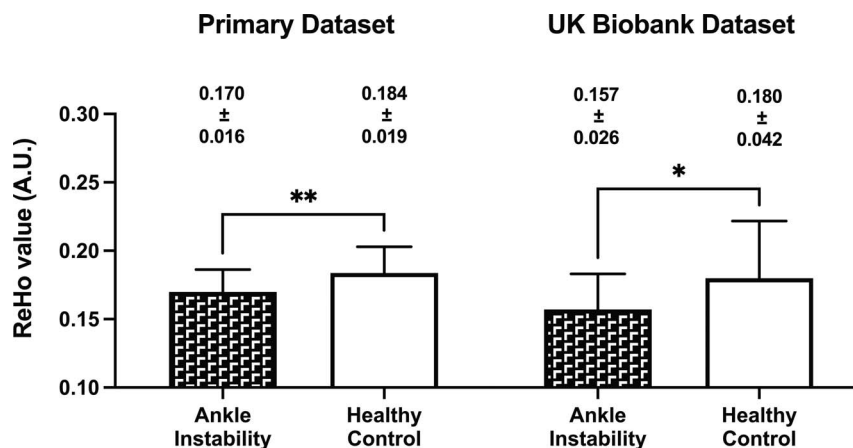
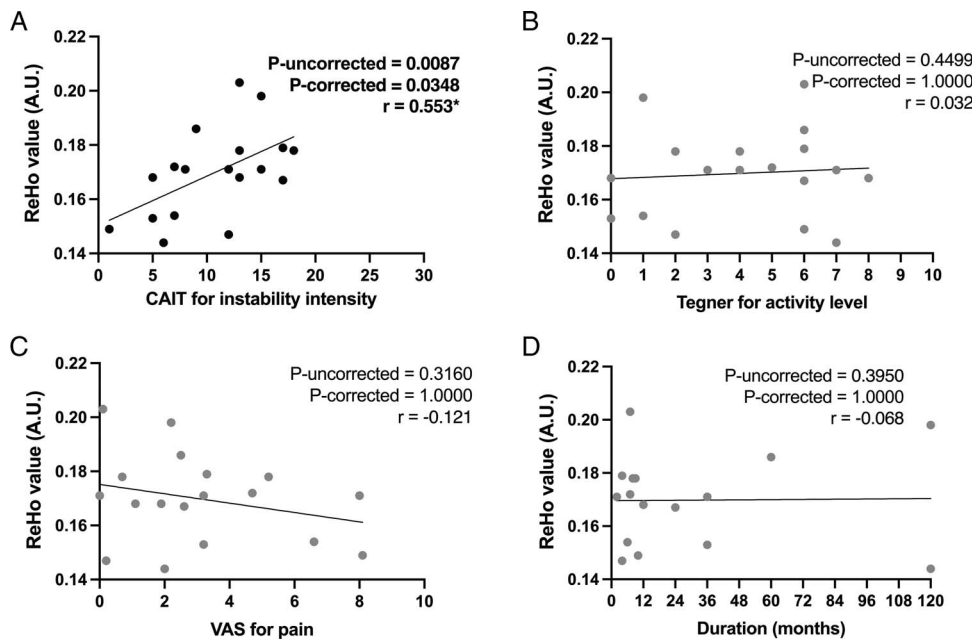


FIGURE 3—Patients with ankle instability have lower intraregional coherence of local neuronal activity (ReHo values) in bilateral cerebellar lobule VIIIb when compared with healthy controls in both the Primary data set and the UK Biobank data set. \**P* < 0.05; \*\**P* < 0.01.



**FIGURE 4**—Scatter plot of the relationship between the ReHo values of bilateral cerebellar lobule VIIIb and the (A) CAIT for self-reported instability, (B) Tegner Activity Rating Scale for sports level, (C) VAS for pain, (D) and the durations of ankle instability. \* $P < 0.05$ .

resting cerebellar coherence to meet the functional demand of running. Our findings on the correlation between the ReHo values and the self-reported feeling of instability intensity might also indicate its relationship with ankle instability, and the recent ReHo study on cerebral cortex also supported that the premotor cortex of the patients had to be more coherent to compensate for sensory deafferentation in ankle instability (15). For this mechanism, we tentatively surmise that the aforementioned joint deafferentation might influence cerebellar lobule VIIIb (reducing ReHo values), thereby causing a failure of appropriate motor output by cerebellar lobule VIIIb (presenting as functional instability). Further research using activators and inhibitors is needed to fully confirm the relationship between the lack of sensory input, reduced ReHo in cerebellar lobule VIIIb, and deficits in motor output.

Our primary data set enrolled patients with both mechanical and functional instability, whereas the UK Biobank data set did not strictly set the criteria of considering functional instability. Although the smaller effect size of the lower ReHo values in the UK Biobank data set might indicate an association between cerebellar deficits and functional instability, the low neuroplasticity caused by old age and the potential self-healing effects caused by the longer duration of ankle instability might also lead to smaller between-group differences in the UK Biobank data sets (38). More controlled studies with patients who only have mechanical or functional instability are needed to fully clarify the central effects of the different types of instability.

Regarding the affected side, cerebellar lobule VIIIb is thought to be responsible for ipsilateral limb actions, but the results of the current study indicate that cerebellar activity was influenced bilaterally by unilateral ankle instability (22,24). Recent studies have suggested that the contralateral and unaffected sides of patients with previous lower-extremity injuries may also have impaired

proprioception, motor cortex excitability, and increased risk of injury (26,39,40). In addition, bilateral improvements in postural stability after unilateral rehabilitation of injured joints have also been reported (41). Various speculative hypotheses, including functional reorganization, interaction, and adaptation of the bilateral sensorimotor network, have been suggested but are accompanied by scarce substantiation (26,39,40). Our findings regarding bilateral alteration of cerebellar lobule VIIIb activity provide direct evidence of a central phenomenon, consistent with previous evidence and hypotheses. Further studies are necessary to elucidate and substantiate the underlying mechanisms.

**Research implications.** We believe that our validated results regarding less coherent activities in cerebellar lobule VIIIb could open the door for future investigations of functional neuroimaging research on ankle instability. For example, fMRI during specific tasks or regional magnetic resonance spectroscopy combined with subjective sensorimotor measurements (e.g., joint position reproduction and force matching) could contribute to our understanding. In addition, to regional activity, the bilateral cerebellar lobule VIIIb could also be applied as a seed (ROI) for functional or structural connectivity research aimed at exploring its role in the brain network of patients with ankle instability. In addition, this study did not observe a difference in the ReHo values of the cerebellar vermis, which was atrophic according to the previous morphology by Xue et al. (10). We speculate that the functional alterations of the atrophic vermis might not be neural coherence, and studies using other rs-fMRI parameters or task fMRI are needed to fully understand the deficits of the cerebellum in ankle instability.

**Clinical implications.** Considering previous theories and the current correlation between CAIT scores and lobule VIIIb activity, we consider that deteriorating organization of lobule

VIIIb may be an intrinsic pathological process associated with sensorimotor deficits in ankle instability. This finding may promote improvement of rehabilitation models and facilitate more specific ways of treating ankle instability, which leads to reorganization of the affected supraspinal structures (42,43). Various therapeutic techniques can induce positive neuroplasticity, such as balance training and supplementary noninvasive brain stimulation (8,42,43). Although the exact doses and action periods of these interventions remain unclear, more targeted treatment strategies based on the aforementioned functions of cerebellar lobule VIIIb might improve sensorimotor ability and subsequently avoid reinjuries. rs-fMRI is an accessible measurement that can be performed in any hospital equipped with MRI, and data are easily analyzed using batched software (compared with those from complex electrophysiological measurements). We suggest that the ReHo values of cerebellar lobule VIIIb may have the potential to act as clinical biomarkers to reflect the progress of treatment and ankle instability prognosis. These assumptions require longitudinal studies with long-term follow-up for clarification.

**Limitations.** This study has some limitations. First, the cross-sectional design made it difficult to detect causal relationships between abnormal neural activity and ankle instability. No significant correlation between the altered ReHo values and the duration of ankle instability was found in this study, and we speculated that the biases generated by the complexity of ankle instability (e.g., injury severity and treatment history) might obscure this potential correlation. Only a prospective cohort study including high-risk healthy individuals with repeated measurements before and after the injury could confirm the negative effect of orthopedic injury on the CNS. Second, the sample sizes of both data sets were relatively small, but we suggest that cross-data set validation might compensate for the lack of power of our observations. Third, the criteria for ankle instability used during the current study did not fully meet the International Ankle Consortium standard, and the participants' characteristics were even different between the two data sets, especially the UK Biobank data set, which is based on the medical history of an ankle instability-related diagnosis. Further studies are needed to

validate our findings in a more homogenous cohort of patients with chronic ankle instability. Fourth, the resolution of the functional images is relatively low in the primary data set because of our device limitations, which might reduce the accuracy of our detection of the cerebellum as a small region. Although the lower ReHo values of lobule VIIIb can also be observed in the UK Biobank data set, more accurate fMRI data acquisition is needed to further support our results. Last but not the least, although widely used in neuroscience research, the exact mechanism of the rs-fMRI to reflect the real-world situation remains unknown, and a more comprehensive understanding of the physiological meaning of the rs-fMRI measurements introduced by future laboratory research is essential for better interpretation of our results.

## CONCLUSIONS

Patients with ankle instability have lower intraregional coherence of local neuronal activity (ReHo values) in the bilateral cerebellar lobule VIIIb than in that of healthy controls. Decreased ReHo values were positively correlated with the intensity of self-reported ankle instability by patients. We speculated that the reduced coherence of cerebellar lobule VIIIb activity might be associated with functional ankle instability, and our findings may allow better targeting of interventions for ankle instability based on the function of the cerebellar lobule VIIIb.

This work was supported by the National Natural Science Foundation of China (Nos. 81871823, 81971583, 81671652, 8207090113), National Key R&D Program of China (No. 2018YFC1312900), Shanghai Natural Science Foundation (No. 20ZR1406400), Science and Technology Commission of Shanghai Municipality (No. 18JC1410403), and Shanghai Municipal Science and Technology Major Project (Nos. 2017SHZDZX01, 2018SHZDZX01).

There are no conflicts of interest to report. The original imaging data used to support the findings of this study have not been made available because of the patient privacy, whereas the extracted ReHo outcomes are available upon reasonable request corresponding to the senior authors (Y. H., hua\_cosm@aliyun.com; H. W., hewang@fudan.edu.cn; S. C., chenshuang6898@126.com). The results of this study are presented clearly, honestly, and without fabrication, falsification, or inappropriate data manipulation. The results of the present study do not constitute endorsement by the American College of Sports Medicine.

## REFERENCES

- Hertel J, Corbett RO. An updated model of chronic ankle instability. *J Athl Train.* 2019;54(6):572–88.
- Waterman BR, Owens BD, Davey S, Zacchilli MA, Belmont PJ. The epidemiology of ankle sprains in the United States. *J Bone Joint Surg Am.* 2010;92(13):2279–84.
- Gribble PA, Delahunt E, Bleakley C, et al. Selection criteria for patients with chronic ankle instability in controlled research: a position statement of the International Ankle Consortium. *Br J Sports Med.* 2014;48(13):1014–8.
- Doherty C, Bleakley C, Delahunt E, Holden S. Treatment and prevention of acute and recurrent ankle sprain: an overview of systematic reviews with meta-analysis. *Br J Sports Med.* 2017;51(2):113–25.
- Song Y, Li H, Sun C, et al. Clinical guidelines for the surgical management of chronic lateral ankle instability: a consensus reached by systematic review of the available data. *Orthop J Sports Med.* 2019;7(9):2325967119873852.
- Freeman MA, Dean MR, Hanham IW. The etiology and prevention of functional instability of the foot. *J Bone Joint Surg Br.* 1965;47(4):678–85.
- Pelletier R, Higgins J, Bourbonnais D. Is neuroplasticity in the central nervous system the missing link to our understanding of chronic musculoskeletal disorders? *BMC Musculoskelet Disord.* 2015;16:25.
- Needle AR, Lepley AS, Grooms DR. Central nervous system adaptation after ligamentous injury: a summary of theories, evidence, and clinical interpretation. *Sports Med.* 2017;47(7):1271–88.
- Terada M, Johnson N, Kosik K, Gribble P. Quantifying brain white matter microstructure of people with lateral ankle sprain. *Med Sci Sports Exerc.* 2019;51(4):640–6.
- Xue X, Zhang Y, Li S, Xu H, Chen S, Hua Y. Lateral ankle instability-induced neuroplasticity in brain grey matter: a voxel-based morphometry MRI study. *J Sci Med Sport.* 2021;24(12):1240–4.
- Guerra-Carrillo B, MacKey AP, Bunge SA. Resting-state fMRI: a window into human brain plasticity. *Neuroscientist.* 2014;20(5):522–33.

12. Allali G, Blumen HM, Devanne H, Pirondini E, Delval A, Van De Ville D. Brain imaging of locomotion in neurological conditions. *Neurophysiol Clin*. 2018;48(6):337–59.
13. Zuo XN, Xing XX. Test–retest reliabilities of resting-state fMRI measurements in human brain functional connectomics: a systems neuroscience perspective. *Neurosci Biobehav Rev*. 2014;45:100–18.
14. Zang Y, Jiang T, Lu Y, He Y, Tian L. Regional homogeneity approach to fMRI data analysis. *Neuroimage*. 2004;22(1):394–400.
15. Shen Y, Wang W, Wang Y, et al. Not only in sensorimotor network: local and distant cerebral inherent activity of chronic ankle instability—a resting-state fMRI study. *Front Neurosci*. 2022;16:835538.
16. Yang J, Gohel S, Vachha B. Current methods and new directions in resting state fMRI. *Clin Imaging*. 2020;65:47–53.
17. Alfaro-Almagro F, Jenkinson M, Bangerter NK, et al. Image processing and quality control for the first 10,000 brain imaging datasets from UK Biobank. *Neuroimage*. 2018;166:400–24.
18. Von Elm E, Altman DG, Egger M, Pocock SJ, Gøtzsche PC, Vandenbroucke JP. The Strengthening of Reporting of Observational Studies in Epidemiology (STROBE) statement: guidelines for reporting observational studies. *PLoS Med*. 2007;4(10):e296.
19. Benedetto U, Head SJ, Angelini GD, Blackstone EH. Statistical primer: propensity score matching and its alternatives. *Eur J Cardiothorac Surg*. 2018;53(6):1112–7.
20. Yan CG, Wang XD, Zuo XN, Zang YF. DPABI: data processing & analysis for (resting-state) brain imaging. *Neuroinformatics*. 2016;14(3):339–51.
21. Yan CG, Cheung B, Kelly C, et al. A comprehensive assessment of regional variation in the impact of head micromovements on functional connectomics. *Neuroimage*. 2013;76:183–201.
22. Diedrichsen J, Balsters JH, Flavell J, Cussans E, Ramnani N. A probabilistic MR atlas of the human cerebellum. *Neuroimage*. 2009;46(1):39–46.
23. Buckner RL, Krienen FM, Castellanos A, Diaz JC, Thomas Yeo BT. The organization of the human cerebellum estimated by intrinsic functional connectivity. *J Neurophysiol*. 2011;106(5):2322–45.
24. Stoodley CJ, Schmahmann JD. Functional topography in the human cerebellum: a meta-analysis of neuroimaging studies. *Neuroimage*. 2009;44(2):489–501.
25. Sang L, Qin W, Liu Y, et al. Resting-state functional connectivity of the vermal and hemispheric subregions of the cerebellum with both the cerebral cortical networks and subcortical structures. *Neuroimage*. 2012;61(4):1213–25.
26. Wikstrom EA, Naik S, Lodha N, Cauraugh JH. Bilateral balance impairments after lateral ankle trauma: a systematic review and meta-analysis. *Gait Posture*. 2010;31(4):407–14.
27. Cohen J. *Statistical Power Analysis for the Behavioral Sciences*. England (UK): Lawrence Erlbaum Associates; 1988.
28. Benjamini Y, Hochberg Y. Controlling the false discovery rate: a practical and powerful approach to multiple testing. *J R Stat Soc Ser B*. 1995;57(1):289–300.
29. Cooper FE, Grube M, Von Kriegstein K, et al. Distinct critical cerebellar subregions for components of verbal working memory. *Neuropsychologia*. 2012;50(1):189–97.
30. Stoodley CJ. The cerebellum and cognition: evidence from functional imaging studies. *Cerebellum*. 2012;11(2):352–65.
31. van Es DM, van der Zwaag W, Knäpen T. Topographic maps of visual space in the human cerebellum. *Curr Biol*. 2019;29(10):1689–1694.e3.
32. Boillat Y, Bazin PL, van der Zwaag W. Whole-body somatotopic maps in the cerebellum revealed with 7 T fMRI. *Neuroimage*. 2020;211:116624.
33. Hulst T, van der Geest JN, Thürling M, et al. Ageing shows a pattern of cerebellar degeneration analogous, but not equal, to that in patients suffering from cerebellar degenerative disease. *Neuroimage*. 2015;116:196–206.
34. Donchin O, Rabe K, Diedrichsen J, et al. Cerebellar regions involved in adaptation to force field and visuomotor perturbation. *J Neurophysiol*. 2012;107(1):134–47.
35. Xue X, Ma T, Li Q, Song Y, Hua Y. Chronic ankle instability is associated with proprioception deficits: a systematic review and meta-analysis. *J Sport Health Sci*. 2021;10(2):182–91.
36. Thompson C, Schabrun S, Romero R, Bialocerkowski A, van Dieën J, Marshall P. Factors contributing to chronic ankle instability: a systematic review and meta-analysis of systematic reviews. *Sports Med*. 2018;48(1):189–205.
37. Labanca L, Mosca M, Ghislieri M, Agostini V, Knaflitz M, Benedetti MG. Muscle activations during functional tasks in individuals with chronic ankle instability: a systematic review of electromyographical studies. *Gait Posture*. 2021;90:340–73.
38. Bonfanti L, Charvet CJ. Brain plasticity in humans and model systems: advances, challenges, and future directions. *Int J Mol Sci*. 2021;22(17):9358.
39. Lee JH, Lee SH, Choi GW, Jung HW, Jang WY. Individuals with recurrent ankle sprain demonstrate postural instability and neuromuscular control deficits in unaffected side. *Knee Surg Sports Traumatol Arthrosc*. 2020;28(1):184–92.
40. Fulton J, Wright K, Kelly M, et al. Injury risk is altered by previous injury: a systematic review of the literature and presentation of causative neuromuscular factors. *Int J Sports Phys Ther*. 2014;9(5):583–95.
41. Hale SA, Fergus A, Axmacher R, Kiser K. Bilateral improvements in lower extremity function after unilateral balance training in individuals with chronic ankle instability. *J Athl Train*. 2014;49(2):181–91.
42. Bruce AS, Howard JS, van Werkhoven H, McBride JM, Needle AR. The effects of transcranial direct current stimulation on chronic ankle instability. *Med Sci Sports Exerc*. 2020;52(2):335–44.
43. Taube W, Gruber M, Gollhofer A. Spinal and supraspinal adaptations associated with balance training and their functional relevance. *Acta Physiol (Oxf)*. 2008;193(2):101–16.