




Vaping as a Risk Factor for Oral Erythema Multiforme: A Case Report and Literature Review

Agustin Ninintowe T Santo ¹, Wahyu Hidayat ², Tenny Setiani Dewi ²

¹Oral Medicine Residency Program, Faculty of Dentistry, Padjadjaran University, Bandung, Indonesia; ²Department of Oral Medicine, Faculty of Dentistry, Padjadjaran University, Bandung, Indonesia

Correspondence: Wahyu Hidayat, Padjadjaran University, Jl. Sekeloa Selatan No. 1, Bandung, West Java, 40132, Indonesia, Tel +62-22-2533044, Email wahyu.hidayat@unpad.ac.id

Introduction: Erythema multiforme is a hypersensitivity reaction caused by various factors, such as viruses, chemicals, and drugs. Electronic cigarettes (e-cigarettes) or vape is a battery-powered nicotine delivery device that substitutes for traditional cigarettes. The chemical components of vaping, including propylene glycol and nicotine, can cause hypersensitivity reactions.

Objective: To report a case of oral erythema multiforme in an e-cigarettes user, treatment, and review the literature regarding the impact of these devices on oral health.

Clinical Case: A 22-year-old woman came to the Oral Medicine Department with complaints of stomatitis causing pain, eating, and drinking difficulty, which started with fever and pimple-like on the lips. She was an active vape user for one year. Extraoral examination revealed no lesions on other body parts. The serosanguinolent crusts on the lips, an erosive area on the labial commissures and tended to bleed. Intraoral examination revealed white ulcers with yellowish edges and irregular, varying sizes in several parts of the oral mucosa. The anti-HSV-1 IgG laboratory results showed non-reactive, leading to a diagnosis of oral erythema multiforme. Management of oral conditions using 0.9% NaCl compress, dexamethasone mouthwash, and hyaluronic acid, applying 2% miconazole cream on labial commissures and vaseline album cream on the dry lips, and stopping vaping. Oral condition improved in a week of therapy.

Conclusion: Erythema multiforme restricted to the mouth is rare, especially associated with electronic cigarettes. Early identification of oral ulcerative disorders is crucial for accurate diagnosis and treatment, where clinicians should consider oral erythema multiforme as a possible diagnosis.

Keywords: erythema multiforme, E-cigarette, E-cigarette vapor, mouth, vaping

Introduction

In 1860, Ferdinand von Hebra introduced the term erythema multiforme.¹ Erythema multiforme is a mucocutaneous hypersensitivity reaction caused by viruses (particularly Herpes Simplex Types I and II), bacteria (particularly Streptococci), chemicals, and medicines (penicillins, cephalosporins, sulfonamides, and analgesics).² Incidence of erythema multiforme is predicted to occur in less than 1% of adults and young people aged 20–40 years, without apparent racial influences that are more likely in women than men (1.5–1.0). Erythema multiforme lesions begin as pink or red papules and progress to plaques. The person may experience burning pain or itching as a result of this disease. This condition has a 37% recurrence rate and tends to be chronic.^{3,4}

Based on the severity and number of mucosal locations involved, erythema multiforme is subclassified into minor and major erythema multiforme.^{5–7} Erythema multiforme minor is the mildest form, characterized by target-type lesions affecting less than 10% of the body surface area (BSA) and involving only one mucosa, usually the mouth.^{5,6} Major erythema multiforme is characterized by ulceration involving more than one mucosa and target-type lesions affecting less than 10% of BSA.^{4,6} Stevens-Johnson syndrome (SJS) is a severe variant of erythema multiforme, involving more than one mucosa and generally involving less than 10% of BSA accompanied by prodromal flu-like systemic symptoms.^{4,5,8} Stevens-Johnson syndrome-Toxic epidermal necrolysis (SJS-TEN) is a condition that involves more than one mucosa

and generally involves 10–30% of BSA with prodromal symptoms that are also found in SJS.⁴ Toxic epidermal necrolysis (TEN) is an even more severe condition with involvement of more than one mucosa and detachment of the epidermis from the body surface (more than 30% BSA) and purpuric macules or atypical flat target lesions are common.^{4,5,8} Typical target skin lesions with mucosal ulceration are required to establish the diagnosis as erythema multiforme minor or major. However, there have been reported cases of oral mucosal ulceration and lip lesions typical of erythema multiforme without skin involvement which is referred to as oral erythema multiforme.^{5,6}

According to its etiology, erythema multiforme can also be induced by substances, including which are found in electronic cigarettes (e-cigarettes). E-cigarettes, commonly known as vapes, are battery-powered nicotine delivery devices promoted as a replacement for traditional cigarettes.^{9,10} Even though the Food and Drug Administration (FDA) reported that e-cigarettes and their solutions (e-liquid) contain harmful substances that are potentially toxic to people, the use of e-cigarettes continues to rise among teenagers and young adults.^{11,12}

An e-cigarettes consists of a cartridge containing e-liquid (generally propylene glycol or vegetable glycerin), a vaporization chamber, a heating element (coil), and a battery. The first commercial e-cigarettes were made in China in 2003, and in 2006 they were marketed in the United States.¹³ Vape components that are thought to trigger hypersensitivity reactions are propylene glycol, glycerin, nicotine, flavorings, or toxins produced by the aerosolization process. Apart from varying amounts of nicotine, aerosol also produces propylene glycol and vegetable glycerin, humectants that function to maintain moisture and stability and to create puffs of smoke, as well as additional flavoring ingredients to increase the attractiveness of the product.¹⁴

E-cigarettes use has significant effects on oral health. Some of the conditions that can occur in the oral cavity as a consequence of e-cigarettes consumption include xerostomia, oral candidiasis, lesions on the oral mucosa, halitosis, caries, and periodontal disease.¹¹ The oral mucosa is comprised of non-keratinized stratified squamous epithelium and a highly vascularized connective tissue known as the lamina propria. The oral mucosa is an immunocompetent area covering the inside of the mouth and functions as a physical barrier. Since the oral mucosa contains immune cells that aid in the maintenance of mucosal homeostasis, an intact and well-functioning oral mucosa is crucial for preventing immune cell reactions to antigens.^{11,15,16} Reports regarding the impact of e-cigarettes use on oral health are available, but its specific effect on the development of erythema multiforme confined to the oral cavity without involving other parts of the body appears to be undocumented. Given the limited documentation regarding disease manifestation associated with e-cigarettes use, this study reported a case of oral erythema multiforme confined to the oral cavity in an e-cigarettes user, detailing its treatment, and reviewed the literature on the impact of these devices on oral health.

Clinical Case

A 22-year-old woman came to the Department of Oral Medicine with complaints of mouth ulcers causing pain and eating and drinking difficulty persisting for a duration of one month. This condition begins with a fever and appears like pimples on the lips. Based on the anamnesis, it was discovered that she had been using pod-type vapes for about a year but had never experienced complaints like when she came for treatment. She had never smoked traditional cigarettes before starting to vape. She said the reason for trying vaping was out of curiosity, and she quite often tried different types of e-liquid with different flavors. Before her complaint, she had simply changed the type of e-liquid to a different flavor without mentioning the brand. She vapes almost every day, but not all day, only in her free time or with friends. She was a healthy individual, and before this condition appeared, she had no history of taking medications, including antibiotics, analgesics, anticonvulsants, non-steroidal anti-inflammatory drugs, and antifungals. She also had no history of drug or food allergies, but the patient has unhealthy eating habits (eating irregularly and not consuming vegetables and fruit). Extraoral examination showed no lesions on other parts of the body, while the lips of the patient had serosanguineous crusts and an erosive area at the corner of the mouth (Figure 1A), and tended to bleed. Intraoral examination revealed white ulcers with yellowish edges, irregular, varying sizes, and pain on the labial, buccal, lateral, and ventral mucosa of the tongue and floor of the mouth (Figure 1B–I).

Based on the medical history of the patient and physical examination, which revealed oral mucosal involvement but no symptoms elsewhere in the body, as well as the non-reactive anti-HSV1 IgG results, the diagnosis of vaping-related oral erythema multiforme was established. The medical condition has been classified as minor erythema multiforme. The

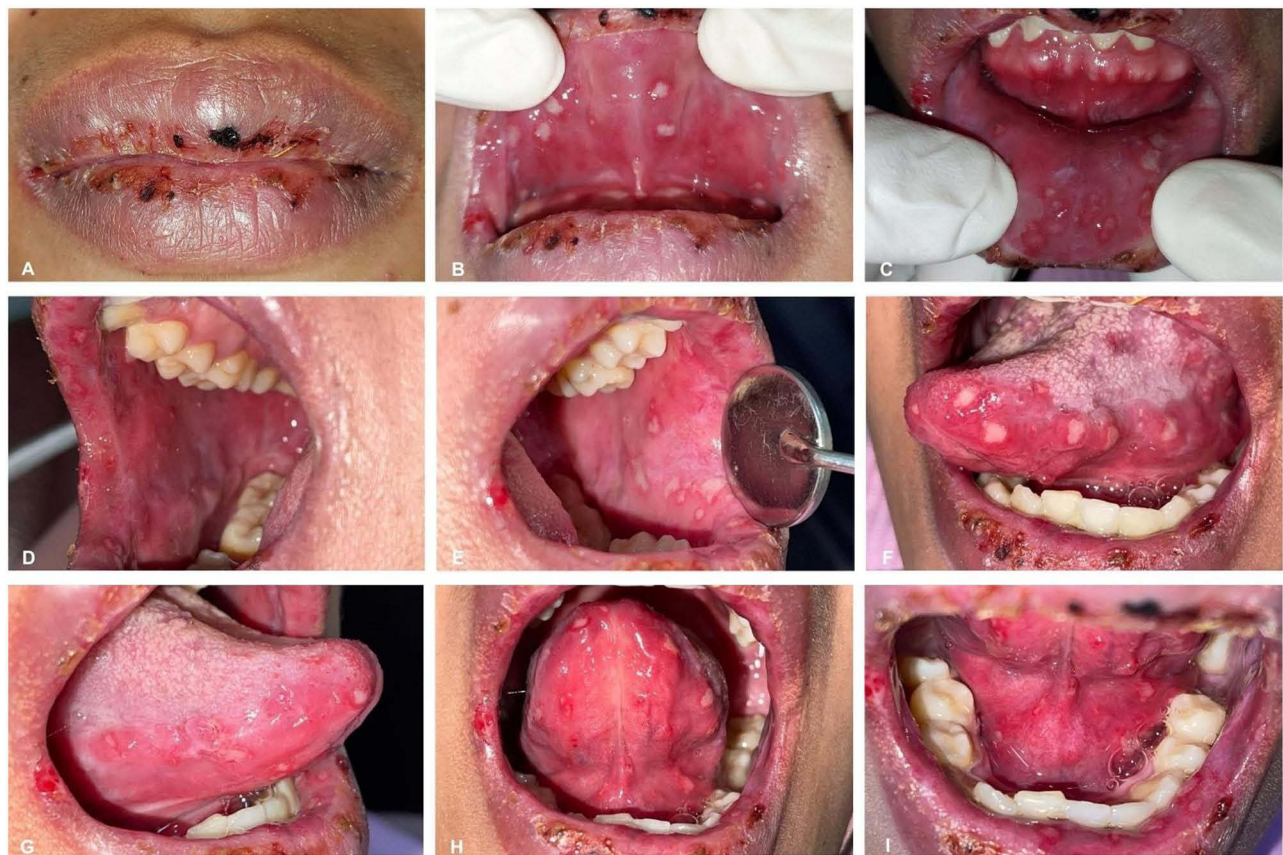

Figure 1 The clinical condition of the patient at the first visit: **(A)** serosanguinolent crusts on the lips, an erosive area on the right corner of the mouth that tended to bleed; **(B–I)** white ulcers with yellowish edges, irregular in shape, and varied in sizes on the labial, buccal, lateral, and ventral mucosa of the tongue, and the floor of the mouth.

oral conditions were treated with 0.9% NaCl, which was moistened in gauze and placed on the lips three times a day. The patient was instructed to gargle 1 mg of dexamethasone in 10 mL of hyaluronic acid three times a day and avoid eating or drinking for at least 30 minutes after gargling. She was also given 2% miconazole cream applied to the wound in the right corner of the mouth twice a day, as well as vaseline album cream for dry lips. To maintain good oral hygiene, she was advised to brush her teeth and tongue twice a day, after breakfast and before bed. She was also instructed to stop vaping and avoid foods containing monosodium glutamate (MSG). The control was carried out after a week following therapy and showed that oral condition had improved (**Figure 2A–I**). Written informed consent for the publication of details was obtained from the patient. This case report conformed with the Helsinki Declaration. The publication of this case report has also been approved by the institution.

Discussion

Erythema multiforme is a mucocutaneous hypersensitivity reaction caused by an unknown etiology. Oral lesions usually begin as erythematous macules on the lips and buccal mucosa, then progress to bullae and ulceration with uneven margins causing a burning sensation. One of the diagnostic signs of this medical condition is the presence of hemorrhagic crusts on the lips^{1,17} also feature in our report. The disease is caused by a complicated immunological system that involves antigen-antibody interactions.⁴ Erythema multiforme is a condition characterized by an acute mucocutaneous hypersensitivity reaction, with typical ulcerative skin eruptions in the form of concentric erythematous rings, known as target lesions, which may involve the oral cavity or other mucous membranes.^{5,18} Erythema multiforme, which only manifests in the oral cavity, is rare. This condition involves the oral mucosa and lip lesions without lesions in other parts of the body and is known as oral erythema multiforme.¹⁸ In the present case, serosanguineous crusts were found on the lips and an erosive area that tended to bleed at the corner of the mouth of the patient. The oral cavity revealed white

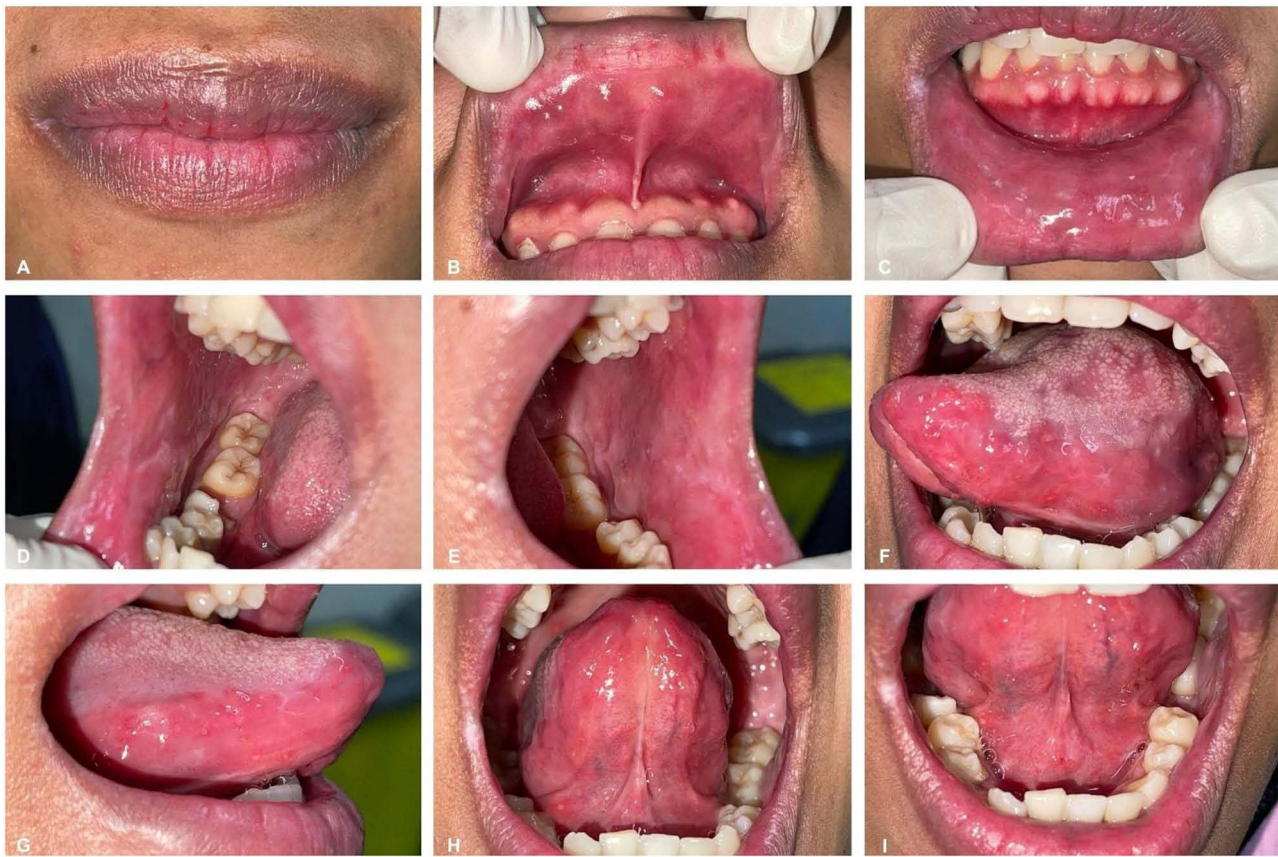

Figure 2 The clinical condition of the patient at the second visit (7 days of therapy): (A and B) the lips of the patient and the upper labial mucosa were healing; (C–I) lower labial mucosa, buccal mucosa, lateral and ventral tongue, and floor of the mouth had undergone improvement.

ulcers with yellowish edges and irregular, varying sizes on the labial, buccal, lateral, and ventral mucosae of the tongue and floor of the mouth. Manifestations in other parts of the body were not found, and no biopsy was performed. There was no history of drug use before the onset of symptoms or the involvement of a herpes simplex virus infection. The following features aid in the diagnosis of minor erythema multiforme.

The diagnosis of erythema multiforme is mainly based on the history and clinical picture because the histopathological picture and laboratory examination are nonspecific. The history generally includes acute oral and/or skin lesions, perhaps preceded by a herpes simplex virus (HSV) infection or recent drug use. This history, in combination with characteristic skin lesions and mucosal involvement, may support the diagnosis of erythema multiforme.⁴ Erythema multiforme is characterized by target-type lesions involving less than 10% BSA. If there is involvement by one mucosa, it is classified as a minor type, whereas if more than one mucosa is involved, it is classified as a major type.^{5,19,20} A biopsy is not performed if the clinical picture is clear because the histopathological findings are not pathognomonic. Histopathological features include intercellular and intracellular edema, focal formation of microvesicles, exocytosis, diffuse inflammatory infiltration, vasodilation, and connective tissue edema.^{4,5,21} As reported by Buch et al in 2017 study of a 22-year-old male with complaints of painful ulceration on the lips and severe pain for the last 7 days. The lesions appeared the day after he consumed various foods with artificial coloring. There was no medical or family history or use of any medications. Extraorally, there is extensive ulceration on the upper and lower lips, accompanied by cracks, fissures, and blood crusts, without manifestations in other parts of the body. Intraoral showed extensive ulceration with a yellow base and erythematous borders on the buccal mucosa, palate, and ventral surface of the tongue. There was tenderness on palpation. The dorsum of the tongue showed a white coating. Mouth opening was reduced due to pain around the ulceration, and there is increased salivation. There was no previous history of similar ulcers. Based on the history and clinical findings, the diagnosis was made as erythema multiforme related to an unknown food additive.¹⁸

Similar findings were reported in the current study of oral erythema multiforme, with lesions in the oral cavity and lips without any manifestation elsewhere in the body. The condition appears to be related to an allergy to vaping in an active vape user, which has never been recorded, making it a rare case. Oral lesions produce symptoms and cause impaired speech and chewing abilities¹ as complained by the patient in present case.

Although most erythema multiforme patients have a history of herpes simplex virus (HSV) infection, the trigger factors for the development of erythema multiforme remain unknown. Bacteria (*Mycoplasma pneumoniae*), viruses (Adenovirus, Enterovirus), fungal infections (Coccidioidomycosis, Dermatophytes), antibiotics (penicillins, cephalosporins, sulfonamides), non-steroidal anti-inflammatory drugs (NSAIDs), anticonvulsants (phenytoin), food ingredients (benzoate, nitrobenzene), and chemicals found in traditional and e-cigarettes are all risk factors.^{22,23} The condition is not usually accompanied by prodromal symptoms.²²

This case was discovered in Indonesia, which has a smoking population of approximately 64.9 million people and is the world's third largest smoker after China and India. According to estimates, two out of every three adult men in Indonesia smoke. Smokers (including men and women) grew from 32.8% in 2016 to 33.8% in 2018. Although low- and middle-income nations, like Indonesia, are having difficulty reducing smoking prevalence, the cigarettes business has marketed new products, one of which is e-cigarettes. E-cigarettes have been advertised and promoted as being less dangerous. However, the World Health Organization (WHO) stated unequivocally in 2020 that this product is hazardous to human health.²⁴

E-cigarettes are available in various concentrations of nicotine inside (e-liquid), various volumes, additives, flavors, and different battery voltages. The carcinogens contained in it and the aerosols produced have an impact on health, including the condition of the lungs, oral cavity, and throat. This condition may be related to the content of nitrosamines, propylene glycol (the main solvent in e-liquid contained in e-cigarettes), and flavoring substances.^{25,26} In the previous decade, e-cigarettes technologies have advanced rapidly.²⁷ This device is intended and promoted to deliver nicotine faster and at higher amounts than traditional cigarettes. Traditional cigarettes have a nicotine content of 1.5–2% (1.5–2 mg/mL), whereas e-cigarettes have a nicotine concentration of 5%, and daily usage can lead to nicotine addiction.²⁸ The initial generation of e-cigarettes devices were closed, non-refillable (disposable) systems known as cig-a-likes, which resembled cigarettes and consisted of a cartridge (cartomizer) containing e-liquid coupled to a coil and a rechargeable low-capacity battery. Later-generation devices include e-pen types (second generation) and tank-like devices (third generation), both of which are open systems, rechargeable, and reusable, and were popular among former smokers between 2015 and 2017. Third-generation open devices (modifiable e-cigarettes, or MODs) are commonly larger, with more powerful batteries, adjustable voltage and wattage, refillable e-liquid reservoirs, and removable heating coils. Fourth-generation devices (called PODs), which are popular among new e-cigarettes users and young people, are much like the first-generation's closed systems, with a low-capacity battery and a disposable pod carrying a high concentration of nicotine-laden liquid attached to a coil. In 2020, the current generation of e-cigarettes devices featured both disposable and hybrid devices with low-battery and rechargeable pods. The heating coil used to generate the aerosol in all generations of devices is typically built of a metal alloy.²⁷

According to a study of high school students in the United States, there are three primary reasons for using e-cigarettes: flavor and enjoyment (63%), experience (29%), and as a substitute for traditional cigarettes. In Germany, the most common motivations for using e-cigarettes were curiosity (73.1%), a desire to quit smoking (14.9%), and as a supplement to tobacco usage (7.5%).²⁸ A different study of e-cigarettes users in the United States found that the majority utilized second- or third-generation devices, and more than half (54%) possessed two or more devices. As many as 36% of participants used e-cigarettes (vaping) for the first time 15 minutes after waking up in the morning, 27% vaped for 5 minutes, and 56% vaped continuously throughout the day. The average voltage recorded was 4.21 V (range: 2.12–12.50 V), with 85% of individuals changing the voltage regularly. Men use higher voltages than women. According to the features and use of e-liquid, 79% of research participants obtained it from vape shops, 14% from the internet, and 7% from other sources, such as producing it themselves or from friends. Women consume less than men, while those with greater levels of education consume less than those with lower levels of education. The average number of puffs per day is roughly 200, with each puff lasting about 4 seconds. The elderly preferred higher nicotine concentrations in e-liquid and fewer puffs per day. Females preferred lower nicotine concentrations than men.²⁷

Although propylene glycol was once assumed to be rather safe, multiple studies have shown that when vaporized, it can cause substantial respiratory irritation and potentially increase the prevalence of asthma. Formaldehyde and hemiacetals such as acetaldehyde can be produced by heating propylene glycol and glycerol. Formaldehyde is a group I carcinogen with a 5–15 times greater tendency to cause cancer. Hemiacetals, such as acrolein and acetone, are formed as byproducts and induce nasal irritation, cardiovascular consequences, and lung mucosal damage. Because the carcinogenic danger of e-cigarettes grows with coil temperature, the amount will be greater in higher voltage devices. Nicotine poisoning in e-cigarettes is possible due to the device's heightened toxicity risk and the higher concentration of nicotine in the liquid. Apart from that, diacetyl, a food additive, is also used as a flavoring in e-cigarettes with a taste similar to butter, but significant concentrations of diacetyl were thought to be the cause of bronchiolitis obliterans organizing pneumonia (BOOP) in the early 2000s. Sweeteners used in e-cigarettes are also cytotoxic and contain higher levels of oxidants. The coil is made of numerous metals, including Nichrome (nickel-chrome), tungsten, stainless steel, and Kanthal (Ferritic iron-chromium aluminum alloy), and it is heated by a battery to a temperature of roughly 375–525 degrees. The coil temperature has been shown to increase exposure to toxins when device voltage increases with more powerful batteries. The long-term effects of sustained exposure to these metals' oxidation products remain unknown.²⁹

The integrity of the oral mucosal epithelium is an important feature of immune cell control; this condition is maintained by epithelial cell-linking complexes. Disorders of this condition have been linked to infections, autoimmune diseases, hypersensitivity reactions, and cancer. The association between epithelial cells and immune cells in the mucosal layer is important in the body's response to allergen exposure. When ingesting food, the oral mucosa is the first line of protection against allergies, including chemical exposure from cigarettes. Exposure to the oral mucosa induces a hypersensitive reaction in which the breakdown of these epithelial cells causes an immune response that leads to an increased risk of allergies.^{15,16,26,30}

The condition erythema multiforme is a T-cell-mediated hypersensitivity reaction to stimuli or allergens.¹ E-cigarettes, also known as vapes, are smoking devices that produce a mixture of aerosols through heating and evaporation. E-liquid used in vaping contains allergens such as nicotine, flavorings, propylene glycol, vegetable glycerin, carbonyl, and nitrosamine.^{26,31} These allergens are absorbed by the oral mucosa, which serves as a physical barrier against everything that enters the human body through the digestive tract and also contains immune cells such as cytotoxic T lymphocytes and pro-inflammatory cytokines (IL-6 and IL-8). These immune cells can cause keratinocyte apoptosis, which leads to the necrosis of oral mucosal epithelial cells and the production of sub- and intra-epithelial vesicles. This condition ultimately causes widespread blistering, erosion, and bleeding, as in oral erythema multiforme (Figure 3).^{16,32,33}

Identifying risk factors for erythema multiforme is a critical first step in delivering therapy.²³ This case discusses one of the risk factors for erythema multiforme, namely the use of e-cigarettes (vapes). Chemical-containing vapes, especially propylene glycol as the primary solvent, appear to be a risk factor for oral erythema multiforme. The patient was advised to quit vaping as a non-pharmacological therapy, which was essential for successful initial treatment. The severity of erythema multiforme with mucosal involvement determines treatment.^{4,23,33} In this case, the condition of oral erythema multiforme was treated with pharmacological therapy, including the administration of dexamethasone and hyaluronic acid mouthwash. Dexamethasone is a corticosteroid that is applied topically as an anti-inflammatory and immunosuppressive agent,³⁴ whilst hyaluronic acid mouthwash can provide analgesic support to patient.²³ A 0.9% NaCl compress is also used as pharmacological therapy to aid in the healing process. This solution does not damage tissue, cause allergies, or change the normal flora³⁵ and 2% miconazole cream, which has anti-fungal effects.³⁶

The effects of smoking traditional cigarettes and e-cigarettes have manifested in the oral cavity, including nicotine stomatitis, palatal erosion, acute necrotizing ulcerative gingivitis, black hairy tongue, burns, and keratotic spots, leukoplakia, smoker's melanosis, epithelial dysplasia, and squamous cell carcinoma.^{37,38} The active components in e-cigarettes are not regulated by the extraction process, and their suspension in e-liquid varies greatly; thus, understanding the chemical by-products of their use is less definite. The risks of inhaling these chemicals change significantly depending on the method of evaporation or heating. In addition, every part of the manufacturing process for e-cigarettes products also allows for errors and contamination, and there are many other unknown things related to potential dangers. Vaping cannot be deemed safer than traditional cigarettes because there are very serious risks to personal and public health.²⁹ This study appears to be the first documentation of a case of oral erythema multiforme confined to the oral

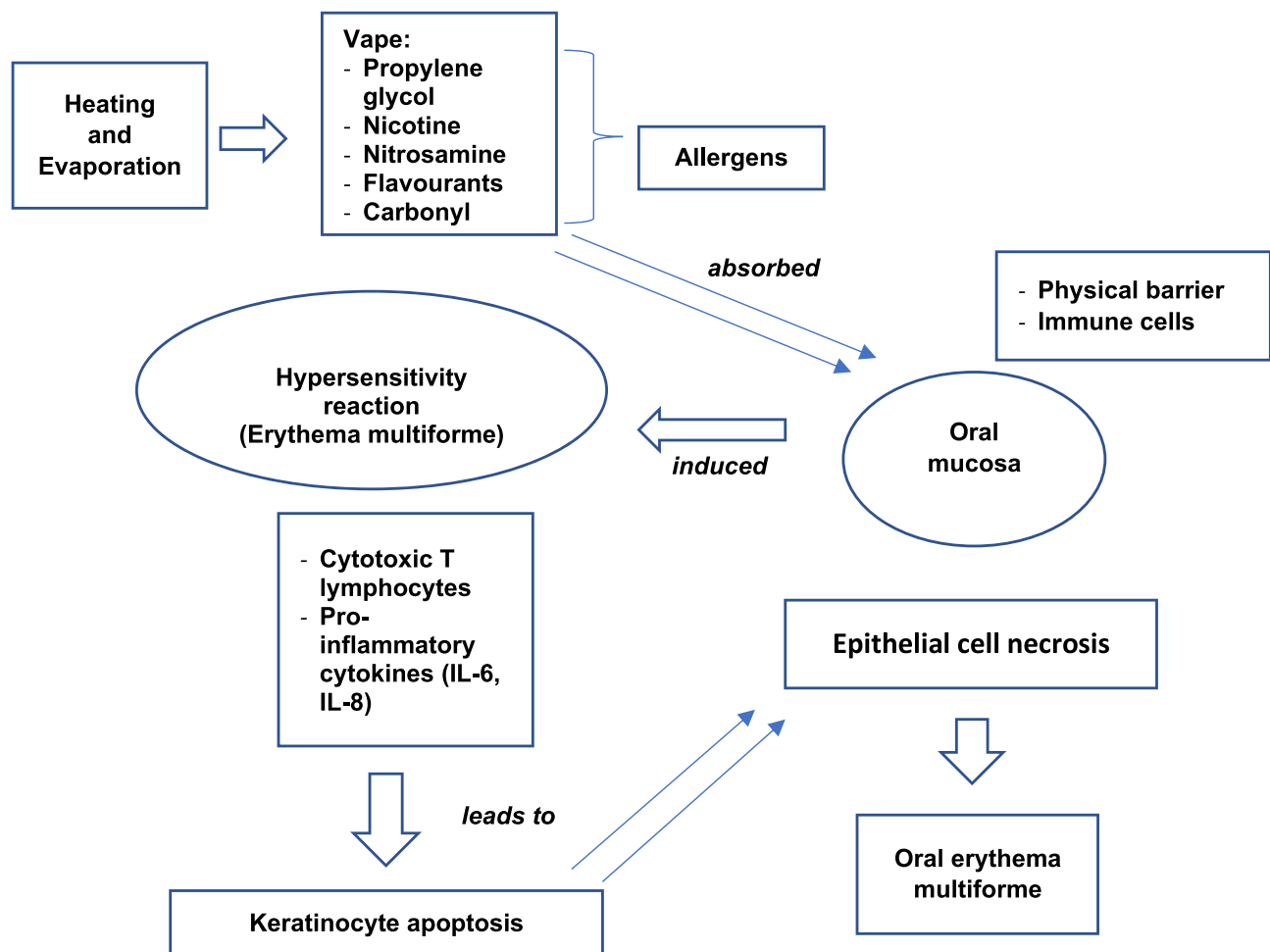


Figure 3 Mechanisms of ingredients in vape e-liquids related to the development of oral erythema multiforme.

cavity related to e-cigarettes use. The rarity of cases has also become a challenge, and further research into the potential risks of e-cigarettes use is urgently required.

Conclusion

Electronic cigarettes (e-cigarettes), commonly known as vapes, are battery-powered nicotine delivery devices promoted as a replacement for traditional cigarettes. Vape components that are thought to trigger hypersensitivity reactions are propylene glycol, nicotine, flavorings, or toxins produced by the aerosolization process. E-cigarettes use has significant effects on oral health. Reports on the effect of e-cigarette use on oral health are available; however, its effect on the development of erythema multiforme confined to the oral cavity does not appear to have been reported, so further research is still needed. The current report presents a case of oral erythema multiforme that appears to be related to allergies in an active vape user. Oral erythema multiforme restricted to the mouth is rare, especially in relation to e-cigarettes, and may pose a diagnostic challenge. It is important to identify signs and symptoms of ulcerative disorders involving the oral cavity for accurate diagnosis, early treatment, and follow-up, where clinicians should consider oral erythema multiforme as a possible diagnosis.

Acknowledgment

The authors would like to thank the patient, staff of Hasan Sadikin General Hospital for their support, and Padjadjaran University for supporting the publishing fees for this case report.

Disclosure

The authors declare no conflicts of interest in this case report.

References

1. Nair KK, Chaudhuri K, Ashok L. Erythema multiforme: a case series and review of literature. *J Trans Med Res*. 2018;2(4):124–130.
2. Herstowska M, Komorowska O, Cubala WJ, et al. Severe skin complications in patients treated with antidepressants: a literature review. *Postep Dermatologii i Alergol*. 2014;31(2):92–97. doi:10.5114/pdia.2014.40930
3. Traves KP, Love G, Studdiford JS. Erythema multiforme: recognition and management. *Am Fam Physician*. 2019;100(2):82–88.
4. Samim F, Auluck A, Zed C, et al. Erythema multiforme a review of epidemiology, pathogenesis, clinical features, and treatment. *Dent Clin N Am*. 2013;57(4):583–596. doi:10.1016/j.cden.2013.07.001
5. Isaias PHC, Bezerra TMM, Chaves FN, et al. Management of pediatric erythema multiforme restricted to the mouth and perioral region: a case report. *Rev Port Estomatol Med Dent Cir Maxilofac*. 2023;64(3):128–132.
6. Joseph TI, Vargheese G, George D, et al. Drug induced oral erythema multiforme: a rare and less recognized variant of erythema multiforme. *J Oral Maxillofac Pathol*. 2012;16(1):145–148. doi:10.4103/0973-029X.92995
7. Taqi SA. Drug-induced oral erythema multiforme: a diagnostic challenge. *Ann Afr Med*. 2018;17(1):43–45. doi:10.4103/aam.aam_19_17
8. Osterne RLV, de Matos Brito RG, Pacheco IA, et al. Management of erythema multiforme associated with recurrent herpes infection: a case report. *J Can Dent Assoc*. 2009;75(8):597–601.
9. Bardellini E, Amadori F, Conti G, et al. Oral mucosal lesions in electronic cigarettes consumers versus former smokers. *Acta Odontol Scand*. 2018;76(3):226–228. doi:10.1080/00016357.2017.1406613
10. Doddawad VG. Effect of E-cigarettes on oral health. *J Oral Hyg Health*. 2021;9(8):1–6.
11. Alhaji MN, Al-Maweri SA, Folayan MO, et al. Oral health practices and self-reported adverse effects of E-cigarette use among dental students in 11 countries: an online survey. *BMC Oral Health*. 2022;22(1):1–9. doi:10.1186/s12903-022-02053-0
12. Tsiouma O, Andreou A, Sklavounou-Andrikopoulou A. E-cigarette and palatal ulcer: a possible relationship? *Oral Surg*. 2021;14(1):59–64. doi:10.1111/ors.12499
13. Cobb NK, Solanki JN. E-Cigarettes, Vaping Devices, and Acute Lung Injury. *Respir Care*. 2020;65(5):713–718. doi:10.4187/respcare.07733
14. Bousquet J, Bachert C, Alexander LC, et al. Hypothesis: may e-cigarette smoking boost the allergic epidemic? *Clin Transl Allergy*. 2016;6(40):1–4. doi:10.1186/s13601-016-0130-y
15. Moutsopoulos NM, Konkel JE. Tissue specific immunity at the oral mucosal barrier. *Trends Immunol*. 2018;39(4):276–287. doi:10.1016/j.it.2017.08.005
16. Gomez-Casado C, Sanchez-Solares J, Izquierdo E, et al. Oral mucosa as a potential site for diagnosis and treatment of allergic and autoimmune diseases. *Foods*. 2021;10(970):1–22. doi:10.3390/foods10050970
17. Mortazavi H, Safi Y, Baharvand M, et al. Diagnostic features of common oral ulcerative lesions: an updated decision tree. *Int J Dent*. 2016;2016:1–14. doi:10.1155/2016/7278925
18. Buch SA, Babu SG, Castelino RL, et al. A rare case of oral erythema multiforme: a case report with a literature review. *J Dent Indones*. 2017;24(2):55–58. doi:10.14693/jdi.v24i2.1065
19. Ayango L, Rogers RS. Oral manifestations of erythema multiforme. *Dermatol Clin*. 2003;21(1):195–205. doi:10.1016/S0733-8635(02)00062-1
20. La Placa M, Chessa MA. Erythema multiforme major with swollen lips and crusted erosions. *Lancet*. 2018;392(10147):592. doi:10.1016/S0140-6736(18)31770-7
21. Lamoreux MR, Sternbach MR, Hsu WT. Erythema multiforme. *Am Fam Physician*. 2006;74(11):1883–1888.
22. Hasan S, Jangra J, Choudhary P, et al. Erythema multiforme: a recent update. *Biomed Pharmacol J*. 2018;11(1):167–170. doi:10.13005/bpj/1358
23. Soares A, Sokumbi O. Recent updates in the treatment of erythema multiforme. *Medicina*. 2021;57(921):1–8. doi:10.3390/medicina57090921
24. Bigwanto M, Arumsari I, Fauzi R. The portrayal of electronic cigarettes in Indonesia: a content analysis of news media. *BMC Public Health*. 2023;23(52):1–10. doi:10.1186/s12889-022-14886-z
25. Qasim H, Karim ZA, Rivera JO, et al. Impact of electronic cigarettes on the cardiovascular system. *J Am Heart Assoc*. 2017;6(9):e006353. doi:10.1161/JAHA.117.006353
26. Ebersole J, Samburova V, Son Y, et al. Harmful chemicals emitted from electronic cigarettes and potential deleterious effects in the oral cavity. *Tob Induc Dis*. 2020;18:1–16. doi:10.18332/tid/116988
27. Aherrera A, Aravindakshan A, Jarmul S, et al. E-cigarette use behaviors and device characteristics of daily exclusive e-cigarette users in Maryland: implications for product toxicity. *Tob Induc Dis*. 2020;18(93):1–10. doi:10.18332/tid/128319
28. Becker TD, Rice TR. Youth vaping: a review and update on global epidemiology, physical and behavioral health risks, and clinical considerations. *Eur J Pediatr*. 2022;181(2):453–462. doi:10.1007/s00431-021-04220-x
29. Laucks P, Salzman GA. The Dangers of Vaping. *Missouri Med*. 2020;117(2):159–164.
30. Brar E, Saxena A, Dukler C, et al. Vaping, SARS-CoV-2, and multisystem inflammatory syndrome: a perfect storm. *Front Pediatr*. 2021;9(647925):1–7. doi:10.3389/fped.2021.647925
31. Xu F, Aboseria E, Janal MN, et al. Comparative effects of E-cigarette aerosol on periodontium of periodontitis patients. *Front Oral Heal*. 2021;2(729144):1–10.
32. Polosa R, Casale TB, Tashkin DP. A close look at vaping in adolescents and young adults in the United States. *J Allergy Clin Immunol Pract*. 2022;10(11):1–11.
33. Kohli PS, Kaur J. Erythema multiforme-oral variant: case report and review of literature. *Indian J Otolaryngol Head Neck Surg*. 2011;63(S1):S9–S12. doi:10.1007/s12070-011-0169-y
34. Kiran MS, Vidya S, Aswal GS, et al. Systemic and topical steroids in the management of oral mucosal lesions. *J Pharm Bioall Sci*. 2017;9:S1–S3.
35. Santos E, Queiros P, Cardoso D, et al. The effectiveness of cleansing solutions for wound treatment: a systematic review. *J Nurs Referência*. 2016;9:133–143.

36. Pandarathodiyil AK, Anil S, Vijayan SP. Angular cheilitis - an updated overview of the etiology, diagnosis, and management. *Int J Dentistry Oral Sci.* 2021;8(2):1433–1438.
37. Alade O, Folayan MO, Adeniyi A, et al. Differences in oral lesions associated with tobacco smoking, E-cigarette use and COVID-19 infection among adolescents and young people in Nigeria. *Int J Environ Res Public Health.* 2022;19(17):10509. doi:10.3390/ijerph191710509
38. Holliday R, Chaffee BW, Jakobovics NS, et al. Electronic cigarettes and oral health. *J Dent Res.* 2021;100(9):906–913. doi:10.1177/00220345211002116

International Medical Case Reports Journal

Dovepress

Publish your work in this journal

The International Medical Case Reports Journal is an international, peer-reviewed open-access journal publishing original case reports from all medical specialties. Previously unpublished medical posters are also accepted relating to any area of clinical or preclinical science. Submissions should not normally exceed 2,000 words or 4 published pages including figures, diagrams and references. The manuscript management system is completely online and includes a very quick and fair peer-review system, which is all easy to use. Visit <http://www.dovepress.com/testimonials.php> to read real quotes from published authors.

Submit your manuscript here: <https://www.dovepress.com/international-medical-case-reports-journal-journal>