

Arthroscopic Drilling for Stable Juvenile Osteochondritis Dissecans of the Knee Is Safe and Patients Reliably Return to Daily Activities by 3 Months



Soroush Baghdadi, M.D., David Isaacs, B.A., Calvin T. Chan, B.A., Lawrence Wells, M.D., Theodore J. Ganley, M.D., and J. Todd R. Lawrence, M.D., Ph.D.

Purpose: To assess the postoperative timeline for the return to activities of daily living (ADLs) in pediatric patients after arthroscopic drilling of a stable osteochondritis dissecans (OCD) lesion of the knee and to determine the rate of and risk factors for complications after the procedure. **Methods:** In a retrospective chart review, data from all patients aged 18 years or younger who underwent arthroscopic drilling for a stable OCD lesion of either femoral condyle from May 2009 through July 2017 were collected. Demographic data, lesion characteristics, operative data, postoperative course, radiographic outcomes, and complications were recorded. Statistical analysis was performed to determine the risk factors for reoperations. **Results:** A total of 139 knees in 131 patients were evaluated, with a mean age of 12.7 years, of which 102 (73%) were male knees. The average follow-up period was 17.8 ± 13.2 months after surgery. All patients regained full extension and flexion within 5° of the contralateral knee at a mean of 12.9 ± 3.2 weeks postoperatively, with 95% having returned fully to ADLs by the 3-month postoperative visit. No cases of infection, stiffness, arthrofibrosis, or other procedure-related complications were recorded. A total of 133 knees (95.7%) showed healing on radiographs, whereas 6 knees (4.3%) underwent additional surgical procedures, all of which were performed for treatment failure related to nonhealing lesions (including loose body removal, chondroplasty, and repeated drilling). Lesion size was the only significant risk factor for reoperation ($P = .02$). **Conclusions:** Our findings suggest that arthroscopic drilling for stable, intact OCD lesions in the pediatric knee is a safe procedure with reliable outcomes and return to ADLs and a minimal risk of complications. Most patients return to their preoperative daily activity level with a full range of motion of the knee by 3 months after surgery. Complications, including reoperations, are related to the progression of the OCD lesion rather than to the surgical procedure. Each 1-cm² increase in lesion size increases the likelihood of reoperation by 2.93 times. **Level of Evidence:** Level IV, therapeutic case series.

From the Division of Orthopaedics, Children's Hospital of Philadelphia, Philadelphia, Pennsylvania, U.S.A.

The authors report the following potential conflicts of interest or sources of funding: D.I. reports a \$750 research grant from the College Alumni Society of University of Pennsylvania to fund summer research for undergraduates at the University of Pennsylvania. L.W. receives personal fees from Zimmer Biomet, Allergan, and Synthes, outside the submitted work. T.J.G. receives personal fees from Vericel, Arthrex, Allosource, and Liberty Surgical, outside the submitted work. J.T.R.L. receives royalties from Sawbones, outside the submitted work. Full ICMJE author disclosure forms are available for this article online, as [supplementary material](#).

Received May 6, 2021; accepted December 1, 2021.

Address correspondence to J. Todd R. Lawrence, M.D., Ph.D., Department of Orthopaedic Surgery, Division of Orthopedics, Children's Hospital of Philadelphia, 3401 Civic Center Blvd, Second Floor, Wood Bldg, Philadelphia, PA 19104, U.S.A. E-mail: lawrencej@email.chop.edu

© 2022 THE AUTHORS. Published by Elsevier Inc. on behalf of the Arthroscopy Association of North America. This is an open access article under the CC BY-NC-ND license (<http://creativecommons.org/licenses/by-nc-nd/4.0/>). 2666-061X/21684

<https://doi.org/10.1016/j.asmr.2021.12.006>

Osteochondritis dissecans (OCD) of the knee is a relatively common cause of knee pain in the pediatric population, with a reported incidence of 9.5 to 29 per 100,000.^{1,2} Early in the disease process, the changes in the subchondral bone may be reversible, especially in children, and the articular cartilage may be saved entirely.³ However, with progression of the lesion, instability and separation of the lesion may lead to damage or loss of the articular cartilage and thus cause long-term dysfunction and pain.⁴⁻⁶

There are a range of possible treatments for OCD lesions, from nonoperative treatment approaches, including bracing and activity modification, to operative treatment approaches, including drilling for stable, intact lesions, and progressing all the way up to fixation or cartilage restoration procedures for unstable lesions.⁵⁻⁸ Most authors agree that skeletal maturity and

lesion stability are the most important factors guiding treatment decisions.^{6,7,9-12}

The most widely accepted initial treatment for stable, intact lesions in skeletally immature patients is nonoperative treatment.^{6,8-11,13-15} Transarticular or retroarticular arthroscopic drilling is a treatment option when nonoperative treatment does not lead to radiographic ossification and clinical healing of the lesion.^{6,11,13,16-18} Drilling breaches the sclerotic margins of the lesion and is believed to promote healing by releasing the underlying growth factors in the cancellous bone, and it has been noted to have a predictably high success rate of 82% to 98% in lesions for which nonoperative treatment has failed.^{6,8-11,13,16,18-25} The optimal duration during which to pursue nonoperative treatment prior to proceeding with operative treatment is unknown, but periods of 3, 6, and 12 months or longer are common practices in many centers.^{6,11,13,16,26} Ultimately, the decision to proceed to operative treatment requires a discussion with the family, weighing the risks and benefits of continued nonoperative management versus the risks and benefits of surgical intervention. From a patient and family perspective, knowing the impact of the operation on the patients' lives and when they can expect to be back to normal after the procedure is often quite important in helping them make this treatment decision.

However, although there are abundant data suggesting that OCD drilling is an effective treatment, there are few data specifically evaluating the impact that the procedure has on the patient's daily life or the complications of the procedure. The purposes of this study were to assess the postoperative timeline for the return to activities of daily living (ADLs) in pediatric patients after arthroscopic drilling of a stable OCD lesion of the knee and to determine the rate of and risk factors for complications after the procedure. We hypothesized that most patients would be back to their normal daily activities by 3 months after surgery and that the risk of complications would be minimal.

Methods

After we obtained approval from our institutional review board (Children's Hospital of Philadelphia, No. 15-012614), a retrospective review was conducted of patients presenting to our tertiary-care pediatric orthopaedic surgery center from May 2009 through July 2017. Patients undergoing arthroscopic drilling of an OCD lesion of the knee were identified based on a query for Current Procedural Terminology (CPT) code 29886 (arthroscopic drilling of intact OCD lesion). The inclusion criteria included patients aged 18 years or younger who underwent arthroscopic drilling for stable, intact OCD lesions of the knee. Lesion stability was determined based on arthroscopic assessment at the time of surgery. Patients with less than 6 months of

follow-up, patients with associated lesions (e.g., anterior cruciate ligament injury), and patients who underwent an additional procedure for an OCD lesion of the same knee (fixation, chondroplasty, osteochondral allograft, or autogenous chondrocyte implantation) were excluded. Patients with trochlear and patellar lesions were also excluded. For patients who underwent bilateral surgical procedures, each knee was considered individually.

Demographic data included age, sex, and body mass index percentile. Obesity status was determined based on Centers for Disease Control and Prevention guidelines normalized to age.²⁷ The duration of nonoperative treatment, defined as the time from the first orthopaedic visit that led to a form of nonsurgical treatment (brace, physical or occupational therapy, and/or weight-bearing limitations) until the time of surgical intervention, was extracted from records of preoperative visits. However, we did not include the duration of nonoperative treatment that patients received prior to undergoing care at our institution.

Magnetic resonance imaging (MRI) scans were reviewed to measure lesion size. Proton density or T1-weighted cuts were reviewed, and the maximal sagittal size and coronal size of the lesion were measured from bone edge to bone edge. On the basis of these measurements, the surface area of the lesion was calculated as an oval (ellipse) with 2 axes. In addition, the status of the physis was assessed on sagittal T2-weighted MRI scans and was recorded as follows: open (when the cartilage signal was visible across the entire femur), closing (when the cartilage signal was incomplete on any image), or closed (when no cartilage signal was present on sagittal cuts). All MRI measurements were performed by a fellowship-trained pediatric orthopaedic surgeon (S.B.). Type of anesthesia and drilling technique (transarticular or retroarticular) were extracted from operative notes.

All patients were treated by a standard arthroscopic technique at our center, as previously described in detail.^{20,23,24} Our routine postoperative clinic visits, which include visits at 1 to 2 weeks, 1 month, 3 months, and 6 months, were reviewed, and the postoperative immobilization time, duration of weight-bearing limitation, and time to full knee range of motion (ROM) were recorded. At our institution, ROM is typically compared with the contralateral side and is not measured with a goniometer. ROM at each visit was recorded, and whether the patient had returned to ADLs was assessed. A successful return to ADLs was defined as a pain-free return to all preoperative activities barring sports activities (e.g., unlimited mobility at home and outside and no functional limitations at school). The time to return to sports (RTS) was determined as the time from surgery until the visit in which the patient was allowed to start the progression toward

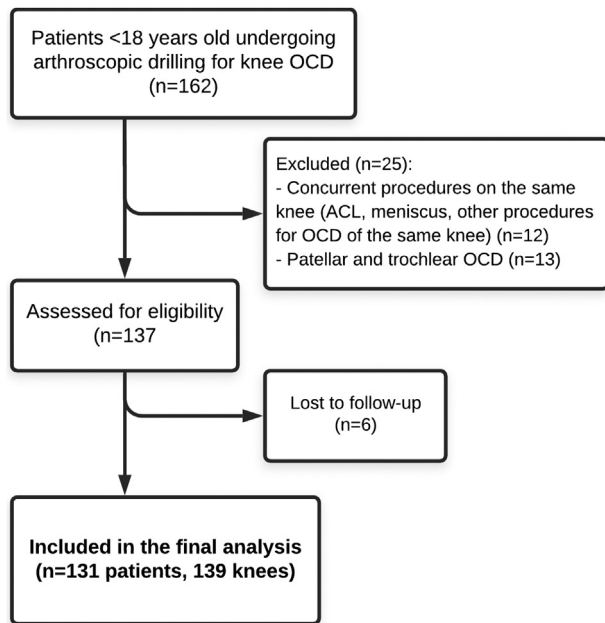


Fig 1. Flowchart of patient selection in study. (ACL, anterior cruciate ligament; OCD, osteochondritis dissecans.)

unrestricted sports activity. At our institution, patients are typically cleared to RTS when painless, full ROM is present and evidence of healing is observed on interval radiographs. All complications during the follow-up period, including but not limited to stiffness, reoperation, pain, and infection (superficial and deep), were extracted from records of the follow-up visits. Healing was defined as progressive improvement of symptoms and radiographic evidence of healing on anteroposterior, lateral, and notch-view radiographs 6 months after surgery. All radiographs and MRI scans were reviewed by a fellowship-trained pediatric orthopaedic surgeon (S.B.).

Statistical Analysis

Statistical analysis was performed using SPSS Statistics for Windows (version 26.0; IBM, Armonk, NY) with 2-tailed analyses; $P < .05$ was considered statistically significant. Descriptive statistics were used to evaluate frequencies and means. A multivariate binary logistic regression model was used to determine the effect of age, sex, physal status, obesity status, laterality, surgical technique (retroarticular vs transarticular drilling), and lesion size on the likelihood of patients requiring reoperation.

Results

During the study period, 162 knees underwent arthroscopic OCD drilling at our institution. After exclusion of patients with non-femoral condyle OCD lesions, as well as those with associated pathologies and incomplete follow-up, a total of 139 involved knees in

131 patients met our inclusion criteria (Fig 1). Of these 139 knees, 102 (73%) were male knees, with a nearly symmetrical side distribution (52% right and 48% left). The mean age at the time of surgery was 12.7 years (range, 9-18 years). Patients were followed up for a mean of 17.8 ± 13.2 months (range, 6-65 months) after surgery.

A total of 37 patients (28.2%) had bilateral symptoms at any time during the study period, of whom 21 (16% of total patients) had bilateral lesions on MRI scans (Fig 2). Eight patients received bilateral drilling, and both knees were included in the analysis. Of the remaining 13 patients who did not receive drilling on the other knee, 3 underwent a more complex surgical procedure on the contralateral knee, 7 had lesions that healed without needing surgery, and 3 received surgery at outside institutions. Prior to surgery, patients were treated nonoperatively for a mean of 6.76 ± 6.6 months (range, 1-30 months). At the time of surgery, 108 knees (78%) had open physes, 19 (14%) had closing physes, and 12 (8%) had fully closed physes. At the time of surgery, only 3 patients (2%) were underweight whereas 83 (60%) had a normal weight, 32 (23%) were overweight, and 21 (15%) were obese.

The average size of the OCD lesion was 3.00 ± 1.49 cm² (range, 0.79-8.16 cm²). There were 127 medial femoral condyle lesions (90%) and 12 lateral femoral condyle lesions (10%), with 2 patients having 2 lesions in the same knee. A transarticular drilling technique was used in 127 knees (91%), whereas retroarticular drilling was performed in 12 (9%). Only 24 surgical procedures (17.2%) were performed with the patient under general anesthesia alone. Nerve blocks were used in addition to general anesthesia in the remainder of the surgical procedures: single-shot femoral block in 66 patients (47%), single-shot femoral and sciatic block in 45 patients (32%), adductor block in 2 patients (1%), and femoral catheter in 2 patients (1%).

Postoperative Course, Outcomes, and Complications

All patients were fitted with a brace after surgery. The brace was locked in extension for 6 weeks and was taken off only for ROM exercises and bathing. All patients were restricted to toe-touch weight bearing initially. In 53 of 139 patients (38%), toe-touch weight bearing was continued for 6 weeks, whereas 86 of 139 (62%) were allowed to gradually advance weight bearing after the first 1 to 2 weeks postoperatively. All patients regained full knee ROM, at a mean of 12.9 ± 3.2 weeks postoperatively (range, 4.5-24 weeks), with 129 patients (93%) having full ROM by the time of the 3-month visit. At the 3-month visit, 132 patients (95%) had returned to their preoperative level of ADLs; however, of the 5 patients who had not returned to their preoperative level of ADLs at the 3-month mark, 3

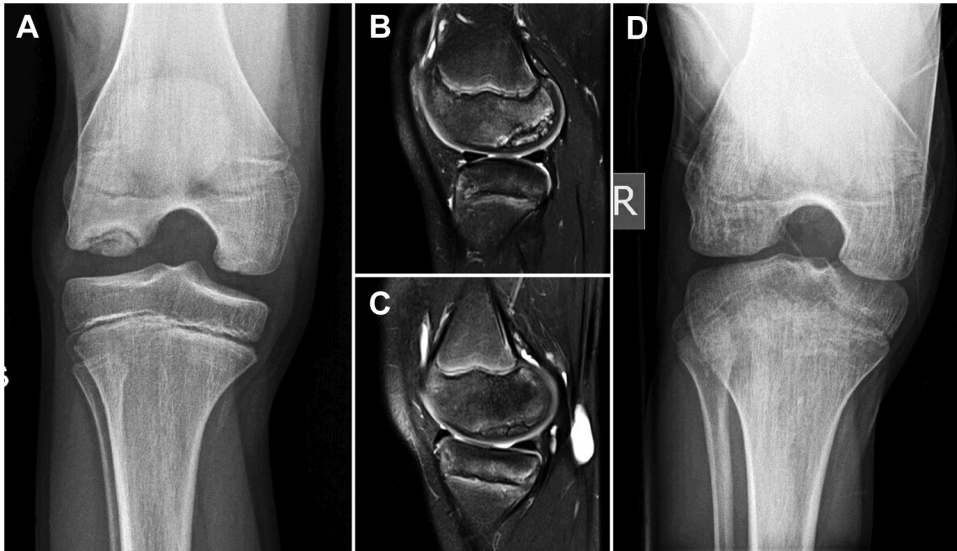


Fig 2. Imaging in a 12-year-old boy with a 1-year history of bilateral knee pain and osteochondritis dissecans unresponsive to nonoperative treatment. (A) Two lesions in the right knee were evident on the preoperative tunnel view. (A, B) Sagittal T2-weighted magnetic resonance images showed a 25 × 15-mm lateral femoral condyle lesion (B) and 23 × 12-mm medial femoral condyle lesion (C). The observation of no breaks in the articular cartilage suggested a stable lesion, which was confirmed on arthroscopic examination. (D) At 1 year postoperatively, both lesions were completely healed; the patient was pain free and had returned to sports activity. Of note, this patient had a fraternal twin who also had bilateral knee osteochondritis dissecans. (R, right.)

were recovering from surgery on the contralateral knee and 2 had sustained an unrelated injury. Thus, ADLs were not limited in any patient at the 3-month mark as a result of the OCD drilling operation. At 3 months postoperatively, only 2 patients (1%) had any pain or discomfort from the initial operation. Patients were cleared to gradually RTS at a mean of 20.9 ± 0.8 weeks after surgery.

No cases of infection (superficial or deep), stiffness, arthrofibrosis, or other procedure-related complications (including intraoperative complications such as broken guidewires) were recorded. Overall, 133 knees (95.7%) were asymptomatic and showed evidence of healing on radiographs at 6 months postoperatively, whereas 6 knees (4%) underwent 7 additional surgical procedures during the follow-up period, all of which were considered to be for treatment failure related to nonhealing lesions rather than complications related to the initial operation (Table 1). It is interesting to note that all of these patients achieved full ROM, were pain free, and had returned to all ADLs by 3 months postoperatively. At the latest follow-up, only 2 knees (1%) were painful; these were observed in 1 patient who underwent 2 reoperations (case 6 in Table 1) and 1 patient who had a painful knee despite an MRI scan confirming a fully healed lesion.

A multivariate binary logistic model showed that age, sex, lesion location, laterality (unilateral or bilateral lesion), physeal status (open vs closing or closed), obesity status, duration of nonoperative treatment, and drilling technique (retroarticular or transarticular) did not increase the likelihood of reoperation (Table 2).

However, lesion size was a significant risk factor for reoperation, and for each 1-cm² increase in size, the odds of requiring a reoperation increased by 2.93 times ($P = .02$).

Discussion

The principal findings of this study were that arthroscopic drilling of a juvenile OCD lesion is a quite safe procedure and that, by 3 months, most of the patients (95%) are back to their preoperative baseline. Even though all of the patients were immobilized for 6 weeks postoperatively, by the 3-month follow-up visit, 93% of patients had recovered full ROM of the knee, and no patients had limitations in their daily activities as a result of the operation. No cases of arthrofibrosis were noted, and all patients eventually recovered ROM within 5° of full knee ROM. There were no documented complications specifically attributable to the surgical procedure itself or the standard postoperative immobilization protocol. Moreover, no infections were noted, either superficial or deep. Although there was a 4% rate of reoperation, all cases of reoperation were because of nonhealing lesions (Table 1).

Arthroscopic drilling is a treatment option for stable OCD lesions for which nonoperative treatment fails.¹⁷ Whereas previous studies have focused on proving the results of drilling in terms of radiographic healing, in this study, we specifically evaluated a large cohort of patients undergoing arthroscopic drilling to evaluate the occurrence of complications and reoperations related to the surgical procedure and the impact that the operation has on the ability of patients to carry on

Table 1. Treatment Details and Outcomes of Patients Who Underwent Reoperation

No.	Sex/Age at Initial Surgery, yr	Details	Final Outcome
1	F/10	Pain initially resolved but the patient was re-evaluated for recurrence of pain and locking 20 mo later. Reoperation was performed 2 yr after the index surgical procedure for loose body removal and repeated drilling.	No pain, full return to activities
2	F/12	The patient underwent bilateral drilling initially with resolution of symptoms. Recurrence of pain ensued on the left side 9 mo after surgery, in addition to clicking and popping. MRI showed a nonhealing lesion. The patient underwent repeated drilling and a loose body removal procedure 2 yr after the index operation.	Full resolution of symptoms bilaterally
3	M/12	The patient had bilateral OCD lesions, with MFC and LFC lesions in the left knee. The patient was symptom free for 2 yr but was re-evaluated because of pain and nonhealing of the MFC lesion. The patient underwent repeated drilling and removal of frayed cartilage 2.5 yr after the index operation.	Mild, intermittent pain in left knee without mechanical symptoms; full return to activities; radiographs still showing lucency of lesion
4	M/14	The patient underwent staged, bilateral drilling, with a full return to sports. Acute pain and locking in the left knee developed 2.5 yr later, and the patient underwent loose body removal, as well as debridement and microfracture of the denuded cartilage and subchondral bone.	Minimal pain, no mechanical symptoms
5	M/14	Pain resolved initially, but the patient was re-evaluated because of recurrent pain and a nonhealing lesion 1 yr later. The patient underwent repeated drilling and debridement of the frayed cartilage 2 yr after the index operation.	No pain or mechanical symptoms, return to previous sports
6	M/17	Pain and limping did not resolve after surgery. MRI showed progression of the lesion, and the patient underwent chondroplasty of the nonviable cartilage 2 yr after the index procedure. The patient underwent ACI 7 mo later at another institution.	Moderate pain, clicking, locking; scheduled for surgery owing to overgrowth of ACI graft

ACI, autologous chondrocyte implantation; F, female; LFC, lateral femoral condyle; M, male; MFC, medial femoral condyle; OCD, osteochondritis dissecans.

with their daily activities. Our findings corroborate the excellent healing potential of stable knee OCD lesions with arthroscopic drilling found in previous reports.^{5,7,15,19,20,24,28,29}

When we consider the impact of an intervention on a patient, the time until he or she is “back to normal” is often a significant concern that helps drive the decision to undergo surgery. Although resolution of pain has been reported in many studies, there is a paucity of data on the time required to regain full ROM and the time required to return to regular daily activities.^{6,19-21,24,30-32} Because these variables constitute an important part of the discussion with the patient and his or her family during the shared decision-making process when considering the downside risk of surgery,

we also sought to assess these factors. All patients in this study eventually regained full knee ROM, and 93% did so by the time of their 3-month postoperative visit. Furthermore, essentially all of the patients who were not recovering from another surgical procedure or an unrelated injury had returned to their preoperative routine daily lives (with the exception of sports participation) by the 3-month visit. Thus, given that all of these OCD patients will likely have had activity restrictions prior to their drilling procedure, it seems reasonable to counsel a patient and family that most patients will be pain free and back to their previous status by 3 months after surgery.

We also evaluated the time to clearance for RTS. In our series, patients were cleared to progress back to

Table 2. Multivariate Binary Logistic Model Predicting Likelihood of Reoperation Based on Perceived Risk Factors

Variable	Wald	P Value	Exp(B)	95% CI for Exp(B)
Age	0.19	.65	1.16	0.59-2.26
Sex	0.58	.44	0.36	0.02-4.91
Physcal status (open vs closing or closed)	0.00	.99	0.99	0.07-13.50
Laterality (unilateral vs bilateral)	2.20	.13	4.38	0.62-30.83
Obesity (underweight or normal weight vs overweight or obese)	1.40	.23	0.23	0.02-2.59
Technique (retroarticular vs transarticular drilling)	0.08	.77	1.50	0.09-23.66
Duration of nonoperative treatment	0.18	.66	0.96	0.82-1.13
Size	5.05*	.02*	2.93*	1.13-6.56*

CI, confidence interval.

*Significant value.

sports activities at a mean of 20.9 weeks after surgery. Only a few studies in the literature have reported the time to RTS after drilling, and our findings seem to be in line with the findings of these prior reports: Adachi et al.²⁸ reported that 78% of their patients had returned to sports 6 months after retroarticular drilling. Moreover, Yonetani et al.²⁹ reported that all of their patients had returned to sports activities at 6 months after transarticular drilling.

The healing potential of OCD lesions in skeletally immature patients with nonoperative treatment is well documented, with smaller lesions in younger patients tending to have better outcomes.^{5,14,15,18,25} Despite the good healing potential of apparently stable OCD lesions in these patients, not all lesions heal, and thus the decision on how and when to proceed with surgical treatment necessarily includes an estimate of the risk-benefit ratio of continued nonoperative treatment relative to operative treatment. This decision regarding risks versus benefits includes a realistic estimate of the healing potential of the patient's lesion with nonoperative and operative treatment approaches. However, it should also include a realistic picture of the impact of the treatment course on the patient's overall quality of life during the treatment period. Patients and surgeons are often dissuaded from pursuing effective operative treatments because of low-frequency but high-acuity complications. These data suggest that the complication rate is realistically below 1% for this operation and that the greatest risk of the procedure is that it does not actually induce a healing response.

The need for another operation is always a concern when there is a consideration to undergo surgical treatment. In our series, a total of 7 reoperations in 6 patients (4%) were observed during the study period. Of note, all patients except 1 had a full recovery from the initial drilling operation with resolution of symptoms. In the patients who underwent reoperations, pain and mechanical symptoms recurred 1 to 2.5 years after the initial surgical procedure. An analysis of these cases suggested that all of these reoperations were because of incomplete healing of the initial pathology rather than sequelae related to the initial operation. This 4% reoperation rate for healing failure compares favorably with previously reported rates: Adachi et al.²⁸ reported a 5% rate of healing failure (1 of 20 patients), whereas Edmonds et al.²⁴ reported a 13% reoperation rate (7 of 59 patients).

In our study, lesion size was the only significant predictor of the failure to achieve healing and thus require further surgical procedures; for each 1-cm² increase in size, the odds of requiring a reoperation increased by 2.93 times. Previous reports of drilling in the treatment of OCD lesions in children and adolescents have failed to find a significant correlation between lesion size and complications or nonhealing,

presumably owing to a lack of statistical power.^{19,20,24,30} However, after nonoperative treatment, other studies have associated the size of the lesion with healing,^{14,15,33} with larger lesions not only having a higher risk of not healing but also taking longer to heal.¹⁵

Limitations

We acknowledge the limitations to this study, including those inherent to a retrospective case series. We did not assess how individual surgeons indicated patients for surgery, which makes our study population more heterogeneous. Our primary goal was to evaluate the complications of drilling of OCD lesions, and therefore, patient-reported outcomes were not assessed. Furthermore, complications were assessed only from clinic notes, and it is possible that some complications may have been missed because of recall bias. In addition, we only assessed healing on radiographs. Although all patients underwent preoperative MRI scans, routine postoperative MRI scans were not obtained unless symptoms failed to improve 3 to 6 months after surgery. Finally, we did not assess the interobserver and intraobserver reliability of our radiologic data.

Conclusions

Our findings suggest that arthroscopic drilling for stable, intact OCD lesions in the pediatric knee is a safe procedure with reliable outcomes and return to ADLs and a minimal risk of complications. Most patients return to their preoperative daily activity level with full ROM of the knee by 3 months after surgery. Complications, including reoperations, are related to the progression of the OCD lesion rather than to the surgical procedure. Each 1-cm² increase in lesion size increases the likelihood of reoperation by 2.93 times.

References

1. Kessler JI, Nikizad H, Shea KG, Jacobs JC Jr, Bechuk JD, Weiss JM. The demographics and epidemiology of osteochondritis dissecans of the knee in children and adolescents. *Am J Sports Med* 2014;42:320-326.
2. Ananthaharan A, Randsborg P-H. Epidemiology and patient-reported outcome after juvenile osteochondritis dissecans in the knee. *Knee* 2018;25:595-601.
3. Bruns J, Werner M, Habermann C. Osteochondritis dissecans: Etiology, pathology, and imaging with a special focus on the knee joint. *Cartilage* 2018;9:346-362.
4. Andriolo L, Crawford DC, Reale D, et al. Osteochondritis dissecans of the knee: Etiology and pathogenetic mechanisms. A systematic review. *Cartilage* 2020;11:273-290.
5. Edmonds EW, Polousky J. A review of knowledge in osteochondritis dissecans: 123 years of minimal evolution from König to the ROCK study group. *Clin Orthop Relat Res* 2013;471:1118-1126.

6. Masquijo J, Kothari A. Juvenile osteochondritis dissecans (JOCD) of the knee: Current concepts review. *EFORT Open Rev* 2019;4:201-212.
7. Abouassaly M, Peterson D, Salci L, et al. Surgical management of osteochondritis dissecans of the knee in the paediatric population: A systematic review addressing surgical techniques. *Knee Surg Sports Traumatol Arthrosc* 2014;22:1216-1224.
8. Flynn JM, Kocher MS, Ganley TJ. Osteochondritis dissecans of the knee. *J Pediatr Orthop* 2004;24:434-443.
9. Chambers HG, Shea KG, Carey JL. AAOS clinical practice guideline: Diagnosis and treatment of osteochondritis dissecans. *J Am Acad Orthop Surg* 2011;19:307-309.
10. Eismann EA, Pettit RJ, Wall EJ, Myer GD. Management strategies for osteochondritis dissecans of the knee in the skeletally immature athlete. *J Orthop Sports Phys Ther* 2014;44:665-679.
11. Kocher MS, Tucker R, Ganley TJ, Flynn JM. Management of osteochondritis dissecans of the knee: Current concepts review. *Am J Sports Med* 2006;34:1181-1191.
12. Winthrop Z, Pinkowsky G, Hennrikus W. Surgical treatment for osteochondritis dissecans of the knee. *Curr Rev Musculoskelet Med* 2015;8:467-475.
13. Heyworth BE, Kocher MS. Osteochondritis dissecans of the knee. *JBJS Rev* 2015;3:e1.
14. Krause M, Hapfelmeier A, Möller M, Amling M, Bohndorf K, Meenen NM. Healing predictors of stable juvenile osteochondritis dissecans knee lesions after 6 and 12 months of nonoperative treatment. *Am J Sports Med* 2013;41:2384-2391.
15. Wall EJ, Vourazeris J, Myer GD, et al. The healing potential of stable juvenile osteochondritis dissecans knee lesions. *J Bone Joint Surg Am* 2008;90:2655-2664.
16. Chambers HG, Shea KG, Anderson AF, et al. Diagnosis and treatment of osteochondritis dissecans. *J Am Acad Orthop Surg* 2011;19:297-306.
17. Chan C, Richmond C, Shea KG, Frick SL. Management of osteochondritis dissecans of the femoral condyle: A critical analysis review. *JBJS Rev* 2018;6:e5.
18. Cruz AI, Shea KG, Ganley TJ. Pediatric knee osteochondritis dissecans lesions. *Orthop Clin North Am* 2016;47:763-775.
19. Kocher MS, Micheli LJ, Yaniv M, Zurakowski D, Ames A, Adrignolo AA. Functional and radiographic outcome of juvenile osteochondritis dissecans of the knee treated with transarticular arthroscopic drilling. *Am J Sports Med* 2001;29:562-566.
20. Boughanem J, Riaz R, Patel RM, Sarwark JF. Functional and radiographic outcomes of juvenile osteochondritis dissecans of the knee treated with extra-articular retrograde drilling. *Am J Sports Med* 2011;39:2212-2217.
21. Salci L, Ayeni O, Abouassaly M, et al. Indications for surgical management of osteochondritis dissecans of the knee in the pediatric population: A systematic review. *Knee Surg* 2014;27:147-156.
22. Bauer KL. Osteochondral injuries of the knee in pediatric patients. *J Knee Surg* 2018;31:382-391.
23. Ganley TJ, Gaugler RL, Kocher MS, Flynn JM, Jones KJ. Osteochondritis dissecans of the knee. *Oper Tech Sports Med* 2006;14:147-158.
24. Edmonds EW, Albright J, Bastrom T, Chambers HG. Outcomes of extra-articular, intra-epiphyseal drilling for osteochondritis dissecans of the knee. *J Pediatr Orthop* 2010;30:870-878.
25. Beck NA, Patel NM, Ganley TJ. The pediatric knee: Current concepts in sports medicine. *J Pediatr Orthop B* 2014;23:59-66.
26. Detterline AJ, Goldstein JL, Rue J-PH, Bach BR. Evaluation and treatment of osteochondritis dissecans lesions of the knee. *Knee Surg* 2008;21:106-115.
27. Barlow SE. Expert committee recommendations regarding the prevention, assessment, and treatment of child and adolescent overweight and obesity: Summary report. *Pediatrics* 2007;120:S164-S192 (suppl 4).
28. Adachi N, Deie M, Nakamae A, Ishikawa M, Motoyama M, Ochi M. Functional and radiographic outcome of stable juvenile osteochondritis dissecans of the knee treated with retroarticular drilling without bone grafting. *Arthroscopy* 2009;25:145-152.
29. Yonetani Y, Tanaka Y, Shiozaki Y, et al. Transarticular drilling for stable juvenile osteochondritis dissecans of the medial femoral condyle. *Knee Surg Sports Traumatol Arthrosc* 2012;20:1528-1532.
30. Gunton MJ, Carey JL, Shaw CR, Murnaghan ML. Drilling juvenile osteochondritis dissecans: Retro- or trans-articular? *Clin Orthop Relat Res* 2013;471:1144-1151.
31. Nepple JJ, Milewski MD, Shea KG. Research in osteochondritis dissecans of the knee: 2016 update. *Knee Surg* 2016;29:533-538.
32. Pennock AT, Bomar JD, Chambers HG. Extra-articular, intraepiphyseal drilling for osteochondritis dissecans of the knee. *Arthrosc Tech* 2013;2:e231-e235.
33. Pill SG, Ganley TJ, Milam RA, Lou JE, Meyer JS, Flynn JM. Role of magnetic resonance imaging and clinical criteria in predicting successful nonoperative treatment of osteochondritis dissecans in children. *J Pediatr Orthop* 2003;23:102-108.