

Pattern of uveitis in North East India: A tertiary eye care center study

Dipankar Das, Harsha Bhattacharjee,
Pankaj Kumar Bhattacharyya, Lokesh Jain,
M J Panicker, Kalyan Das, Akshay C Deka

We conducted an institutional-based retrospective study on 308 uveitic patients and analyzed the pattern of uveitis in Northeastern India. Anterior uveitis was the most common type (47.07%) followed by posterior (29.87%), intermediate (12.98%) and panuveitis (10.06%). Toxoplasmosis (40.21%) had the highest incidence among posterior uveitis cases. Harada's form of Vogt Koyanagi Harada's disease is a frequent occurrence in this subset of the population.

Key words: Acute retinal necrosis, uveitis, Vogt Koyanagi Harada's disease

Indian J Ophthalmol. 2009;57:144-146

The pattern of uveitis is influenced by a number of geographic, demographic and racial factors. Collaborative studies between different areas would be most helpful in establishing etiology and pattern of uveitis.

A few studies on the pattern of uveitis from southern,^[1-3] central and northern India^[4] have been reported in literature. We present this retrospective study from North East India with the objective of determining the cause of uveitis, associated systemic conditions, comparing the pattern seen in this part of India and elsewhere in India and the world.

Materials and Methods

The clinical records of all patients with uveitis seen at our clinic between January 2005 and December 2005 were analyzed retrospectively. Our material mostly included outpatient uveitis cases. A standard clinical proforma, had the patient profile and clinical findings including explicit uveitic characteristics, specific ocular cause and systemic association. Patients were classified according to current International Uveitis Study Group (IUSG) classification based on the localization of intraocular inflammation.^[1] Ocular findings were analyzed in each case by external examination, slit-lamp biomicroscopy, applanation tonometry and indirect ophthalmoscopy (IDO) with scleral depression in full dilatation. Fundus examination was done with IDO using 20-diopter (D) lens and slit-lamp using 90-D lenses. Ancillary tests included B scan ultrasound, fundus fluorescein angiography in selected cases and tailored laboratory investigations in each case. Routine investigations included radiography of chest, lumbar spine, sacro-iliac joints;

complete blood count with sedimentation rate; anti-nuclear antibody (ANA); VDRL, Mantoux test; HLA-B27 for ankylosing spondylitis; toxoplasma serology, seldom, in children, toxocara antibody; serum angiotensin converting enzyme (ACE), serum calcium, gallium scan for sarcoidosis and ELISA for HIV positive cases. Standard diagnostic criteria were employed for all syndromes or entities of uveitis.^[5,6] Consultation was done with the concerned medical specialist whenever needed. The final etiological diagnosis was made based on clinical features, laboratory investigations and systemic evaluation. All patients of endophthalmitis and Eales' disease were excluded from the study.

Results

The records of 308 successive uveitic patients during January 2005-December 2005 were analyzed. Males outnumbered females: 209: 99; mean age of presentation was 32.5 years in males and 30.8 years in females with a range of 2 to 61 years.

Anterior uveitis (iritis, iridocyclitis) was the most commonly occurring form accounting for 47.07% of all cases [Fig. 1]. In anterior uveitis, specific diagnosis could be made in 79 cases (54.49%), of which the most common underlying cause was

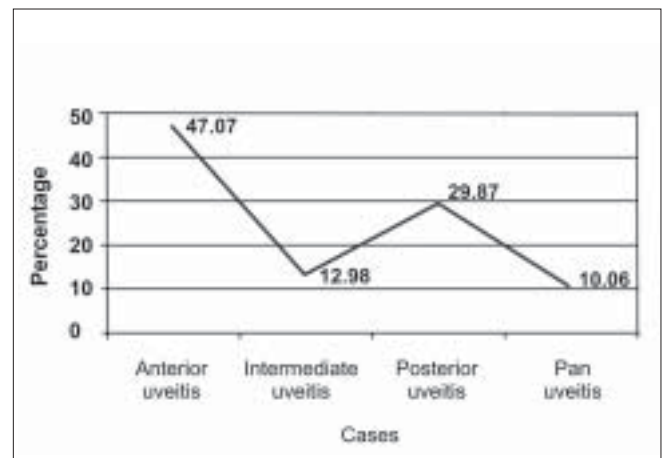


Figure 1: Graphical representation showing anatomical distribution of various uveitic entities (IUSG)




Figure 2: Graphical representation showing etiological distributions of anterior uveitis

Sri Sankaradeva Nethralaya, Guwahati, Assam, India

Correspondence to Dr. Dipankar Das, Department of Ocular Pathology and Uveitis Services, Sri Sankaradeva Nethralaya, Beltola, Guwahati - 781 028, Assam, India. E-mail: dr_dasdipankar@yahoo.com

Manuscript received: 22.01.08; Revision accepted: 16.05.08

DOI: 10.4103/0301-4738.45506 - PMID: 19237790

seronegative spondyloarthopathy in 34 cases (23.44%) followed by traumatic anterior uveitis in 25 cases (17.24%), intraocular lens (IOL)-induced uveitis in 10 cases (6.89%). Other causes were Fuchs heterochromic cyclitis (seven cases), herpes zoster virus infectious uveitis (one case), leprosy (one case) and parasitic (one case). Diagnosis remained idiopathic in 66 (45.51%) cases [Fig. 2].

In the posterior uveitis group, a total of 92 cases (29.87%) were seen, of which ocular toxoplasmosis was the commonest in 37 (40.21%) cases followed by idiopathic choroiditis in 18 (19.56%) cases, serpiginous choroiditis (14 cases, 15.21%), acute posterior multifocal placoid pigment epitheliopathy (APMPPE) (five cases), multifocal choroiditis (four cases), tuberculosis (five cases), toxocara (four cases), cytomegalovirus (CMV) retinitis (two cases), syphilis (one case), punctate inner choroidopathy (one case) and acute retinal necrosis (ARN, one case) [Fig. 3].

In the intermediate uveitis group (40 cases, 12.98%), the etiology was idiopathic pars planitis in 31 cases (77.5%) and a specific diagnosis was arrived at in the remaining nine cases, of which sarcoidosis (five cases) and tuberculosis (four cases) were the most common primary causes.

In panuveitis (31 cases, 10.06%), Vogt Koyanagi Harada's (VKH) disease was the most common cause seen in 14 cases (45.16%), followed by sarcoidosis (nine cases), idiopathic (five cases), Behcet's disease (one case), sympathetic ophthalmia (one case) and parasitic panuveitis (one case) [Fig. 4].

Discussion

The uveitic population seen in our institute comprises seven North East states of India. Higher incidence is seen in males (67.85%) as compared to females (32.14%). This is similar to various studies from India^[1-4] and abroad.^[5-7] Higher incidence of anterior uveitis (47.07%) was striking in our study as compared to Henderly *et al.*,^[5] (27.8%) and Biswas *et al.*,^{(39.28%).} Majority of anterior uveitis was idiopathic (45.51%).

Posterior uveitis was the second commonest. The most common specific entity encountered was toxoplasmosis (40.21%) which is significantly higher than in the studies from South India (Biswas *et al.*, 27.87%)^[1] and the western India.^[8] In Assam, ocular toxoplasmosis is found around

the main river Brahmaputra, which may be a significant observation. This is followed by idiopathic choroiditis (19.56%) and serpiginous choroiditis (15.21%). In a study from northern India, serpiginous choroiditis is the foremost cause of posterior uveitis.^[4] The differential diagnosis of uveitis has changed over time. The incidence of tubercular uveitis is increasing while there is a decrease in syphilis as a cause of uveitis. In a recent study by Rathinam *et al.*, it has been seen that the incidence of leptospiral uveitis and uveitis following tuberculosis and leprosy is quite common in South Indian states.^[3] We have found two cases of CMV retinitis in an HIV patient. In our region, Manipur has epidemic foci of HIV infection but it has a peculiarity in that most of the positive cases are intravenous (IV) drug users. There may be a difference in the biological behavior of CMV retinitis in AIDS patients following IV use or other routes of transmission. In South and West India, cases of HIV infection due to sexual exposure are much more common and the incidence of CMV retinitis is also high there.

In the majority of intermediate uveitis cases, the cause is unknown (77.5%). IUSG recommended the term intermediate uveitis for any known cause and all idiopathic cases are termed as pars planitis. In this study, sarcoidosis was seen in five cases with vitritis and pars plana exudates. The cases which had panuveitis are not grouped with the intermediate uveitis cases.

In the panuveitis group, VKH was the leading etiological cause (45.16%). Most of the cases were Harada's disease without skin or hair changes and probably this variety of incomplete VKH is predominant in this subset of the population. VKH is also a leading cause of panuveitis in the US,^[9] and Indian^[1,4] referral center-based studies. This is followed by sarcoidosis (29.03%). Behcet's disease was seen in one case which is more common in Middle Eastern countries and Japan.^[10] Bechet's disease is the most frequently encountered form of endogenous uveitis in Japan; it comprises more than 20% of all cases.^[10] This disease is infrequently seen in Europe and the US.^[5,9,10] In India it is a relatively rare disease entity.^[1,2,4]

New uveitic entities have been emerging over the last decade such as parasitic uveitis, CMV retinitis, HIV-related uveitis, ARN and a spectrum of other infectious uveitis, particularly tuberculosis. These stretched out epidemiological uniqueness serve to provide ophthalmologists and epidemiologists with

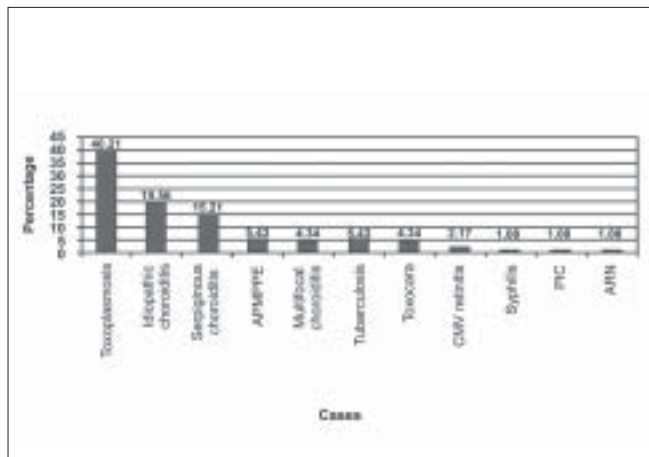


Figure 3: Bar-diagram showing etiological distributions of posterior uveitis

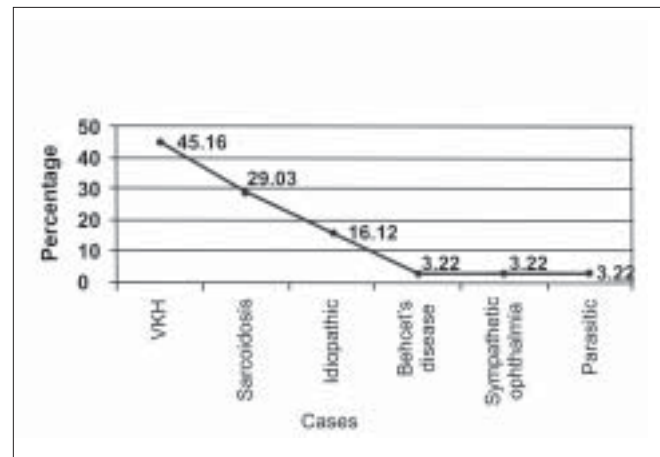


Figure 4: Graphical representation of panuveitis cases

groundwork to monitor future disease patterns in the North East Indian population and provide a basis for comparison with other selected populations elsewhere.

Acknowledgment

Support from Sri Kanchi Sankara Health and Educational Foundation

References

1. Biswas J, Narain S, Das D, Ganesh SK. Pattern of uveitis in a referral uveitis clinic in India. *Int Ophthalmol* 1996-1997;20:223-8.
 2. Dandona L, Dandona R, John RK, McCarty CA, Rao GN. Population based assessment of uveitis in an urban population in southern India. *Br J Ophthalmol* 2000;84:706-9.
 3. Rathinam SR, Namperumalsamy P. Global variation and pattern changes in epidemiology of uveitis. *Indian J Ophthalmol* 2007;55:173-83.
 4. Singh R, Gupta V, Gupta A. Pattern of uveitis in a referral eye clinic in North India. *Indian J Ophthalmol* 2004;52:121-5.
 5. Henderly DE, Genstler AJ, Smith RE, Rao NA. Changing patterns of uveitis. *Am J Ophthalmol* 1987;103:131-6.
 6. Smith RE, Nozik RA. Uveitis: A clinical approach to diagnosis and management. 2nd ed. Baltimore: Williams and Wilkins; 1989.
 7. Perkins ES, Folk J. Uveitis in London and Iowa. *Ophthalmologica* 1984;189:36-40.
 8. Weiner A, Ben Ezra D. Clinical patterns and associated conditions in chronic uveitis. *Am J Ophthalmol* 1991;112:151-8.
 9. Williams GJ, Brannan S, Forrester JV, Gavin MP, Paterson-Brown SP, Purdie AT, *et al.* The prevalence of sight-threatening uveitis in Scotland. *Br J Ophthalmol* 2007;91:33-6.
 10. Sugita M, Enomoto Y, Nakayma S. Epidemiological study on endogenous uveitis in Japan. *Proceedings of the 3rd International Symposium on Uveitis, Brussels, Belgium: 1992.* p. 24-7.
-