



Contents lists available at ScienceDirect

International Journal of Surgery Case Reports

journal homepage: www.casereports.com

Performing an intestinal stoma with placement of an Artificial Sphincter[®] Intestinal Valve (VITEA): A case report

Carlos Eduardo Álvarez-Ponce^a, Elizabeth Barrios^{b,*}, Javier López-Gómez^c, Oscar Xenon Rosas-Guerra^a, José de Jesus Perez-Yañez^a, Joacim Meneses-León^d, Armando Ramírez-Ramírez^a

^a Department of Oncologic Surgery, Juarez Hospital of Mexico, Mexico City, Mexico

^b Planning, Development and Statistics Department Director, Civil Service Social Security and Services Institute ISSSTE, Mexico City, Mexico

^c Department of Oncologic Surgery, National Cancer Institute, Mexico City, Mexico

^d Research Center in Policy, Population and Health, School of Medicine, National Autonomous University of Mexico, Mexico City, Mexico

ARTICLE INFO

Article history:

Received 2 September 2020

Received in revised form 20 October 2020

Accepted 1 November 2020

Available online 7 November 2020

Keywords:

Stoma

VITEA

Ostomized

Case report

ABSTRACT

INTRODUCTION: Intestinal stomas are created for distinct clinical conditions. They may involve the small bowel (ileostomy) or the large bowel (colostomy), depending on the objective or site of the stoma. Intestinal stomas may be temporary or permanent; they cause loss control of intestinal transit due to the absence of a sphincter that regulates its exit, provoking a continuous passage of fecal matter through the stoma. Within the environment of the ostomized patients, there are several important complications involving their quality of life.

CASE PRESENTATION: The Intestinal Valve Type Artificial Sphincter (VITEA) device is placed in a patient diagnosed with cervical cancer, who has a vaginal-rectum fistula that requires a definitive colostomy.

DISCUSSION: Intestinal stomas have been validated for over a century. We present the case with a similar complication rate to those described after performing a stoma with conventional open technique in terms of quality of life and cost-benefit ratio. The proportion of complications and the quality of life found in the ostomized patient with the VITEA* device is acceptable, and also eliminates the colostomy bags, providing the function of an artificial sphincter by everting the mucosa on the same device. No complications were found during the follow-up.

CONCLUSIONS: The results from this proposal will allow to evaluate the safety and efficacy profile associated with a stomal bags.

© 2020 The Authors. Published by Elsevier Ltd on behalf of IJS Publishing Group Ltd. This is an open access article under the CC BY-NC-ND license (<http://creativecommons.org/licenses/by-nc-nd/4.0/>).

1. Introduction

Intestinal stoma has been used for decades given the safety and feasibility of the surgical technique [1]. The complications associated with this procedure can be determined not only by the surgical technique but also by different conditions inherent to the disease and characteristics of each patient [2,3]. Stoma patients need preoperative protocols that should vary according to the characteristics of the disease, as a result of such evaluation the physician can

determined the patients who are suitable to undergo in the device placement procedure [4].

This work has been reported in line with the SCARE criteria [5], and submitted and registered with the “Research Registry UIN” as a novel device / technique with identification number 6076.

The procedure was performed by a Surgical Oncologist, Chief of the Surgical Oncology Department at Hospital Juarez de Mexico, and by his surgical team, including the inventor of the device.

2. Case presentation

The case of 43-years-old woman, with a diagnosis of cervical cancer clinical stage IIIC, the patient does not have medical history related to her current condition prior to the cancer treatment based on 5 weekly sessions of chemoradiotherapy in combination with Cisplatin, and 25 sessions of radio therapy 45 Gy and 4 sessions of brachytherapy. No allergies reported, and her psychosocial or family history does not include relevant genetic information.

Abbreviations: VITEA, Intestinal Valve Type Artificial Sphincter; CT Scan, computed tomography.

* Corresponding author at: Paseo de la Reforma Nte. No. 39, Col. Tabacalera, Alcaldía Cuauhtémoc, CP. 06030 Ciudad de México, Mexico.

E-mail addresses: dr_carlosalvarez@quirurgie.com (C.E. Álvarez-Ponce), nebarrios141083@gmail.com (E. Barrios), dr.javierlopgom@gmail.com (J. López-Gómez), quiromanofilia@gmail.com (O.X. Rosas-Guerra), jjopeya.12@hotmail.com (J.d.J. Perez-Yañez), ml.joacim@gmail.com (J. Meneses-León), armando7771@hotmail.com (A. Ramírez-Ramírez).

<https://doi.org/10.1016/j.ijscr.2020.11.005>

2210-2612/© 2020 The Authors. Published by Elsevier Ltd on behalf of IJS Publishing Group Ltd. This is an open access article under the CC BY-NC-ND license (<http://creativecommons.org/licenses/by-nc-nd/4.0/>).

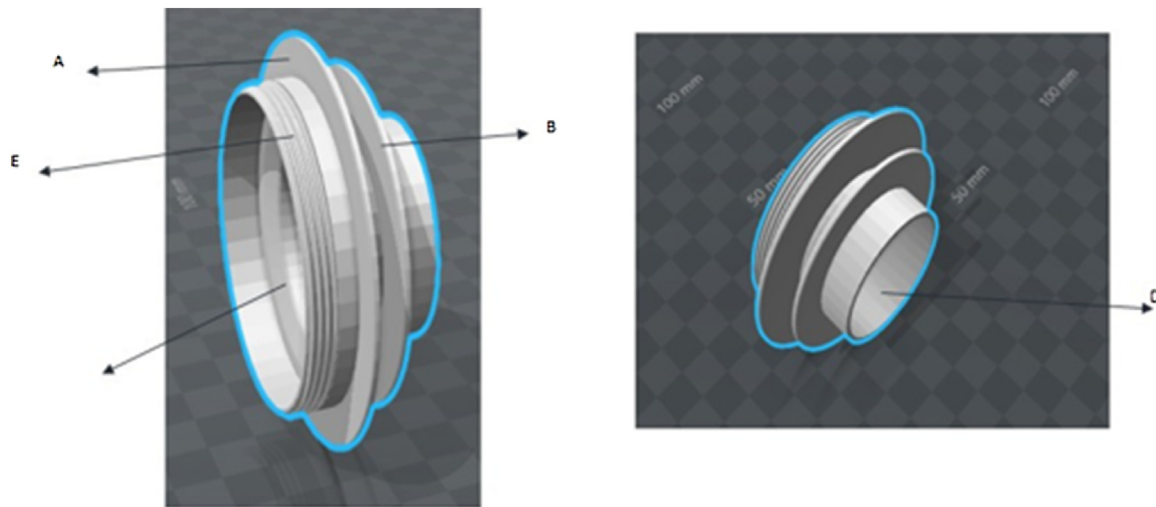


Fig. 1. Representative diagram of the VITEA device; A. - Outer fixation ring, B. - Inner Fixation ring, C.- Stoma Surface D.- Intestinal tube, E.- Hermetic Thread.

Additionally, she was a non-smoker, no use of walking aids and no history for cervical cancer.

During the physical examination, an 8 × 8 cm exophytic cervical tumor was identified with a fixed right parametrium up to the pelvic wall and a right parametrium with incipient infiltration, the digital rectal palpation revealed extrinsic compression without evidence of fistula or tumoral activity in the rectal mucosa. An abdomen and pelvis computed tomography without contrast was performed with tumor load at cervical level and extensive pelvic floor without obstructive uropathy nor metastatic disease, rectum flexible sigmoidoscopy and normal cystoscopy were reported, histopathological study compatible with moderately differentiated squamous cell carcinoma, ulcerated in a fragment of up to 0.4 mm. The patient was classified with a clinical stage IIIC.

When the above-mentioned treatment was completed, the patient progressed and developed a complication with a rectovaginal fistula, therefore she was not eligible for a pelvic exenteration, considering that all therapeutic possibilities against cancer had been exhausted, after the informed consent of the patient, we performed a terminal colostomy of the descending colon placing an artificial sphincter type intestinal valve (VITEA).

2.1. Intestinal Valve Type Artificial Sphincter (VITEA)

The biomedical device used in this case was independently developed, it was approved and placed in the Hospital Juárez de México. The device is an integral unit assembled with a tubular structure of biocompatible polypropylene mesh material and a mechanical valve which was installed intraoperatively and can be voluntarily manipulated by the patient to regulate intestinal transit through the stoma. Subsequently, it was covered with a hermetic plug (Fig. 1).

2.2. Surgical technique

After asepsis and antisepsis of the abdominal region, the stoma site is surgically marked at a midpoint between the iliac spine and the umbilical scar (avoiding skin folds), sterile fields are installed under balanced general anesthesia to make a supra-umbilical incision dissecting by planes until reaching the abdominal cavity.

We proceed to dissect Toldt's fascia up until splenic angle, realizing the left colon in the usual way. Subsequently, a cross section is made with a scalpel with distal closure of the colon in two planes: the first with Vycril 2/0 and the second with silk 3/0 (Fig. 2).

Wall tunneling is carried out using the technique described by Brooke. The bowel loop is then tunneled to insert the VITEA medical device into the wall tunnel (Fig. 3).

Subsequently we exteriorize the colostomy through the device and ensured there is no tension and coloration changes secondary to ischemia. Once the colostomy loop is loose, the inner ring of the VITEA device is fixed with Vycril 3/0 points to the anterior aponeurosis with cardinal points knotting the suture at the end.

Once the device is fixed, the intestinal mucosa is circumferentially everted over the skin with separate dots of Prolene 3/0 over the adjacent skin area. Finally, once the device is fixed to the abdominal wall and mucosa, the device is attached to the skin with Nylon 2/0 (Fig. 4).

Finally, once the intestinal mucosa has matured to the device, and the device is fixed to the skin, the hermetic plug of the device is placed to verify again the closure and final position. Once the success of the procedure was confirmed, the surgical event was completed (Fig. 5).

3. Results

3.1. Post-surgical evolution

The main consideration after the intervention was to generate a timely diagnosis and treatment of any complication or emergency related to the device, in order to establish an effective resolution strategy, based on the complications described in the literature.

Our interventions were: follow-up visits to review the viability of the intestinal mucosa, presence of peristomal changes (hernia, fasciitis and abscess), permeability of the intestinal lumen, hemorrhage, among others. Which resulted in the phases detailed below.

The post-surgery phases consist mainly in 3 stages: 1) Early (in-hospital, less than 72 h), Late (Ambulatory, after 72 h.) and Follow-up (external consultation).

3.2. Early postsurgical

The patient evolved favorably during the first hours, showing moderate post-surgical pain in the wound that was controlled with analgesics. The intestinal mucosa had moderate edema without data of bleeding, ischemia or necrosis. Postoperative care was the usual for an intestinal stoma, a liquid diet started the following day

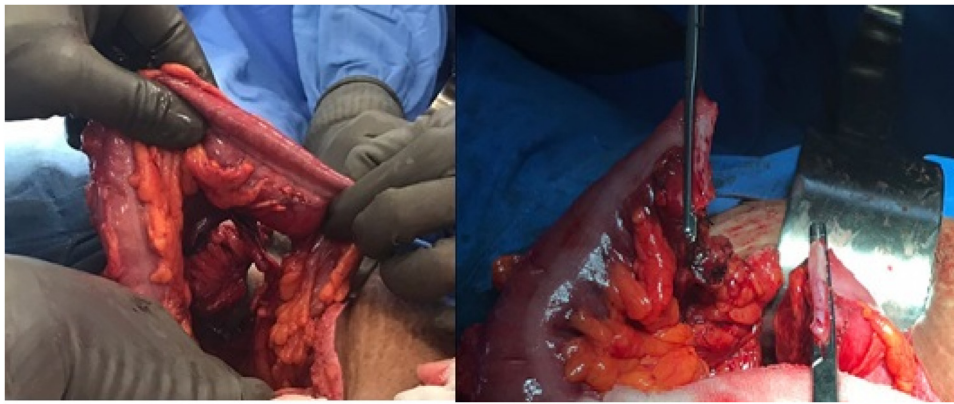


Fig. 2. We proceed to dissect Toldt's fascia until splenic angle freeing left colon in a habitual way.

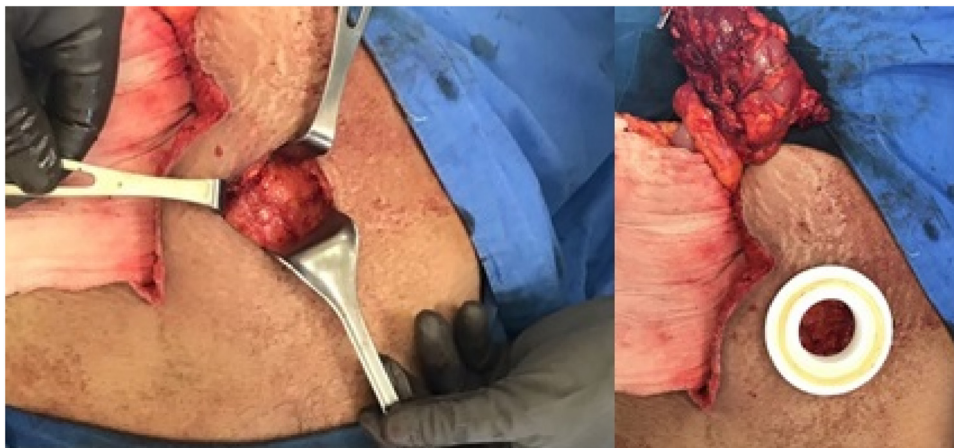


Fig. 3. Creation of the tunnel for the colostomy and insertion of the VITEA device.

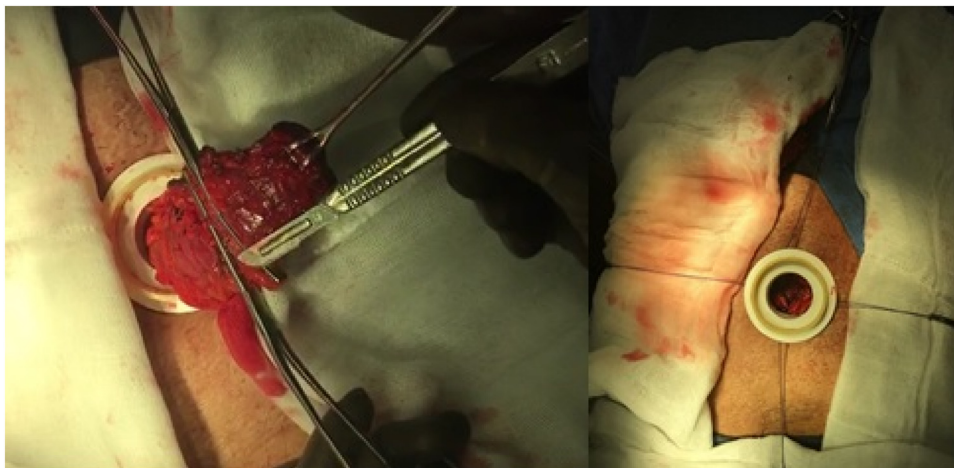


Fig. 4. Exteriorization of the stoma through the VITEA device and fixation with cardinal points of Vycril 3/0 to the anterior aponeurosis.

after surgery and fecal waste was observed through the stoma 48 h after the procedure.

The exploration and systematic review of the characteristics of the stoma and clinical data focused mainly on ruling out complications associated with the rejection of the material, stoma dysfunction, or leakage which includes from fecal material to soft tissues, also abscesses or parastomal hernia, umbilication, ischemia, necrosis or absence of fecal expenditure. The patient was discharged satisfactorily 72 h after postoperative monitoring, without clinical data suggestive of complication with feeding and fecal

waste through the stoma with the use of colostomy bags during the first postoperative week.

3.3. Late postsurgical (72 h - 15 days)

Surveillance during this period focused on ruling out signs and symptoms suggestive of abdominal sepsis, material leakage, valve dysfunction (rupture, lack of tightness) as well as determining the functional characteristics of the device such as opening schedule, technique adopted by the patient to empty and clean the colostomy

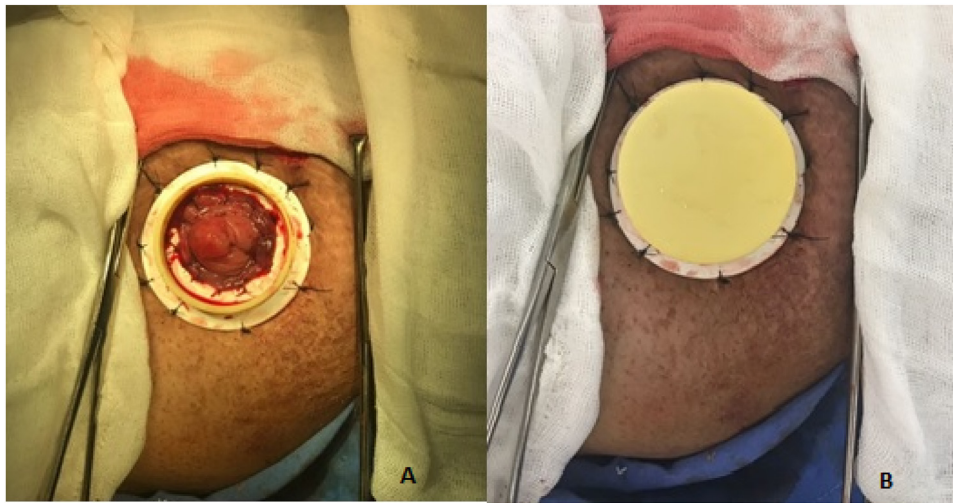


Fig. 5. Final position of the fixed device A) without hermetic plug placement, B) with hermetic plug placement.

bags, and also know the patient experience. The patient attended 7 days after the valve placement reporting good general condition, oral nutrition and fecal waste through the semi-liquid stoma. No clinical data of systemic inflammatory response or symptomatology associated with it was found. She reported being able to perform her cleaning and disposal activities on her own 4–5 times a day when she felt abdominal distension.

3.4. Follow up

Our main objective during this phase was to describe late complications after surgery, a follow-up was conducted according to symptoms or clinical findings.

The patient returned 5 weeks after the device placement with significant deterioration due to tumor activity, she referred fatigue, generalized pain and poor general condition. Abdominal ultrasound, axial tomography (CT Scan) and control laboratories are requested to rule out abdominal sepsis.

Abdominal ultrasound and CT scan were reported without intra-abdominal or wall collections. The hemogram with severe anemia with Hemoglobin of 6.5 mg/dl due to tumor activity so transfusion therapy was proposed, however, the patient did not accept management and decided to withdraw voluntarily.

Physical examination shows the device fixed to the abdominal wall, with the intestinal mucosa not adhering to the device, with no evidence of hernia, abscess or intestinal sepsis data. The patient left the follow-up, communicating only her general condition by telephone. Lack of adhesion is not considered a failure in the placement technique, or in the device quality, since medical grade silicone is an inert material, the lack of adhesion is a physical-chemical characteristic associated to the material. In this case, the inert materials such as medical grade silicone elastomer, have the advantage of the absence of cytotoxicity, which is widely described, and the reason they are currently used in a wide variety of medical devices.

The patient's perspective was widely explained and described in the testimonial video attached in the last submission, including the patient's personal experience, the improvement in life quality, as well as overall impact of the medical intervention.

4. Discussion

Other types of artificial sphincters have been used successfully in different specialties. In this case, we modified the technique described by Bryan Brook 1952 [5] where he proposes the eversion of the mucosa to the skin and currently is one of the most popu-

lar technics and has not undergone under significant changes since its creation. We propose the eversion of the intestinal mucosa to the eversion surface of the stoma of the medical device by directly fixing the mucosal border to the device.

We propose the use of a medical device called artificial sphincter type intestinal valve to provide voluntary containment in order to eliminate the collection bags and improve the quality of life of patients as well as reduce costs.

We present the case of an adult woman with oncological pathology in palliative care (she was not a candidate for palliative chemotherapy and pelvic exenteration) who agreed to the placement of this device, eliminating 100% of the colostomy bags. It should be noted that the patient expresses the possibility of performing the tasks of cleaning and disposal by herself despite a poor general condition due to oncological pathology.

No complications associated with the device were identified and the goal of eliminating the colostomy bags was achieved, however, the intestinal mucosa did not completely adhere to the device, so design modifications will be made to accomplish it. One of the limitations of this report is that it was unable to provide the complete follow-up due to patient abandonment, so a clinical trial is needed to corroborate its functionality and safety.

This case-report provides an overview of the quality of life and functionality of the VITEA device in ostomized patients. In the presentation of this case, it was found that the proportion of complications and the quality of life of the ostomized patient carrying the VITEA device are acceptable, which aim at improving both aspects which is consistent with multiple studies previously conducted in various Health Institutions in Mexico.

The results from this proposal will allow to evaluate the safety and efficacy profile (increase in voluntary containment of intestinal material) associated with a complication rate similar to those described after performing a stoma with conventional open technique in terms of quality of life and cost-benefit ratio. After the device placement, the patient reported no need to use a colostomy bag again, she did not refer pain or discomfort related to the valve, she performed daily activities autonomously and self-confident, considerably recovering her quality of life.

5. Conclusions

Surgical management of future candidates for a stoma with placement of an Artificial Sphincter Type Intestinal Valve proposed and experimentally tested in this case-report are:

- 1) Multidisciplinary management; from diagnosis to follow-up that includes: nutritionist or dietitian, nursing staff trained in stomata management, psychologist or behavioral medicine physicians.
- 2) Pre-surgical marking to clinically identify the site of the stoma (if possible) or prior to the procedure by the surgeon trained to perform the technique properly.
- 3) Verify in each follow-up consultation the proper management, hygiene and maintenance of the stoma.
- 4) The artificial sphincter valve represents a potential solution to eliminate the use of colostomy bags and provide voluntary continence to ostomized patients.
- 5) Both the stoma technique and the device placement technique were viable in terms of functionality and permanence; however, we recognize that they can evolve and involve new technologies.
- 6) Similar results were confirmed in previously published studies, where fecal continence was achieved in high percentages with good tolerance by the patient, without increasing surgical risk.
- 7) The development of new research lines is required, which includes of pressure, peristalsis, and intestinal physiology in response to the device.
- 8) Future experience will determine the groups with the greatest benefit and will contribute on the development of objective criteria and clinical guidelines for each group of patients according to their clinical and anthropometric characteristics, for the safe and efficient implantation of the device.

The lines of research that could be developed from this case (based on the final analysis) are the analysis and description of the epidemiological panorama of ostomized patients in Mexico and the validation of the questionnaire of the Hospital Juarez of Mexico to evaluate the quality of life of ostomized patients before and after the placement of the VITEA device.

Declaration of Competing Interest

The authors report no declarations of interest.

Funding

No funds were received from any public or private institution for this study.

Ethical approval

For this case presentation, the informed consent needed to collect the patients information has been waived and approved by the institutional review board, the Human Ethics Committee of Hospital Juarez de México (Reference number: HJM 0415/18-1).

Consent

Patient privacy and confidentiality was protected with data anonymization in the data collection forms. No unauthorized person had access to the collected data from medical record and chart review.

Open Access

This article is published Open Access at [sciencedirect.com](https://www.sciencedirect.com). It is distributed under the [IJSCR Supplemental terms and conditions](#), which permits unrestricted non commercial use, distribution, and reproduction in any medium, provided the original authors and source are credited.

Author's contribution

EB wrote the paper. AR, RG, and PY, provided the case. AP and EB provided the interpretation of the data. AP, EB, JM and JLG reviewed and edited the manuscript. AP and AR provided the clinical/ surgical images. All authors performed literature review, read and approved the final manuscript.

Registration of research studies

1. Name of the registry: "Performing an intestinal stoma with placement of an Artificial Sphincter® Intestinal Valve (VITEA), A case report".
2. Unique identifying number or registration ID: 6076
3. Hyperlink to your specific registration (must be publicly accessible and will be checked): <https://www.researchregistry.com/browse-the-registry#home/>.

Guarantor

Elizabeth Barrios.

Provenance and peer review

Not commissioned, externally peer-reviewed.

Acknowledgments

Total gratitude to the Hospital Juarez Mexico for making possible this study. To the Department of Oncological Surgery, medical residents of multiple specialties, nurses and of course patients and family who consented their participation in this research project, always supporting the multidisciplinary team involved, with the purpose of contributing to the improvement of medical care in Mexico and in the world.

Appendix A. Supplementary data

Supplementary material related to this article can be found, in the online version, at <https://doi.org/10.1016/j.ijscr.2020.11.005>.

References

- [1] R. Krouse, M. Grant, B. Ferrell, G. Dean, et al., Quality of life outcomes in 599 cancer and non-cancer patients with colostomies, *J. Surg. Res.* 138 (1) (2007) 79–87, <http://dx.doi.org/10.1016/j.jss.2006.04.033>.
- [2] C.S. Wendel, M. Grant, L. Herrinton, et al., Reliability and validity of a survey to measure bowel function and quality of life in long-term rectal cancer survivors, *Qual. Life Res.* 23 (10) (2014) 2831–2840, <http://dx.doi.org/10.1007/s11136-014-0724-6>.
- [3] L.K. Temple, J. Bacik, S.G. Savatta, et al., The development of a validated instrument to evaluate bowel function after sphincter-preserving surgery for rectal cancer, *Dis. Colon Rectum* 48 (7) (2005) 1353–1365, <http://dx.doi.org/10.1007/s10350-004-0942-z>.
- [4] P.E. Toth, Ostomy care and rehabilitation in colorectal cancer, *Semin. Oncol. Nurs.* 22 (3) (2006) 174–177, <http://dx.doi.org/10.1016/j.soncn.2006.04.001>.
- [5] B.N. Brooke, The management of an ileostomy, including its complications, *Lancet* 2 (6725) (1952) 102–104.