



# The Efficacy of Suture Fixation of the Greater Trochanter in Unstable Intertrochanteric Fractures

Ki-Choul Kim, MD, Hee-Gon Park, PhD, Jae-Wook Park, MD

*Department of Orthopedic Surgery, Dankook University College of Medicine, Cheonan, Korea*

**Background:** Intertrochanteric fractures are one of the most common fractures in the elderly, especially those having osteoporosis. Stable intertrochanteric fractures may be fixed with implants including the dynamic hip screw and proximal femoral nail antirotation; however, this method is difficult to apply to unstable fractures. Bipolar hemiarthroplasty can be applied to unstable fractures and it prevents complications by facilitating early ambulation in the elderly. Many studies reported on how to fix the greater trochanter in unstable fractures during arthroplasty. We suggest that suture fixation alone can be a useful, effective, and affordable method.

**Methods:** We retrospectively enrolled 294 patients who underwent hemiarthroplasty for an unstable intertrochanteric fracture, and 225 patients were included in this study after excluding 69 patients who had not been available for follow-up until 1 year after surgery or died. The patients were divided into suture fixation and wiring fixation groups. Relationships of operation time, estimated blood loss, tip-to-stem distance, union rate, and physical performance in the groups of suture fixation and wiring were analyzed respectively.

**Results:** Changes in the tip-to-stem distance between the initial assessment at 1 year after surgery were statistically significantly different between the suture fixation group and wiring group ( $p < 0.001$ ). There was no significant difference in change of the Koval score between the suture fixation and wiring groups ( $p = 0.362$ ). The operation time and estimated intraoperative blood loss were statistically significantly lower in the suture group than in the wiring group ( $p < 0.001$ ). There was no significant difference in the union rate between the groups ( $p = 0.470$ ).

**Conclusions:** Compared to tension-band wiring, the suture fixation technique demonstrated an effective fixing force. In addition to the clinical results, it had an advantage of preventing complications due to shortening of the operation time and estimated intraoperative blood loss. Suture fixation of the greater trochanter is recommended for elderly patients with unstable intertrochanteric fractures.

**Keywords:** Hip fractures, Femur, Sutures, Fixation

Hip fractures including intertrochanteric fractures have high morbidity and mortality among all fractures.<sup>1)</sup> The prevalence of osteoporosis has been increasing along with

the aging of the society, thereby increasing the risk of fracture.<sup>2)</sup> Approximately 280,000 hip fractures occurred annually in the United States in the past, and the incidence is expected to rise continuously.<sup>3)</sup> Currently, the management of hip fractures in osteoporotic elderly individuals has become a topic of great interest.

Intertrochanteric fractures are classified by several methods, such as the Evans and AO/OTA classifications. They divide intertrochanteric fractures on the basis of anatomical and functional aspects; however, the definition of unstable intertrochanteric fractures has not been clearly

Received December 1, 2020; Revised February 2, 2021;

Accepted February 2, 2021

Correspondence to: Ki-Choul Kim, MD

Department of Orthopedic Surgery, Dankook University College of Medicine,  
119 Dandae-ro, Dongnam-gu, Cheonan 31116, Korea

Tel: +82-41-550-3060, Fax: +82-41-556-0551

E-mail: puhoo73@hanmail.net

established. Several reports suggested that the postero-medial component fracture type, reverse oblique fracture type, and intertrochanteric fracture with subtrochanteric extension type should be considered unstable fractures. Recently, further studies have insisted that the lateral wall fracture type and osteoporosis should be included in unstable fractures.<sup>4)</sup> In addition, three-dimensional computed tomography (3D CT) classification was developed to provide accurate information about fracture patterns. This classification uses the concept of the four major components (femoral head, greater trochanter, lesser trochanter, and femur shaft) and is more effective in preventing misdiagnosis than classifications based on simple plain radiographs.<sup>5)</sup> Nakano classified three-part and four-part fractures into unstable fractures, except for three-part fractures with small or large fragments of the greater trochanter and intact lesser trochanter.<sup>6)</sup>

Greater trochanter fractures are usually combined with the lateral wall fracture and they influence the postoperative outcome.<sup>7)</sup> Several external rotation muscles such as the gluteus medius, minimus, gemellus, obturator externus, and internus are inserted into the greater trochanter, and the lack of greater trochanter fragment fixation causes pain, muscle weakness, trendelenburg gait, and periprosthetic dislocation.<sup>8)</sup> Due to this, much effort has been made to attach the greater trochanter fragments. The cable plate system and wiring were often used and studied through various techniques. They decreased the nonunion rate and loss of reduction although complications including implant breakage or osteolysis could occur.

Transosseous suture techniques are widely used for greater tubercle fixation in proximal humeral fractures. These suture techniques produced remarkable results in terms of the rotator cuff function, as well as the union rate.<sup>9)</sup> We thought that these suture fixation techniques

could be applied to proximal femoral fractures. Our hypothesis was that suture fixation of greater trochanter fragments would not be inferior to the conventional techniques in terms of union rate and functional outcome, and it would be beneficial in terms of cost, effectiveness, and complications.

## METHODS

### Patient Enrollment

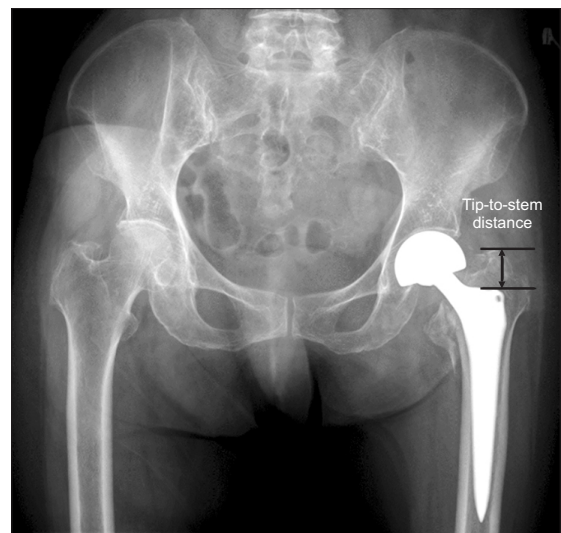
This study was approved by Institutional Review Board of Dankook University Hospital (IRB No. DKUH 2020-04-008) and owing to the retrospective design, the requirement for informed consent was waived.

A total of 294 consecutive patients with osteoporosis who underwent hemiarthroplasty for unstable intertrochanteric fractures classified by 3D CT classification between May 2012 and January 2019 were enrolled. A total of 225 patients were included in this study after excluding 69 patients who had not visited the clinic until 1 year after surgery or had died (Table 1). All the operations and suture fixation or tension-band wiring for greater trochanter fixation in unstable intertrochanteric fractures were performed in a single center by one surgeon (KCK). The patients were divided into the suture fixation and tension-band wiring fixation groups. To check the intraoperative efficiency, the operative time and estimated intraoperative blood loss (EIBL) were checked with the anesthesia records. Regarding the radiologic outcomes, we checked greater trochanter migration using the tip-to-stem distance and union of the greater trochanter (Fig. 1).<sup>10)</sup> These radiological evaluations were performed by comparing

**Table 1.** Demographic Data

Characteristic	Suture (n = 138)	Tension-band wiring (n = 87)
Age (yr)	82.23 ± 6.35	82.48 ± 6.57
Male	22 (16)	21 (24)
Female	116 (84)	66 (76)
Fracture type (3D classification)		
3	70	42
4	68	45

Values are presented as mean ± standard deviation or number (%). 3D: three-dimensional.



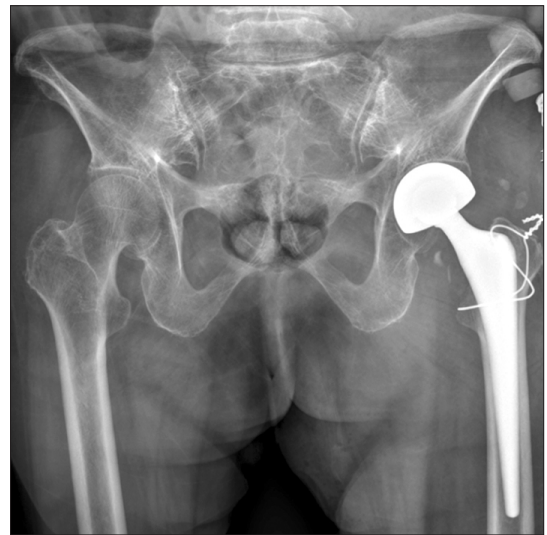
**Fig. 1.** The tip-to-stem distance was measured on the plain radiograph.

initial postoperative simple plain radiographs with 1-year postoperative simple plain radiographs. To assess the physical performance, we used the Koval score, which divides ambulatory ability into seven levels: independent community ambulators, community ambulatory with cane, community ambulatory with a walker, independent household ambulatory, household ambulatory with a cane, household ambulatory with a walker, and nonfunctional ambulatory (Table 2).<sup>11)</sup> This score was checked preoperatively and 1 year postoperatively.

### Surgical Technique

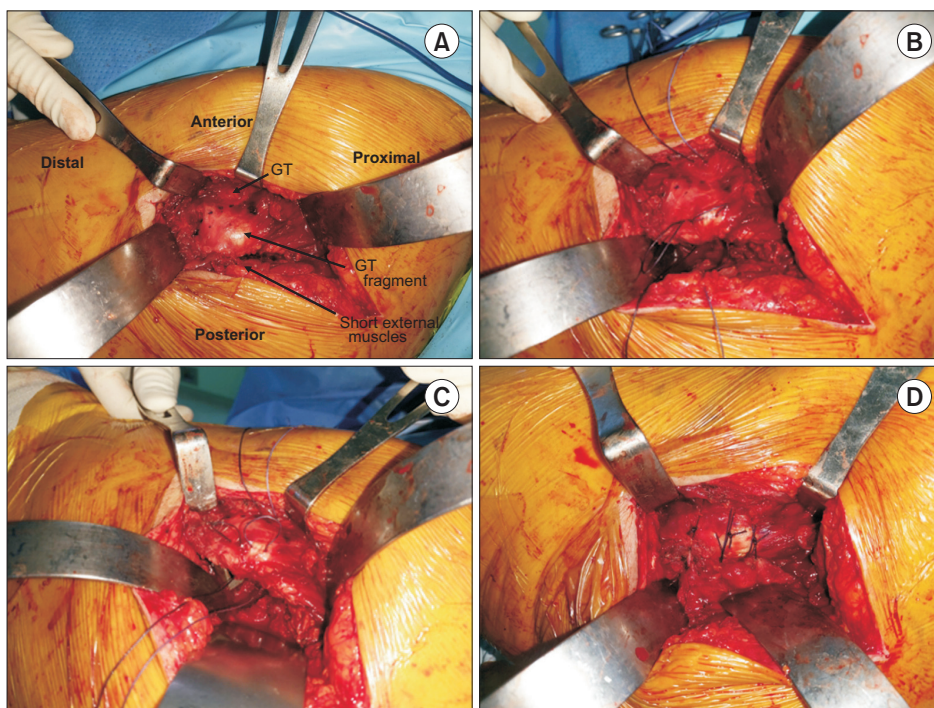
All operations were performed in the lateral decubitus position, using the posterolateral approach. An incision

was made along the intertrochanteric crest, and the approach was done by dividing the piriformis, short external rotator muscles, and the joint capsule. With a prosthesis inserted, the suture fixation technique was performed after confirming proper stability and range of motion. We performed the figure-of-eight wiring technique in the wiring group (Fig. 2) and the suture technique in the suture fixation group in the following steps: first, we checked the ap-



**Fig. 2.** Tension-band wiring was performed using the figure-of-eight technique.

Table 2. Koval Classification	
Ambulatory ability	Score
Independent community ambulators	7
Community ambulatory with cane	6
Community ambulatory with walker	5
Independent household ambulatory	4
Household ambulatory with cane	3
Household ambulatory with walker	2
Nonfunctional ambulatory	1



**Fig. 3.** (A) The approximate location is marked by a marking pen. (B) Absorbable sutures are passed through the intact greater trochanter (GT) and GT fragment. (C) Absorbable sutures are passed through the short external rotator muscle and joint capsule continuously. (D) After the sutures are passed through short external muscles, the procedure is repeated with the same thread, and knots are made with as much tension as possible.

**Table 3.** Comparison between the Suture Fixation Group and Tension-Band Wiring Group

Factor	Suture fixation	Tension-band wiring	T/Z	p-value
Initial tip-to-stem distance (mm)	15.27 ± 5.86	15.11 ± 5.29	0.210	0.834
FU tip-to-stem distance (mm)	18.00 ± 6.17	19.15 ± 6.93	-1.290	0.198
Initial Koval score	4.58 ± 1.96	4.61 ± 1.93	-0.135	0.893
Postoperative 1-year FU Koval score	3.48 ± 1.99	3.32 ± 1.71	-0.303	0.762
Union rate	0.88 ± 0.33	0.91 ± 0.29	-0.724	0.470
Difference of tip-to-stem distance (mm)*	2.73 ± 2.02	4.04 ± 3.37	-3.635	< 0.001
Difference of Koval score*	1.10 ± 1.31	1.29 ± 1.45	-0.912	0.362
Operation time (min)	70.94 ± 18.26	90.69 ± 21.36	-8.731	< 0.001
EIBL (mL)	329.35 ± 147.70	467.24 ± 216.32	-5.483	< 0.001

Values are presented as mean ± standard deviation.

T/Z: T-score or Z-score, FU: follow-up, EIBL: estimated intraoperative blood loss.

\*Difference between the initial assessment and 1-year postoperative assessment.

proximate location using a marking pen (Fig. 3A). Second, the greater trochanter and greater trochanter fragment were passed through the absorbable suture (Fig. 3B and C), and the greater trochanter fragment and the short external rotator muscles were passed continuously. For suturing, we used the Novosyn (B. Braun, Melsungen, Germany) 1-0 that was mid-term absorbable braided and coated suture made of polyglactin. To perform this procedure easily, the tip of the needle and the greater trochanter fragment were placed at right angles to each other, which was possible because the bone was spongy and osteoporotic. Third, this procedure was repeated with the same thread. Then, knots were made with as much tension as possible and at least 3 sutures were performed until sufficient stability was achieved (Fig. 3D).

### Statistical Analysis

We used IBM SPSS ver. 26.0 (IBM Corp., Armonk, NY, USA) for statistical analyses. The *t*-test and Mann-Whitney *U*-test were used to compare the tip-to-stem distance, Koval score, union rate, operation time, and EIBL between the suture fixation and tension-band wiring groups. The differences in the tip-to-stem distance and Koval score were assessed using a *t*-test.

## RESULTS

The study population consisted of 43 men (17%) and 182 women (83%) and their mean age was 82.3 years (range, 54–98 years). There were 138 patients (61%) in the suture fixation group and 87 patients (39%) in the tension-band

wiring group. The mean initial tip-to-stem distance was 15.27 ± 5.86 mm in the suture fixation group and 15.11 ± 5.29 mm in the wiring group (*p* = 0.834). The mean postoperative 1-year tip-to-stem distance was 18.00 ± 6.17 mm in the suture fixation group and 19.15 ± 6.93 mm in the wiring group (*p* = 0.198). However, the difference in tip-to-stem distance between postoperative 1 year and the initial time was 2.73 ± 2.02 mm in the suture fixation group and 4.04 ± 3.37 mm in the wiring group (*p* < 0.001), showing a statistically significant difference between the groups. The mean initial Koval score was 4.58 ± 1.96 in the suture fixation group and 4.61 ± 1.93 in the wiring group (*p* = 0.893). The mean postoperative 1-year Koval score was 3.48 ± 1.99 in the suture fixation group and 3.32 ± 1.71 in the wiring group (*p* = 0.762). The difference of the Koval score between the postoperative 1 year and preoperative time was 1.10 ± 1.31 in the suture fixation group and 1.29 ± 1.45 in the wiring group. (*p* = 0.362), showing no statistically significant difference between the groups. The mean operation time was 70.94 ± 18.26 minutes in the suture fixation group and 90.69 ± 21.36 minutes in the wiring group (*p* < 0.001). The mean EIBL was 329.35 ± 147.70 mL in the suture fixation group and 467.24 ± 216.32 mL in the wiring group (*p* < 0.001). There was a significant difference in the operation time and EIBL between the suture fixation and wiring groups. The mean union rate was 0.88 ± 0.33 in the suture fixation group and 0.91 ± 0.29 in the wiring group (*p* = 0.470), showing no significant difference between the groups (Table 3).



## DISCUSSION

There are several methods for managing intertrochanteric fractures and many studies have reported that bipolar hemiarthroplasty is recommended for elderly patients with osteoporosis. Prevention of postoperative complications such as pneumonia, embolism, and sore is important in the elderly, and bipolar hemiarthroplasty helps to prevent postoperative complications through early ambulation compared to internal fixation.<sup>12)</sup> Moreover, it has no risk of avascular necrosis and nonunion.<sup>13)</sup>

There are several intraoperative factors that increase postoperative complications. An increase in the EIBL demands blood transfusion, which can trigger an immune response or lead to disease transmission and fluid imbalance.<sup>14)</sup> Moreover, a longer operation time is associated with an increased risk of complications such as reoperation, surgical site infection, and general weakness.<sup>15)</sup> Even small complications can lead to adverse outcomes in the elderly; therefore, we need to make an effort to prevent them. In view of this, we think that the suture fixation technique is more effective in managing complications than the wiring technique.

The importance of greater trochanter fixation was emphasized due to the external rotation muscle weakness and pain. Through greater trochanter fixation, operators take advantage of anatomical reduction and functional recovery. Several techniques, including the cable plate systems, were introduced in the past, and several wiring techniques such as tension-band wiring have been mainly used. A cable plate system can achieve a strong fixation force and high union rate, but it requires longer operation times and skin incisions, increasing the risk of infection.<sup>8)</sup> Although it depends on the shape and degree of the fracture fragment, tension-band wiring is mainly known for effectiveness among various wiring methods.<sup>16)</sup> Tension-band wiring has the advantage of being able to produce the clinical results comparable to those of the cable system and requires a shorter operation time. Kim et al.<sup>17)</sup> reported that the tension-band wiring technique was a good option when the fracture fragment was not small. However, it has a risk of wire breakage due to wire tension and viscoelasticity, as well as material irritation. In fact, three wire breakage cases were found and one case required reoperation due to material infection among our 87 wiring cases.

According to a biomechanical study that involved tension-band wiring, suture anchor, and polyester suture fixation, suture anchor and tension-band wiring had good fixation, but polyester sutures also showed good performance in functional areas.<sup>18)</sup> Considering that the elderly

were the subjects of the current study, we thought that time-effective polyester suture fixation would be more efficient than a method with a strong fixing force due to the characteristics of the greater trochanter. In general, greater trochanter bone union is not necessary in elderly people because of low activity level. The greater trochanter is composed of spongy bones with an abundant blood supply and it has better fibrous union than other parts.<sup>17)</sup> Good clinical results can be expected with fibrous union and there have been several reports about suture fixation. Due to fibrous union, it was not necessary to hold the suture for a long time; therefore, we selected an absorbable suture. Lee et al.<sup>10)</sup> reported that the prevention of displacement was obtained by suture fixation, but they did not compare to wiring cases. Choi et al.<sup>19)</sup> treated suture fixation according to fracture pattern and shape, but did not use it alone. Therefore, in the current study, we attempted to compare suture fixation and wiring clinically and radiologically in larger cases than other studies. The results showed that suture fixation was not inferior to wiring fixation in terms of greater trochanter migration and union rate, but suture fixation did not show significant improvement in terms of physical performance compared to wiring fixation.

Our study has several limitations. First, suture fixation has the advantage of being an effective fixation method in the elderly, but it can be highly dependent on the operator's competence; some operators who are more confident with tension-band wiring may not achieve better fixation with suture fixation. However, we think that it can be done easily because surgeons are used to the suture technique. Second, this study lacks sufficient clinical evaluation due to the retrospective study design. The only clinical evaluation was the Koval score assessment, which shows the physical performance. It is thought that more evaluation is needed to investigate problems caused by greater trochanter migration, including muscle power. Third, there may be selection bias. Rather than randomly selecting cases for surgical techniques, the operator's selection may have been based on CT. To minimize this bias, the subjects were limited to those with unstable fractures and greater trochanter fractures. Finally, although greater trochanter migration was less noticeable in the suture fixation group, the results should not be generalized to the entire population because the study population was limited to older people who are less active.

The suture fixation technique had an effective fixing force compared to tension-band wiring. In addition to the clinical results, it had the advantage of preventing complications due to shortening of the operation time and EIBL. Considering these results, greater trochanter fixation using the

suture technique is recommended for the elderly in bipolar hemiarthroplasty for unstable intertrochanteric fractures.

## CONFLICT OF INTEREST

No potential conflict of interest relevant to this article was reported.

## ORCID

Ki-Choul Kim <https://orcid.org/0000-0002-7012-0695>  
 Hee-Gon Park <https://orcid.org/0000-0002-7389-7280>  
 Jae-Wook Park <https://orcid.org/0000-0003-0918-155X>

## REFERENCES

- Panula J, Pihlajamäki H, Mattila VM, et al. Mortality and cause of death in hip fracture patients aged 65 or older: a population-based study. *BMC Musculoskelet Disord*. 2011;12:105.
- Adeyemi A, Delhougne G. Incidence and economic burden of intertrochanteric fracture: a Medicare claims database analysis. *JB JS Open Access*. 2019;4(1):e0045.
- Dhanwal DK, Dennison EM, Harvey NC, Cooper C. Epidemiology of hip fracture: worldwide geographic variation. *Indian J Orthop*. 2011;45(1):15-22.
- Tawari AA, Kempegowda H, Suk M, Horwitz DS. What makes an intertrochanteric fracture unstable in 2015? Does the lateral wall play a role in the decision matrix? *J Orthop Trauma*. 2015;29 Suppl 4:S4-9.
- Shoda E, Kitada S, Sasaki Y, et al. Proposal of new classification of femoral trochanteric fracture by three-dimensional computed tomography and relationship to usual plain X-ray classification. *J Orthop Surg (Hong Kong)*. 2017;25(1):2309499017692700.
- Nakano T. Proximal femoral fracture. *Seikei Geka*. 2014;65: 842-50.
- Baixaui F, Vicent V, Baixaui E, et al. A reinforced rigid fixation device for unstable intertrochanteric fractures. *Clin Orthop Relat Res*. 1999;(361):205-15.
- Kim WY, Han CH, Ji JH, Kim YY, Lee KS, Lee SW. Fixation for reattachment of trochanteric fragment in pertrochanteric fracture treated with bipolar hemiarthroplasty. *J Korean Hip Soc*. 2006;18(1):67-72.
- Dimakopoulos P, Panagopoulos A, Kasimatis G. Transosseous suture fixation of proximal humeral fractures. *J Bone Joint Surg Am*. 2007;89(8):1700-9.
- Lee KH, Lee DH, Noh JH, Kim YV. Is rigid fixation of the greater trochanter necessary for arthroplasty of intertrochanteric fractures? *Orthop Traumatol Surg Res*. 2019; 105(1):41-5.
- Kim JW, Moon KP, Hwang YS, Song JY, Chae JH. Predictors of ambulatory recovery after fixation of intertrochanteric fracture with proximal femoral nail in the elderly. *J Korean Orthop Assoc*. 2017;52(5):428-34.
- Dimon JH, Hughston JC. Unstable intertrochanteric fractures of the hip. *J Bone Joint Surg Am*. 1967;49(3):440-50.
- Yoo MC, Kim KT, Cho YJ, Sun SD, Park GC. Treatment of femur neck and intertrochanteric fractures in the elderly with primary hemiarthroplasty. *J Korean Fract Soc*. 1994;7(2):412-21.
- Sambandam B, Batra S, Gupta R, Agrawal N. Blood conservation strategies in orthopedic surgeries: a review. *J Clin Orthop Trauma*. 2013;4(4):164-70.
- Surace P, Sultan AA, George J, et al. The association between operative time and short-term complications in total hip arthroplasty: an analysis of 89,802 surgeries. *J Arthroplasty*. 2019;34(3):426-32.
- Suh YS, Choi SW, Park JS, Yim SJ, Shin BJ. Comparison between the methods for fixation of greater trochanteric fragment in cemented bipolar hemiarthroplasty for unstable intertrochanteric fracture. *J Korean Hip Soc*. 2008;20(2):104-9.
- Kim WY, Shin ES, Moon CY. Modified double tension band wiring for reattaching the greater trochanter when performing hemiarthroplasty for intertrochanteric fracture in elderly patients. *J Korean Hip Soc*. 2009;21(3):257-62.
- von Keudell A, Kachooei A, Mohamadi A, et al. Biomechanical properties of an intramedullary suture anchor fixation compared to tension band wiring in osteoporotic olecranon fractures: a cadaveric study. *J Orthop*. 2019;17:144-9.
- Choi DH, Heo JY, Jang YJ, Chung YY. Fixation of the greater trochanter in arthroplasty for unstable intertrochanteric fracture. *J Korean Fract Soc*. 2014;27(1):58-64.