

Neonatal Curettage of Large to Giant Congenital Melanocytic Nevi Under Local Anesthetic: A Case Series With Long-Term Follow Up



Article reuse guidelines:
sagepub.com/journals-permissions
DOI: 10.1177/112034754211057751
journals.sagepub.com/home/cms



Laura C. Soong¹ , Alma Bencivenga², and Loretta Fiorillo¹

Abstract

Background: Neonatal curettage of large to giant congenital melanocytic nevi (L-GCMN) is a simple, minimally invasive procedure typically performed within the first 2 weeks of life.

Objectives: To retrospectively review our experience with serial curettage of L-GCMN in the neonatal period performed under local anesthesia and their long-term outcomes.

Methods: Curettage was performed by a single pediatric dermatologist on nine neonates with L-GCMN under local anesthetic and with oral analgesia between 2002 and 2016 in Red Deer, Alberta, Canada. Patient charts were reviewed retrospectively to assess patient and procedure characteristics, tolerability, safety, cosmetic and functional outcomes, and malignant transformation.

Results: Patients were treated with an average of 6 curettage sessions (range 3 to 15) to remove the majority or entirety of the nevus. All patients tolerated local anesthesia well. The most common adverse event of the procedure was transient neutropenia. Two patients developed positive bacterial cultures without clinical signs of infection, treated with antibiotics. All curetted specimens demonstrated benign pathology. Patients were followed annually thereafter, for an average of 6 years. Eight patients with L-GCMN of the trunk had minimal to partial repigmentation with good cosmetic outcome. One patient had recurrence of a facial nevus. None of the patients developed cutaneous malignant melanoma.

Conclusions: Curettage appears to be a safe and effective treatment option for select cases of L-GCMNs of the trunk. We do not recommend the procedure for face or scalp CMN. This procedure can be performed under local anesthesia with serial curettage to avoid potential risks of general anesthesia.

Keywords

congenital melanocytic nevus, neonatal, curettage, local anesthesia

Introduction

Congenital melanocytic nevi (CMN) are nevi that present at or shortly after birth. Large to giant congenital melanocytic nevi (L-GCMN) are classified based on projected adult size, with large CMNs being greater than 20 cm and giant CMNs being greater than 40 cm¹. The condition is rare, with incidence reported between 1:20,000 to 1:500,000 lives births.¹ They are often associated with proliferative nodules within the lesion, hypertrichosis, and satellite nevi and are more commonly found on the trunk.¹ Psychosocial burden of L-GCMNs has been reported, particularly social, behavioral, and emotional problems.² In one study, children felt a scar was more socially acceptable than their nevus.² Numerous treatment options have been investigated for these patients, including surgical excision, which may involve serial excisions, grafting or tissue expanders,

dermabrasion, chemical peels, cryotherapy, electrosurgery, laser, and curettage.

Neonatal curettage of giant congenital melanocytic nevi performed within the first few weeks of life was first described by Moss³ in 1987. The procedure is a simple, minimally invasive treatment option for large to giant CMNs (L-GCMN) and is typically well tolerated, with minimal blood loss and tissue trauma.^{4,5} The procedure takes

¹Division of Dermatology, Department of Medicine, University of Alberta, Edmonton, AB, Canada

²Airdrie Medical Clinic, Airdrie, Canada

Corresponding Author:

Loretta Fiorillo, Edmonton Clinic Health Academy 11405-87 Ave, 3rd floor, Edmonton, AB T6G 1C9, Canada.
Email: fiorillo@ualberta.ca

advantage of an early cleavage plane between the upper and lower dermis in the first weeks of life.^{3,5} Cosmetic results have been reported comparable to surgical excision.⁴ In most cases, the goals of treatment of L-GCMNs are to improve the aesthetic appearance and decrease the psychosocial impact of the condition.⁶ Removal of L-GCMN by any method has not been shown to decrease the lifetime risk of melanoma,⁷ and therefore removal should not be performed with the intent of reducing this risk. Curettage is one of the few potential interventions that provides tissue for histologic examination and is a less invasive option for removal compared to surgical excision, which often requires tissue expanders, multiple stages, general anesthesia, and longer operating time. Tissue expansion carries additional risks of explantation, port exposure, skin necrosis, hematoma or seroma formation, rupture, and infection.⁸ Previous studies investigating curettage for L-GCMNs have reported treatment as a single stage procedure under general anesthesia (GA), which carries the potential for additional anesthetic risks in neonates, as well as fluid and electrolyte shifts due to the large, denuded area. We report a case series of 9 patients treated with neonatal curettage under local anesthesia performed as serial daily or every second day scrapings within the first 2 weeks of life and their long term follow up. We describe safety of the procedure, physician assessment of aesthetic outcome, and potential role for curettage in the treatment ladder of L-GCMN using our serial scrapings approach.

Patients and Methods

Nine neonates with L-GCMNs were treated with neonatal curettage in Red Deer, Alberta, Canada between the year 2002 and 2016. Patient records were retrospectively reviewed to assess patient characteristics, duration of treatment, peri-procedural complications, tolerability, functional outcomes, clinician subjective assessment of cosmetic outcomes of the procedure, and long-term complications. This study was approved by the University of Alberta research ethics board (Pro00091803).

Patients born with a L-GCMN between 2002 and 2016 were offered the option of neonatal curettage. Parents interested in an interventional approach were advised of the alternatives, the risks (including bleeding, infection, pain, scarring, recurrence of nevus) and benefits (including potential for lightening the color of the nevus, improved cosmesis, maintenance of skin elasticity, potential reduction of psychosocial impact) of the procedure. Parents were advised that the procedure could only be offered within the first 2 weeks of life, and those who expressed hesitancy were encouraged to consider observation/surveillance or alternative interventional approach when the child was older. For those who wished to move forward with the procedure, informed consent was obtained, using the standard institutional consent

form and protocols. Patients were admitted to the neonatal intensive care unit (NICU) for these elective procedures.

All procedures were performed by a single pediatric dermatologist with neonatal care and resuscitation available at the bedside in the NICU. Each procedure was performed under sterile technique. Neonates were placed on continuous cardiorespiratory monitoring throughout their admission and during the curettage sessions. A section of the nevus of approximately 10 cm² was predetermined and marked for curettage. The area was cleansed with chlorhexidine wash, and the site was draped with sterile towels. Sterile gloves, gowns, and instruments were used. Neonates were given a dose of oral sucrose prior to the procedure and as needed throughout. A single dose of oral morphine 0.05-0.1 mg/kg was also administered before the procedure to maintain comfort. The area to be curetted was then anesthetized by local subcutaneous injection of lidocaine 1% with epinephrine diluted with saline to reach a final concentration of 0.25%. The maximum dose of lidocaine used per session was 7 mg/kg. Under sterile technique, a 7 mm curette was used to debride the nevus, starting from the center of the nevus on the first day and progressing towards the periphery. At each session, an area of approximately 7 to 10 cm² was curetted to a demarcation plane in the reticular dermis. Curettage was performed daily or every second day until the entire nevus was removed, the patient no longer tolerated the procedure, or the cleavage plane was lost, the latter manifested as resistance to curettage of the epidermis and increased bleeding in the dermis. Curettage at the border of the lesion typically proved challenging, and there was often a rim of residual nevus left at the periphery. All curetted samples were sent for pathology. There was minimal bleeding during each procedure, controlled by dabbing with gauze and application of calcium alginate dressing, followed by foam dressing and gauze, the dressing was changed daily. Electrocautery was available in the event of excessive bleeding, however this was not required for any of the cases. Neonates were given oral acetaminophen as needed for post-procedure discomfort and with dressing changes. All patients had one or more blood cultures drawn to ensure absence of bacteremia. None of the patients were febrile or symptomatic when blood cultures were taken. Daily bacterial swabs of curetted areas were taken at each dressing change. Patients remained admitted while undergoing the serial curettage procedures and were discharged 24-48 hours after the last scraping with home care for daily to every second day dressing changes for 2 weeks. Parents continued to provide all routine newborn care.

Results

A total of 9 patients underwent complete or partial curettage of their CMN within the first 2 weeks of life. The average number of curettage sessions was 6, ranging from 3 to 15 per

Table 1. Baseline Patient Data and Curettage Procedure Performed Within the First 2 weeks of Life.

Patient	Year of scraping	Weeks gestation	Age at first scraping (days)	Age at last scraping (days)	Number of scrapings	Length of stay (days)	Location of nevus	Location of scraping
1	2016	40	8	15	6	7	Upper back, left upper arm	Upper back, left upper arm
2	2014	38	9	16	7	8	Entire back, shoulders, neck, part of chest and part of abdomen, face	Most of nevus
3	2011	41	1	6	5	6	Back (shoulders to lumbar region)	Most of nevus on back, leaving a thin rim
4	2010	40	1	3	3	4	Left cheek and neck	Entire nevus
5	2009	26	87 ^a	102	15	17 ^b	Entire back, extending onto abdomen	Most of the back
6	2009	38	12	16	5	6	Entire back, left chest, abdomen	Most of the nevus, shaved thick nodules to debulk on chest
7	2008	38	6	11	5	6	Thoracic spine to buttocks	Most of nevus, buttocks was not curetted
8	2004	38	0	4	4	10	Scalp, posterior neck, to thoracic spine	Entire back
9	2002	41	9	14	3	4	Entire back and left arm	Back

^aAdjusted for prematurity, curettage was performed within 14 days of term gestational age.

^bLength of stay for scrapings only, patient was admitted to NICU for prematurity and other reasons as well.

patient (Table 1). Eight of 9 patients had CMN involving the trunk. One patient had curettage of a facial CMN.

In the post-procedural period, 3 of 9 patients had transient neutropenia. Two of 9 patients developed positive cultures without clinical signs of infection; one had transient bacteremia with *Staphylococcus epidermidis*, and one had a wound swab positive for *Staphylococcus aureus*, both were treated with appropriate courses of antibiotics without any adverse outcomes. One patient (patient 8) had a brief nocturnal seizure-like episode after completion of the course of curettage. The patient received 4 doses of morphine in total (0.1 mg/kg/dose equal to 0.25 mg per dose). The curettage for this patient was performed every second day. Two days after the last curettage, the patient was noted to have jerky movements during sleep. The initial diagnosis was a seizure, possibly due to morphine withdrawal, however it was an isolated incident and did not occur while awake or recur. Neurology suspected benign sleep myoclonus. EEG and MRI were normal. He received a single loading dose of phenobarbital. His development and neurological status are normal over 11 years post-curettage.

Patients were followed for an average of 6 years (range 3 months to 11 years). Eight of 9 patients had partial repigmentation, though in most cases this appeared as speckled, macular light brown pigmentation with minimal textural surface changes (Table 2). Two patients had very mild repigmentation (Figures 1–2). One patient had residual tan colored skin with prominent hypertrichosis (Figure 1). Three patients had excision of residual CMN or satellites that were not removed by the initial curettage. Patient 4 had recurrence of the facial

CMN, and subsequently underwent a 3-stage excision and reconstruction. Six patients had an MRI of the brain and none demonstrated neurocutaneous melanosis. One patient (patient 5) months later developed a cellular schwannoma involving the lower thoracic to upper lumbar region in the dermis and subcutaneous tissue, treated with excision. All patients had normal functional outcome with no restricted mobility or complications from wound healing. Cosmetic outcome was satisfactory to good; treated skin had normal texture, elasticity, and thickness, and minimal to no scarring. There was no hypertrophic scarring or keloid formation. The skin adnexa remained preserved. Pathology of curetted specimens revealed benign congenital nevi in all patients. To date, none of the patients have developed primary cutaneous malignant melanoma. One patient developed a primary leptomeningeal melanoma at age 7, despite a normal brain MRI 5 months prior. Palpation for subcutaneous nodules was not affected by the procedure.

Discussion

Curettage of L-GCMNs was first described by Moss³ within the first few weeks of life. In their case series, 6 of 10 patients had no return of pigment and acceptable appearance. Since that time, several case series were published,^{4,5,9-11} the majority of which reported favorable cosmetic and functional results. Hypertrophic scarring has been reported as a complication, however this was not observed in our case series after long term follow up. Repigmentation is not uncommon within months to years after curettage, however it is often

Table 2. Follow Up Data Regarding Outcomes of Curettage Procedure, Additional Procedures, and Satellite Lesions.

Patient	Age at most recent follow up	Recurrence	Additional procedures	Satellite lesions
1	3 months	Partial repigmentation, hypertrichosis	None	++++
2	5 years	Partial repigmentation	Surgical excision of nevi on the face and neck	++++
3	7 years	Minimal repigmentation, light brown border, central hypertrichosis	None	+
4	12 months	Recurrence of nevus	3-stage wide local excision age 4 years	n/a
5	8 years	Partial repigmentation	Excision of parts of CMN ^a at age 8 years	++++
6	10 years	Partial repigmentation, darker periphery, hypertrichosis	Wide local excision part of CMN on chest	++
7	11 years	Minimal, darker periphery	None	++
8	11 years	Partial repigmentation	None	++++
9	Lost to follow up	Partial repigmentation	Incisional biopsies for areas of increased nodularity in satellite lesion, benign pathology	n/a

Satellite lesions: + = less than 20; ++ = 20-50; +++ = 50-100; ++++ = >100.

N/A: not available

^aCMN = congenital melanocytic nevus.

described as a heterogenous repigmentation⁹ and lighter in color than the congenital nevus,⁵ and this does not occur in all cases. We report similar results, with eight patients developing speckled light brown to tan repigmentation within the curetted field. We observed that the pigmentation of the curetted part of L-GCMNs was significantly lighter than the remaining non-curetted areas or of untreated satellite nevi.

This contrasts with the results of a longitudinal study that reported no effect on long term color of the CMN after being removed by various techniques, including curettage.¹²

In our study, only one patient had complete recurrence of pigmentation of a facial nevus, requiring surgical excision. In another case series,⁴ one patient developed cicatricial alopecia with curettage of a scalp nevus, hence we avoided

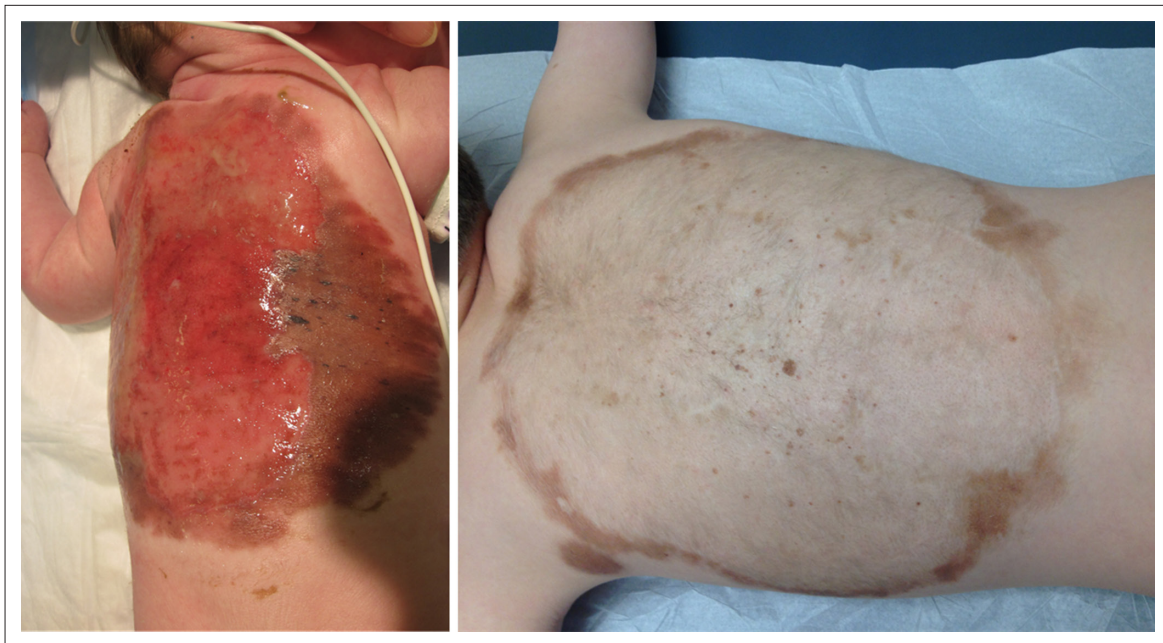


Figure 1. Case 3 several days after birth with (a) partially curetted large congenital nevus involving almost the entire back and (b) in follow up at 4 years of age demonstrating hypertrichosis, minimal repigmentation, and persistent light brown border.

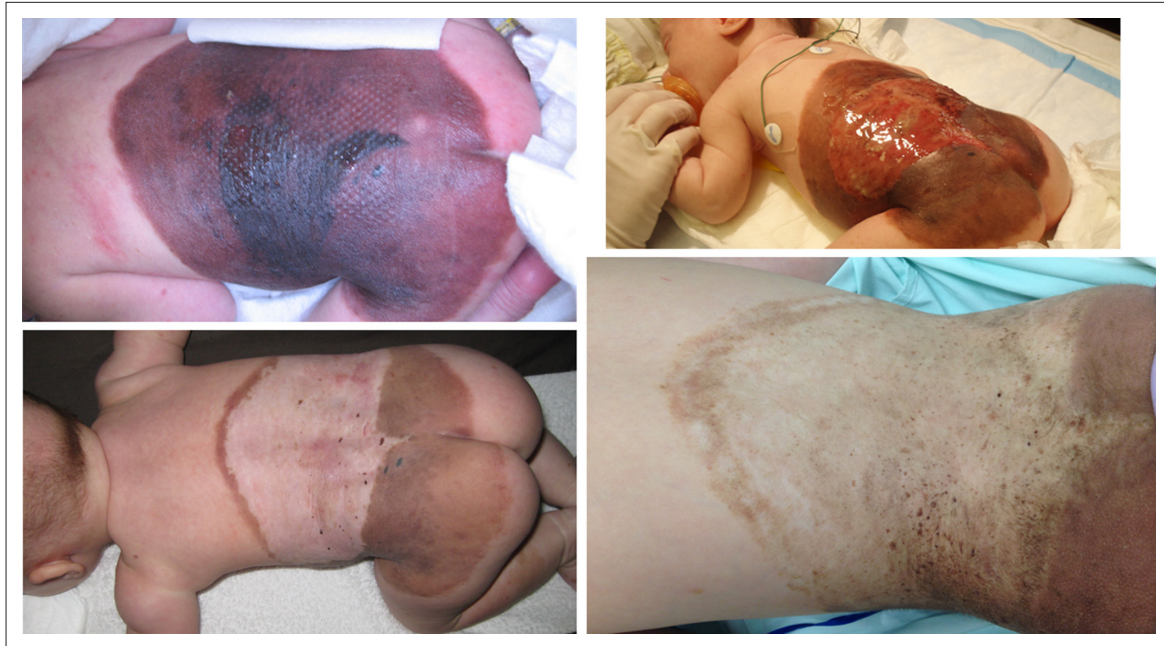

Figure 2. Case 7 demonstrating (a) dark black to brown giant congenital melanocytic nevus at birth with focal areas of ulceration (b) partially curetted nevus in neonatal period (c) healed site of curetted nevus to the back at 3 month follow up, and (d) curetted nevus to the back with mild speckled repigmentation at 9 years of age.

curetting scalp nevi. Curettage may therefore best be utilized for L-GCMNs on the trunk or extremities, with simple observation preferred for scalp nevi and surgical excision for the face for optimal cosmetic and functional outcome if removal is desired by the parents and/or patient.

The risk of malignant transformation of congenital melanocytic nevi has been an ongoing area of controversy in the realm of management of CMNs. Removal of CMNs, whether by surgical excision, curettage, or other means, has not been shown to reduce the risk of malignant melanoma.⁷ Although there is consensus that patients with CMNs are at an increased risk for developing malignant melanoma, with an overall incidence 0.7 to 2.9 percent⁷, melanoma can occur within the CMN, in other cutaneous sites outside of the CMN, as well as extracutaneous sites (meninges, mucosa, retroperitoneum, gastrointestinal tract).¹³ Excision does not adequately remove these other potential sites of malignant transformation, and removal of the primary CMN by curettage only removes the cells in the epidermis and superficial component of the CMN,¹⁴ leaving behind cells in the deeper dermis and subcutaneous tissue. A recent review highlights the current notion that the literature does not support removing CMNs with the intent of reducing the risk of melanoma.⁷ To date, none of our patients developed malignant transformation of the CMN. Patients should continue to be monitored closely, regardless of whether the lesion has been removed. It is important to counsel parents that surgical removal does not

replace close clinical observation and does not decrease the risk of malignant transformation.

Curettage has traditionally been performed under GA. However, concerns have been raised in the literature regarding GA in newborns and young infants, including a potential increased risk of respiratory insufficiency, cardiac arrest and adverse effects on neurological development.¹⁵⁻¹⁷ The effect on the latter has been debated in the literature, as evidence for potential neurotoxicity is derived from animal studies, and human studies have not established a cause and effect relationship. The risk of GA decreases after the 6th month of life, and it is suggested that surgical intervention with GA be delayed until after that time.¹⁸ However, curettage is ideally performed within the first 2 weeks of life. A full discussion regarding the use of GA in neonates for elective procedures is beyond the scope of this article, however general consensus guidelines by SmartTots¹⁹ encourages discussion with the family regarding the benefits of the elective procedure and weighing this against all risks associated with anesthesia and surgery. We used diluted local anesthetic, oral sucrose, and a single dose of morphine per session of curettage as an alternative to GA. This allowed us to avoid the potential risks of GA in early life, while also curetting the majority of the nevus. The use of a single dose of oral morphine prior to or during the procedure was overall well tolerated by the neonates, with no hemodynamic instability, no respiratory depression or hypoxia, and no change in feeding habits.

Curettage also has the advantage of being performed during a time when formed memories of the procedure likely does not yet occur. That said, the impact of medical trauma in the neonatal period is still being investigated. Surgical excision is typically delayed until the child is older. A recent study of children aged 1-6 years hospitalized to the pediatric surgery ward found that approximately 10% of patients showed symptoms of post-traumatic stress disorder 3-5 months after hospitalization and 29% showed signs of distress resulting in dysfunction and difficulty with adjustment.²⁰ Approximately 60% of these admissions were for elective surgeries. This may also have long lasting effects, with children being more anxious or distressed with further exposure to medical appointments and follow up. Performing the curettage procedure within the first 2 weeks of life may mitigate this impact in a patient population that requires regular contact with medical professionals.

Curettage has been reported to be overall quite safe. However, the main adverse effect in our series was positive wound or blood cultures. These were collected daily during curettage sessions, and no patients had systemic symptoms to suggest severe infection. One patient developed transient bacteremia with coagulase negative *Staphylococcus*, which could have been a skin contaminant, however this was promptly treated with a course of intravenous antibiotics without any other adverse sequelae. One patient had a wound swab positive for *Staphylococcus aureus*, and antibiotics were given. Neither patient had systemic symptoms suggestive of sepsis. This procedure has minimal blood loss, minimal tissue trauma, and relatively fast wound healing over 7-21 days. With the use of sterile technique and meticulous wound care, this procedure was generally tolerated well. Close monitoring for infection and appropriate treatment for such is recommended.

Recent literature has suggested a more conservative approach to congenital melanocytic nevi, including more careful selection of cases for surgical intervention.⁷ We agree with this approach and routinely recommend simple observation and monitoring. However, L-GCMN are often disfiguring and distressing for parents, and for children as they age, and many families do seek options for removal. For the families whose wishes involve removal of the nevus, curettage in the first 2 weeks of life is a reasonable treatment option for L-GCMNs, particularly for those located on the trunk for which surgical excision may be extensive, not possible, or requiring multiple stages. Curettage of the face was followed by regrowth of the nevus in one case and was avoided afterwards, although no scarring occurred in our patient. It is the opinion of the authors that curettage can continue to be considered as a less invasive approach for families seeking surgical options for removal in select cases of L-GCMN involving the trunk, providing acceptable aesthetic outcome. We would favor our approach of serial curettage under local anesthetic to avoid the risks of GA. Families

must be counseled on the potential risks of the procedure, including pain, infection, repigmentation, and scarring, and lack of evidence to support decreasing the risk of malignant melanoma.

Acknowledgments

The legal guardians/parents of patients whose images have been included in this manuscript have given written informed consent to publication of their case details.

Declaration of Conflicting Interests

The author(s) declared no potential conflicts of interest with respect to the research, authorship, and/or publication of this article.

Funding

The author(s) received no financial support for the research, authorship, and/or publication of this article.

ORCID iD

Laura C. Soong  <https://orcid.org/0000-0003-2483-3325>

References

1. Alikhan A, Ibrahim OA, Eisen DB. Congenital melanocytic nevi: where are we now? Part I. clinical presentation, epidemiology, pathogenesis, histology, malignant transformation, and neurocutaneous melanosis. *J Am Acad Dermatol.* 2012;67(4):495.e1-495.e17.
2. Koot HM, de Waard-van der Spek F, Peer CD, Mulder PG, Oranje AP. Psychosocial sequelae in 29 children with giant congenital melanocytic naevi. *Clin Exp Dermatol.* 2000;25(8):589-593. doi:10.1046/j.1365-2230.2000.00712.x
3. Moss AL. Congenital "giant" naevus: a preliminary report of a new surgical approach. *Br J Plast Surg.* 1987;40(4):410-419. doi:10.1016/0007-1226(87)90046-4
4. Rasmussen BS, Henriksen TF, Kolle S-FT, Schmidt G. Giant congenital melanocytic nevus report from 30 years of experience in a single department. *Ann Plas Surg.* 2015;74(2):223-229.
5. De Raeve LE, Roseeuw DI. Curettage of giant congenital melanocytic nevi in neonates: a decade later. *Arch Dermatol.* 2002;138(7):943-947. doi:10.1001/archderm.138.7.943
6. Ibrahim OA, Alikhan A, Eisen DB. Congenital melanocytic nevi: where are we now? Part II. Treatment options and approach to treatment. *J Am Acad Dermatol.* 2012;67(4):515.e1-515.e13.
7. Arad E, Zuker RM. The shifting paradigm in the management of giant congenital melanocytic nevi: review and clinical applications. *Plast Reconstr Surg.* 2014;133(2):367-376. doi:10.1097/01.prs.0000436852.32527.8a
8. Kim MJ, Lee DH, Park DH. Multifactorial analysis of the surgical outcomes of giant congenital melanocytic nevi: single versus serial tissue expansion. *Arch Plast Surg.* 2020;47(6):551-558. doi:10.5999/aps.2020.01494

9. Gatibelza ME, Denis D, Bardot J, Casanova D, Degardin N. Current place of curettage in the management of giant congenital nevi: report of 29 patients. *Ann Chir Plast Esthet*. 2013;58(3):228-234. doi:10.1016/j.anplas.2012.11.002
10. Casanova D, Bardot J, Andrac-Meyer L, Magalon G. Early curettage of giant congenital naevi in children. *Br J Dermatol*. 1998;138(2):341-345. doi:10.1046/j.1365-2133.1998.02088.x
11. Zaal LH, Mooi WJ, Smitt HJS, Sillevius Smitt HJ. Results of early curettage of giant congenital melanocytic nevi; a report of eight cases and review of the literature. *Eur J Plast Surg*. 2008;30(6):257-262. doi:10.1007/s00238-007-0192-0
12. Polubothu S, Kinsler VA. Final congenital melanocytic naevi colour is determined by normal skin colour and unaltered by superficial removal techniques: a longitudinal study. *Br J Dermatol*. 2020;182(3):721-728. doi:10.1111/bjd.18149
13. Arneja JS, Gosain AK. Giant congenital melanocytic nevi. *Plast Reconstr Surg*. 2007;120(2):26e-40e. doi:10.1097/01.prs.0000267583.63342.0a
14. De Raeve LE, Claes A, Ruiters DJ, van Muijen GNP, Rosseeuw D, Van Kempen LCLT, LCLT vanK. Distinct phenotypic changes between the superficial and deep component of giant congenital melanocytic naevi: a rationale for curettage. *BJD*. 2006;154(3):485-492. doi:10.1111/j.1365-2133.2005.07055.x
15. Morray JP, Geiduschek JM, Ramamoorthy C, et al. Anesthesia-related cardiac arrest in children: initial findings of the pediatrics perioperative cardiac arrest (POCA) registry. *Anesthesiology*. 2000;96:6-14.
16. Mellon RD, Simone AF, Rappaport BA. Use of anesthetic agents in neonates and young children. *Anesthesia & Analgesia*. 2007;104(3):509-520. doi:10.1213/01.ane.0000255729.96438.b0
17. Loepke AW, Soriano SG. An assessment of the effects of general anesthetics on developing brain structure and neurocognitive function. *Anesth Analg*. 2008;106(6):1681-1707. doi:10.1213/ane.0b013e318167ad77
18. Tromberg J, Bauer B, Benvenuto-Andrade C, Marghoob AA. Congenital melanocytic nevi needing treatment. *Dermatol Ther*. 2005;18(2):136-150. doi:10.1111/j.1529-8019.2005.05012.x
19. Smart Tots Consensus Statement on the Use of Anesthetic and Sedative drugs in Infants and Toddlers. October 2015. <http://smarttots.org/wp-content/uploads/2015/05/ConsensusStatementV10-10.2017.pdf>
20. Ari AB, Peri T, Margalit D, Galili-Weisstub E, Udassin R, Benarroch F. Surgical procedures and pediatric medical traumatic stress (PMTS) syndrome: assessment and future directions. *J Pediatr Surg*. 2018;53(8):1526-1531. doi:10.1016/j.jpedsurg.2017.10.043