

Available online at [www.sciencedirect.com](http://www.sciencedirect.com)

ScienceDirect

journal homepage: [www.elsevier.com/locate/radcr](http://www.elsevier.com/locate/radcr)

## Case Report

# Nuclear imaging in the identification of aberrant vascular anatomy prior to hepatic arterial infusion<sup>☆</sup>

Tristan R. Lawson, MD<sup>a,\*</sup>, Jennifer A. Schroeder, MD<sup>b</sup><sup>a</sup> Department of Diagnostic Radiology, Atrium Health Wake Forest Baptist, Winston-Salem, NC 27157 USA<sup>b</sup> Atrium Health Wake Forest Baptist, Winston-Salem, NC 27157 USA

## ARTICLE INFO

## Article history:

Received 16 March 2022

Revised 1 April 2022

Accepted 2 April 2022

## Keywords:

Nuclear medicine

Colon cancer

Hepatic arterial infusion

Vascular

## ABSTRACT

Hepatic arterial infusion (HAI) pumps are a specialized therapeutic modality designed to deliver high dose local chemotherapy to hepatic metastases in carefully selected patients resulting in improved survival, with patients living an average of 2 years longer than those who did not receive HAI pumps. While beneficial, these chemoinfusion pumps require a multidisciplinary approach to ensure safe and effective treatment for the patient. Here, we present a case where scintigraphic evaluation by the nuclear medicine department directly affected management of a patient with a hepatic arterial infusion pump. Variant vascular anatomy was initially discovered on the postoperative Tc-99m MAA SPECT/CT and was ultimately embolized by interventional radiology prior to initiation of chemoinfusion. This case report demonstrates the utility of obtaining nuclear medicine scintigraphy prior to chemoinfusion in patients with hepatic arterial infusion pumps.

© 2022 The Authors. Published by Elsevier Inc. on behalf of University of Washington.

This is an open access article under the CC BY-NC-ND license

(<http://creativecommons.org/licenses/by-nc-nd/4.0/>)

## Introduction

Colorectal cancer remains a prevalent disease and is currently the third leading cause of cancer-related deaths in the United States [1]. Approximately 50% of patients with colorectal cancer will develop liver metastases during their disease course, which presents unique opportunities for management [2]. Surgical resection of hepatic metastases can improve long-term survival and can be potentially curative in selected patients. However, only about 15%-20% of patients will be candidates for surgical resection at the time of presentation [2]. For

patients who are not candidates for resection of metastatic lesions, there are a variety of locally delivered therapies including hepatic arterial infusion pumps, radioembolization, and chemoembolization, which are usually combined with systemic therapies. In the case of the hepatic arterial pump, patients typically undergo hepatic artery infusion scintigraphy with Tc-99m MAA SPECT/CT after surgical implantation but prior to initiation of local chemoinfusion. This study allows for the evaluation of anticipated distribution of the chemoinfusion agent to maximize the potential benefit of therapy and pre-emptively identify complicating factors including perfusion shunts and variant anatomy.

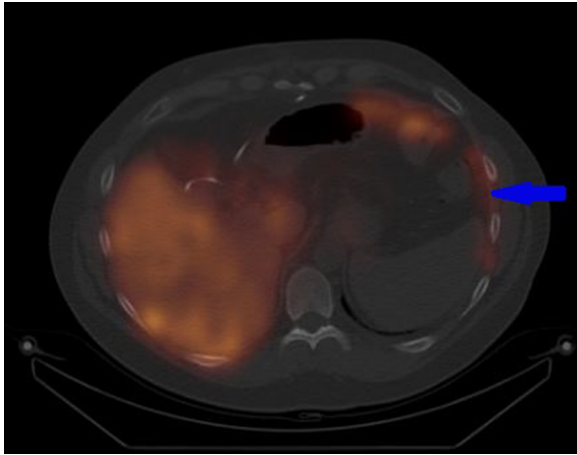
<sup>☆</sup> Competing interest: Neither Drs. Lawson or Schroeder nor our immediate family members have a financial relationship with a commercial organization that may have a direct or indirect interest in the content.

\* Corresponding author.

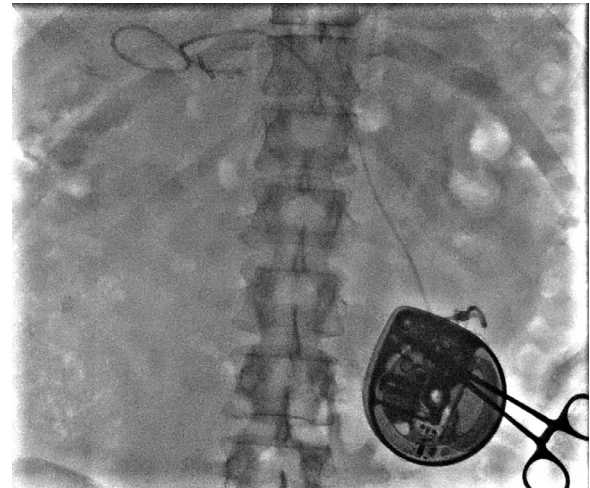
E-mail address: [trilawso@wakehealth.edu](mailto:trilawso@wakehealth.edu) (T.R. Lawson).

<https://doi.org/10.1016/j.radcr.2022.04.001>

1930-0433/© 2022 The Authors. Published by Elsevier Inc. on behalf of University of Washington. This is an open access article under the CC BY-NC-ND license (<http://creativecommons.org/licenses/by-nc-nd/4.0/>)



**Fig. 1 – SPECT/CT of the upper abdomen with abnormal Tc-99m MAA uptake in the left upper quadrant along the left hemidiaphragm (arrow).**



**Fig. 2 – Fluoroscopic image of the abdomen obtained during IR-assisted pump access.**

## Case report

A 45-year-old male patient presented to the nuclear medicine department for a postoperative Tc99m MAA SPECT/CT after surgical implantation of a hepatic arterial infusion pump and simultaneous microwave ablations of multiple hepatic metastases. This patient's cancer history began 1 year before when his metastatic colon cancer was initially discovered as hepatic metastatic disease. He was initially treated with systemic chemotherapy as he was not a candidate for surgical resection. The patient had an excellent response from systemic chemotherapy and was re-evaluated by surgical oncology who recommended microwave ablation of hepatic metastases and hepatic arterial infusion pump implantation, which he underwent without complication. During surgery, a replaced right hepatic artery was identified arising from the superior mesenteric artery and the infusion pump was placed in the left hepatic artery arising from the celiac axis.

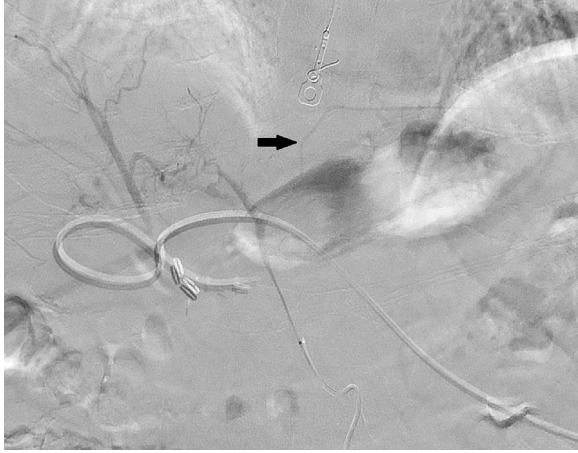On the day of his first postoperative scintigraphic evaluation, the patient's hepatic arterial infusion pump was accessed by the nuclear medicine physician and 2.53 mCi of Tc-99m MAA was administered intra-arterially. Planar imaging and SPECT/CT of the chest and abdomen were performed. SPECT/CT demonstrated primary distribution of radiotracer within the left hepatic lobe with a lung shunt percentage of 7%, as expected. However, there were some unexpected findings including curvilinear region of radiotracer uptake in the left upper quadrant in the region of the left hemidiaphragm of unclear etiology (Fig. 1) as well as free pertechnetate in the thyroid. The corresponding available anatomic imaging demonstrated expected positioning of the hepatic artery infusion pump with the tip in the region of the left hepatic artery. The etiology of the abnormal tracer uptake was unclear at this time as no other variant anatomy had been identified that would explain the SPECT/CT results. One possible explanation put forwards was free tracer within the abdomen due to pump access; although, the uncertainty was too high to rely on this

supposition. Thus to be cautious, a repeat study was recommended.

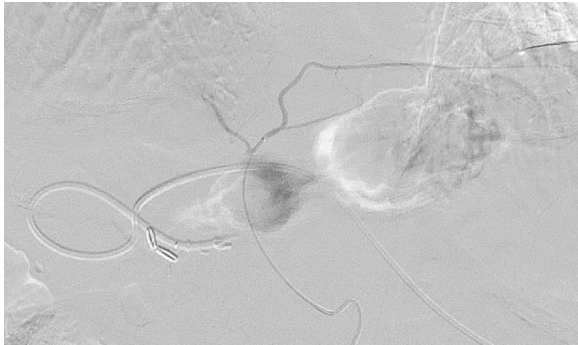
Patient then presented again to the nuclear medicine department 1 week after his initial imaging for the recommended repeat study. Unfortunately, there was difficulty accessing the hepatic artery pump for radiotracer injection and subsequent imaging showed radiotracer primarily within the port pocket itself. A repeat Tc-99m MAA perfusion study was recommended in combination with Interventional Radiology to ensure successful pump access.

Patient presented to interventional radiology 3 weeks later where his infusion pump was accessed under fluoroscopy (Fig. 2). Two mCi of Tc99m MAA was administered intra-arterially and repeat SPECT/CT was obtained. Abnormal tracer uptake was again noted in the left upper quadrant in the region of the left hemidiaphragm and splenic flexure in addition to expected tracer uptake within the left hepatic lobe. Lung shunt percentage remained within acceptable limits at 4%. Persistent abnormal uptake within the left upper quadrant across multiple examinations raised concern for variant vascular anatomy arising from the left hepatic artery. By this time, the clinical team was impatient to begin chemoinfusion and was anxious at the thought of delaying further. However, the importance of further evaluation by interventional radiology with angiogram was strongly conveyed, with the explanation that identification and embolization of variant anatomy could reduce related complications of extrahepatic infusion.

Interventional Radiology performed a diagnostic angiogram supplemented by cone beam CT 1 week later which demonstrated an aberrant left phrenic artery arising from the left hepatic artery which accounted for the abnormal radiotracer distribution (Figs. 3 and 4). This aberrant left phrenic artery was successfully embolized with coils without residual filling on post-embolization angiogram (Fig. 5). The next day, patient was able to safely receive a therapeutic infusion through his pump and avoid potential complication related to his rare aberrant vascular anatomy.



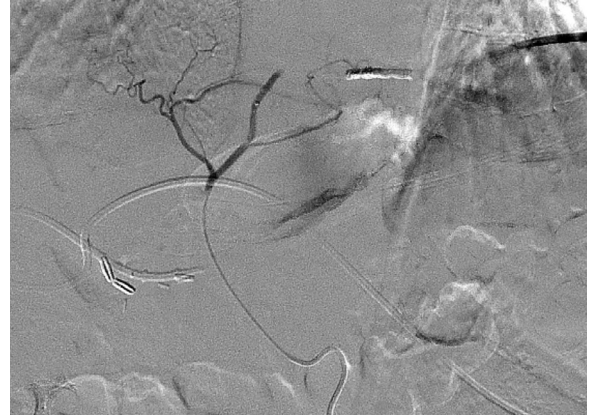
**Fig. 3 – Angiogram demonstrates aberrant left phrenic (arrow) arising from the left hepatic artery.**



**Fig. 4 – Selective angiogram of the aberrant left phrenic artery.**

## Discussion

Hepatic arterial infusion (HAI) pumps have been shown to be efficacious in combination with systemic chemotherapy when treating colorectal liver metastases [3]. These pumps require a multidisciplinary approach for successful therapy and are usually limited to large, specialized centers. The HAI device is typically implanted into a subcutaneous pocket in the abdominal wall and connected to a surgically or percutaneously placed catheter in the hepatic or gastroduodenal arteries [3]. Prior to placement, CTA of the abdominal vasculature should be obtained to define any aberrant vascular anatomy. Postoperative complications occur in approximately 20% of patients and can include arterial thrombosis, extrahepatic perfusion, hepatitis and biliary sclerosis. Extrahepatic uptake occurs in approximately 2%-9% of cases, with the most common sites being the stomach, duodenum, and pancreas [3]. Extrahepatic uptake can be discovered on the postoperative HAI perfusion SPECT/CT or symptomatically after the initiation of chemoinfusion. The source of extrahepatic uptake should be identified and treatment is selective embolization of the causative vessel.



**Fig. 5 – Post embolization angiogram demonstrates coil occlusion of the aberrant left phrenic without residual flow.**

Standard celiac axis anatomy is present when the first celiac branch is the left gastric artery after which the vessel divides into the splenic artery and common hepatic artery. The common hepatic artery then bifurcates into the proper hepatic artery and the gastroduodenal artery with the proper hepatic bifurcating again to form the right and left hepatic arteries. This standard or classical anatomy is only present in approximately 60% of patients on angiography with the remainder showing some degree of variant anatomy [4]. The most common variants include replaced hepatic arteries where the right hepatic artery arises from the superior mesenteric artery or the left hepatic artery arises from the left gastric artery [4]. The inferior phrenic artery (IPA), as demonstrated in our case, is an important artery to be aware of. The right and left IPAs commonly arise from the abdominal aorta or celiac trunk and supply the diaphragm, adrenals, and esophagus. The liver can also be supplied by the right inferior phrenic artery, and it is the most common extrahepatic arterial supply of a hepatocellular carcinoma [5]. More uncommonly, the inferior phrenic artery can arise from the renal arteries, left gastric artery, hepatic artery, or SMA. In a collection of 383 Interventional Radiology cases, only 2.1% of patients demonstrated an inferior phrenic arising from the hepatic artery, as our patient did [5].

Hepatic artery perfusion SPECT/CT is typically performed after HAI pump placement to confirm hepatic perfusion and to exclude extrahepatic uptake. Although variant vascular anatomy is often recognized on preoperative CTA or during pump placement, small aberrant vessels can be missed or not evident due to modality limitations. Because of the sensitivity of perfusion SPECT/CT, extrahepatic uptake on postoperative HAI flow studies should be taken seriously and investigated further with a diagnostic angiogram, even if variant anatomy is not identified prospectively on CTA. In a prior case series, approximately 9.5% of HAI patients had extrahepatic uptake on postoperative perfusion scans, with the majority undergoing selective arterial embolization [6]. Our case demonstrates the direct impact the nuclear medicine department can have on HAI patients. Nuclear Medicine physicians should diligently search for areas of extrahepatic uptake, correlate with

anatomic imaging to identify variant vascular anatomy, and recommend further workup with diagnostic angiogram if appropriate.

---

## Conclusion

Our case illustrates the importance of nuclear medicine imaging during the assessment of complex oncologic patients and provides an example of a direct change in management based on hepatic artery perfusion scintigraphy. Identification of variant vascular anatomy prior to chemoinfusion can improve patient outcomes and improve morbidity. A multidisciplinary approach including surgical oncology, medical oncology, interventional radiology, and nuclear radiology was required in order for this patient to receive safe and effective therapy.

---

## Patient consent statement

Informed written consent was obtained from the patient prior to submission of this case report.

## REFERENCES

---

- [1] Colorectal Cancer Statistics. Centers for Disease Control and Prevention.  
<https://www.cdc.gov/cancer/colorectal/statistics/index.htm>. Published June 8, 2021. Accessed July 12, 2021.
- [2] Zarour LR, Anand S, Billingsley KG, Bisson WH, Cercek A, Clarke MF, et al. Colorectal cancer liver metastasis: evolving paradigms and future directions. *Cell Mol Gastroenterol Hepatol* 2017;3(2):163–73. doi:10.1016/j.jcmgh.2017.01.006.
- [3] Doussot A, Kemeny NE, D'Angelica MI. Hepatic arterial infusional chemotherapy in the management of colorectal cancer liver metastases. *Hepatic Oncol* 2015;2(3):275–90. doi:10.2217/hep.15.9.
- [4] Covey AM, Brody LA, Maluccio MA, Getrajdman GI, Brown KT. Variant hepatic arterial anatomy revisited: digital subtraction angiography performed in 600 patients. *Radiology* 2002;224(2):542–7. doi:10.1148/radiol.2242011283.
- [5] Gwon DI, Ko G-Y, Yoon H-K, Sung K-B, Lee JM, Ryu SJ, et al. Inferior phrenic artery: anatomy, variations, pathologic conditions, and interventional management. *Radiographics* 2007;27(3):687–705. doi:10.1148/rg.273065036.
- [6] Perez DR, Kemeny NE, Brown KT, Gewirtz AN, Paty PB, Jarnagin WR, et al. Angiographic identification of extrahepatic perfusion after hepatic arterial pump placement: implications for surgical prevention. *HPB* 2014;16(8):744–8. doi:10.1111/hpb.12208.