

# Treatment approach for coexisting chest wall fractures and unstable thoracolumbar spine fractures in polytrauma patients requiring prone spine surgery

Aymen Alqazzaz <sup>1</sup>, Zan Naseer,<sup>1</sup> Carl A Beyer,<sup>2</sup> Jeremy W Cannon <sup>2</sup>, Amrit Khalsa<sup>1</sup>

<sup>1</sup>Department of Orthopaedics, University of Pennsylvania Perelman School of Medicine, Philadelphia, Pennsylvania, USA  
<sup>2</sup>Division of Traumatology, Surgical Critical Care & Emergency Surgery, Department of Surgery, University of Pennsylvania Perelman School of Medicine, Philadelphia, Pennsylvania, USA

## Correspondence to

Dr Aymen Alqazzaz; aymen.alqazzaz@penmedicine.upenn.edu

Received 12 July 2023

Accepted 31 December 2023

## SUMMARY

Concomitant chest wall fractures (sternal and/or rib fractures) with unstable thoracolumbar fractures that require surgical fixation are rare but highly morbid injuries that mandate a multidisciplinary approach to treatment. There is limited evidence in the literature regarding optimal timing and order of surgical fixation of these patients with multiple injuries. Here, we present our experience with two patients at a single institution that demonstrates the challenges that present with this patient population. We advocate for earlier fixation of the chest wall fractures in the appropriately indicated patients, prior to prone positioning for spinal fixation.

## INTRODUCTION

Thoracic trauma occurs in up to 60% of polytraumatized patients. Despite advancements in treating these patients, thoracic injury is reported as the cause of mortality in up to 25% of polytrauma patients.<sup>1–3</sup> Blunt injuries, including chest wall trauma, account for 70% of these injuries.<sup>4</sup> In cases with concurrent chest wall and spinal column injuries, management of unstable spinal fractures complicates matters, particularly if subsequent prone spine surgery is required. In recent years, there has been increasing interest in a multidisciplinary approach with initial surgical fixation of sternal and rib fractures with the aim of reducing cardiopulmonary complications and subsequent morbidity and mortality in these patients.

Current literature favors surgical rib fixation in patients with flail chest in the polytraumatized patient.<sup>5–7</sup> Sternal fractures, though less common, carry a significant morbidity burden, particularly with concomitant injuries such as spinal fractures or pulmonary contusions. A study by Krinner *et al* demonstrated that surgical fixation of sternal fractures was associated with a significant reduction in mortality in patients with concomitant spinal fractures.<sup>8</sup> Other studies have confirmed similar results, reporting surgical fixation of sternal fractures resulted in improved pain control, respiratory function, and overall patient satisfaction compared with non-surgical management.<sup>9 10</sup> The optimal timing and sequence of surgical intervention in these patients are critical, as decision is influenced by multiple considerations, including the severity and location of both the chest wall and spinal fractures, the patient's overall health and neurologic status, and the potential risks associated with

surgery. However, literature describing the ideal order of treatment when there are both unstable spine and chest wall fractures remains scarce. Some studies have advocated for early surgical intervention in patients with severe or multiple chest wall fractures,<sup>11 12</sup> whereas others suggest alternative approaches, including delaying surgery until after the spine has been stabilized.<sup>9 13 14</sup>

Lebhar *et al* presented an algorithm for surgical intervention in a patient with thoracic instability, advocating for anterior stabilization prior to spinal fixation.<sup>15</sup> Here, we report on our experience with two polytrauma patients with unstable sternal/rib fractures and unstable spine fractures requiring prone spine surgery to highlight different operative approaches and to recommend what we think to be the optimal timing and order of treatment for these patients.

## CASES

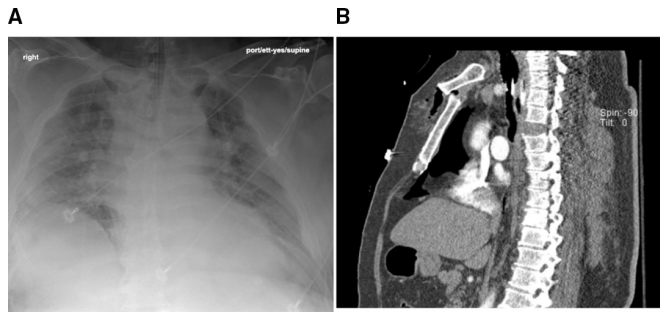
### Patient 1

A patient in their 60s (weight: 151.7 kg, body mass index (BMI): 44.12 kg/m<sup>2</sup>) was transported to our trauma center from a referring hospital after a high-speed motor vehicle collision with prolonged extrication. On initial presentation at the referring hospital, the patient had normal Glasgow Coma Scale (GCS), but soon after arrival became hypoxic. Tension pneumothorax and hemorrhagic shock were noted, requiring bilateral chest tubes, intubation, and volume resuscitation with 4 units of packed red blood cells. On arrival at our institution, the patient presented with GCS3T and a hypermobile sternum, but no further obvious signs of external injury. CT of the chest revealed a distraction injury at T3–4 disc space with no apparent bony fracture (*figure 1*), as well as sternal manubrial dislocation, and multiple rib fractures (ribs 4, 5, 6, 7 and 8 on the right; and ribs 3 and 4 on the left). Additionally, MRI of the T-spine showed no compressive hematoma at the level of distraction injury. On physical examination after improvement in GCS score, the patient strength was 3/5 to upper extremities and 0/5 to lower extremities.

Given concern for gross instability of the thoracic spine, a decision was made to urgently stabilize the spine initially. However, upon positioning the patient prone, they became hypotensive, tachycardic, and hypoxic. The patient was quickly repositioned supine and returned to baseline preoperative hemodynamics without losing

© Author(s) (or their employer(s)) 2024. Re-use permitted under CC BY-NC. No commercial re-use. See rights and permissions. Published by BMJ.

**To cite:** Alqazzaz A, Naseer Z, Beyer CA, *et al*. *Trauma Surg Acute Care Open* 2024;**9**:e001196.

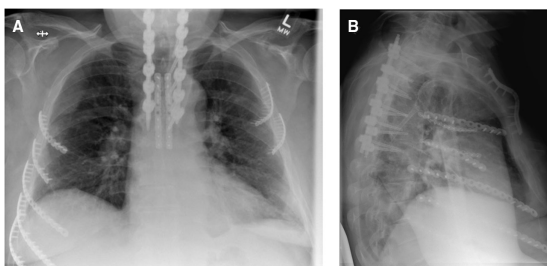


**Figure 1** Patient 1 initial injury films. (A) Initial injury chest X-ray. (B) Sagittal thoracic spine CT scan demonstrating the distraction injury at the T3–T4 level.

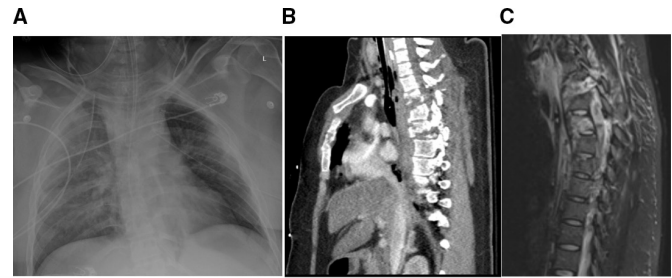
pulses. A transesophageal echo was performed revealing no structural abnormalities, contusion, or pericardial effusion, with direct visualization of the right ventricle showing no wall motion abnormalities or contusion, with appropriate function and filling. It was felt that proning caused this patient's hemodynamic instability due to right ventricular compression in the setting of unstable sternal/rib fractures. Spine surgery was aborted and the patient was transferred to the surgical intensive care unit (ICU) for monitoring. The following day, the patient was taken back to the operating room for spinal fixation given concerns for ongoing severe spinal instability. The patient was placed in the left lateral decubitus position to avoid hemodynamic instability and underwent T1–T6 lateral instrumented fusion. The patient tolerated the procedure with no complications (figure 2). On postoperative day 2 (POD2), the patient underwent open reduction and internal fixation (ORIF) of the sternum in the supine position, followed by surgical stabilization of right ribs 4, 5, 6, 7, 8 and repair of a traumatic lung laceration in the lateral decubitus position. On POD4, the patient further underwent ORIF of left ribs 3 and 4. Sternal and rib fixation was performed with bicortical anterior plate systems. The patient remained in the hospital for 28 days and was then discharged to an inpatient rehabilitation facility in stable condition with no neurologic sequelae from his initial episode of intraoperative hemodynamic instability.

### Patient 2

A patient in their 20s (weight: 94.3 kg, BMI: 39.83 kg/m<sup>2</sup>) was transferred from a referring hospital to our trauma center after a motor vehicle collision with ejection from the vehicle. At initial evaluation, the patient was unconscious with a GCS of 3 and absent bilateral breath sounds requiring intubation, and emergent bilateral chest tubes were placed. The patient was transferred to the trauma ICU at our institution for further management on the same day as the injury. Further workup demonstrated an



**Figure 2** Patient 1 postoperative anteroposterior and lateral chest X-rays showing instrumentation of the chest and spine.



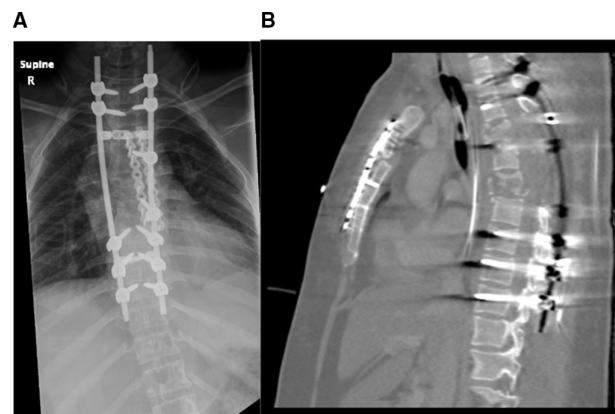
**Figure 3** Patient 2 initial injury films. (A) Initial injury chest X-ray, (B) sagittal thoracic spine CT scan and (C) sagittal MRI cut showing initial injury.

unstable sternal fracture through the sternal-manubrial junction, right 3–7 rib fractures, and left 2–6 rib fractures. Spine injuries included T3–5 unstable three-column injury and cord compression, right C6 facet fracture, C7–T5 spinous process fractures, and C7/T1 transverse process fractures (figure 3). There was no evidence of intracranial hemorrhage or other injuries at the time of evaluation at the referring hospital. Upon arrival at our institution, sedation was weaned to obtain a neurological examination, and the patient was able to follow commands and move upper extremities; however, motor examination was notable for 0/5 in the bilateral lower extremities, and no sensation below the level of nipples. Absent volitional tone, lack of perianal sensation, negative bulbocavernosus reflex, and negative Babinski reflex bilaterally were noted.

Decision was made to perform initial ORIF of the sternum with a bicortical anterior plate system on the third day after injury, and after the sternum and chest wall were confirmed to be stable, the patient was immediately prone and underwent T1–T9 posterior spinal fusion with T3–T7 laminectomy with no intraoperative complications (figure 4). Postoperative hospital course was notable for only hypervolemia requiring diuresis. The patient was discharged on POD23 to an acute inpatient rehabilitation facility in stable condition.

### DISCUSSION

The sternum and upper thoracic spine along with the ribs form a mechanical and anatomic unit called ‘the upper thoracic cage,’ and the added stability of the sternum to the thoracic spine has led some to label the sternum as the ‘fourth column of the spine’.<sup>16</sup> Combined injuries to these structures place patients at



**Figure 4** Patient 2 postoperative images. (A) Postoperative posteroanterior chest X-ray and (B) sagittal CT scan showing instrumentation of the chest and spine.

higher risk than isolated injuries and therefore order of planned interventions must be critically considered. The role for early surgical intervention for unstable traumatic spinal cord injury is well documented, particularly in those with incomplete neurologic deficits.<sup>17</sup> In the polytraumatized patient, this can be complicated in the presence of chest wall trauma. These patients require co-management through a multidisciplinary approach between the trauma surgeons and spine surgeons, as well as other involved services. Given the complex fracture pattern, prone positioning during spine surgery can complicate cardiopulmonary stability in addition to multiple other concerns.<sup>18</sup>

The challenges of prone positioning during spine surgery in patients with coexisting chest wall trauma are sparsely discussed in the literature. These challenges include hemodynamic instability secondary to increase in intrathoracic pressure and venous return compromise, concurrent potential cardiopulmonary injury, and proximity of anterior chest wall to major vasculature. Pennington *et al* described two cases with flail chest that had previously experienced hemodynamic collapse during prone positioning for spine surgery. After implementing a novel technique using the anterior portion of a thoracolumbar sacral orthosis during positioning, both patients were then able to tolerate proning for successful spinal fixation.<sup>19</sup>

In the largest review of patients with combined chest wall and spine fractures to date, Alvi *et al* discussed a retrospective study of 57 patients with concomitant rib fractures who underwent spinal fixation.<sup>20</sup> Only seven patients (12%) had received rib fixation surgery and only one of which was performed before spinal surgery. Furthermore, four spinal fixation cases had to be aborted, three of which were due to cardiopulmonary complications and a fourth case due to increased intracranial pressure in the setting of a traumatic brain injury. Similarly, Wessell *et al* published a case of flail chest physiology associated with unstable cervical and thoracic fractures that tolerated proning only after rib fixation.<sup>21</sup> This patient was scheduled to undergo occipital-cervical-thoracic fusion for C1 burst fracture, C2 lamina fracture, left C5–7 lateral mass fractures, and T1 three-column injury. He developed hemodynamic instability shortly after prone positioning that was refractory to pressor therapy. He was repositioned supine, spine surgery was aborted, and the trauma team performed internal fixation of right fifth and sixth ribs, the left fifth rib, and sternum. Three days later, the patient underwent successful occipital to T3 fusion with no complications.

Here, we presented two cases: the first patient initially had an attempted prone spine surgery that was aborted due to hemodynamic instability during prone positioning and later had a delayed and more technically demanding spinal fixation in the lateral decubitus position followed by sternal and rib fixation. The second patient underwent sternal fixation first, followed by uncomplicated and timely spinal fixation in the more traditional prone position. These patients highlight the unique clinical predicament in the management of these polytrauma patients. The findings of this study advocate for initial sternal and chest wall stabilization prior to proning for spinal surgery. Further larger-scale studies to demonstrate optimal timing and order of surgical interventions are warranted.

**Contributors** Every listed author has significantly contributed to the conception and design of the work, as well as the acquisition and interpretation of data for the work. Each author has contributed to drafting and revising the work, as well as final approval of the version to be published.

**Funding** The authors have not declared a specific grant for this research from any funding agency in the public, commercial or not-for-profit sectors.

**Competing interests** None declared.

**Patient consent for publication** Not applicable.

**Provenance and peer review** Not commissioned; internally peer reviewed.

**Open access** This is an open access article distributed in accordance with the Creative Commons Attribution Non Commercial (CC BY-NC 4.0) license, which permits others to distribute, remix, adapt, build upon this work non-commercially, and license their derivative works on different terms, provided the original work is properly cited, appropriate credit is given, any changes made indicated, and the use is non-commercial. See: <http://creativecommons.org/licenses/by-nc/4.0/>.

#### ORCID iDs

Aymen Alqazzaz <http://orcid.org/0009-0005-6698-5222>

Jeremy W Cannon <http://orcid.org/0000-0002-2969-9316>

#### REFERENCES

- 1 Broderick SR. Hemothorax: etiology, diagnosis, and management. *Thorac Surg Clin* 2013;23:89–96.
- 2 Khandhar SJ, Johnson SB, Calhoun JH. Overview of thoracic trauma in the United States. *Thorac Surg Clin* 2007;17:1–9.
- 3 LoCicero J, Mattox KL. Epidemiology of chest trauma. *Surg Clin North Am* 1989;69:15–9.
- 4 Harrison M. Traumatic Pneumothorax: a review of current practices. *Br J Hosp Med* 2014;75:132–5.
- 5 Kasotakis G, Hasenboehler EA, Streib EW, Patel N, Patel MB, Alarcon L, Bosarge PL, Love J, Haut ER, Como JJ. Operative fixation of rib fractures after blunt trauma: a practice management guideline from the Eastern association for the surgery of trauma. *J Trauma Acute Care Surg* 2017;82:618–26.
- 6 Pieracci FM, Rodil M, Stovall RT, Johnson JL, Biffi WL, Mauffrey C, Moore EE, Jurkovich GJ. Surgical stabilization of severe rib fractures. *J Trauma Acute Care Surg* 2015;78:883–7.
- 7 Morgenstern M, von Rüden C, Callsen H, Friederichs J, Hungerer S, Bühren V, Woltmann A, Hierholzer C. The unstable thoracic cage injury: the concomitant sternal fracture indicates a severe thoracic spine fracture. *Injury* 2016;245–72.
- 8 Krinner S, Grupp S, Oppel P, Langenbach A, Hennig FF, Schulz-Drost S. Do low profile implants provide reliable stability in fixing the sternal fractures as a "fourth vertebral column." *J Thorac Dis* 2017;9:1054–64.
- 9 Klei DS, de Jong MB, Öner FC, Leenen LPH, van Wessem KJP. Current treatment and outcomes of traumatic sternal fractures—a systematic review. *Int Orthop* 2019;43:1455–64.
- 10 Zhao Y, Yang Y, Gao Z, Wu W, He W, Zhao T. Treatment of traumatic sternal fractures with titanium plate internal fixation: a retrospective study. *J Cardiothorac Surg* 2017;12:22.
- 11 Ciriaco P, Casiraghi M, Negri G, Gioia G, Carretta A, Melloni G, Zannini P. Early surgical repair of isolated traumatic sternal fractures using a cervical plate system. *J Trauma* 2009;66:462–4.
- 12 Schulz-Drost S, Oppel P, Grupp S, Schmitt S, Carbon RT, Mauerer A, Hennig FF, Buder T. Surgical fixation of sternal fractures: preoperative planning and a safe surgical technique using locked titanium plates and depth limited drilling. *J Vis Exp* 2015:e52124.
- 13 Harston A, Roberts C. Fixation of sternal fractures: a systematic review. *J Trauma* 2011;71:1875–9.
- 14 Klei DS, Öner FC, Leenen LPH, van Wessem KJP. No need for sternal fixation in traumatic sternovertebral fractures: outcomes of a 10-year retrospective cohort study. *Global Spine J* 2021;11:283–91.
- 15 Lehtar MS, Anastasio A, Fernandez-Moure JS, Shiroff A. Four columns of the thorax: operative decision-making in the setting of complete bony instability. *Ann Thorac Surg* 2021;111:e101–3.
- 16 Breitenbach M, Phan A, Botros M, Paul D, Molinari R, Menga E, Mesfin A. The fourth column of the spine: prevalence of sternal fractures and concurrent Thoracic spinal fractures. *Injury* 2022;53:1062–7.
- 17 Qadir I, Riew KD, Alam SR, Akram R, Waqas M, Aziz A. Timing of surgery in thoracolumbar spine injury: impact on neurological outcome. *Global Spine J* 2020;10:826–31.
- 18 DePasse JM, Palumbo MA, Haque M, Ebersson CP, Daniels AH. Complications associated with prone positioning in elective spinal surgery. *World J Orthop* 2015;6:351–9.
- 19 Pennington MW, Roche AM, Bransford RJ, Zhang F, Dagal A. A technique to allow prone positioning in the spine surgery patient with unstable spine fracture and flail segment rib fractures. *Case Rep* 2016;7:2–4.
- 20 Alvi MA, Kapurch JRI, Ivanov DV, Kerezoudis P, Bydon M, Freedman BA. Does the coexistence of multiple segmental rib fractures in polytrauma patients presenting with "major" vertebral fracture affect care and acute outcomes? *J Orthop Trauma* 2019;33:23–30.
- 21 Wessell JE, Pereira MP, Eriksson EA, Kalthorn SP. Rib fixation for flail chest physiology and the facilitation of safe prone spinal surgery: illustrative case. *J Neurosurg Case Lessons* 2022;4:CASE22337.