

# CASE REPORT

Nagoya J. Med. Sci. 82, 775–781, 2020  
doi:10.18999/nagjms.82.4.775

## A rare case of myocardial calcification secondary to acute myocarditis due to an *Escherichia coli* infection

Masaya Washino<sup>1</sup>, Tomoki Tanaka<sup>1</sup>, Yukiko Nakase<sup>1</sup>, Tomonori Aoi<sup>1</sup>, Nobuhide Endo<sup>1</sup>,  
Hideaki Ishikawa<sup>1</sup> and Yoshihiro Morishita<sup>2</sup>

<sup>1</sup>Department of Nephrology, Japanese Red Cross Nagoya First Hospital, Nagoya, Japan

<sup>2</sup>Department of Cardiology, Japanese Red Cross Nagoya First Hospital, Nagoya, Japan

### ABSTRACT

Myocardial calcification secondary to acute myocarditis is a rare but possibly life-threatening complication.

We report a 43-year-old woman with minimal change nephrotic syndrome who developed sepsis caused by *Escherichia coli*. We simultaneously detected the complication of acute myocarditis in the patient.

Although echocardiography showed hypokinesis of the apical segment when acute myocarditis was diagnosed, no sign of myocardial calcification was observed.

After two weeks, a CT showed myocardial calcification in the same area. Although myocardial calcification was still observed 12 months later, the patient's cardiac function had improved.

Keywords: myocardial calcification, acute myocarditis, *Escherichia coli*, sepsis

This is an Open Access article distributed under the Creative Commons Attribution-NonCommercial-NoDerivatives 4.0 International License. To view the details of this license, please visit (<http://creativecommons.org/licenses/by-nc-nd/4.0/>).

### CASE REPORT

A 43-year-old woman had gradually gained weight with leg edema since December 2016 and was referred to a clinic. She was found to have the nephrotic syndrome by a primary care doctor and was therefore admitted to a hospital. A diagnosis of minimal change nephrotic syndrome (MCNS) was made and steroid therapy was initiated. She received steroid pulse (1000 mg/day for 3 days), following by daily oral administration of prednisolone (1 mg/kg/day). One week after the start of this treatment the patient suddenly developed a high fever, with laboratory data indicating the complication of acute kidney injury (AKI), that necessitated admission to our hospital.

On admission, she appeared drowsy with a blood pressure of 121/93 mmHg, pulse rate 80/min, and body temperature 36.8°C. Physical examination showed bilateral lower extremity edema, but no chest pain or abdominal tenderness. Laboratory tests demonstrated extremely high inflammation, abnormal cardiac biomarkers, and renal dysfunction: CRP 48.93 mg/dL, Alb

Received: September 20, 2019; accepted: March 9, 2020

Corresponding Author: Hideaki Ishikawa, MD, PhD

Department of Nephrology, Japanese Red Cross Nagoya First Hospital, 3-35 Michishita-cho, Nakamura-ku, Nagoya 453-8511, Japan

Tel: +81-52-481-5111, Fax: +81-52-482-7733, E-mail: h-ishikawa@nagoya-1st.jrc.or.jp

1.4 g/dL, CK 2529 mg/dL, CK-MB 196 mg/dL, Cr 3.75 mg/dL, troponin-T 14.19 < ng/mL, and PCT (procalcitonin) 100.0 < ng/mL. Marked proteinuria was also observed consistent with the nephrotic syndrome (Table 1).

An electrocardiogram (ECG) showed an ST-elevation at every lead except aVR and V1 (Figure 1). Chest X-ray identified a pleural effusion but no pulmonary congestion, while computed tomography (CT) also showed pleural effusion (Figure 2A). An echocardiogram demonstrated reduced wall motion of the mid and apical segments of the left ventricle, with the ejection fraction (EF) of the basal walls being approximately 30%, a finding that indicated hypokinesis.

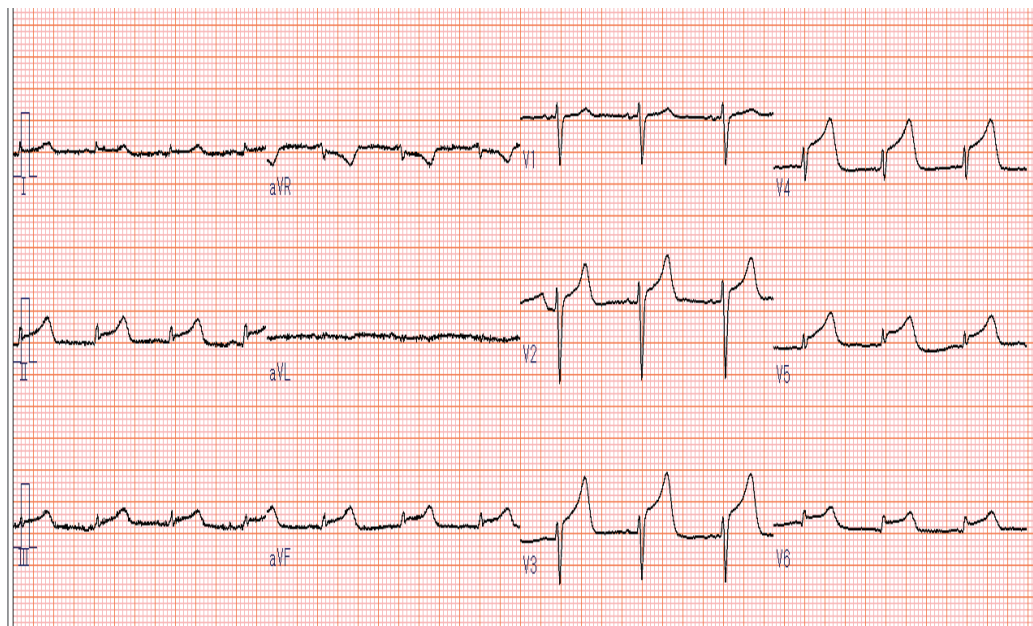
Taken together, these findings are similar to those seen in Takotsubo cardiomyopathy, leading to a diagnosis of acute myocarditis. Although we speculated this condition may have been associated with a viral infection, there was no significant elevation in antibody titers in paired serum samples for influenza A/B, adenovirus, coxsackie A9/B1/B3/B4/B5/B6, cytomegalovirus, parvovirus B19, HHV-6, or echovirus.

Although *Escherichia coli* was not identified in the urine culture, a blood culture was positive for this organism, which was shown to be susceptible to many different types of antibiotics.

The patient was considered to have several complications including acute kidney injury (AKI), acute myocarditis, and sepsis due to *Escherichia coli* and was therefore treated with Meropenem and Levofloxacin.

The following day, severe respiratory distress with pulmonary congestion developed suddenly, with the AKI resulting in anuria. These two outcomes required treatment with non-invasive positive pressure ventilation continuous hemodiafiltration in our intensive care unit.

The myocarditis was monitored using echocardiography and CT, and on the fifth hospital day CT identified a slight sign of a high-density region consistent with an area of hyperkinesis thought to be calcification. Fortunately, the myocarditis and respiratory status recovered by the



**Fig. 1** Electrocardiogram on admission.

The heart rate was 77/minute. An ST-elevation at every lead except leads aVR and V1 can be seen.

## Myocardial calcification due to infection

**Table 1** Laboratory data on admission

Laboratory data on admission	
Complete blood count	
WBC	142,000 / $\mu$ L
RBC	325 $\times$ 10 <sup>4</sup> / $\mu$ L
Hb	10.7 g/dL
Hemetocrit	41.1 %
Neut	91.5 %
Plt	164 $\times$ 10 <sup>4</sup> / $\mu$ L
Coagulation	
PT-INR	1.44
APTT	48.5 sec
Fib	1184 mg/dL
FDP	11.6 $\mu$ g/mL
D-dimer	4.06 $\mu$ g/mL
Biochemistry	
CRP	48.93 mg/dL
TP	5.1 g/dL
Alb	1.4 g/dL
T-Bil	0.5 mg/dL
AST	232 IU/L
ALT	54 IU/L
LDH	538 IU/L
CK	2529 IU/L
CK-MB	196 IU/L
BUN	96 mg/dL
Cre	3.75 mg/dL
high sensitive Troponin T	14.19 ng/mL
Procalcitonin	100< ng/mL
Hb1Ac	5.9 %
Na	129 mEq/L
K	6 mEq/L
Cl	97 mEq/L
Urinalysis	
Protein	10.0 g/gCr
Occult blood	3+
RBC	50–99 /HPF
Cast	(–)

Hb: hemoglobin

PT-INR: *prothrombin time*-international normalized ratio

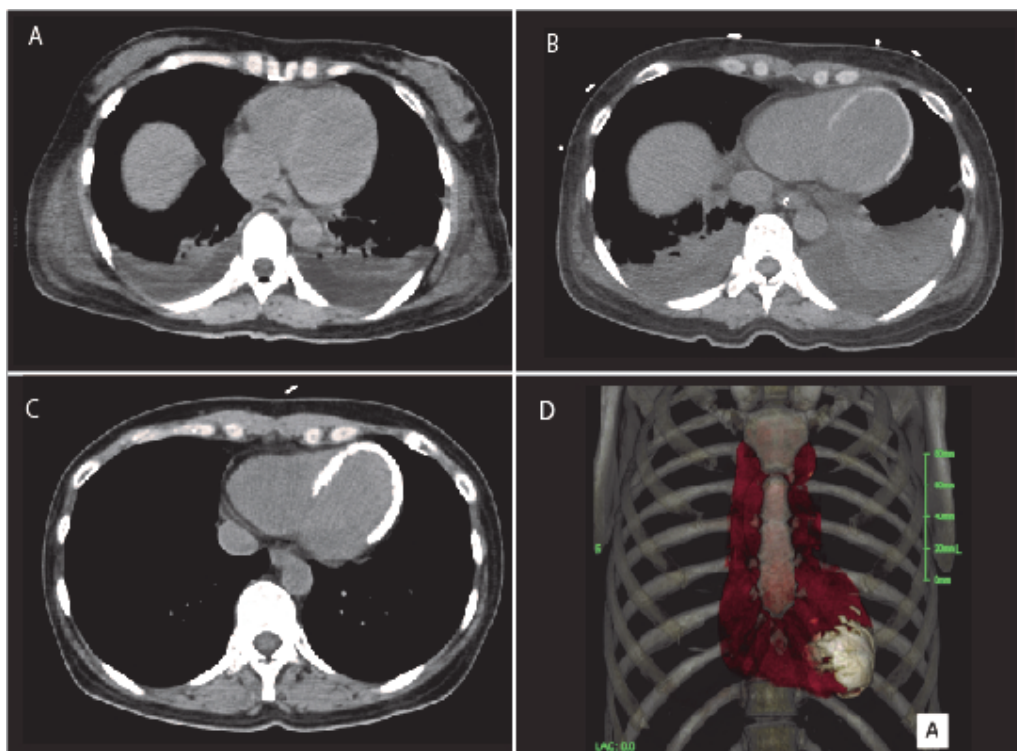
APTT: activated partial thromboplastin time

Fib: fibrinogen

FDP: fibrinogen degradation products

CRP: C-reactive protein

Alb: albumin



**Fig. 2** The series of CT images showing the patient's clinical course

**Fig. 2A:** While a bilateral pleural effusion was detected there were no apparent signs of abnormalities in the heart on admission.

**Fig. 2B:** A slight calcification was identified in the left ventricle on the fifth hospital day.

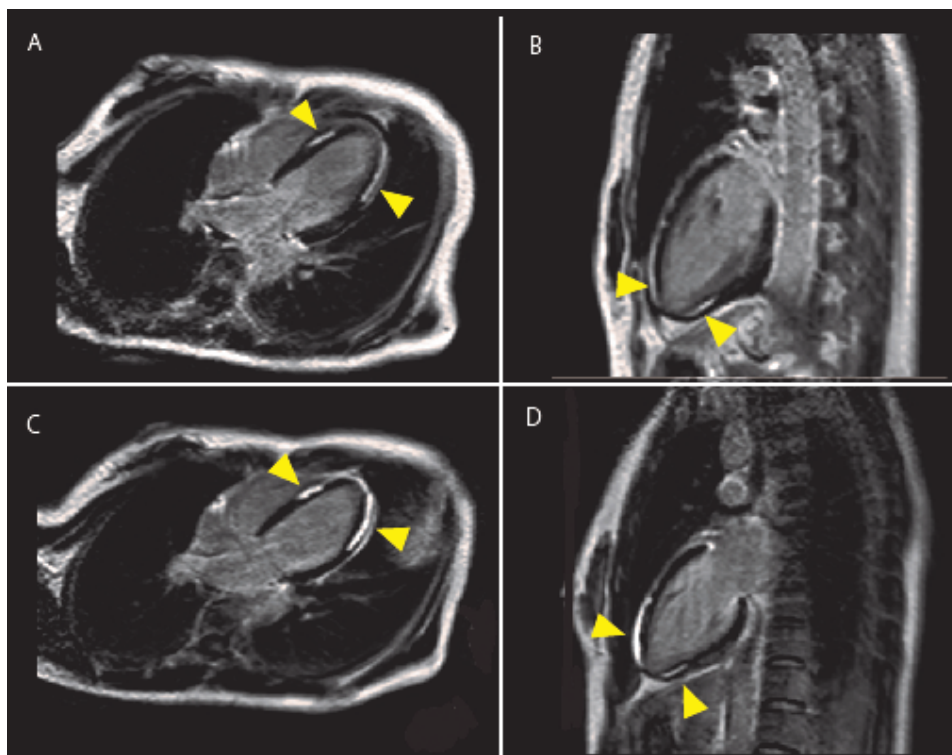
**Fig. 2C:** The range of the calcification spread simultaneously with an increase in density after one month in hospital.

**Fig. 2D:** Calcification at the apex site confirmed by a three dimensional CT image taken after one month in hospital.

10th hospital day. Because her AKI had also improved the patient was able to stop dialytic therapy on the 14th hospital day.

Warfarin was prescribed to prevent intracardiac thrombosis. Remission of MCNS was confirmed a month after admission, leading to careful reduction in the dose of oral prednisolone. Despite cardiac function not having fully recovered (EF46%), we regarded the physical status of the patient as almost stable and accordingly she was discharged on the 38th hospital day.

The patient's cardiac function was followed-up with CT that showed a widespread area of calcification (Figures 2C, 2D) and that cardiac function was still impaired one month after discharge. The EF remained at approximately 46%, although magnetic resonance imaging (MRI) showed wall motion was impaired at the apical segment. Late Gadolinium Enhancement (LEG) revealed delayed images at the mid and apical segments (Figures 3A, 3B). These findings were likely to be consistent with the CT and echocardiography results but may also indicate myofiber fibrosis. Interestingly, the CT images taken one year after discharge were almost similar to the previous images, despite cardiac function showing slight improvement in both the echocardiography and MRI examinations (Figures 3C, 3D). We therefore anticipated that the patient's left



**Fig. 3** A series of contrast-enhanced MRI images of the heart

**Fig. 3A:** The axial image taken one month after the onset of myocarditis.

**Fig. 3B:** The sagittal image taken one month after the onset of myocarditis.

**Fig. 3C:** The axial image taken one year after onset of myocarditis.

**Fig. 3D:** The sagittal image taken one year after onset of myocarditis.

The arrows show delayed enhancement around the area of the interventricular septum and middle part of the apex. The apex wall motion was severely impaired, based on the results of an EF of 46.7% evaluated in the MRI examination. Delayed enhancement areas shown in 3C and 3D are similar to those observed in the earlier images 3A, 3B. Although the EF improved to 60.6%, the wall motion of the apex did not fully recover.

ventricular function would recover gradually, despite the presence of myofiber fibrosis associated with calcification.

## DISCUSSION

It is known that acute myocarditis may be associated with many kinds of virus such as influenza A /B, adenovirus, coxsackieA9/B1/B3/B4/B5/B6, cytomegalovirus, parvovirus B19, HHV-6, and echovirus.<sup>1</sup> While myocardial calcification followed by myocarditis is rare, it is associated with a high risk of mortality.<sup>2</sup> Guy Bower's group has published a review of myocardial calcification secondary to sepsis that described two newborns both with myocardial calcification, and reported that only one in eight cases survived this condition.<sup>3</sup> To our knowledge a large number of case reports on myocardial calcification have discussed these issues at autopsy.<sup>4</sup>

Although myocardial calcification associated with sepsis, as described in this case report, is gradually becoming more recognized, there are no established standard management options for

the disease.<sup>5</sup> We consider that patients who have survived the acute phase of the illness need to be monitored carefully for signs of cardiomyopathy. We also consider that clinicians should be encouraged to undertake research on the detailed pathogenesis, risk factors, clinical implications, and meaningful treatment of myocardial calcification.

Fortunately, the patient in our case report survived as a result of intensive care, enabling us to follow her for a year following onset of the disease. The experiences we encountered may be worthwhile reporting and helpful for other clinicians.

Although a viral infection may cause myocardial calcification, it is possible a bacterial infection with *Klebsiella* or *Pseudomonas aeruginosa* may also be involved. As described in our case report, *Escherichia coli* was certainly the cause of the acute myocarditis<sup>6,7</sup> and therefore myocardial calcification may have also been associated with this bacterial infection. In this regard, the patient would have been susceptible to such infections because of steroid treatment for MCNS.

While there had been four case reports of acute myocarditis secondary to *Escherichia coli* infection, myocardial calcification did not occur as a complication in any of these cases.<sup>8</sup> In general, the process of calcification had been classified as either metastatic or dystrophic.<sup>9</sup> The metastatic pathway can be related to renal insufficiency, secondary hyperparathyroidism, or a disorder of vitamin D metabolism, while the dystrophic pathway is associated with severe cell injury or necrosis. Regardless of the serum calcium concentration, in cases in whom the cellular membrane is damaged, the calcium concentration in cell membrane-bound vesicles may be increased. Integration of these two phenomenon results in induction of calcification.

Nevertheless, myocardial calcification following myocarditis is rare. Rossi<sup>10</sup> reported a possible relationship between factors such as cardiac injury or myocytolysis due to infection and the process of myocardial calcification under experimental conditions. However, the detailed mechanism of this relationship was not determined. It has been suggested that catecholamines may also cause calcification. Based on the findings of echocardiography examinations, we hypothesize that the pathophysiology of myocardial calcification may be as follows. Initially, myofibers in the apical area may become severely damaged due to inflammation. As a result, calcification may be induced at the site, a process known as dystrophic calcification. In addition, metastatic factors such as AKI with MCNS that require steroid therapy may also be associated with the development of calcification. LEG in an MRI is regarded as informative for diagnosing calcification<sup>11,12</sup> as it is a non-invasive examination that provides helpful data in these cases. We confirmed that calcification in our patient developed several days after the onset of myocarditis and therefore our hypothesis regarding the calcification mechanism may be reasonable.

Interestingly, we detected that our patient's cardiac function had recovered gradually during the year following onset of the disease. However, the extent of the calcified area was not different from that observed in the initial phase. Wada<sup>13</sup> has reported previously that improvements in myocardial calcification are possible and therefore it may be expected that this occurred during the clinical course in our patient. We therefore plan to continue to carefully follow her cardiac function using imaging such as echocardiography and CT.<sup>14</sup>

## ACKNOWLEDGEMENTS

None.



## CONFLICTS OF INTERESTS

None.

## REFERENCES

1. Sagar S, Liu PP, Cooper LT. Myocarditis. *Lancet*. 2012;379(9817):738–747.
2. Nance JW, Crane GM, Halushka MK, Fishman EK, Zimmerman SL. Myocardial calcifications: pathophysiology, etiologies, differential diagnoses, and imaging findings. *J Cardiovasc Comput Tomogr*. 2015;9(1):58–67.
3. Bower G, Ashrafi H, Cappelletti S, et al. A proposed role for sepsis in the pathogenesis of myocardial calcification. *Acta Cardiol*. 2017;72(3):249–255.
4. Itoh E, Saitoh H, Miida T, et al. An autopsied case of acute myocarditis with myocardial calcification. *Jpn Circ J*. 1997;61(9):798–802.
5. Ahmed T, Inayat F, Haq M, Ahmed T. Myocardial calcification secondary to toxic shock syndrome: a comparative review of 17 cases. *BMJ Case Rep*. 2019;12(1):bcr-2018-228054.
6. Chen TC, Lu PL, Lin CY, Lin WR, Chen YH. Escherichia coli urosepsis complicated with myocarditis mimicking acute myocardial infarction. *Am J Med Sci*. 2010;340(4):332–334.
7. Komuro J, Ueda K, Kaneko M, Nitta S, Kasao M, Yokoyama M. Various Cardiac Abnormalities Caused by Bacterial Myocarditis. *Int Heart J*. 2018;59(1):229–232.
8. Gentile G, Meles E, Carbone C, Gantú E, Maggiolini S. Unusual case of myocardial injury induced by Escherichia coli sepsis. *Monaldi Arch Chest Dis*. 2010;74(1):40–43.
9. Elsherif L, Huang MS, Shai SY, et al. Combined deficiency of dystrophin and beta1 integrin in the cardiac myocyte causes myocardial dysfunction, fibrosis and calcification. *Circ Res*. 2008;102(9):1109–1117.
10. Rossi MA, Santos CS. Sepsis-related microvascular myocardial damage with giant cell inflammation and calcification. *Virchows Arch*. 2003;443(1):87–92.
11. Grigoratos C, Di Bella G, Aquaro GD. Diagnostic and prognostic role of cardiac magnetic resonance in acute myocarditis. *Heart Fail Rev*. 2019; 24(1):81–90.
12. Luetkens JA, Petry P, Kuetting D, et al. Left and right ventricular strain in the course of acute myocarditis: a cardiovascular magnetic resonance study. *Rofo*. 2018;190(8):722–732.
13. Wada A, Nakata T, Tsuchihashi K, et al. Massive myocardial calcification of right and left ventricles following acute myocarditis complicated with rhabdomyolysis-induced acute renal failure. *Jpn Circ J*. 1993;57(6):567–572.
14. Simonson S, Miller WT, Perl A, Torigian DA. Diffuse left ventricular myocardial calcification in the setting of sepsis on CT imaging. *J Thorac Imaging*. 2007;22(4):343–345.