

Antithyroid Arthritis Syndrome: A Case Report and Review of the Literature

Kazuhiko Takaya, Natsumi Kimura and Toru Hiyoshi

Abstract

We herein report the case of a 38-year-old Japanese woman with antithyroid arthritis syndrome who experienced severe migratory polyarthritis after the initiation of thiamazole therapy. The patient's symptoms promptly disappeared without any sequelae after the withdrawal of the drug. Antithyroid arthritis syndrome is poorly characterized, and the findings from our literature review indicate that this syndrome exhibits serological features that are distinct from those of antithyroid agent-induced vasculitis syndrome. The absence of autoantibodies, especially anti-neutrophil cytoplasmic antibodies, may help characterize and diagnose antithyroid arthritis syndrome. Furthermore, physicians' awareness of this syndrome is essential for its diagnosis in clinical practice.

Key words: Graves' disease, thiamazole, antithyroid, arthritis, ANCA

(Intern Med 55: 3627-3633, 2016)

(DOI: 10.2169/internalmedicine.55.7379)

Introduction

Graves' disease (GD) is a common autoimmune disease, and oral antithyroid agents remain the first line of treatment in Japan and European countries (1-3), although radioactive iodine is currently the primary treatment in the US. Among the available antithyroid agents, thiamazole (MMI) is the most widely used agent in Japan. Although MMI has a better safety profile than propylthiouracil (PTU) (4), the adverse effects of MMI range from mild events (e.g., skin eruptions) to life-threatening events (e.g., agranulocytosis and severe hepatitis). Musculoskeletal complaints are not rare among patients with thyroid disorders and are also described as adverse effects of antithyroid drugs (5). Furthermore, vasculitis can manifest as arthritis and has been described since the 1950s as a major toxic reaction to antithyroid agents (6), and attention is currently focused on anti-neutrophil cytoplasmic antibody (ANCA)-associated vasculitis (AAV) syndrome. However, the focus on this syndrome has obscured the fact that non-vasculitis arthritis can also be induced by antithyroid drugs, defined as antithyroid arthritis syndrome (5). Thus, there are few detailed reports regarding antithyroid arthritis syndrome, especially in the context of

differentiating it from antithyroid agent-induced vasculitis.

We report the case of a 38-year-old Japanese woman who experienced severe migratory polyarthritis after receiving MMI. We excluded the possibility of reactive arthritis and MMI-induced vasculitis syndrome and observed that the patient's symptoms promptly resolved after withdrawing the MMI treatment. This case and the accompanying literature review highlight the importance of antithyroid arthritis syndrome when diagnosing patients who develop arthritis after receiving antithyroid agents.

Case Report

A 38-year-old Japanese woman was referred to our hospital with symptoms of a goiter. She had previously been healthy, with no history of delivery, allergies, or joint symptoms. There was no family history of thyroid or collagen diseases. A physical examination revealed that the patient was afebrile, had a blood pressure of 140/71 mmHg, and had a pulse rate of 99 beats/min with regular rhythm. Her height was 160 cm, and her weight was 54.4 kg. We observed that her thyroid gland was diffusely enlarged and that she exhibited fine hand tremors, although an examination using an exophthalmometer did not reveal exophthalmos.

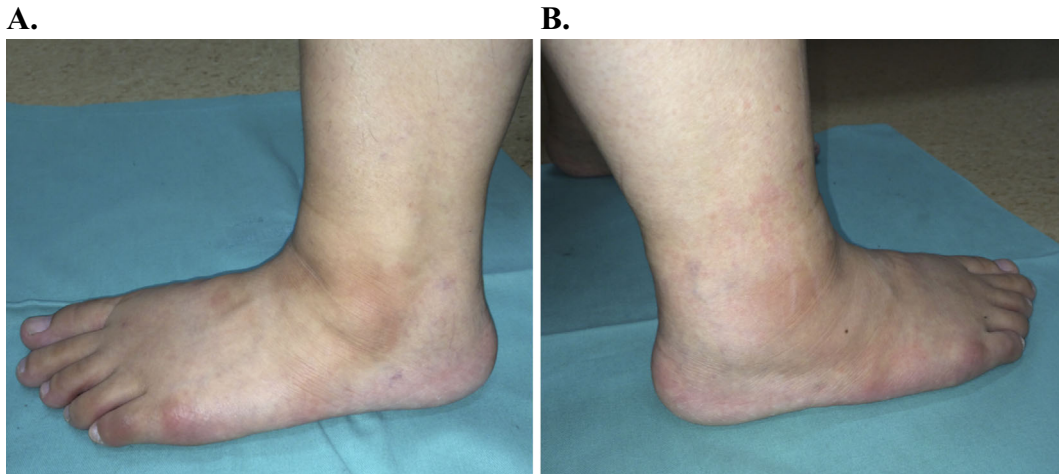


Figure 1. The patient's left foot (A) and right foot (B).

The laboratory results included hemoglobin levels of 12.0 g/dL, a total white blood cell count of 3,800/ μ L, and a platelet count of 29.3×10^3 / μ L. There was no proteinuria or hematuria, and her levels of C-reactive protein (CRP), aspartate aminotransferase, and alanine aminotransferase were within the normal ranges. However, her alkaline phosphatase levels were slightly elevated (479 U/L), and we found markedly elevated levels of free serum thyroxine (FT₄; 9.44 ng/dL) and free triiodothyronine (FT₃; >30 pg/mL). The patient's thyroid stimulating hormone (TSH) levels were suppressed (0.02 μ IU/mL), and a third-generation TSH receptor antibody test revealed positive results (190 IU/L). We also observed positive results for antithyroid peroxidase antibody (493 IU/mL) and antithyroglobulin antibody (73 IU/mL). Homogenous and diffuse uptake was observed in both lobes using thyroid scintigraphy with ^{99m}Tc pertechnetate. Based on these findings, we diagnosed the patient with GD and started treatment using MMI at a dose of 45 mg/day. We also added potassium iodide (50 mg/day) and propranolol hydrochloride (30 mg/day) because of the severe hyperthyroidism and tachycardia.

Three weeks later, the patient presented with a fever and arthralgia, particularly in the right ankle, which prevented her from walking. Five days prior, she had experienced spontaneous progressive arthralgia that started in the metacarpophalangeal joint of her right thumb and then migrated to the left thumb, thoracic vertebrae, and right ankle. The pain in the affected joints worsened each day and eventually became intolerable. She also complained of a low-grade fever at night (37.5-37.9°C), and a physical examination revealed that her right lateral malleolus was mildly swollen, slightly flushed, warm, and remarkably tender (Fig. 1). It also revealed a tender right Achilles' tendon and middle thoracic vertebrae, and tender and slightly swollen carpometacarpal and metacarpophalangeal joints in both thumbs. The right ankle's motion was limited by the severe pain, although there were no signs of skin eruptions, facial erythema, or photosensitivity, Raynaud's phenomenon, suggesting lupus-like syndrome. The patient's superficial lymph

nodes were not palpable, and she did not have an enlarged liver or spleen.

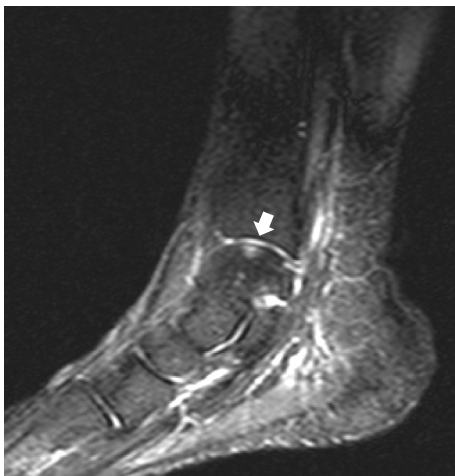
At that time, laboratory testing (Table 1) revealed an elevated erythrocyte sedimentation rate, CRP levels, and IL-6 levels, which indicated moderate inflammation. The serum levels of FT₃, FT₄, and TSH were 10.7 pg/mL, 3.18 ng/dL, and 0.02 μ IU/mL, respectively, which indicated an improved thyroid function. We performed an orthopedic examination, although foot radiography revealed no specific findings. Magnetic resonance imaging of the right ankle also revealed no abnormalities, with the exception of a non-specific signal at the talus (Fig. 2).

Although she did not have any diarrheal symptoms that indicated enterocolitis, a stool culture was performed to identify any bacteria that might have caused reactive arthritis. The results were negative for *Yersenia*, *Salmonella*, *Shigella*, and *Campylobacter* species. Based on her age, we also considered that she might have reactive arthritis that was secondary to *Neisseria* or *Chlamydia* infection, although transcription-mediated amplification tests revealed negative results for *Chlamydia trachomatis* and *Neisseria gonorrhoeae*. We did not detect any antibodies to *Mycoplasma* (using the complement fixation and passive agglutination tests), and there was no increase in the paired sera titers after two weeks. Therefore, we considered that the patient had reactive arthritis that was secondary to a viral infection, although we did not detect hepatitis virus antigens or antibodies. The titers of human parvovirus B19-specific IgG were high, although the IgM titers were within the normal range, and neither antibody exhibited any increase in the paired sera titers after two weeks.

Next, we considered the possibility of autoimmune diseases or antithyroid drug-induced AAV. However, we did not detect any autoantibodies, including myeloperoxidase (MPO)-ANCA and proteinase 3 (PR3)-ANCA. We therefore excluded idiopathic collagen diseases and drug-induced AAV. We performed drug lymphocyte stimulation tests (DSLSTs) with ³H-thymidine incorporation and found that the stimulation index for MMI was high (26.9, positive: >1.8).

Table 1. Laboratory Findings at the Presentation with Arthritis.

Urinalysis		Serological tests	
Protein	(-)	IgG	1,073 mg/dL
Blood	(-)	IgA	424 mg/dL
Complete Blood Count		IgM	74 mg/dL
ESR	62 mm/hr	IgE	101 IU/mL
Peripheral blood		IgD	1.5 mg/dL
WBC	7,200/ μ L	CH ₅₀	85 U/mL
Segmented	64.5%	RF	3 U/mL
Stab	7.5%	Anti-CCP antibody	< 0.06 U/mL
Lymph	19.5%	MPO-ANCA	< 1.0 EU
Bas	0.0%	PR3-ANCA	< 1.0 EU
Eo	0.0%	ANA	< \times 40
Mon	8.5%	LE test	(-)
RBC	448 \times 10 ⁴ / μ L	Anti-DNA antibody	< 2.0 IU/mL
Hemoglobin	11.9 g/dL	Anti-Sm antibody	< 0.5 U/mL
Platelet	30.8 \times 10 ⁴ / μ L	Anti-U1RNP antibody	< 0.5 U/mL
Blood Chemistry and Hormones		Anti-SCL-70 antibody	(-)
Total protein	6.9 g/dL	Anti-Jo-1 antibody	(-)
Albumin	4.2 g/dL	Anti-cardiolipin antibody	< 8 U/mL
AST	12 IU/L	Anti-GAD antibody	< 0.3 U/mL
ALT	11 IU/L	ASLO	203 IU/mL
ALP	581 IU/L	Stool Culture	
LDH	160 IU/L	<i>Yersenia</i>	(-)
CK	31 U/L	<i>Salmonella</i>	(-)
Postprandial glucose	126 mg/dL	<i>Shigella</i>	(-)
BUN	8 mg/dL	<i>Campylobacter</i>	(-)
Creatinine	0.31 mg/dL	Urine Tests for Microorganisms	
Na	139 mEq/L	<i>C. trachomatis</i>	(-)
K	4.1 mEq/L	<i>N. gonorrhoea</i>	(-)
Cl	105 mEq/L	Mycoplasma antibodies	
CRP	2.33 mg/dL	Viral Tests	
IL-6	13 pg/mL	HBs antigen	0.1 COI
TSH	0.02 μ IU/mL	HCV antibody	0.1 COI
FT ₄	3.18 ng/dL	HA antibody (EIA)	0.28 S/CO
FT ₃	10.7 pg/mL	IgM-HA antibody	0.10 S/CO
Coagulation Study		Parvovirus B19 antibody	
PT	94%	IgG (reference: <0.80)	3.23
APTT	30.2 sec	IgM (reference: <0.80)	0.26
Fibrinogen	314 mg/dL		

**Figure 2. Magnetic resonance imaging of the right foot (short tau inversion recovery-T1). The arrow indicates a non-specific signal at the talus.**

Therefore, as we suspected an adverse reaction to the MMI treatment, we substituted PTU treatment at 450 mg/day. The same dosages of propranolol hydrochloride and potassium

iodide were continued, and loxoprofen sodium hydrate was started for the arthralgia.

The patient's symptoms promptly resolved the same day after withdrawing the MMI and starting loxoprofen. In addition, the pain and swelling in the affected joints disappeared after one week (except for in the right ankle), and we stopped treating the patient using loxoprofen sodium hydrate. A follow-up evaluation at two weeks after discontinuing the MMI revealed that the right ankle appeared normal, with the full range of motion restored and no swelling, redness, or pain. We also observed that the inflammatory indexes were almost normalized (CRP: 0.17 mg/dL, IL-6: 6 pg/mL). At that time, her FT₃, FT₄, and TSH levels were 7.7 pg/mL, 2.56 ng/dL, and 0.02 μ IU/mL, respectively; thus, we continued the PTU and tapered and stopped the potassium iodide. Follow-up magnetic resonance imaging at three months revealed no significant changes, although the signal at the right talus persisted, despite the improvement in the patient's symptoms. We therefore deemed that this signal was not clinically significant. The patient has continued to receive PTU for >1 year and has a normalized thyroid status, with no recurrent joint symptoms or toxic reactions

Table 2. Reports Regarding Antithyroid Drug-induced Lupus-like Syndrome that Examined Anti-neutrophil Cytoplasmic Antibodies.

Reference	ATD	MPO (p) -ANCA	PR3 (c) -ANCA	ANA	Anti-dsDNA antibody	Joint symptoms
(33)	PTU		(+)*	(+)		
(34)	PTU		(+)*	(+)		(+)
(35)	MMI	(+)		(+)	(+)	
(36)	PTU	(+)	(±)	(+)	(+)	(+)
(17)	PTU	(+)	(-)	(+)	(+)	(+)
(37)	MMI	(+)	(-)	(+)	(+)	
(38)	MMI	(+)	(-)	(+)	(+)	(-)
(18)	PTU	(+)	(-)	(+)		(+)
	PTU	(+)	(-)	(+)	(-)	(+)
	PTU	(+)		(+)		(+)
(13)	PTU	(+)	(-)	(+)	(+)	(+)
	PTU	(+)	(-)	(+)	(-)	(+)
	PTU	(+)	(-)	(+)	(-)	(+)
	PTU	(+)	(-)	(+)	(-)	(+)
(39)	PTU	(+)	(+)	(+)	(-)	(+)
(40)	MMI		(+)*	(+)	(+)	(+)
(41)	CBZ	(+)	(-)	(+)	(+)	
(42)	PTU	(+)	(+)	(+)	(+)	(+)

ATD: antithyroid drug, PTU: propylthiouracil, MMI: thiamazole, CBZ: carbimazole,
*: ANCA subtypes not known. Blank line indicates "not described"

experienced during the follow-up period.

Discussion

Musculoskeletal complaints are not rare in cases of thyroid disorders and are often unnoticed or unremarked. In the present case, we considered the episode of multi-joint pain to be polyarthritis, rather than arthralgia, because of the objective joint swelling and elevated values of inflammation markers (e.g., CRP and IL-6), which indicated the existence of synovitis. In this context, arthritis may occur in association with a wide variety of diseases, and bacterial or viral infections can cause either acute or chronic arthritis (7). However, the patient in the present case did not exhibit any symptoms that suggested infection, and the test results were negative for various infectious diseases and antibody titers. Autoimmune diseases should also be included in the differential diagnosis of arthritis, although our laboratory test results were negative for autoimmune diseases. Given that the arthritis in the present case developed shortly after the patient started receiving MMI, and the symptoms resolved shortly after discontinuing this drug, we concluded that the symptoms were induced by the MMI treatment (8).

Vasculitis is a major toxic reaction that is induced by antithyroid treatment, and this condition may manifest as arthritis (5). Drug-induced vasculitis is commonly associated with ANCA-positivity (9, 10), especially in patients who have received antithyroid agents (11), although the exact positivity rate is unclear, because the diagnostic criteria for

drug-induced vasculitis include ANCA-positivity in many reports (12, 13). Pillinger et al. described 23 cases of PTU-related vasculitis (14) and found positive results for ANCA in all 20 cases that underwent ANCA testing. The first case was reported in 1992 (15), and >100 cases of antithyroid agent-induced AAV have currently been reported (11); these cases are especially common among Asian patients treated using PTU (16). The spectrum of its manifestations is broad and ranges from non-specific syndromes to single-organ involvement and life-threatening vasculitis, with arthralgia and arthritis being among the most frequent symptoms at the onset of AAV (11). Most patients have perinuclear (p)-ANCA, with a majority of these patients having MPO-ANCA (5).

Drug-induced lupus can also manifest as arthritis, and clinical and serological results that are consistent with lupus erythematosus have been observed in some patients who were treated using antithyroid agents (17). Interestingly, many researchers insist that it is irrelevant to distinguish between antithyroid agent-induced lupus-like syndrome and AAV (11), although other researchers make a clear distinction between these conditions (18). Furthermore, Yamada et al. described 22 cases of PTU-induced lupus-like syndrome from before 2001 (including their ANCA-positive case) (17). Table 2 shows the results of a literature review regarding ANCA and antithyroid agent-induced lupus-like syndrome, which has been reported in association with all kinds of anti-thyroid agents that are currently in use. All 18 cases that were examined for ANCA had positive results, especially for MPO-ANCA or p-ANCA. This result appears to

Table 3. Literature Review of Antithyroid Arthritis Syndrome.

Reference	Age /sex	Drug	Latency	Fever	Skin Eruption	CRP (mg/dL)	ESR (mm/hr)	WBC (/ μ L)	MPO (P) -ANCA	PR3 (C) -ANCA	ANA
(25)	30/F	PTU	10 dy	(+)	(+)			3,800			
(6)	50/M	MMI	5.5 wk	(+)	(-)		40	13,000			
	25/F	MMI	4 mo	(+)	(+)			3,600			
	45/F	MMI	1 mo		(+)			10,000			
	31/F	MMI	4 wk	(+)	(+)		30	7,200			
(43)	26/F	MMI	15 dy	(+)		(3+)	54	10,000			(-)
(44)	28/F	MMI	3 wk	(+)	(+)	WNR	23	10,500			(-)
	63/F	MMI	2 wk				37	6,400			
	47/F	PTU	3 wk	(+)			48	4,500			
(30)	12/F	PTU/MMI	18 mo		(+)		30	WNR			(+)
	11/F	PTU/MMI	22 mo		(+)	WNR	39	WNR			(+)
(28)	25/F	MMI/PTU	7 wk								
(45)	42/F	MMI	4 wk	(+)	(-)	WNR	WNR	WNR			(-)
(26)	45/F	PTU	>10 yr	(+)		elevated	WNR	WNR			(-)
(29)	37/F	MMI	1 wk	(-)	(-)						(+)
(46)	69/F	MMI	5 wk				60	11,600			(-)
(47)	50/M	CBZ	1 wk	(+)	(+)	18.7	48	WNR			
(48)	15/F	MMI	3 wk	(-)	(+)	12		8,600	(-)	(-)	(+)
(49)	15/F	MMI	24 dy	(+)	(+)	3.41		8,600	(-)	(-)	
	11/F	MMI	28 dy	(+)	(+)	2.41	64	6,800	(-)		(+)
(27)	40/F	MMI	2-3 mo			WNR	WNR		(-)	(-)	(+)
(50)	13/F	MMI	2 wk	(-)	(+)	21			(-)	(-)	(-)
Present Study	38/F	MMI	2 wk	(+)	(-)	2.33	62	7,200	(-)	(-)	(-)

PTU: propylthiouracil, MMI: thiamazole, CBZ: carbimazole, WNR: within normal range. Blank line indicates "not described"

support the previous findings that drug-induced lupus has serological features that are different from those of idiopathic systemic lupus erythematosus (only 15-20% of the patients are ANCA-positive) (19) and that anti-thyroid agent-induced lupus-like syndrome cannot be clearly distinguished from AAV (20). Furthermore, specific types of antithyroid agent-induced AAV have been reported, such as Wegener's granulomatosis (14), Henoch-Schönlein purpura (21), Churg-Strauss syndrome (22), and bilateral sensorineural hearing loss (23). Thus, it has been hypothesized that antithyroid drugs, especially PTU, can react with MPO and form reactive intermediates that promote autoimmune inflammation (24).

Based on the absence of ANCAs and most vasculitis symptoms (e.g., nephritis, skin lesions, and systemic symptoms), the present case appears to be antithyroid arthritis syndrome, rather than vasculitis or lupus-like syndrome as mentioned above. Antithyroid arthritis syndrome has been recognized for longer than 60 years and was initially described as a rare toxic reaction to antithyroid agents. Williams et al. described three cases of PTU-associated arthritis in 1946, and one of those cases could be considered antithyroid arthritis syndrome (25). Although this syndrome typically develops as a minor reaction to antithyroid agents, erythema and swelling of the joints may be present (as in the current case) and may indicate a more severe migratory polyarthritis (5). The arthralgia is continuously progressive, although it can occasionally be intermittent over a prolonged course (e.g., 10 years) (26). However, antithyroid arthritis syndrome has been poorly characterized and is underappre-

ciated (27), especially regarding its discrimination from vasculitis-related arthritis.

Table 3 shows the findings from a literature review of the reports regarding this syndrome, which predominantly affects female patients, reflects the epidemiology of GD, occurs within 1 month after starting the antithyroid agent, and exhibits inflammatory signs, such as fever, leukocytosis, and elevated CRP levels. However, many of these reports, especially the older reports, lack information regarding ANCA status. Nevertheless, ANCAs were confirmed to be absent in the six latest reports (including the present case), which indicate that antithyroid arthritis syndrome has serological characteristics (e.g., negative for ANCAs) that are different from those of antithyroid agent-induced vasculitis and lupus-like syndrome.

Antithyroid arthritis syndrome usually resolves without any sequelae within several weeks after the cessation of the causative drug (28), and steroids have occasionally been administered without any evidence of efficacy (29). Alternative antithyroid agents can occasionally be used without symptom recurrence (as in the present case), although cross-reactivity has also been reported (28, 30). Little is known regarding the mechanism of this syndrome, although some researchers insist that the complex of copper and the antithyroid agent affects glutathione metabolism and induces the release of interleukins, which can cause synovial inflammation (31). Alternatively, other researchers claim that the binding of the antithyroid agent to macromolecules can induce auto-antibody production, despite the absence of evidence for autoantibody production in this syndrome (32).

Nevertheless, an allergic mechanism may be involved, based on the strongly positive DSLT results for MMI in the present case. Therefore, further studies are needed to evaluate the mechanism of this syndrome.

In conclusion, the present case highlights the importance of recognizing antithyroid arthritis syndrome as an adverse effect of antithyroid agents, which can result in severe migratory polyarthritis. Given the unpredictable and potentially life-threatening vasculitis that can be caused by antithyroid agents, it is essential for clinicians to be aware of this condition and to promptly withdraw the causative agent in similar cases. The symptoms, onset form, and presence or absence of autoantibodies may be helpful for distinguishing between antithyroid arthritis syndrome and vasculitis, and negative results for ANCA may help define this syndrome.

The authors state that they have no Conflict of Interest (COI).

References

- Burch HB, Burman KD, Cooper DS. A 2011 survey of clinical practice patterns in the management of Graves' disease. *J Clin Endocrinol Metab* **97**: 4549-4558, 2012.
- Bahn RS, Burch HB, Cooper DS, et al. Hyperthyroidism and other causes of thyrotoxicosis: management guidelines of the American Thyroid Association and American Association of Clinical Endocrinologists. *Endocr Pract* **17**: 456-520, 2011.
- Yamashita S, Amino N, Shong YK. The American Thyroid Association and American Association of Clinical Endocrinologists hyperthyroidism and other causes of thyrotoxicosis guidelines: viewpoints from Japan and Korea. *Thyroid* **21**: 577-580, 2011.
- Nakamura H, Noh JY, Itoh K, Fukata S, Miyauchi A, Hamada N. Comparison of methimazole and propylthiouracil in patients with hyperthyroidism caused by Graves' disease. *J Clin Endocrinol Metab* **92**: 2157-2162, 2007.
- Cooper DS. Antithyroid drugs. *N Engl J Med* **352**: 905-917, 2005.
- Fraser TR, Garrod O, Hanno MG, Jadresic A. Antithyroid activity and toxicity of mercazole and neo-mercazole. *J Clin Endocrinol Metab* **14**: 1230-1244, 1954.
- Mathew AJ, Ravindran V. Infections and arthritis. *Best Pract Res Clin Rheumatol* **28**: 935-959, 2014.
- Naranjo CA, Busto U, Sellers EM, et al. A method for estimating the probability of adverse drug reactions. *Clin Pharmacol Ther* **30**: 239-245, 1981.
- Cambridge G, Wallace H, Bernstein RM, Leaker B. Autoantibodies to myeloperoxidase in idiopathic and drug-induced systemic lupus erythematosus and vasculitis. *Br J Rheumatol* **33**: 109-114, 1994.
- Wiik A. Drug-induced vasculitis. *Curr Opin Rheumatol* **20**: 35-39, 2008.
- Chen M, Gao Y, Guo XH, Zhao MH. Propylthiouracil-induced antineutrophil cytoplasmic antibody-associated vasculitis. *Nat Rev Nephrol* **8**: 476-483, 2012.
- Cao X, Lin W. Clinical study of renal impairment in patients with propylthiouracil-induced small-vessel vasculitis and patients with primary ANCA-associated small-vessel vasculitis. *Exp Ther Med* **5**: 1619-1622, 2013.
- Wu R, Li R. Propylthiouracil-induced autoimmune syndromes: 11 case report. *Rheumatol Int* **32**: 679-681, 2012.
- Pillinger M, Staud R. Wegener's granulomatosis in a patient receiving propylthiouracil for Graves' disease. *Semin Arthritis Rheum* **28**: 124-129, 1998.
- Stankus SJ, Johnson NT. Propylthiouracil-induced hypersensitivity vasculitis presenting as respiratory failure. *Chest* **102**: 1595-1596, 1992.
- Gunton JE, Stiel J, Cateson RJ, McElduff A. Clinical case seminar: anti-thyroid drugs and antineutrophil cytoplasmic antibody positive vasculitis. A case report and review of the literature. *J Clin Endocrinol Metab* **84**: 13-16, 1999.
- Yamada A, Sato K, Hara M, et al. Propylthiouracil-induced lupus-like syndrome developing in a Graves' patient with a sibling with systemic lupus erythematosus. *Intern Med* **41**: 1204-1208, 2002.
- Aloush V, Litinsky I, Caspi D, Elkayam O. Propylthiouracil-induced autoimmune syndromes: two distinct clinical presentations with different course and management. *Semin Arthritis Rheum* **36**: 4-9, 2006.
- Sen D, Isenberg DA. Antineutrophil cytoplasmic autoantibodies in systemic lupus erythematosus. *Lupus* **12**: 651-658, 2003.
- Araujo-Fernandez S, Ahijon-Lana M, Isenberg DA. Drug-induced lupus: including anti-tumour necrosis factor and interferon induced. *Lupus* **23**: 545-553, 2014.
- Ohta K, Shimizu M, Yokoyama T, et al. Analysis of MPO-ANCA subtypes in a patient with propylthiouracil-induced vasculitis with multiple complications. *Clin Nephrol* **68**: 315-321, 2007.
- Quax RA, Swaak AJ, Baggen MG. Churg-Strauss syndrome following PTU treatment. *Int J Rheumatol* **2009**: 504105, 2009.
- Sano M, Kitahara N, Kunikata R. Progressive bilateral sensorineural hearing loss induced by an antithyroid drug. *ORL J Otorhinolaryngol Relat Spec* **66**: 281-285, 2004.
- Helfgott SM, Smith RN. Case records of the Massachusetts General Hospital. Weekly clinicopathological exercises. Case 21-2002. A 21-year-old man with arthritis during treatment for hyperthyroidism. *N Engl J Med* **347**: 122-130, 2002.
- Williams RH, Clute HW, Anglem TJ, Kenney FR. Thiouracil treatment of thyrotoxicosis; toxic reactions. *J Clin Endocrinol Metab* **6**: 23-51, 1946.
- Tosun M, Guler M, Erem C, Uslu T, Miskioglu E. Intermittent polyarthritis due to propylthiouracil. *Clin Rheumatol* **14**: 574-575, 1995.
- Gruber CN, Finzel K, Gruber BL. A case of methimazole-induced chronic arthritis masquerading as seronegative rheumatoid arthritis. *J Clin Rheumatol* **20**: 229-232, 2014.
- Shabtai R, Shapiro MS, Orenstein D, Taragan R, Shenkman L. The antithyroid arthritis syndrome reviewed. *Arthritis Rheum* **27**: 227-229, 1984.
- Moreno MJ, Marras C, Linares LF, Martinez-Ferrin J, Moreno Ramos MJ. Polyarthritis in association with antithyroid therapy. *J Clin Rheumatol* **3**: 182-183, 1997.
- Hung W, August GP. A "collagen-like" syndrome associated with antithyroid therapy. *J Pediatr* **82**: 852-854, 1973.
- Rafter GW. Methimazole and arthritis. *Scand J Rheumatol* **19**: 385, 1990.
- Wing SS, Fantus IG. Adverse immunologic effects of antithyroid drugs. *CMAJ* **136**: 121-127, 1987.
- Berkman EM, Orlin JB, Wolfsdorf J. An anti-neutrophil antibody associated with a propylthiouracil-induced lupus-like syndrome. *Transfusion* **23**: 135-138, 1983.
- Sato K, Miyakawa M, Han DC, et al. Graves' disease with neutropenia and marked splenomegaly: autoimmune neutropenia due to propylthiouracil. *J Endocrinol Invest* **8**: 551-555, 1985.
- Kawachi Y, Nukaga H, Hoshino M, Iwata M, Otsuka F. ANCA-associated vasculitis and lupus-like syndrome caused by methimazole. *Clin Exp Dermatol* **20**: 345-347, 1995.
- Noh JY, Asari T, Hamada N, et al. Frequency of appearance of myeloperoxidase-antineutrophil cytoplasmic antibody (MPO-ANCA) in Graves' disease patients treated with propylthiouracil and the relationship between MPO-ANCA and clinical manifestations. *Clin Endocrinol (Oxf)* **54**: 651-654, 2001.

37. Thong HY, Chu CY, Chiu HC. Methimazole-induced antineutrophil cytoplasmic antibody (ANCA)-associated vasculitis and lupus-like syndrome with a cutaneous feature of vesiculo-bullous systemic lupus erythematosus. *Acta Derm Venereol* **82**: 206-208, 2002.
38. Wang LC, Tsai WY, Yang YH, Chiang BL. Methimazole-induced lupus erythematosus: a case report. *J Microbiol Immunol Infect* **36**: 278-281, 2003.
39. Tetikkurt C, Yuruyen M, Tetikkurt S, Bayar N, Ozdemir I. Propylthiouracil-induced lupus-like or vasculitis syndrome. *Multidiscip Respir Med* **7**: 14, 2012.
40. Seo JY, Byun HJ, Cho KH, Lee EB. Methimazole-induced bullous systemic lupus erythematosus: a case report. *J Korean Med Sci* **27**: 818-821, 2012.
41. Haq I, Sosin MD, Wharton S, Gupta A. Carbimazole-induced lupus. *BMJ Case Rep* **2013**: published online 7 Feb, 2013.
42. Taguchi T, Nakayama S, Fujimoto S, Terada Y. Lupus nephritis with positive myeloperoxidase/proteinase 3-antineutrophil cytoplasmic autoantibody that developed after 17 years of propylthiouracil therapy. *Endocrine* **46**: 357-359, 2014.
43. Kurtz MD. Migratory polyarthritis occurring with methimazole therapy. *N Y State J Med* **68**: 2810-2811, 1968.
44. Farbman K, Wheeler MF, Glick SM. Arthritis induced by antithyroid medication. *N Y State J Med* **69**: 826-831, 1969.
45. Hietarinta M, Merilahti-Palo R. Methimazole-induced arthritis. *Scand J Rheumatol* **18**: 61-62, 1989.
46. Bajaj S, Bell MJ, Shumak S, Briones-Urbina R. Antithyroid arthritis syndrome. *J Rheumatol* **25**: 1235-1239, 1998.
47. Richards AJ. Antithyroid arthritis syndrome: a case induced by carbimazole. *J Rheumatol* **26**: 1851, 1999.
48. Ploegstra WM, Boontje RP, Kamps AW. Arthritis associated with antithyroid therapy in a 15-year-old girl. *J Pediatr Pharmacol Ther* **16**: 98-101, 2011.
49. Nihei H, Tada H, Naruse Y, et al. Polyarthritis caused by methimazole in two Japanese patients with Graves' disease. *J Clin Res Pediatr Endocrinol* **5**: 270-272, 2013.
50. Janson JA, de Laat P, Draaisma JM. Migratory polyarthritis as an adverse effect of thiamazole use in a 13-year-old girl with Graves' disease. *J Pediatr Endocrinol Metab* **28**: 1169-1171, 2015.

The Internal Medicine is an Open Access article distributed under the Creative Commons Attribution-NonCommercial-NoDerivatives 4.0 International License. To view the details of this license, please visit (<https://creativecommons.org/licenses/by-nc-nd/4.0/>).