

# Advances on Capsular Contracture—Prevention and Management Strategies: A Narrative Review of the Literature

Pietro Susini, MD  
Giuseppe Nisi, MD  
Diletta Maria Pierazzi, MD  
Francesco Ruben Giardino, MD  
Mirco Pozzi, MD  
Luca Grimaldi, MD  
Roberto Cuomo, MD

**Background:** Capsular contracture (CC) is the most relevant complication of both aesthetic and reconstructive breast implant surgery. For many years, experimental and clinical trials have attempted to analyze CC risk factors, clinical features, and appropriate management strategies. It is commonly accepted that a multifactorial etiology promotes CC development. However, the heterogeneity in patients, implants and surgical techniques make it difficult to suitably compare or analyze specific factors. As a consequence, discordant data are present in literature, and a true systematic review is often limited in its conclusions. Hence, we decided to present a comprehensive review of current theories on prevention and management strategies, rather than a specific “solution” to this complication.

**Methods:** The PubMed database was searched for literature regarding CC prevention and management strategies. Pertinent articles in English, published before December 1, 2022, were compared with selection criteria and eventually included in this review.

**Results:** Through the initial search, 97 articles were identified, of which 38 were included in the final study. Several articles explored different medical and surgical preventive and therapeutic strategies, showing numerous controversies on appropriate CC management.

**Conclusions:** This review provides a clear overview of the complexity of CC. The wide variety of clinical situations in term of patients, implants, and surgical techniques prevent the standardization of CC management strategies. By contrast, a patient-customized approach should be preferred, and different strategies should be considered depending on the specific case. Further research is desirable to better ascertain evidence-based protocols with regard to CC prevention and treatment. (*Plast Reconstr Surg Glob Open* 2023; 11:e5034; doi: 10.1097/GOX.0000000000005034; Published online 9 June 2023.)

## INTRODUCTION

Accounting for more than 1.2 million procedures worldwide each year, breast implant placement represents one of the most popular procedures within aesthetic and reconstructive surgery.<sup>1,2</sup> When a breast implant is set, the immune system reacts physiologically by forming a thin fibrous capsule, which stabilizes the implant in place. The capsule normally does not exceed 1–1.5 mm,<sup>3,4</sup> but in some cases, it undergoes a pathological fibrotic thickening

process, leading to capsular contracture (CC).<sup>5</sup> CC develops from a few months to several years after implant surgery.<sup>6</sup>

CC incidence is heterogenous. Data range from 2.8% to 20.4% between 5 and 10 years after breast augmentation,<sup>7–9</sup> and up to 30% at 3 years in cases of reconstruction.<sup>9</sup> Discordant data result as a lack in standardization in implants choice and surgical techniques.<sup>5,10</sup> Most authors agree on a multifactorial etiology of CC, yet discordant reports award greater importance to different risk factors.<sup>11,12</sup> Biofilm, injuries, hematomas, type of implant, silicone leakage, surgical incision, individual susceptibility, and propensity for hypertrophic scarring are thought

*From the Plastic Surgery Unit, Department of Medicine, Surgery and Neuroscience, University of Siena, Italy.*

*Received for publication January 30, 2023; accepted April 6, 2023.*

*Copyright © 2023 The Authors. Published by Wolters Kluwer Health, Inc. on behalf of The American Society of Plastic Surgeons. This is an open-access article distributed under the terms of the Creative Commons Attribution-Non Commercial-No Derivatives License 4.0 (CCBY-NC-ND), where it is permissible to download and share the work provided it is properly cited. The work cannot be changed in any way or used commercially without permission from the journal.*

*DOI: 10.1097/GOX.0000000000005034*

Disclosure statements are at the end of this article, following the correspondence information.

Related Digital Media are available in the full-text version of the article on [www.PRSGlobalOpen.com](http://www.PRSGlobalOpen.com).

**Table 1. The Baker Classification**

Grade I	The breast is normally soft and looks natural
Grade II	The breast is a little firm but looks normal
Grade III	Visible distortion: the breast is firm and looks abnormal
Grade IV	Greater distortion: the breast is hard, painful, and looks abnormal

to play a major role in its development.<sup>13–15</sup> Radiotherapy itself is associated with a 50% to 70% increase in CC incidence.<sup>13,14</sup> Increase in breast firmness, hard breast, and breast pain eventually associated with visible distortion is the typical clinical presentation of CC. Standard evaluation relates to the Baker classification introduced by Baker in 1978<sup>16</sup> (Table 1). Patients with Baker Class III and IV typically require intervention. Proper treatment is still an open debate.

With this article, we reviewed the most recent research on CC prevention and treatment. Current approaches to the management of this complication are discussed as follows.

## MATERIAL AND METHODS

A PubMed search was carried out using the terms “breast implant,” “capsular contracture,” “capsular contracture AND prevention,” “capsular contracture AND risk factors” and “capsule contracture AND implant size.” A manual search of study references was also performed. Studies were excluded using the following criteria: studies not written in English, communication letters, case reports, animal studies, studies not relevant to CC diagnosis and management strategies, and review articles. Pertinent studies in English published up to December 1, 2022 were included in this review.

## RESULTS

The primary search yielded a total of 1877 articles, which were assessed for relevance based on their title and abstract. As a result, 97 articles were compared against the exclusion criteria, of which 43 were then fully reviewed, and 38 included and used in the synthesis of the information presented in this review (Fig. 1). The publications were categorized based on whether they aimed to describe CC risk factors and prevention (19) (Supplemental Digital Content 1), or management strategies (19) (Supplemental Digital Content 2). (See table, Supplemental Digital Content 1, which shows clinical evidence for risk factors and prevention of CC. <http://links.lww.com/PRSGO/C608>.) (See table, Supplemental Digital Content 2, which shows clinical evidence for the appropriate treatment of CC. <http://links.lww.com/PRSGO/C609>.)

## DISCUSSION

### Pathogenesis

Researchers agree of CC multifactorial origin.<sup>17</sup> Patient characteristics, implant factors and surgical techniques are known to influence on host immune response, which

## Takeaways

**Question:** Capsular contracture: where are we now and what are the future prospects?

**Findings:** The heterogeneity in patients, implants, and surgical techniques make it difficult to suitably compare or analyze specific factors. As a consequence, discordant data are present in the literature, and a true systematic review is often limited in its conclusions. Hence, we decided to present a narrative review of current theories on prevention and management strategies.

**Meaning:** The wide variety of clinical situations prevent the standardization of capsular contracture management strategies. By contrast, a patient-customized approach should be preferred, and different strategies should be considered depending on the specific case.

seems to be the real CC causative agent.<sup>17</sup> A schematic mechanism is represented in Figure 2. The periprosthetic chronic inflammation may drive a progressive fibrotic thickening process leading to CC.<sup>10,18,19</sup> Macrophages, cytokine, and cellular mediators such as IL 8 and TNF- $\alpha$  and transforming growth factor sustain the local inflammation,<sup>20,21</sup> adhesion, and fibrosis.<sup>22</sup>

A recent study has also demonstrated a direct association between capsular fibrosis and hypoxia.<sup>23</sup> The implant is avascular, and the neighboring area encounters relatively hypoxic conditions. Hypoxia may enhance tissue release of hypoxia-inducible factor-1 (HIF-1), increase levels of extracellular matrix (ECM)-associated factors, and promote epithelial-mesenchymal transition of the periprosthetic tissues.<sup>23</sup> Epithelial-mesenchymal transition seems to be a predominant source of myofibroblasts,<sup>24,25</sup> and their concentration has been directly associated with contracture severity.<sup>26</sup> HIF-1 may become a new pharmacological target, and future research should take this finding into consideration.

### Risk Factors

#### Patient Factors

Genetics and individual susceptibility could promote exaggerated immunological response and periprosthetic inflammation.<sup>27,28</sup> The correlation is well known with hypertrophic scarring; however, little is known about CC.<sup>11</sup> In addition, within patient factors, recent research has highlighted a possible role of pregnancy.<sup>29</sup> Pregnancy induces breast increase in vascularization and trophism.<sup>29</sup> The vascularity increase has been associated with a higher risk of hematoma formation and may precipitate CC.<sup>29</sup>

#### Radiotherapy

Postmastectomy radiation therapy is a strong pro-fibrotic risk factor. Data show up to a 50% increase risk of CC in patients who undergo breast postmastectomy radiation therapy and silicone implant breast reconstruction over nonirradiated reconstructions.<sup>30,31</sup> In particular, postmastectomy radiation therapy promotes scarring of the pectoralis major muscle, pain, and implant displacement.<sup>32</sup> A recent study identified radiotherapy-related

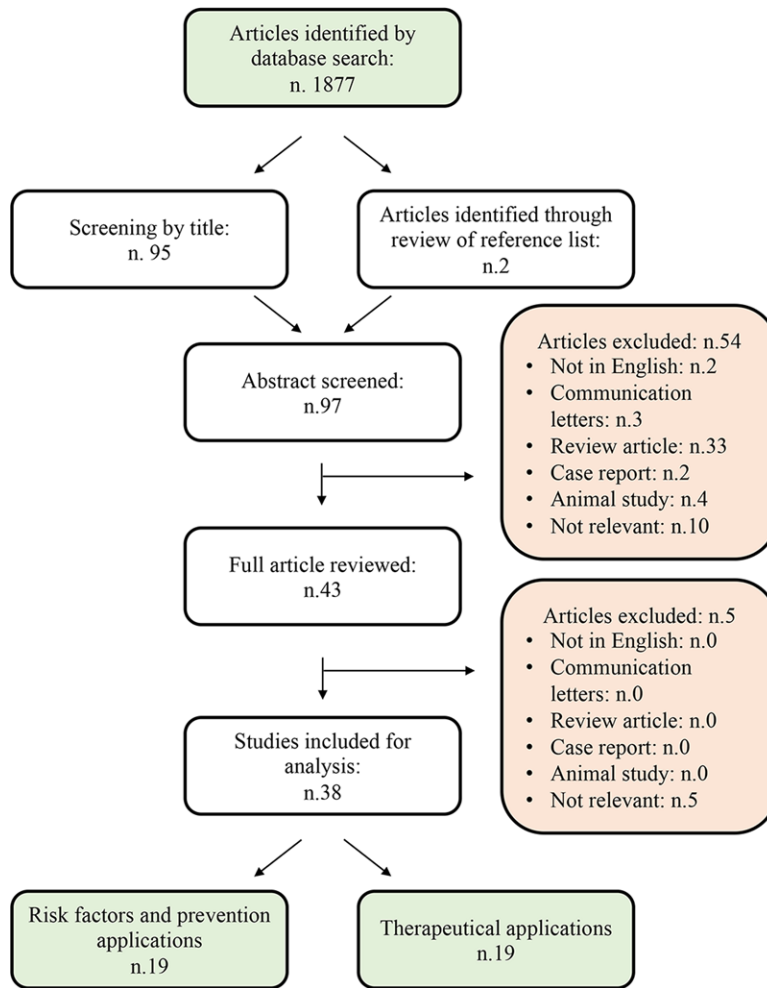


Fig. 1. Flow diagram summarizing the research results.

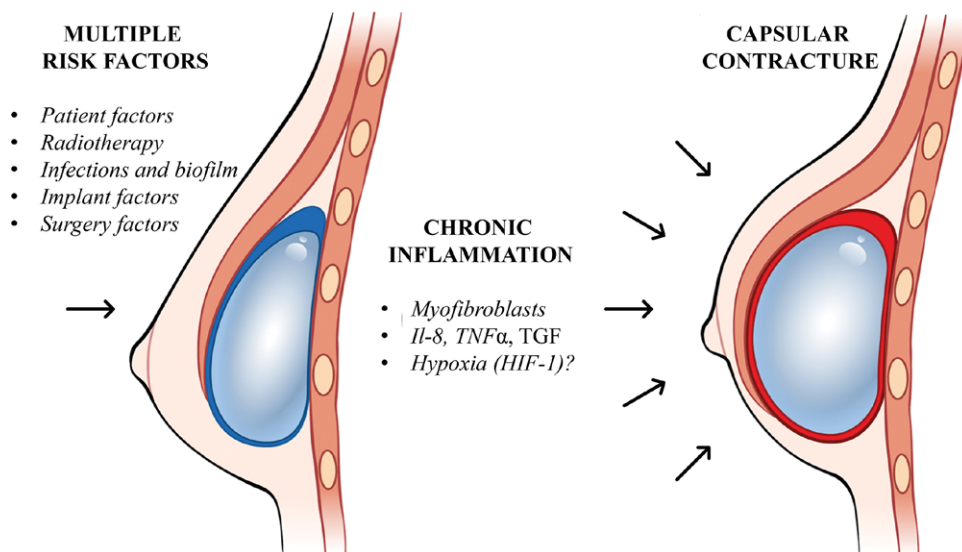


Fig. 2. CC pathogenesis schematic model.

activation of myofibroblasts with overexpression of the Thy1 protein (also called CD90). The study has also shown that in vitro Thy1 targeting with salinomycin has an interesting anti-scarring ability that should be further explored with in vivo studies.<sup>33</sup>

### **Infections and Biofilm**

The association between subacute peri-prosthetic infection and CC is well known, and surgeons routinely use antiseptic preparations to wash the implant and irrigate the pocket during surgery.<sup>34–36</sup> *Propionibacterium acnes*, *E. coli*, and *Staphylococcus epidermidis* are the most frequently implicated agents.<sup>34–36</sup> Minimizing skin contact reduces the risk of CC, but contamination may still occur, as *Staphylococcus epidermidis*, a common part of the skin flora, has also been identified as part of the endogenous flora of the breast.<sup>35,37</sup>

Different types of pocket irrigation have been studied,<sup>38</sup> and data show that saline irrigation is associated with a higher risk of CC compared with antibiotic irrigation.<sup>38</sup> It is noteworthy that the United States Food and Drug Administration in 2000 banned implant instillation with povidone-iodine, due to the increased risk of implant deflation.<sup>39</sup> The ban was later revoked in 2017.<sup>40</sup> Venkataram et al<sup>41</sup> studied both the Betadine and non-Betadine antibiotic regimens, with the Betadine regimen being preferred. In particular, Betadine was preferred due to its greater coverage on Gram-negative bacteria.<sup>41</sup> Overall, infection prevention is critical in CC prevention, yet specific protocols should be further investigated.

### **Implant Factors**

Since Thomas Cronin and Franck Gerow first used a silicone implant in 1962, continuous refinement and optimization of implant materials has led to numerous improvements in both aesthetic results and surgical safety.<sup>42</sup> Nowadays, implant-based breast surgery may rely on a wide variety of implants. These can be primarily summarized depending on their main characteristics: silicone gel or saline solution filling, smooth or textured surface and round or anatomical shape.<sup>5</sup> Size, of course, may change as well. Different implants have slightly different properties regarding CC formation and therefore have been investigated by several studies.<sup>43–47</sup>

#### **Silicone Gel versus Saline**

Saline and silicone gel filled implants are both characterized by an outer silicone shell.<sup>48</sup> Saline implants can be inserted through a small incision and subsequently filled with saline at surgery; however, any eventual breach in the shell would result in instant deflation of the implant.<sup>48</sup> Silicone gel filled implants have a much more natural consistency because of the viscosity of the filler.<sup>49</sup> However, old-generation silicone implants have been associated with implant rupture<sup>48</sup> and silicone bleeding, which is a strong CC trigger.<sup>50</sup> New-generation silicone implants are realized with a much more viscous and cohesive gel that prevents silicone leakage, therefore reducing CC risk. Caplin et al<sup>51</sup> investigated MemoryGel breast implant safety. These new-generation implants consist

of a single-lumen, round silicone elastomer shell, with a patch on the posterior side, and are filled with a cohesive silicone gel. CC rate was identified as 12.1% for primary augmentation and 24.4% for primary reconstruction; low rupture rates were identified as well.<sup>51</sup> Nowadays, it is unanimously accepted that new-generation silicone implants should be preferred.<sup>47,52</sup>

#### **Smooth versus Textured**

Implant surfaces modulate implant-tissue interface, which is critical in CC development.<sup>53</sup> Textured surface implants carry a lower CC risk.<sup>34,54–58</sup> The surface pores of textured implants seem to promote fibroblast deep random arrangement<sup>59</sup> and force vectors deviation.<sup>14,60–62</sup> Conversely, smooth implants allow for the fibroblasts within the capsule to align parallel to the implant surface, readily allowing for contraction.<sup>60,61,63</sup>

However, textured implants carry a higher risk of BIA-ALCL,<sup>64,65</sup> and a higher rate of cancer recurrence in breast oncologic reconstruction surgery.<sup>66</sup> New micro and nanotextured implants have come to the market as a possible solution.<sup>67,68</sup> The goal is to maintain a texturization, but balance oncological concern.<sup>69</sup> New implant biocompatibility improvement may reduce CC risk as well as other complications such as seroma, hematoma, and rippling.<sup>69</sup>

#### **Size and Shape**

Implant size and shape may affect CC risk by modulating tissue mechanical interactions.<sup>70</sup> Available literature has shown contradictory results. Implants greater than 350 cm<sup>3</sup> have been associated with a higher CC incidence,<sup>71</sup> but other authors could not confirm the association.<sup>29</sup> By contrast, a biochemical study designed by making use of basic elasticity theories demonstrated a counterintuitive amplified stress field at the capsule-implant interface for small-size implants.<sup>70</sup> Other researchers have identified a reduction in CC recurrence when a lower volume implant is applied in place of a larger volume one.<sup>72</sup> For what concerns shape and CC association, we could not find any significant study.

### **Surgery Factors**

Surgical choices include incision site selection, implant type, implant pocket location,<sup>73</sup> skin preparation strategies,<sup>73,74</sup> and eventual antiseptic breast pocket irrigation.<sup>73</sup> Preventive approaches should include proper prophylactic antibiotics, minimal-touch handling of the implant, strict respect for sterility, change of surgical gloves, and minimal time of implant opening.<sup>73,75</sup>

#### **Surgery Incision Accesses**

Incision accesses include inframammary, periareolar and transaxillary.<sup>76</sup> Collected data show that the inframammary incision results in lower CC rates.<sup>73,77</sup> The presence of bacterial flora in the ductal systems could account for the increased risk of CC in the periareolar access.<sup>78,79</sup> However, patients with larger areolas may still benefit from it.<sup>80</sup> The transaxillary incision has been associated with increased risk of implant malposition, secondary

procedures, and hematoma, which may precipitate CC.<sup>81</sup> However, the endoscopic assisted transaxillary approach seems to lower complications by minimizing bleeding and surgical trauma.<sup>82</sup>

### Breast Implant Placements

Traditionally, implant placements include submuscular<sup>83–85</sup> and subglandular placement.<sup>86,87</sup> An epidemiological study reports CC incidence rates of 1.9% and 9.6%, respectively.<sup>88</sup> The submuscular placement isolates the implant from the endogenous flora of the glandular tissue.<sup>35,37</sup> It also reduces mechanical friction in the surrounding tissues.<sup>17</sup> Implants might also be located dual plane<sup>86</sup> by creating a plane of surgical dissection between the subglandular tissue and the pectoralis major fascia.<sup>86</sup> This approach appears to promote retraction of the upper parenchyma, thus reducing breast ptosis.<sup>86</sup> However, in a multicenter retrospective clinical study performed in Italy from January 2010 to June 2018 on 716 direct-to-implant reconstructions,<sup>89</sup> dual plane reconstruction was associated with a CC rate of 13.87% versus 8.7% for prepectoral placement.

Surgical choices also include subfascial placement, which involves placing the breast implant under the prepectoral fascia and over the pectoralis muscle.<sup>90,91</sup> This technique may avoid the pain and complications associated with submuscular pocket dissection, while still providing the benefits of subfascial placement such as lower CC frequency and lower implant visibility.<sup>92,93</sup> Proper indications include thin and athletic patients, as subfascial placement preserves the pectoral muscle.<sup>92,93</sup> Kerfant et al<sup>94</sup> conducted a study on 156 cases describing a CC rate of 3.85% with a mean follow-up period of 22.5 months. In another study on 200 cases, Brown et al<sup>95</sup> found an even lower CC rate, estimated at 0.5%. In the light of these considerations, further comparative studies on the different techniques should be carried out.

### CC Diagnosis

CC diagnosis and severity evaluation traditionally relies on clinical examination based on a subjective classification system proposed by Baker in 1978<sup>16</sup> (Table 1) and integrated by Spear and Baker with categories IA/B for palpable and nonpalpable implants in soft breasts.<sup>16</sup> However, this approach prevents a standardized assessment of the disease and its severity, and consensus is not present among surgeons. As a possible solution to this concern, ultrasound examination has been proposed.<sup>95</sup>

Zuniga et al<sup>96</sup> aimed to correlate ultrasound findings, such as an increased number of radial folds, calcification areas, abnormal wrinkles, and deformation of the implant,<sup>97</sup> with CC severity. A total of 21 patients with smooth surface contracted implants were included. When comparing breasts graded Baker I to IV, a mean capsule thickness of  $0.6 \pm 0.2$ ,  $1.0 \pm 0.53$ ,  $1.68 \pm 0.99$ , and  $1.52 \pm 0.46$  mm, respectively, was shown. A similar correlation was also described by Kim et al.<sup>98</sup> The author reported that a capsule thickness of 0.4–0.8 mm, 0.8–1.31 mm, and 1–4.1 mm was associated with Baker grades II, III, and IV,

respectively. Ultrasound may provide a rapid, effective, noninvasive, and replicable test for CC severity assessment. It is hoped that future studies will validate these findings.

### CC Surgical Treatment

Most authors agree that the gold standard of CC treatment is represented by capsulectomy, site change, and implant exchange.<sup>15,99,100</sup> Success rate is estimated at 79%, but the procedure carries morbidity, and it is not free from complications.<sup>101</sup> It is also technically more complicated than capsulotomy, which involves incision and release of the pathological capsule, or partial capsulectomy in which the fibrotic capsule is only partially dissected and removed.<sup>102</sup> Recurrence rate studies have shown similar results between techniques ranging from 0% to 54%,<sup>99</sup> thus opening the debate.

Implant replacement, with or without implant site change, is essential in CC recurrence prevention, as it guarantees any biofilm removal.<sup>99,102</sup> When changing the implant, smooth or textured implants can be chosen, and consensus is not present.<sup>71,102</sup> Capsulotomy and partial capsulectomy do not completely remove the fibrotic capsule, and the remaining parts could act as an instigator for CC recurrence.<sup>102</sup> Literature suggests that different clinical situations may benefit from different treatments.<sup>71,102,103</sup> If the contracted implant is in a premuscular pocket, capsulectomy, implant exchange, and site change into a sub-muscular pocket should be preferred.<sup>103</sup> If the first implant placement was sub-muscular, partial capsulectomy or capsulotomy should be considered for less surgical trauma, bleeding, and complications risk.<sup>104</sup> Capsulotomy is indicated when replacing a saline implant, as the capsule of these implants typically disappears within 1 year of removal.<sup>102</sup> Partial capsulectomy represents a great compromise between total capsulectomy, which carries important scarring and hematoma risk, and capsulotomy, which does not include capsule removal,<sup>105</sup> and it could potentially become the new standard of treatment for CC.<sup>106</sup>

### New Possible Preventive Strategies

#### Autologous Fat Transfer

The surgeon can place a fat graft in the initial procedure and use lipofilling as an alternative CC treatment. Data showed that lipofilling was effective in ameliorating pain from capsular formation, as it reduced the foreign body sensation, the feeling of tension, and the feeling of cold breast.<sup>107</sup> Haran et al<sup>108</sup> showed that fat grafting elevated the CC resolution rate of secondary procedures up to 86%.<sup>108</sup> Overall, CC treatment with autologous fat transfer, possibly associated with surgery, may represent an innovative procedure, and further studies should be performed.<sup>109</sup>

#### Acellular Dermal Matrix

Acellular dermal matrix (ADM) is a biotechnological tissue prepared from human, porcine, or bovine components.<sup>110</sup> The tissue is modified by removing cells and inflammatory components. The result is an inert matrix that provides support for physiological tissue ingrowth,

cellular repopulation, and revascularization.<sup>110,111</sup> When ADM is used in implant breast surgery, it provides additional coverage of the implant, especially in the inferolateral pole where the pectoralis muscle is lacking.<sup>112,113</sup> It also offers an additional layer of tissue between the skin and the implant.<sup>110,111</sup> Researchers hypothesized that ADM may reduce CC recurrence rate, and several clinical studies showed encouraging results.<sup>114–116</sup> However, other studies reported ADM association with a higher risk of seroma and pocket infection; moreover, the expensive cost of the procedure limits a wide use.<sup>117</sup>

As a possible solution to minimize ADM costs, new bioabsorbable meshes have been studied. GalaFLEX is a biosynthetic meshes that derives from a linear polyester produced by recombinant fermentation.<sup>118</sup> The mesh is designed with strong fibers, which help tissue ingrowth and minimize infections; it is fully absorbed in 18–24 months.<sup>118</sup> Singalove et al<sup>119</sup> compared safety of using GalaFLEX-AlloDerm construct in 128 patients (249 breasts) versus AlloDerm alone in 135 patients (250 breasts) in prepectoral reconstructions. In GalaFLEX-AlloDerm reconstructions, the lower third of the expander was covered by the AlloDerm, whereas the rest of the expander was covered by GalaFLEX, thus requiring much less AlloDerm. The rate of CC did not differ significantly between groups, and it was less than 3.0%. An alternative solution may be represented by Durasorb. Durasorb is a resorbable polydioxanone mesh designed with macro-porous monofilament which promote rapid tissue incorporation.<sup>120</sup> Turin et al<sup>120</sup> evaluated its efficacy in revisional breast surgery describing 17 patients (27 breasts) with no infections, wound healing problems, or recurrences of implant malposition/CC encountered with an average follow-up of 355 days. In light of these considerations, GalaFLEX and Durasorb may represent equally effective and less expensive devices than ADM.

## CONCLUSIONS

This narrative review of the literature has attempted to outline some of the recent research on CC prevention and management strategies. From the current review, surgery seems to represent the most effective therapeutic approach to CC. Surgeons should be able to perform different techniques and manage different implants and innovative procedures as a proper approach to the wide variety of clinical situations. The next challenge, in our perspective, is to further acknowledge a “personalized approach” in which the treatment is customized to the patient, and future research is desirable to achieve such an ambitious target.

**Pietro Susini, MD**

Policlinico le Scotte, Via Bracci 16  
53100 Siena (SI), Italy  
E-mail: p.susini@student.unisi.it

## DISCLOSURE

The authors have no financial interest to declare in relation to the content of this article.

## REFERENCES

- Somogyi RB, Brown MH. Outcomes in primary breast augmentation: a single surgeon's review of 1539 consecutive cases. *Plast Reconstr Surg*. 2015;135:87–97.
- Hidalgo DA, Spector JA. Breast augmentation. *Plast Reconstr Surg*. 2014;133:567e–583e.
- Ganott MA, Harris KM, Ilkhanipour ZS, et al. Augmentation mammoplasty: normal and abnormal findings with mammography and US. *Radiographics*. 1992;12:281–295.
- Siggelkow W, Faridi A, Spiritus K, et al. Histological analysis of silicone breast implant capsules and correlation with capsular contracture. *Biomaterials*. 2003;24:1101–1109.
- Headon H, Kasem A, Mokbel K. capsular contracture after breast augmentation: an update for clinical practice. *Arch Plast Surg*. 2015;42:532–543.
- Zeplin PH, Corduff N. Influence of patient age on capsular contracture after aesthetic breast augmentation. *Plast Surg (Oakv)*. 2015;23:67–69.
- Berry T, Brooks S, Sydow N, et al. Complication rates of radiation on tissue expander and autologous tissue breast reconstruction. *Ann Surg Oncol*. 2010;17:202–210.
- Spear, SL, Murphy DK. Allergan silicone breast implant, natrelle round silicone breast implants: core study results at 10 years. *Plast Reconstr Surg*. 2014;133:1354–1361.
- Wagner DS, Mirhaidari SJ. Capsulectomy, implant exchange, and placement of acellular dermal matrix is effective in treating capsular contracture in breast augmentation patients. *Aesthet Surg J*. 2021;41:304–312.
- Domanskis E, Owsley JQJr. Histological investigation of the etiology of capsule contracture following augmentation mammoplasty. *Plast Reconstr Surg*. 1976;58:689–693.
- Chong SJ, Deva AK. Understanding the etiology and prevention of capsular contracture: translating science into practice. *Clin Plast Surg*. 2015;42:427–436.
- Wyatt LE, Sinow JD, Wollman JS, et al. The influence of time on human breast capsule histology: smooth and textured silicone-surfaced implants. *Plast Reconstr Surg*. 1998;102:1922–1931.
- Cordeiro PG, Pusic AL, Disa JJ, et al. Irradiation after immediate tissue expander/implant breast reconstruction: outcomes, complications, aesthetic results, and satisfaction among 156 patients. *Plast Reconstr Surg*. 2004;113:877–881.
- Namnoum JD, Largent J, Kaplan HM, et al. Primary breast augmentation clinical trial outcomes stratified by surgical incision, anatomical placement and implant device type. *J Plast Reconstr Aesthet Surg*. 2013;66:1165–1172.
- Adams, WP, Jr. Capsular contracture: what is it? What causes it? How can it be prevented and managed? *Clin Plast Surg*. 2009. 36(1):119–126, vii.
- Spear SL, Baker JL, Jr. Classification of capsular contracture after prosthetic breast reconstruction. *Plast Reconstr Surg*. 1995;96:1119–1123. . discussion 1124.
- Henriksen TF, Hölmich LR, Søren F, et al. The Danish Registry for Plastic Surgery of the Breast: establishment of a nationwide registry for prospective follow-up, quality assessment, and investigation of breast surgery. *Plast Reconstr Surg*. 2003;111:2182–2189. . discussion 2190–2191.
- Prantl L, Schreml S, Fichtner-Feigl S, et al. Clinical and morphological conditions in capsular contracture formed around silicone breast implants. *Plast Reconstr Surg*. 2007;120:275–284.
- Casella D, et al. Positive ROS (reactive oxygen species) modulator engineered device support skin treatment in locally advanced breast cancer (LABC) enhancing patient quality of life. *J Clin Med*. 2021;11:126.
- Kyle DJ, Harvey AG, Shih B, et al. Identification of molecular phenotypic descriptors of breast capsular contracture formation

- using informatics analysis of the whole genome transcriptome. *Wound Repair Regen.* 2013;21:762–769.
21. Tan KT, Wijeratne D, Shih B, et al. Tumour necrosis factor-alpha expression is associated with increased severity of periprosthetic breast capsular contracture. *Eur Surg Res.* 2010;45:327–332.
  22. Siegel PM, Massague J. Cytostatic and apoptotic actions of TGF-beta in homeostasis and cancer. *Nat Rev Cancer.* 2003;3:807–821.
  23. Kuo YL, Jou I-M, Jeng S-F, et al. Hypoxia-induced epithelial-mesenchymal transition and fibrosis for the development of breast capsular contracture. *Sci Rep.* 2019;9:10269.
  24. Sun YB, Qu X, Caruana G, et al. The origin of renal fibroblasts/myofibroblasts and the signals that trigger fibrosis. *Differentiation.* 2016;92:102–107.
  25. Stone RC, Pastar I, Ojeh N, et al. Epithelial-mesenchymal transition in tissue repair and fibrosis. *Cell Tissue Res.* 2016;365:495–506.
  26. Lossing C, Hansson HA. Peptide growth factors and myofibroblasts in capsules around human breast implants. *Plast Reconstr Surg.* 1993;91:1277–1286.
  27. Bachour Y, Ritt MJPF, Heijmans R, et al. Toll-like receptors (TLRs) expression in contracted capsules compared to uncontracted capsules. *Aesthetic Plast Surg.* 2019;43:910–917.
  28. Alijotas-Reig J, Fernandez-Figueras MT, Puig L. Inflammatory, immune-mediated adverse reactions related to soft tissue dermal fillers. *Semin Arthritis Rheum.* 2013;43:241–258.
  29. Dancy A, Nassimizadeh A, Levick P. Capsular contracture – what are the risk factors? A 14 year series of 1400 consecutive augmentations. *J Plast Reconstr Aesthet Surg.* 2012;65:213–218.
  30. Pomahac B, Recht A, May JW, et al. New trends in breast cancer management: is the era of immediate breast reconstruction changing? *Ann Surg.* 2006;244:282–288.
  31. Sinnott CJ, Persing SM, Pronovost M, et al. Impact of postmastectomy radiation therapy in prepectoral versus subpectoral implant-based breast reconstruction. *Ann Surg Oncol.* 2018;25:2899–2908.
  32. Bray FN, Simmons BJ, Wolfson AH, et al. Acute and chronic cutaneous reactions to ionizing radiation therapy. *Dermatol Ther (Heidelb).* 2016;6:185–206.
  33. Hansen TC, Woeller CF, Lacy SH, et al. Thyl1 (CD90) expression is elevated in radiation-induced periprosthetic capsular contracture: implication for novel therapeutics. *Plast Reconstr Surg.* 2017;140:316–326.
  34. Burkhardt BR, Demas CP. The effect of Siltex texturing and povidone-iodine irrigation on capsular contracture around saline inflatable breast implants. *Plast Reconstr Surg.* 1994;93:129–130. . discussion 129–30.
  35. Virden CP, Dobke MK, Stein P, et al. Subclinical infection of the silicone breast implant surface as a possible cause of capsular contracture. *Aesthetic Plast Surg.* 1992;16:173–179.
  36. Rubino C, Brongo S, Pagliara D, et al. Infections in breast implants: a review with a focus on developing countries. *J Infect Dev Ctries.* 2014;8:1089–1095.
  37. Pajkos A, Deva AK, Vickery K, et al. Detection of subclinical infection in significant breast implant capsules. *Plast Reconstr Surg.* 2003;111:1605–1611.
  38. Awad AN, Heiman AJ, Patel A. Implants and breast pocket irrigation: outcomes of antibiotic, antiseptic, and saline irrigation. *Aesthet Surg J.* 2022;42:NP102–NP111.
  39. Adams WP, Jr, Conner WC, Barton FE, et al. Optimizing breast-pocket irrigation: the post-betadine era. *Plast Reconstr Surg.* 2001;107:1596–1601.
  40. Jewell ML, Adams WP Jr. Betadine and breast implants. *Aesthet Surg J.* 2018;38:623–626.
  41. Venkataram A, Lahar N, Adams WP. Enhancing patient outcomes in aesthetic breast implant procedures using proven antimicrobial breast pocket irrigations: a 20-year follow-up. *Aesthet Surg J.* 2023;43:66–73.
  42. Handel N, Cordray T, Gutierrez J, et al. A long-term study of outcomes, complications, and patient satisfaction with breast implants. *Plast Reconstr Surg.* 2006;117:757–767; discussion 768–72.
  43. Handel N, Jensen JA, Black Q, et al. The fate of breast implants: a critical analysis of complications and outcomes. *Plast Reconstr Surg.* 1995;96:1521–1533.
  44. Handel N, Gutierrez J. Long-term safety and efficacy of polyurethane foam-covered breast implants. *Aesthet Surg J.* 2006;26:265–274.
  45. Blount AL, Martin MD, Lineberry KD, et al. Capsular contracture rate in a low-risk population after primary augmentation mammoplasty. *Aesthet Surg J.* 2013;33:516–521.
  46. Kulmala I, McLaughlin JK, Pakkanen M, et al. Local complications after cosmetic breast implant surgery in Finland. *Ann Plast Surg.* 2004;53:413–419.
  47. Vinci V, Domenico C, Luca M, et al. The evolution of breast prostheses. *Breast J.* 2020;26:1801–1804.
  48. Maxwell GP, Gabriel A. The evolution of breast implants. *Plast Reconstr Surg.* 2014;134(1 Suppl):12Sp. 12S–12Sp. 17S.
  49. Nichter LS, Hardesty RA, Anigian GM. IDEAL IMPLANT structured breast implants: core study results at 6 years. *Plast Reconstr Surg.* 2018;142:66–75.
  50. Moyer HR, Ghazi BH, Losken A. The effect of silicone gel bleed on capsular contracture: a generational study. *Plast Reconstr Surg.* 2012;130:793–800.
  51. Caplin DA, Calobrace MB, Wixtrom RN, et al. MemoryGel breast implants: final safety and efficacy results after 10 years of follow-up. *Plast Reconstr Surg.* 2021;147:556–566.
  52. Gabriel A, Maxwell GP. The evolution of breast implants. *Clin Plast Surg.* 2015;42:399–404.
  53. Lista F, Austin RE, Saheb-Al-Zamani M, et al. Does implant surface texture affect the risk of capsular contracture in subglandular breast augmentation and breast augmentation-mastopexy? *Aesthet Surg J.* 2020;40:499–512.
  54. Burkhardt BR, Eades E. The effect of Biocell texturing and povidone-iodine irrigation on capsular contracture around saline-inflatable breast implants. *Plast Reconstr Surg.* 1995;96:1317–1325.
  55. Coleman DJ, Sharpe DT, Naylor IL, et al. The role of the contractile fibroblast in the capsules around tissue expanders and implants. *Br J Plast Surg.* 1993;46:547–556.
  56. Ersek RA. Rate and incidence of capsular contracture: a comparison of smooth and textured silicone double-lumen breast prostheses. *Plast Reconstr Surg.* 1991;87:879–884.
  57. Barnsley GP, Sigurdson LJ, Barnsley SE. Textured surface breast implants in the prevention of capsular contracture among breast augmentation patients: a meta-analysis of randomized controlled trials. *Plast Reconstr Surg.* 2006;117:2182–2190.
  58. Hakelius L, Ohlsen L. A clinical comparison of the tendency to capsular contracture between smooth and textured gel-filled silicone mammary implants. *Plast Reconstr Surg.* 1992;90:247–254.
  59. Wong CH, Samuel M, Tan B-K, et al. Capsular contracture in subglandular breast augmentation with textured versus smooth breast implants: a systematic review. *Plast Reconstr Surg.* 2006;118:1224–1236.
  60. Wickman M, Johansson O, Olenius M, et al. A comparison of the capsules around smooth and textured silicone prostheses used for breast reconstruction. A light and electron microscopic study. *Scand J Plast Reconstr Surg Hand Surg.* 1993;27:15–22.
  61. Rubino C, Mazzarello V, Farace F, et al. Ultrastructural anatomy of contracted capsules around textured implants in augmented breasts. *Ann Plast Surg.* 2001;46:95–102.
  62. Kuriyama E, Ochiai H, Inoue Y, et al. Characterization of the capsule surrounding smooth and textured tissue expanders

- and correlation with contracture. *Plast Reconstr Surg Glob Open*. 2017;5:e1403.
63. Steiert AE, Boyce M, Sorg H. Capsular contracture by silicone breast implants: possible causes, biocompatibility, and prophylactic strategies. *Med Devices (Auckl)*. 2013;6:211–218.
  64. Hu H, Jacombs A, Vickery K, et al. Chronic biofilm infection in breast implants is associated with an increased T-cell lymphocytic infiltrate: implications for breast implant-associated lymphoma. *Plast Reconstr Surg*. 2015;135:319–329.
  65. Cuomo R. The state of the art about etiopathogenetic models on breast implant associated-anaplastic large cell lymphoma (BIA-ALCL): a narrative review. *J Clin Med*. 2021;10:2082.
  66. Lee KT, Kim S, Jeon B-J, et al. Association of the implant surface texture used in reconstruction with breast cancer recurrence. *JAMA Surg*. 2020;155:1132–1140.
  67. Buonomo OC, Morando L, Materazzo M, et al. Comparison of round smooth and shaped micro-textured implants in terms of quality of life and aesthetic outcomes in women undergoing breast reconstruction: a single-centre prospective study. *Updates Surg*. 2020;72:537–546.
  68. Tanner B. Low rate of capsular contracture in a series of 214 consecutive primary and revision breast augmentations using microtextured implants. *JPRAS Open*. 2018;15:66–73.
  69. Shauly O, Gould DJ, Patel KM. Microtexture and the cell/bio-material interface: a systematic review and meta-analysis of capsular contracture and prosthetic breast implants. *Aesthet Surg J*. 2019;39:603–614.
  70. Fraldi M, Esposito L, Cutolo A, et al. Stealthy role of size-driven stresses in biomechanics of breast implants capsular contracture. *J Mech Behav Biomed Mater*. 2016;64:199–208.
  71. Henriksen TF, Fryzek JP, Hölmich LR, et al. Surgical intervention and capsular contracture after breast augmentation: a prospective study of risk factors. *Ann Plast Surg*. 2005;54:343–351.
  72. Ganon S, Morinet S, Serron K, et al. epidemiology and prevention of breast prosthesis capsular contracture recurrence. *Aesthetic Plast Surg*. 2021;45:15–23.
  73. Wiener TC. Relationship of incision choice to capsular contracture. *Aesthetic Plast Surg*. 2008;32:303–306.
  74. Carvajal J, Carvajal M, Hernandez G. Back to basics: could the preoperative skin antiseptic agent help prevent biofilm-related capsular contracture? *Aesthet Surg J*. 2019;39:848–859.
  75. Mladick RA. “No-touch” submuscular saline breast augmentation technique. *Aesthetic Plast Surg*. 1993;17:183–192.
  76. Khavanin N, Jordan SW, Rambachan A, et al. A systematic review of single-stage augmentation-mastopexy. *Plast Reconstr Surg*. 2014;134:922–931.
  77. Bresnick SD. Correlation between capsular contracture rates and access incision location in vertical augmentation mastopexy. *Plast Reconstr Surg*. 2022;150:1029–1033.
  78. Thornton JW, Argenta LC, McClatchey KD, et al. Studies on the endogenous flora of the human breast. *Ann Plast Surg*. 1988;20:39–42.
  79. Rusby JE, Brachtel EF, Michaelson JS, et al. Breast duct anatomy in the human nipple: three-dimensional patterns and clinical implications. *Breast Cancer Res Treat*. 2007;106:171–179.
  80. Tebbetts JB. Axillary endoscopic breast augmentation: processes derived from a 28-year experience to optimize outcomes. *Plast Reconstr Surg*. 2006;118(7 Suppl):53S–80S.
  81. Coombs DM, Grover R, Prassinis A, et al. Breast augmentation surgery: Clinical considerations. *Cleve Clin J Med*. 2019;86:111–122.
  82. Liu C, Chen Y, Xu Y, et al. Transaxillary endoscopic approach to capsular contracture following previous breast augmentation: operative technique and clinical outcome. *Aesthetic Plast Surg*. 2020;44:28–34.
  83. Spear SL, Jespersen MR. Breast implants: saline or silicone? *Aesthet Surg J*. 2010;30:557–570.
  84. Torre G, Avedimento S, Guastafierro A, et al. Brachial plexus block versus wide-awake local anaesthesia for open reduction internal fixation surgery in distal radius fracture: A preliminary retrospective report. *J Plast Reconstr Aesthet Surg*. 2021;74:2776–2820.
  85. Casella D, Fusario D, Cassetti D, et al. Controlateral symmetrisation in srm for breast cancer: now or then? Immediate versus delayed symmetrisation in a two-stage breast reconstruction. *Curr Oncol*. 2022;29:9391–9400.
  86. Adams WP, Jr., Mallucci P. Breast augmentation. *Plast Reconstr Surg*. 2012;130:597e–611e.
  87. Cuomo R, Giardino FR, Neri A, et al. Optimization of prepectoral breast reconstruction. *Breast Care (Basel)*. 2021;16:36–42.
  88. Shen Z, Chen Xi, Sun J, et al. A comparative assessment of three planes of implant placement in breast augmentation: a Bayesian analysis. *J Plast Reconstr Aesthet Surg*. 2019;72:1986–1995.
  89. Ribuffo D, Berna G, De Vita R, et al. Dual-plane retro-pectoral versus pre-pectoral DTI breast reconstruction: an italian multi-center experience. *Aesthetic Plast Surg*. 2021;45:51–60.
  90. Graf RM, Bernardes A, Rippel R, et al. Subfascial breast implant: a new procedure. *Plast Reconstr Surg*. 2003;111:904–908.
  91. Graf RM, Bernardes A, Auersvald A, et al. Subfascial endoscopic transaxillary augmentation mammoplasty. *Aesthetic Plast Surg*. 2000;24:216–220.
  92. Siclován HR, Jomah JA. Advantages and outcomes in subfascial breast augmentation: a two-year review of experience. *Aesthetic Plast Surg*. 2008;32:426–431.
  93. Brown T. Subfascial breast augmentation: is there any advantage over the submammary plane? *Aesthetic Plast Surg*. 2012;36:566–569.
  94. Kerfant N, Henry A-S, Hu W, et al. Subfascial primary breast augmentation with fat grafting: a review of 156 cases. *Plast Reconstr Surg*. 2017;139:1080e–1085e.
  95. Zahavi A, Sklair ML, Ad-El DD. Capsular contracture of the breast: working towards a better classification using clinical and radiologic assessment. *Ann Plast Surg*. 2006;57:248–251.
  96. Torres-Zuniga S, Ziade NV, Zambrano JC. Ultrasound criteria and baker scale for breast implant capsular contracture diagnosis. *Plast Reconstr Surg Glob Open*. 2022;10:e4582.
  97. Gossner J. Sonography in capsular contracture after breast augmentation: value of established criteria, new techniques and directions for research. *J Ultrasound*. 2017;20:87–89.
  98. Kim JH, Nam SE, Sung JY, et al. The value of capsule thickness on breast ultrasound as an indicator of the severity of capsular contracture and its correlation with the baker classification. *Aesthetic Plast Surg*. 2022;46:621–629.
  99. Pereira Leite L, Correia Sa I, Marques M. [Etiopathogenesis and treatment of breast capsular contracture]. *Acta Med Port*. 2013;26:737–745
  100. Sadeghi P, et al. , Post-bariatric plastic surgery: abdominoplasty, the state of the art in body contouring. *J Clin Med*. 2022;11:4315.
  101. Lee HK, Jin US, Lee YH. Subpectoral and precapsular implant repositioning technique: correction of capsular contracture and implant malposition. *Aesthetic Plast Surg*. 2011;35:1126–1132.
  102. Araco A, Caruso R, Araco F, et al. Capsular contractures: a systematic review. *Plast Reconstr Surg*. 2009;124:1808–1819.
  103. Zingaretti N, Vittorini P, Savino V, et al. Surgical treatment of capsular contracture (CC): literature review and outcomes utilizing implants in revisionary surgery. *Aesthetic Plast Surg*. 2021;45:2036–2047.
  104. Lam MC, Walgenbach-Brünagel G, Pryalukhin A, et al. Management of capsular contracture in cases of silicone gel breast implant rupture with use of pulse lavage and open capsulotomy. *Aesthetic Plast Surg*. 2019;43:1173–1185.
  105. Swanson E. Evaluating the necessity of capsulectomy in cases of textured breast implant replacement. *Ann Plast Surg*. 2020;85:691–698.



106. Castello MF, Lazzeri D, Silvestri A, et al. Maximizing the use of precapsular space and the choice of implant type in breast augmentation mammoplasty revisions: review of 49 consecutive procedures and patient satisfaction assessment. *Aesthetic Plast Surg*. 2011;35:828–838.
107. Papadopoulos S, Vidovic G, Neid M, et al. Using fat grafting to treat breast implant capsular contracture. *Plast Reconstr Surg Glob Open*. 2018;6:e1969.
108. Haran O, Bracha G, Tiosano A, et al. Postirradiation capsular contracture in implant-based breast reconstruction: management and outcome. *Plast Reconstr Surg*. 2021;147:11–19.
109. Roca GB, Graf R, da Silva Freitas R, et al. Autologous fat grafting for treatment of breast implant capsular contracture: a study in pigs. *Aesthet Surg J*. 2014;34:769–775.
110. Macadam SA, Lennox PA. Acellular dermal matrices: economic considerations in reconstructive and aesthetic breast surgery. *Clin Plast Surg*. 2012;39:187–216.
111. del Pozo JL, Auba C. Role of biofilms in breast implant associated infections and capsular contracture. *Adv Exp Med Biol*. 2015;831:53–67.
112. Sisti A, Sadeghi P, Cuomo R, et al. Pre-pectoral one-stage breast reconstruction with anterior coverage using superior anterior biological acellular dermal matrix (ADM) and inferior anterior dermal sling support. *Medicina (Kaunas)*. 2022;58:992.
113. Cuomo R. Submuscular and pre-pectoral ADM assisted immediate breast reconstruction: a literature review. *Medicina (Kaunas)*. 2020;56:256.
114. Carpaneda CA. Inflammatory reaction and capsular contracture around smooth silicone implants. *Aesthetic Plast Surg*. 1997;21:110–114.
115. Wolfram D, Rabensteiner E, Grundtman C, et al. T regulatory cells and TH17 cells in peri-silicone implant capsular fibrosis. *Plast Reconstr Surg*. 2012;129:327e–337e.
116. Kamel M, Protzner K, Fornasier V, et al. The peri-implant breast capsule: an immunophenotypic study of capsules taken at explantation surgery. *J Biomed Mater Res*. 2001;58:88–96.
117. Safran T, Al-Halabi B, Viezel-Mathieu A, et al. Direct-to-implant, prepectoral breast reconstruction: a single-surgeon experience with 201 consecutive patients. *Plast Reconstr Surg*. 2020;145:686e–696e.
118. Williams SF, Martin DP, Moses AC. The history of GalaFLEX P4HB scaffold. *Aesthet Surg J*. 2016;36:S33–S42.
119. Sigalove S, O'Rorke E, Maxwell GP, et al. Evaluation of the safety of a GalaFLEX-AlloDerm construct in prepectoral breast reconstruction. *Plast Reconstr Surg*. 2022;150:75S–81S.
120. Turin SY, Gutowski K. Bioabsorbable polydioxanone mesh for soft tissue reinforcement in revisional breast surgery. *Aesthet Surg J Open Forum*. 2022;4:ojac004.