

Dorsal dumb-bell melanotic schwannoma operated on by posterior and anterior approach: case report and a review of the literature

Leonardo De Cerchio · Filiberto Contratti · Mario F. Fraioli

Received: 22 January 2006 / Revised: 29 June 2006 / Accepted: 6 July 2006 / Published online: 1 September 2006
© Springer-Verlag 2006

Abstract The schwannomas are benign tumors originating from Schwann cells which constitute the nerve sheath. The dorsal pigmented type of schwannomas is relatively rare (Goldstein in *Am J Med Genet* 86:62–65, 2004; Kurtkaya-Yapicier in *Histol Histopathol* 18(3):925–934, 2003). There are two distinct types of melanotic schwannoma: the sporadic melanotic schwannomas and the psammomatous melanotic schwannomas of Carney complex. We report a case of a patient harboring a right dorsal dumb-bell melanotic schwannoma and left adrenal mass. The patient underwent a surgical procedure for en bloc total removal of the mass by a posterior and anterior approach. Histopathological examination revealed the diagnosis of melanotic schwannoma. At present, we have no reliable marker of histopathological malignancy of melanotic schwannoma so the follow-up period ought to continue for a period of more than 5 years. As the total removal of the melanotic neurinomas is mandatory to prevent possible malignant transformation of the tumor recurrence or regrowth, we believe that the posterior and trans-thoracic approach are the most suitable one for the dorsal dumb-bell schwannoma.

Keywords Dorsal dumb-bell melanotic schwannoma · Thoracic nerve sheath tumor · Spinal tumor · Carney syndrome

Introduction

Dorsal dumb-bell melanotic schwannomas are very rare [13]. They are rather frequently associated to Carney's complex [8–10]. They present problems on different aspects, such as pre-operative diagnosis, surgical approach and post-operative course. We describe the case of a 53-year-old man who presented with left adrenal hyperplasia and right paravertebral mass suggesting a dumb-bell schwannoma.

Case report

Presentation and examination

In January 2003, a 53-year-old salesman, heavy smoker with an elevated level of arterial hypertension, began to complain about pain in his right chest and upper limb. Chest X-ray and thoracic CT scan in the following February revealed a D9–D10 dumb-bell mass extending into the intrathoracic right space for about 2.5 cm. The patient was admitted to our clinic. A spinal dorsal MRI confirmed the presence of the voluminous D9–D10 right paravertebral mass (Figs. 1, 2). Abdomen MRI showed an almost 4 cm swelling of the left suprarenal gland, suggesting a pheochromocytoma (Fig. 3). The neurologic examination and brain MRI were normal. The renal arterial echodoppler, the dosing of vanilmandelic acid, alpha-fetoprotein, carcinoembryonic antigen, urinary catecholamine and cortisol were normal. The renin activity and the plasmatic level of aldosterone resulted normal in orthostasis and increased in recumbency. The medullar adrenal gland scintigrams (123 IIs MIBG-148 MBqs e.v.) resulted

L. De Cerchio (✉) · F. Contratti · M. F. Fraioli
Division of Neurosurgery, Department of Neuroscience,
Tor Vergata Hospital, University of Rome "Tor Vergata",
Viale Oxford 81, 00133 Rome, Italy
e-mail: leonardo.decerchio@fastwebnet.it

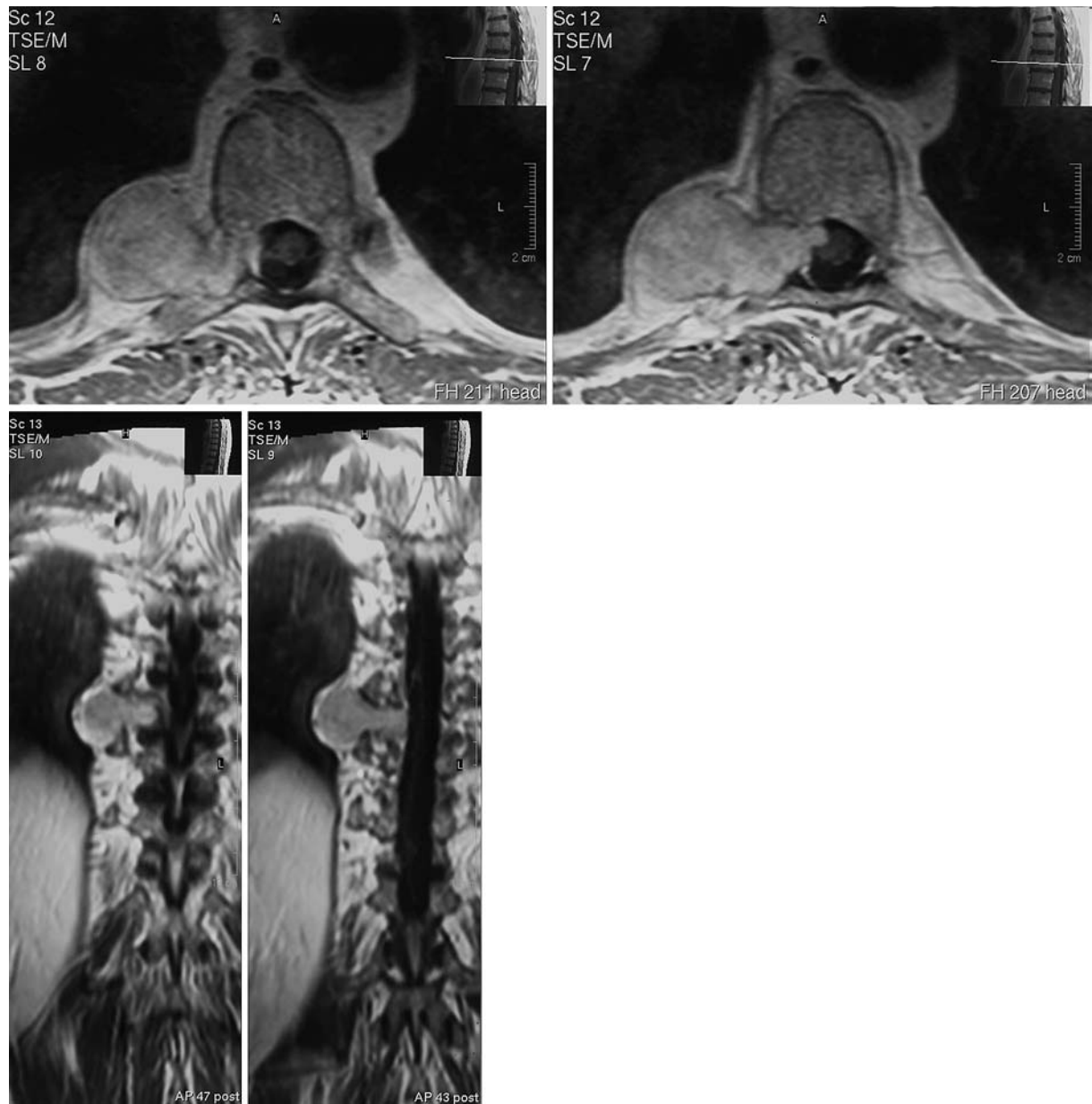


Fig. 1 MR images demonstrating a right dumb-bell intra-extradural mass at T9–T10 level extending into the intrathoracic right space for about 2.5 cm. Coronal and axial T1-weighted images with Gd-DTPA enhancement

negative for pheochromocytoma. Therefore, we excluded a pheochromocytoma and the patient underwent a surgical procedure for total removal of the dorsal mass by posterior and anterior approach in collaboration with the thoracic surgeons.

Operation

A D9–D10 laminectomy after radioscopic control was performed. A right dumb-bell intra-extradural mass of blackish aspect was seen. En bloc total removal of a

markedly melanotic intradural lesion was achieved using operating microscope. Then the patient was placed in the left lateral decubitus and by trans-thoracic approach the paravertebral mass was radically removed en bloc, also freeing the right D9–D10 intervertebral foramen from the black and well-encapsulated neoformation. Accurate plastic of the paravertebral pleural wall was obtained. Histological examination revealed melanotic schwannoma with mitotic index not superior to one for ten fields on high magnification indicating low risk for malignancy.

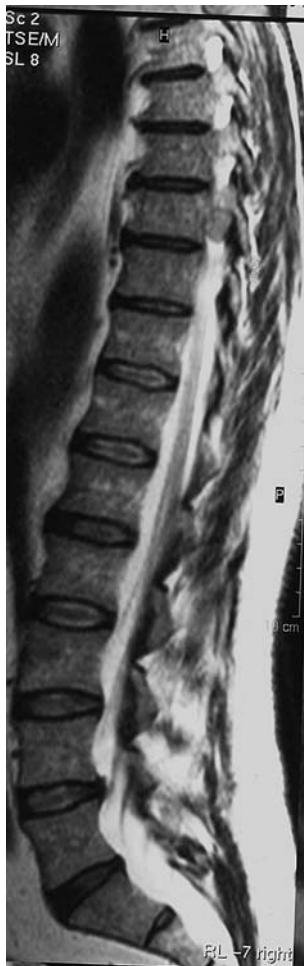

Fig. 2 Sagittal T2-weighted MRI showing T9–T10 right intervertebral foramen occupied by the tumor

Postoperative course

Post-operative course was uneventful, with marked improvement of the painful symptomatology and good healing of the surgical wounds. The patient was discharged from our ward after 10 days, with a recommendation for ichnographic controls of the left adrenal gland hyperplasia. During a 2-year follow-up period, no recurrence was evident on surveillance MRI.

Discussion

The schwannomas are benign tumors originating from Schwann cells which constitute the nerve sheath. The first case was described by Bjornboe [13, 15] in 1934 in a patient with neurofibromatosis type I. There are two distinct types of melanotic schwannoma: the sporadic and the psammomatous melanotic schwannomas of Carney complex [8, 14, 24, 27, 29, 36]. In 1985, Carney

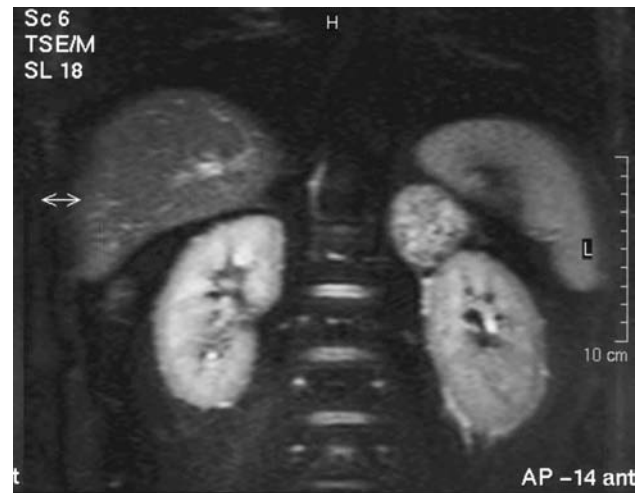

Fig. 3 Coronal abdominal spectral fat saturation inversion recovery (SPIR) MR images showing left suprarenal swelling

described a syndrome characterized by mixomas (heart, skin and breast), mucus-cutaneous spotty pigmentations and endocrine overactivity (due to thyroid dysfunction or hypophysial adenoma or Cushing syndrome secondary to adrenocortical pigmented primary nodular hyperplasia) [8, 9].

A year later, a Mendelian dominant heredity was defined responsible for the symptomatologic complex [43]. About 50% of patients with melanotic psammomatous schwannomas are affected by the syndrome of Carney and one-fifth of them are carriers of multiple lesions [21, 42]. Generally, melanotic schwannoma affects the spinal nerves, the central nervous system and the autonomous nerve system, but extra-nervous locations can also exist. The dorsal location represents 30.5% of the spinal melanotic schwannoma [41]. Until today we were able to find 47 spinal cases of extramedullary melanotic neurinoma in literature (Table 1) [1, 2, 3, 5, 6, 7, 11, 12, 13, 16, 18, 20, 21, 26, 28, 30, 31, 33, 34, 35, 38, 39, 44, 45]. The clinical presentation is not specific but similar to that of other extramedullary spinal tumors (radicular pain, dysesthesias, progressive sensorial-motor deficits). Preoperative diagnosis is based on magnetic resonance imaging (MRI): melanotic schwannomas appear hyperintense on T1-weighted sequences and hypointense on T2-weighted sequences compared to the nonmelanotic type of schwannomas that are hypo-isointense on T1 and hyperintense on T2 [1, 13, 17, 25, 37].

The histological differential diagnosis with the other spinal pigmented tumors is with the meningeal melanocytoma, the pigmented neurofibroma, the paraganglioma, the ganglioneuroma, the fibrous form of meningioma and above all with the primitive melanoma or relative metastasis [13, 15]. Even if the asso-

Table 1 Review of 47 cases of spinal extramedullary melanotic schwannoma reported in literature

References	Age	Gender	Level
Aprile et al. [1]	70	F	L3
Bagchi et al. [2]	40	M	T6–T7
Belak et al. [3]	44	–	Dorsal
Bosman et al. [4]	43	M	L4–L5
Bouziani et al. [5]	46	M	Lumbar
Buhl et al. [6]	28	M	L5–S1
Bunc et al. [7]	–	–	T12–L2
Cornejo et al. [10]	36	M	L3–L4
Di Gregorio et al. [11]	–	–	Sacral
Erlandson et al. [12]	36	M	L5–S1
Goasguen et al. [13]	66	F	C2–C3
Graziani et al. [15]	40	F	T3
Gregorios et al. [16]	45	F	T2
Iizuka et al. [18]	58	F	T10
Killeen et al. [19]	26	F	S1
Krichen et al. [20]	27	M	C6–C7
Kuchelmeister et al. [21]	53	F	C5–C6
Le Cam et al. [23]	35	F	L4
Leger et al. [24]	36	M	C4
Lowman et al. [26]	17	F	T12–L1
Lowman et al. [26]	26	F	C6
Ludvikova et al. [27]	56	F	Spine
Ludvikova et al. [27]	58	M	Spine
Mandybur et al. [28]	59	M	T7
Martin-Reay et al. [29]	32	M	Sacrum
McGavran et al. [30]	12	F	T2
McGavran et al. [30]	49	F	C8
Mennemeyer et al. [31]	23	F	L1
Mennemeyer et al. [31]	25	M	T7
Mennemeyer et al. [31]	36	M	S1
Parent et al. [33]	63	F	S1
Paris et al. [34]	49	F	C8
Parker et al. [35]	18	F	Dorsal
Prieto-Rodriguez et al. [36]	38	M	T5
Schmitz et al. [38]	42	F	Cervical
Tawk et al. [39]	61	M	T7
Vallat-Decouvelaere et al. [41]	5 cases	F and M	C–T–L–S
Zhang et al. [44]	5 cases	F and M	Spinal nerve root
Zonenshayn et al. [45]	27	F	L2 and L4–L5

ciation of the left adrenal swelling and arterial hypertension with the dumb-bell thoracic melanotic schwannoma can be correlated to the Carney complex, in our opinion our patient did not harbor such a syndrome. In fact only the adrenocortical pigmented primary nodular hyperplasia is a characteristic stigmata of Carney complex. Moreover, our patient did not show cutaneous signs of neurofibromatosis and his family history was negative for Carney complex stigmata. The total body CT scan showed the left adrenal mass and excluded any other typical lesion of the syndrome. The increased plasmatic level of renin and aldosterone in recumbency in our patient, that was on heavy medical therapy for high level of arterial blood pressure, may

be correlated to left adrenal hyperplasia or solitary adrenal adenoma [40] and not to adrenocortical pigmented nodular hyperplasia, which is the cause of ACTH-independent adrenal Cushing's syndrome [8] and normally do not trigger elevation of plasmatic aldosterone. Moreover, in our case the histological examination of the neurinoma did not show the most common, psammomatous aspect of Carney complex [8, 13]. In summary, we did not perform a left adrenal biopsy as we ruled out the Carney syndrome and malignancy of the adrenal mass by clinic and radiological investigations. Hypertension, adrenal mass and dumb-bell melanotic schwannoma do not imply Carney complex.

In our patient the hypertension was not correlated to the Carney complex, but to the hyperaldosteronism caused by left adrenal hyperplasia or solitary adrenal adenoma. Nevertheless, neurosurgeons ought to keep in mind the connection between the melanotic schwannoma and the Carney complex, since more than 50% of the cases described in literature have been related to such syndrome. A complete endocrinological evaluation and a total body CT should always be performed together with a genetic study in the suspicion of Carney complex. The risk of possible malignant transformation of the neurinoma should also be taken into consideration as cases of recurrences or metastases have been described even 13 years after surgery [4, 6, 19, 21, 23, 32, 41]. It is not possible to have any reliable histopathological indication of possible malignant transformation after the first surgical operation [42]. The follow-up ought to continue for a period of more than 5 years. We have both to check the primitive tumor regrowth or recurrence and the possible remote locations, particularly in the lungs.

From the surgical point of view the total removal of the melanotic neurinomas is mandatory to prevent possible malignant transformation of the tumor remnants. The therapeutic potential of radiotherapy is not proven [42]. The prognosis depends, therefore, almost entirely on the extent of surgical removal of the tumor [3, 44]. So we believe that the posterior and anterior approach is the most suitable one to remove the dorsal dumb-bell schwannoma completely, both in the thoracic cavity and in the intervertebral foramen, and to avoid possible liquor leakage.

References

- Aprile I, Scott CA, Cervasato D, Beltrami CA, Meo A, Fabris G (2000) Two rare lumbar tumours with unusual MRI characteristics. *Neuroradiology* 42(6):458–461

2. Bagchi AK, Sarkar SK, Chakraborti DP (1975) Melanotic spinal schwannoma. *Surg Neurol* 3(2):79–81
3. Belak J, Vajo J, Boor A, Janik M, Sauka C, Lukac I, Menova K, Stebnicky M (2001) A “dumbbell” tumor of the mediastinum case report (Abstract). *Rozhl Chir* 80(11):572–574
4. Bosman C, Boldrini R, Corsi A (1995) Malignant melanotic schwannoma or schwannian melanoma? *Tumori* 81:208–212
5. Bouziani A, Kammoun N, Zidi B, Ben Hamadi F, Benzarti H, Khelil A, Ben Ayed M (1994) Melanotic schwannoma. A case with review of the literature (in French). *Arch Anat Cytol Pathol* 42:46–53
6. Buhl R, Barth H, Hugo HH, Mautner VF, Mehdorn HM (2004) Intracranial and spinal melanotic schwannoma in the same patient. *J Neurooncol* 68(3):249–254
7. Bunc G, Kramberger S, Kovacic S, Seruga T, Vorsic M (2004) Recurrent giant invasive thoracolumbar schwannoma (Abstract). *Wien Klin Wochenschr* 116(Suppl 2):93–96
8. Carney JA (1990) Psammomatous melanotic schwannoma A distinctive, heritable tumor with special associations, including cardiac myxoma and the cushing syndrome. *Am J Surg Pathol* 14:206–222
9. Carney JA, Stratakis CA (1998) Epithelioid blue nevus and psammomatous melanotic schwannoma: the unusual pigmented skin tumors of the Carney complex. *Semin Diagn Pathol* 15:216–224
10. Cornejo M, Pierron D, Robine D, Lepreux JF, Aviera EJJM (1992) Schwannome melanocytique intrarachidien A propos d'un cas. *Revue de la literature. Rachis* 4:281–286
11. Di Gregorio C, Fano RA, Criscuolo M (1984) Melanotic schwannoma: a case report. *Appl Pathol* 2(2):110–115
12. Erlandson RA (1985) Melanotic schwannoma of spinal nerve origin. *Ultrastruct Pathol* 9(1–2):123–129
13. Goasguen O, Boucher E, Pouit B, Soulard R, Le Charpentier M, Pernot P (2003) French Melanotic schwannoma, a tumor with a unpredictable prognosis: case report and review of the literature. *Neurochirurgie* 49:31–38
14. Goldstein MM, Casey M, Carney JA, Basson CT (1999) Molecular genetic diagnosis of the familiar myxoma syndrome (Carney complex). *Am J Med Genet* 86:62–65
15. Graziani N, Gambardelli D, Bartoli JM, Decham-Benoit G, Bellard S, Grisoli F (1988) French extra-medullary intradural melanotic tumor: a propos of a case of dorsal pigmented neurinoma. Review of the literature. *Neurochirurgie* 34:210–217
16. Gregorios JB, Chou SM, Bay J (1982) Melanotic schwannoma of the spinal cord. *Neurosurgery* 11:57–60
17. Hollinger P, Godoy N, Sturzenegger M (1999) Magnetic resonance imaging findings in isolated spinal psammomatous melanotic schwannoma [letter]. *J Neurol* 246:1100–1102
18. Iizuka H, Nakamura T, Kadoya S (1988) Spinal melanotic schwannoma: report of a case (in Japanese). *No Shinkei Geka* 16:1199–1205
19. Killeen RM, Davy CL, Bauserman SC (1988) Melanocytic schwannoma. *Cancer* 62:174–183
20. Krichen H, Daghfous MS, Mrabet A, Douik M, Slimane N, Forest M (1993) Extended melanocytic tumor of the cervical spine. A propos of a case of melanotic schwannoma (in French). *Ann Pathol* 13:184–187
21. Kuchelmeister K, Lotz C, Schonmayr R, Schachenmayr W (2004) April 2004: woman in her early fifties with a cervical intraspinal and extraspinal mass lesion. *Brain Pathol* 14(4):453–454, 458–459
22. Kurtkaya-Yapicier O, Scheithauer B, Woodruff JM (2003) The pathobiologic spectrum of Schwannomas. *Histol Histopathol* 18(3):925–934
23. Le Cam C, Gontier M, Martin A, Sevestre H, Cordonnier C, Smadja A (1995) French Schwannome mélanocytique spinal d'évolution maligne. Etude microscopique et ultrastructurale d'un cas. *Arch Anat Cytol Pathol* 43:160–163
24. Leger F, Vital C, Rivel J, Benjelloun B, San Galli F, Guerin J (1996) Psammomatous melanotic schwannoma of a spinal nerve root. Relationship with the Carney complex. *Pathol Res Pract* 192:1142–1147
25. Liessi G, Barbazza R, Sartori F, Sabbadin P, Scapinello A (1990) CT and MR imaging of melanocytic schwannomas; report of three cases. *Eur J Radiol* 11:138–142
26. Lowman RM, Livolsi VA (1980) Pigmented melanotic schwannomas of the spinal canal. *Cancer* 46:391–397
27. Ludvikova M, Michal M, Marek J, Syrucek M (1997) Psammomatous melanotic schwannoma (Abstract). *Cesk Patol* 33:141–145
28. Mandybur TI (1974) Melanotic nerve sheath tumors. *J Neurosurg* 41:187–192
29. Martin-Reay DG, Shattuck MC, Guthrie FW Jr (1991) Psammomatous melanotic schwannoma: an additional component of Carney's complex. Report of a case. *Am J Clin Pathol* 95:484–489
30. McGavran WL III, Sybert GW, Ballinger WE (1978) Melanotic schwannoma. *Neurosurgery* 2:47–51
31. Menemeyer RP, Hallman KO, Hammar SP, Raisia JE, Tytus JS, Bockus D (1979) Melanotic schwannoma. Clinical and ultrastructural studies of three cases with evidence of intracellular melanin synthesis. *Am J Surg Pathol* 3:3–10
32. Noubari BA, Chiaramonte I, Magro G, Tropea R, Mancuso P (1998) Spinal malignant melanotic schwannoma. Case report. *J Neurosurg Sci* 42:245–249
33. Parent M, Beyls-Noel I, Lecomte-Houcke M, Fontaine C, Dupont A (1987) Melanotic schwannoma. Anatomoclinical study of a case and review of the literature (in French). *Arch Anat Cytol Pathol* 35:76–81
34. Paris F, Cabanes J, Munoz C, Tamarit L (1979) Melanotic spinothoracic schwannoma. *Thorax* Apr 34:243–246
35. Parker JB, Marcus PB, Martin JH (1980) Spinal melanotic clear-cell sarcoma: a light and electron microscopic study. *Cancer* 46:718–724
36. Prieto-Rodriguez M, Camanas-Sanz A, Bas T, Cortes B, Vera-Sempere FJ (1998) Psammomatous melanotic schwannoma localized in the mediastinum: diagnosis by fine-needle aspiration cytology. *Diagn Cytopathol* 19:298–302
37. Riffaud L, Morandi X, Massengo S, Carsin-Nicol B, Heresbach N, Guegan Y (2000) MRI of intramedullary spinal schwannomas: case report and review of the literature. *Neuroradiology* 42:275–279
38. Schmitz KJ, Unkel C, Grabellus F, Baba HA, Dirsch O, Neumann A (2005) Melanotic schwannoma of the neck mimicking a malignant melanoma. *Eur Arch Otorhinolaryngol* 262(3):182–185
39. Tawk RG, Tan D, Mechtler L, Fenstermaker RA (2005) Melanotic schwannoma with drop metastases to the caudal spine and high expression of CD117 (c-kit). *J Neurooncol* 71(2):151–156
40. Tiu SC, Choi CH, Shek CC, Ng YW, Chan FK, Ng CM, Kong AP (2005) The use of aldosterone–renin ratio as a diagnostic test for primary hyperaldosteronism and its test characteristics under different conditions of blood sampling. *J Clin Endocrinol Metab* 90(1):72–78
41. Vallat-Decouvelaere AV, Wassef M, Lot G, Catala M, Moussalam M, Caruel N, Mikol J (1999) Spinal melanotic schwannoma : a tumor with poor prognosis. *Histopathology* 35:558–566

42. Watson JC, Stratakis CA, Bryant-Greenwood PK, Koch CA, Kirschner LS, Nguyen T, Carney JA, Oldfield EH (2000) Neurosurgical implications of Carney complex. *J Neurosurg* 92:413–418
43. Wilkes D, Mcdermott DA, Basson CT (2005) Clinical phenotypes and molecular genetic mechanisms of Carney complex. *Lancet Oncol* 6(7):501–508
44. Zhang HY, Yang GH, Chen HJ, Wei B, Ke Q, Guo H, Ye L, Bu H, Yang K, Zhang YH (2005) Clinicopathological, immunohistochemical, and ultrastructural study of 13 cases of melanotic schwannoma. *Chin Med J (Engl)* 118(17):1451–1461
45. Zonenshayn M, Edgar MA, Lavyne MH (2000) Removal of a lumbar melanotic schwannoma via the far-lateral approach in a patient with Carney complex case report. *J Neurosurg* 92:241–245