

Dermatoses of the Glans Penis in Korea: A 10-Year Single Center Experience

Hyang-Suk You¹, Gun-Wook Kim¹, Won-Jeong Kim¹, Je-Ho Mun¹, Margaret Song¹, Hoon-Soo Kim¹, Hyun-Chang Ko^{1,2}, Byung-Soo Kim^{1,2}, Moon-Bum Kim^{1,2}

¹Department of Dermatology, Pusan National University School of Medicine, ²Medical Research Institute, Pusan National University Hospital, Busan, Korea

Background: A variety of infectious, inflammatory, and neoplastic dermatoses can develop on the glans penis, and definitive diagnosis in such cases may be difficult owing to their non-specific symptoms and clinical appearance. Furthermore, data on dermatoses of the glans penis in Korea are limited.

Objective: In the present study, we aimed to determine the prevalence of dermatoses of the glans penis in Korea and provide clinical data to assist in making an accurate diagnosis.

Methods: We retrospectively reviewed the medical records, clinical photographs, and histologic slides of 65 patients with dermatoses of the glans penis that visited the Pusan National University Hospital between January 2004 and August 2013.

Results: Twenty-six types of dermatoses were identified: inflammatory dermatosis was the most common (38/65, 58.5%), followed by infectious (13/65, 20.0%), neoplastic (10/65, 15.4%), and other dermatoses (4/65, 6.2%). The most common dermatosis of the glans penis was seborrheic dermatitis, followed by lichen planus, herpes progenitalis, condyloma accuminatum, erythroplasia of Queyrat, Zoon's balanitis, and psoriasis. In the topographic analysis, the most common type of dermatosis was dermatoses that localized to the glans penis (39/65, 60.0%), followed by dermatoses involving the extra-genitalia and glans penis (22/65, 33.9%), and the genitalia (glans penis plus other genital areas) (4/65, 6.2%).

Conclusion: This study shows the usefulness of a topo-

graphic approach in the diagnosis of dermatoses of the glans penis in Korea. The findings could be used as baseline data for establishing an accurate diagnosis in Koreans. (**Ann Dermatol 28(1) 40~44, 2016**)

-Keywords-

Dermatoses, Korea, Penis

INTRODUCTION

Skin problems related to the glans penis can be of great concern to patients. In Korea, most patients with penile skin problems tend to self-medicate to avoid seeking treatment at a hospital. Physicians, including dermatologists, might not be familiar with penile skin diseases and may find it difficult to establish an accurate diagnosis. In particular, a variety of infectious, inflammatory, and neoplastic dermatoses can affect the glans penis, and may diminish quality of life^{1,2}. Many dermatoses present with similar clinical features; therefore, accumulation of clinical data on the different skin lesions of the glans penis in Korea is needed. In the present study, we aimed to determine the penile dermatoses prevalent in Korea and to provide data for making an accurate clinical diagnosis.

MATERIALS AND METHODS

This retrospective study included patients with dermatoses of the glans penis presenting at the Pusan National University Hospital between January 2004 and August 2013. Skin biopsies were performed in all the enrolled patients, and medical records, clinical photographs, and histology slides were reviewed retrospectively. Clinical data including age, signs, and symptoms were analyzed. Based on

Received January 15, 2015, Revised May 7, 2015, Accepted for publication May 11, 2015

Corresponding author: Moon-Bum Kim, Department of Dermatology, Pusan National Hospital, 179 Gudeok-ro, Seo-gu, Busan 49241, Korea. Tel: 82-51-240-7338, Fax: 82-51-245-9467, E-mail: drkmp@hanmail.net

This is an Open Access article distributed under the terms of the Creative Commons Attribution Non-Commercial License (<http://creativecommons.org/licenses/by-nc/4.0>) which permits unrestricted non-commercial use, distribution, and reproduction in any medium, provided the original work is properly cited.

the clinicopathological findings, the dermatoses were classified into 3 types: inflammatory, infectious, or neoplastic. Dermatoses not belonging to any of the above groups were classified as "other." The dermatoses were also categorized according to the anatomical distribution of the skin lesions: dermatoses localized to the glans penis, dermatoses localized to the genitalia (glans penis and other genital areas), and dermatoses involving the extra-genitalia and glans penis. This study was approved by the Institutional Review Board of the Pusan National University Hospital (No.: E-2014122).

RESULTS

Sixty-five patients with dermatoses of the glans penis were included in the study. All patients were circumcised, except for one patient with a chancroid. The demographic data of all patients are summarized in Table 1. The age range of the patients was 4~77 years (average, 47.5 years). The number of patients affected showed a tendency to increase from the age of 30 years and over. Twenty-three patients (35.4%) presented with an itching problem and 11 patients (16.9%) had pain. Of the features of cutaneous lesions, red scaly patches (32/65, 49.2%)

were the most common, followed by erosion/ulcers (9/65, 13.8%), pigmented papules (6/65, 9.2%), hypopigmentation (6/65, 9.2%), red plaques (4/65, 6.2%), and hyperpigmentation (4/65, 6.2%).

Twenty-six types of dermatoses were identified (Table 2). Of these, inflammatory dermatosis (38/65, 58.5%) was the most common, followed by infectious (13/65, 20.0%), neoplastic (10/65, 15.4%), and other dermatoses (4/65, 6.2%). The most common inflammatory dermatoses were seborrheic dermatitis (12/65, 18.5%), lichen planus (12/65, 18.5%), psoriasis (3/65, 4.6%), and Zoon's balanitis (3/65, 4.6%). The most prevalent infectious dermatoses were condyloma accuminatum (4/65, 6.2%) and herpes progeneritalis (4/65, 6.2%). The most common neoplastic penile lesions were erythroplasia of Queyrat (3/65, 4.6%), melanocytic nevus (2/65, 3.1%), hemangioma (1/65, 1.5%), lymphoma cutis (1/65, 1.5%), lentigo (1/65, 1.5%), squamous cell carcinoma (1/65, 1.5%), and verrucous carcinoma (1/65, 1.5%).

The dermatoses are presented according to anatomical distribution in Fig. 1. Most commonly, the dermatoses were localized on the glans penis (39/65, 60.0%), followed by the extra-genitalia and glans penis (22/65, 33.8%), and the genitalia (glans penis plus other genital areas) (4/65, 6.2%). Of the dermatoses localized to the glans penis, the most common were seborrheic dermatitis (8/39, 20.5%), lichen planus (5/39, 12.8%), erythroplasia of Queyrat (3/39, 7.7%), herpes progeneritalis (3/39, 7.7%), Zoon's balanitis (3/39, 7.7%), chancro (2/39, 5.1%), melanocytic nevus (2/39, 5.1%), and post-inflammatory hyperpigmentation (2/39, 5.1%). Of the dermatoses involving the extra-genitalia and glans penis, the most common was lichen planus (7/22, 31.8%), followed by seborrheic dermatitis (3/22, 13.6%), balanitis circinata (2/22, 9.1%), fixed drug eruption (2/22, 9.1%), and psoriasis (2/22, 9.1%). Of the dermatoses localized to the genitalia (glans penis plus other genital areas), the most common were condyloma accuminatum (3/4, 75.0%) and seborrheic dermatitis (1/4, 25.0%).

Table 1. Clinical data of patients with dermatoses of the glans penis

Data	Number (%)
Circumcision	64 (98.5)
Ten-year age group (yr)	
0~9	1 (1.5)
10~19	1 (1.5)
20~29	5 (7.7)
30~39	14 (21.5)
40~49	17 (26.2)
50~59	10 (15.4)
60~69	7 (10.8)
70~79	10 (15.4)
Symptom	
Pruritus	23 (35.4)
Pain	11 (16.9)
None	31 (47.7)
Clinical manifestation	
Hypopigmentation	6 (9.2)
Hyperpigmentation	4 (6.2)
Red scaly patch	32 (49.2)
Red plaque	4 (6.2)
Erosion and ulcer	9 (13.8)
Red papule	3 (4.6)
Pigmented papule	6 (9.2)
Cyst and nodule	3 (4.6)
Total	65 (100)

DISCUSSION

In Korea, it is not uncommon for patients to have penile glans dermatoses; however physicians dealing with them might not be familiar with these skin conditions because most patients tend to conceal them and avoid seeking treatment. Although there are a variety of dermatoses of the glans penis, their clinical features can be quite similar. Moreover, the glans penis is exposed to external factors such as urine, sexual secretions, condoms, microorganisms, and physical factors that can alter the clinical presentation

Table 2. Dermatoses of the glans penis

	Diagnosis	Number (%)	Age (yr)	
			Range	Average
Inflammatory	Seborrheic dermatitis	12 (18.5)	32~77	54.5
	Lichen planus	12 (18.5)	29~61	40.5
	Psoriasis	3 (4.6)	34~39	36.5
	Zoon's balanitis	3 (4.6)	51~70	60.3
	Balanitis circinata	2 (3.1)	31~56	43.5
	Fixed drug eruption	2 (3.1)	24~35	29.5
	Foreign body granuloma	1 (1.5)	45	45.0
	Lichen sclerosus	1 (1.5)	14	14.0
	Necrobiosis lipoidica	1 (1.5)	59	59.0
	Pityriasis lichenoides chronica	1 (1.5)	38	38.0
Infectious	Condyloma accuminatum	4 (6.2)	29~57	45.0
	Herpes progenerialis	4 (6.2)	47~75	68.3
	Charcre	2 (3.1)	42~75	58.5
	Scabietic nodule	1 (1.5)	22	22.0
	Syphilid	1 (1.5)	37	37.0
	Tuberculosis	1 (1.5)	42	42.0
	Neoplastic	Erythroplasia of Queyrat	3 (4.6)	72~79
Melanocytic nevus		2 (3.1)	24~32	28.0
Hemangioma		1 (1.5)	4	4.0
Lentigine		1 (1.5)	71	71.0
Lymphoma cutis		1 (1.5)	72	72.0
Squamous cell carcinoma		1 (1.5)	34	34.0
Verrucous carcinoma		1 (1.5)	54	54.0
Others	Postinflammatory hyperpigmentation	2 (3.1)	48~58	53.0
	Porokeratosis of Mibelli	1 (1.5)	48	48.0
	Vitiligo	1 (1.5)	41	41.0
Total		65 (100)	4~77	47.5

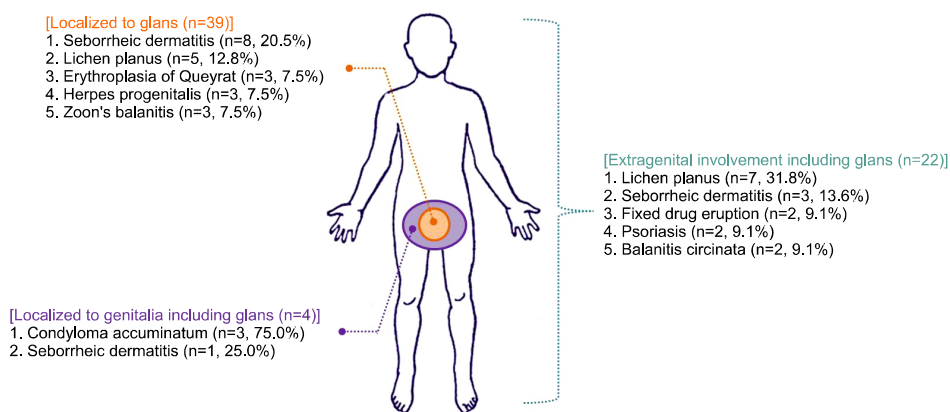


Fig. 1. Dermatoses localized only to the glans penis, dermatoses localized to the genitalia (glans penis plus other genital areas), and dermatoses involving the extra-genitalia and glans penis.

of these dermatoses. There have been no comprehensive studies of glans penis dermatoses in Korea and clinical data are needed. Hence, we attempted to document the types of dermatoses of the glans penis prevalent in Korea in order to accumulate clinical data.

A recent study has reported that the rate of circumcision in a given population has a strong impact on the occurrence

of the dermatoses of the glans penis³. Mallon et al.⁴ showed that skin infections and inflammatory skin diseases including psoriasis, seborrheic dermatitis, lichen planus, and contact dermatitis are more common in uncircumcised individuals. A surprisingly high circumcision rate is observed in South Korea, with a rate of >90% in the 14~29-year age group⁵. In the present study, all patients with

dermatoses of the glans penis were circumcised, except for one patient who presented with chancroid. More detailed studies are needed to understand the association between the prevalence of penile dermatoses and circumcision rates in Korea.

The age incidence by decade tended to increase from the age of 30 years and over. This could be due to the following reasons: (1) the number of cases of congenital abnormalities was extremely low in this study, (2) sexual activities begin to increase from early and middle adulthood, (3) inflammatory dermatoses such as lichen planus and seborrheic dermatitis usually occur between the 30 and 60 years of age, and (4) many neoplastic dermatoses are commonly seen in the elderly. Furthermore, more than half of the patients presented with itching or pain. The dermatoses of the glans penis exhibited a variety of cutaneous signs, but red scaly patches were the most common and were found in various dermatoses such as seborrheic dermatitis, psoriasis, lichen planus, erythroplasia of Queyrat, and Zoon's balanitis. Although patients presented with

dermatologic symptoms and signs, many dermatoses of the glans penis, except for neoplastic dermatoses and condyloma accuminatum, had similar symptoms. Therefore, dermatologists should always be alert to diagnose these patients based on patient history and careful examination. The range of histopathological diagnoses is broad despite the similarities in clinical manifestations. In the present study, 32 patients (49.2%) showed discordance between the clinical and histological diagnoses. This could be due to the similar clinical appearance among various penile dermatoses (Fig. 2), while the diagnosis was confirmed mainly by examining biopsy samples.

In this study, inflammatory dermatoses were most prevalent followed by infectious and neoplastic dermatoses. Another study on the prevalence of penile dermatoses reported that infectious dermatosis was the most common type, followed by papulosquamous dermatoses, dermatitis, drug reactions, and neoplasms⁶. The most common dermatosis of the glans penis in the present study was seborrheic dermatitis, followed by lichen planus, herpes

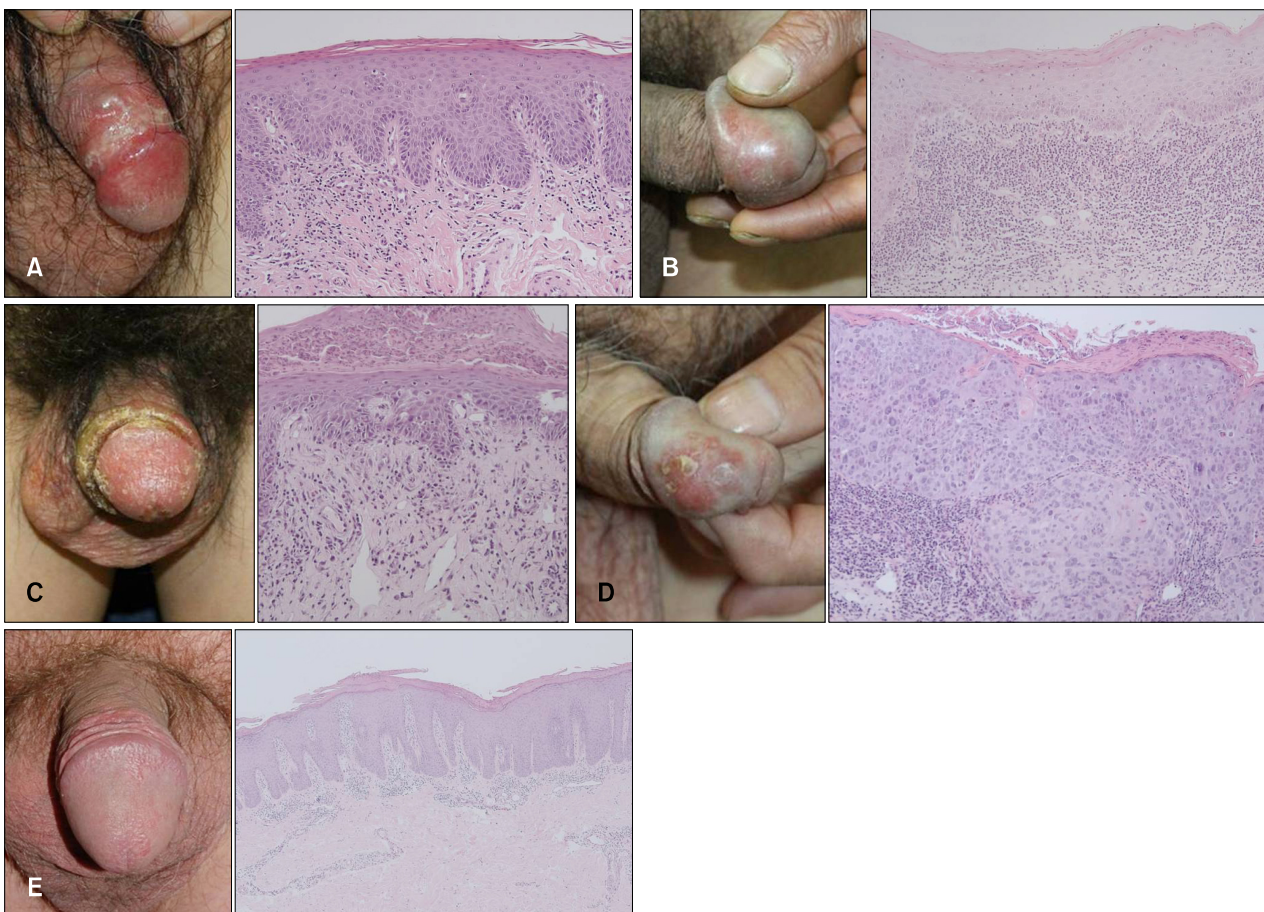


Fig. 2. Dermatoses of glans penis showing a similar clinical appearance and histopathology findings. (A) Seborrheic dermatitis (H&E, $\times 100$), (B) Zoon's balanitis ($\times 100$), (C) Syphilis ($\times 100$), (D) Erythroplasia of Queyrat ($\times 200$), and (E) Psoriasis ($\times 40$).

progenitalis, condyloma accuminatum, erythroplasia of Queyrat, Zoon's balanitis, and psoriasis. Hillman et al.⁶ reported that the most common histopathological diagnosis in a study of 60 patients with penile dermatoses was non-specific dermatitis followed by condyloma accuminatum, lichen sclerosus, and lichen planus. The prevalence of seborrheic dermatitis and lichen planus in this study was significantly lower than that in the present study. We hypothesize that this difference may be attributable to the inclusion of patients with mild seborrheic dermatitis as well as ethnic, environmental, socio-economic, and sexual factors. However, the reason for this difference could not be confirmed because of the limited data on the prevalence of dermatoses of the glans penis recorded over 10 years of investigation in the present study.

The clinical approach in the diagnosis of male genital dermatoses involves a thorough assessment of medical and family history, and physical examination. It is helpful to consider a topographic approach for accurate differential diagnoses. The most prevalent dermatoses localized to the glans penis and genitalia were seborrheic dermatitis and lichen planus. The high prevalence of seborrheic dermatitis can be explained by the fact that seborrhea has a predilection for the glans penis and the penile shaft⁷. Similarly, lichen planus often affects the genital mucosa including the glans penis as the initial or sole manifestation⁸. Several reports have also cited the isolated occurrence of lichen planus on the glans penis^{9,10}. Therefore, dermatologists should strongly consider seborrheic dermatitis and lichen planus in the differential diagnosis of patients with inflammatory dermatosis localized at the glans penis. Twenty-two patients (32.8%) with dermatoses of the glans penis showed extra-genital skin lesions, which commonly included lichen planus, seborrheic dermatitis, fixed drug

eruptions, psoriasis, and vitiligo. The topographic predilection of lichen planus, psoriasis, and vitiligo could be related to the Koebner phenomenon and the usual tendency for the generalized distribution of these skin manifestations. Although the sample size of this study was small, to our knowledge, this was the first study describing prevalent dermatoses of the glans penis in Korea. Our findings provide useful clinical data for the diagnoses of penile glans dermatoses and serve as a basis for further studies.

REFERENCES

1. English JC 3rd, Laws RA, Keough GC, Wilde JL, Foley JP, Elston DM. Dermatoses of the glans penis and prepuce. *J Am Acad Dermatol* 1997;37:1-24.
2. Singh S, Bunker C. Male genital dermatoses in old age. *Age Ageing* 2008;37:500-504.
3. Parker SW, Stewart AJ, Wren MN, Gollow MM, Straton JA. Circumcision and sexually transmissible disease. *Med J Aust* 1983;2:288-290.
4. Mallon E, Hawkins D, Dinneen M, Francics N, Fearfield L, Newson R, et al. Circumcision and genital dermatoses. *Arch Dermatol* 2000;136:350-354.
5. Kim D, Koo SA, Pang MG. Decline in male circumcision in South Korea. *BMC Public Health* 2012;12:1067.
6. Hillman RJ, Walker MM, Harris JR, Taylor-Robinson D. Penile dermatoses: a clinical and histopathological study. *Genitourin Med* 1992;68:166-169.
7. Eichmann AR. Dermatoses of the male genital area. *Dermatology* 2005;210:150-156.
8. Buechner SA. Common skin disorders of the penis. *BJU Int* 2002;90:498-506.
9. Karthikeyan K, Jeevankumar B, Thappa DM. Bullous lichen planus of the glans penis. *Dermatol Online J* 2003;9:31.
10. Alinovi A, Barella PA, Benoldi D. Erosive lichen planus involving the glans penis alone. *Int J Dermatol* 1983; 22:37-38.