

[ CASE REPORT ]

## Systemic Sarcoidosis Associated with Certolizumab Pegol Treatment for Rheumatoid Arthritis: A Case Report and Review of the Literature

Keigo Koda<sup>1</sup>, Mikio Toyoshima<sup>1</sup>, Tsuyoshi Nozue<sup>1</sup> and Takafumi Suda<sup>2</sup>

### Abstract:

A 69-year-old woman presented with appetite loss, fatigue, and a low-grade fever. She had been receiving certolizumab pegol for rheumatoid arthritis for six years. Computed tomography of the chest showed multiple micronodules in both lungs and bilateral hilar and mediastinal lymphadenopathy. An ophthalmic examination showed the findings of uveitis. Lymphocytosis with an increased CD4/CD8 ratio was seen in the bronchoalveolar lavage fluid. Video-assisted thoracoscopic biopsy specimens obtained from the right lung and a right hilar lymph node showed noncaseous epithelioid cell granulomas. Anti-tumor necrosis factor- $\alpha$ -induced sarcoidosis was diagnosed, and she was successfully treated with cessation of certolizumab pegol and systemic corticosteroid therapy.

**Key words:** sarcoidosis, anti-tumor necrosis factor- $\alpha$  agent, certolizumab pegol

(Intern Med 59: 2015-2021, 2020)

(DOI: 10.2169/internalmedicine.4275-19)

### Introduction

Sarcoidosis is a systemic granulomatous disease of unknown etiology, and most patients are asymptomatic and do not require treatment. However, some patients with symptomatic, active sarcoidosis require immunosuppressive treatment, such as methotrexate and anti-tumor necrosis factor- $\alpha$  (TNF- $\alpha$ ) agents, in addition to systemic corticosteroid treatment (1, 2). Further complicating matters is the fact that previous reports have shown that anti-TNF- $\alpha$  treatment can also induce sarcoidosis and/or a sarcoid-like reaction in patients with autoimmune diseases such as rheumatoid arthritis (RA), psoriatic arthritis (PsA), ankylosing spondylitis (AS), and inflammatory bowel diseases (IBD) (3-68). In addition, information on the clinical features and the pathogenesis of anti-TNF- $\alpha$  agent-induced sarcoidosis is still limited (69).

A case of sarcoidosis occurring during certolizumab pegol (CZP) treatment in a patient with rheumatoid arthritis is presented, and the clinical features and pathogenesis of anti-TNF- $\alpha$  agent-induced sarcoidosis are discussed along with a

review of the English-language literature.

### Case Report

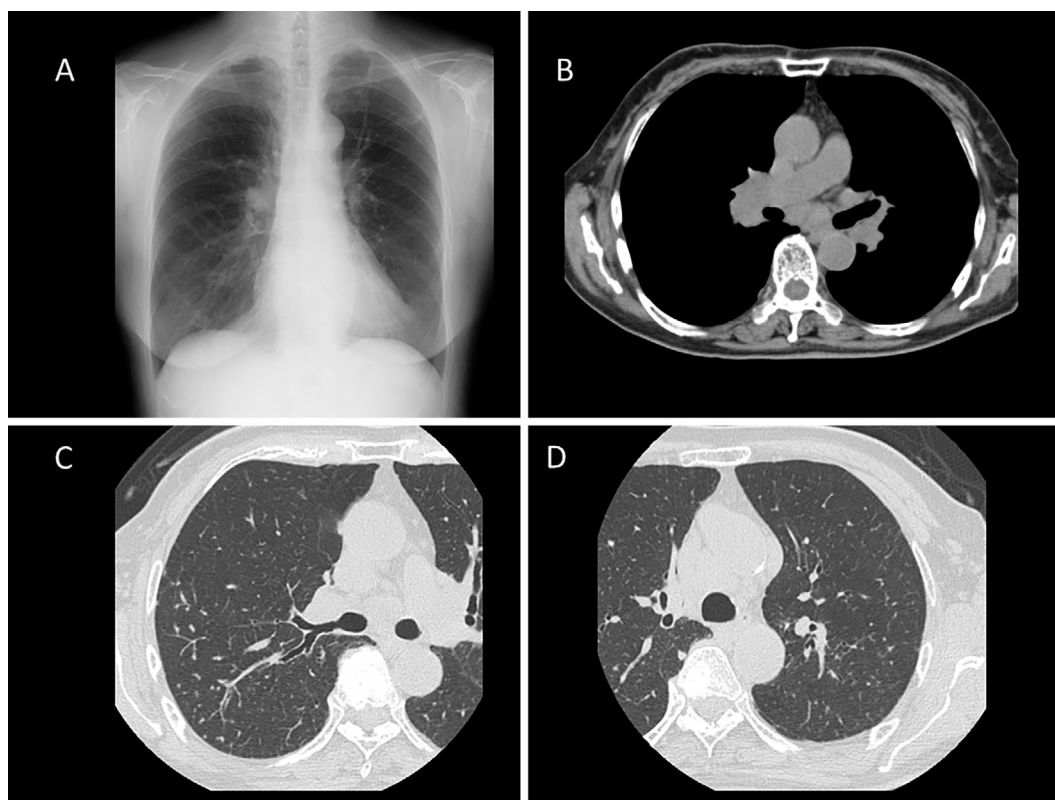
A 69-year-old woman with a 1-month history of appetite loss, general fatigue, and a low-grade fever was referred to our hospital for a detailed examination. She had never smoked. Her history included rheumatoid arthritis since 60 years old. She did not have a history of tuberculosis. She was then treated with salazosulfapyridine and low-dose oral corticosteroids, and her polyarthralgia resolved. However, two years later, because of worsening of polyarthritits, adalimumab was initiated, and her symptoms resolved with discontinuation of systemic corticosteroids. One year later, adalimumab was switched to etanercept because of an injection site reaction, and six months later, etanercept was switched to CZP because her polyarthritits had not improved sufficiently. She had been receiving CZP treatment for six years, and her RA activity decreased.

The results of a whole blood IFN- $\gamma$  release assay for *Mycobacterium tuberculosis* antigens before the initiation of

<sup>1</sup>Department of Respiratory Medicine, Hamamatsu Rosai Hospital, Japan and <sup>2</sup>Second Department of Internal Medicine, Hamamatsu University School of Medicine, Japan

Received: November 29, 2019; Accepted: March 16, 2020; Advance Publication by J-STAGE: May 8, 2020

Correspondence to Dr. Mikio Toyoshima, mi-toyoshima@hamamatsuh.johas.go.jp



**Figure 1.** A chest radiograph taken at the first visit to our hospital showing bilateral hilar lymphadenopathy (A). Computed tomography of the chest showing bilateral hilar and mediastinal lymphadenopathy (B) and multiple micronodules distributed predominantly in both upper lobes (C, D).

adalimumab were negative. On admission, her temperature was 37.4°C. A physical examination showed ulnar deviation of the fingers of both hands. There were no abnormalities on chest auscultation, and superficial lymph node swelling and skin eruptions were not evident.

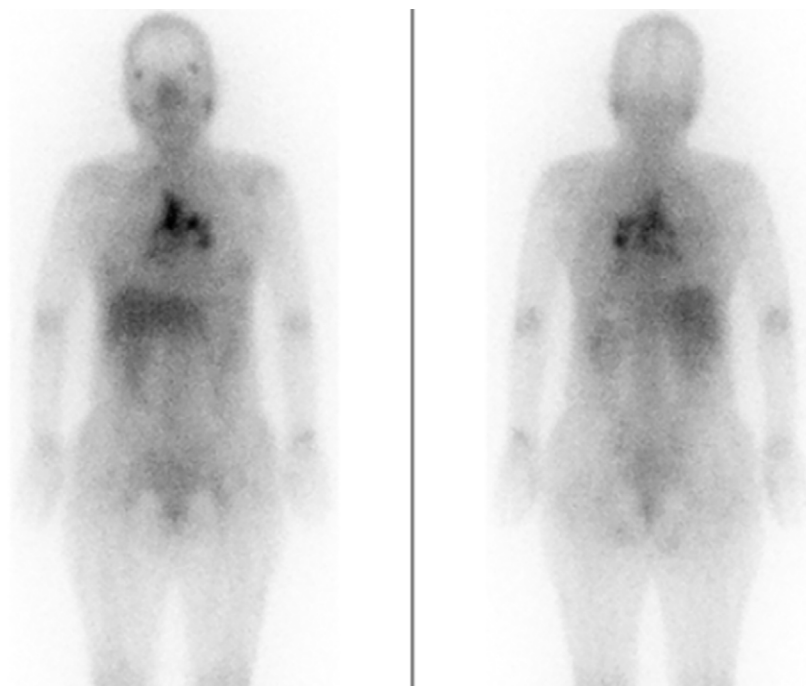
The laboratory data showed an elevated serum level of rheumatoid factor (40 IU/mL). Serum levels of C-reactive protein, anti-cyclic citrullinated peptide antibody, and angiotensin converting enzyme were normal. Hypoxemia was not evident on an arterial blood gas analysis. The results of respiratory function testing were as follows: vital capacity 1.64 L (75.9% predicted), forced vital capacity 1.60 L (74.1% predicted), forced expiratory volume in 1 second 1.30 L (86.7% predicted), and diffusion capacity of the lung for carbon monoxide 8.42 mL/min/mmHg (67.7% predicted).

The electrocardiogram and echocardiogram findings were normal. She denied any ocular symptoms, but an ophthalmic examination showed findings of granulomatous uveitis, such as corner nodules and snowball opacities of vitreous bodies, in both eyes. A chest radiograph showed bilateral hilar lymphadenopathy (Fig. 1A). Computed tomography (CT) of the chest showed bilateral hilar and mediastinal lymphadenopathy (Fig. 1B) and multiple micronodules distributed predominantly in both upper lobes (Fig. 1C, D). No findings of old pulmonary tuberculosis were evident on chest CT. Gallium (Ga) scintigraphy showed an increased uptake of <sup>68</sup>Ga in the bilateral hilar and mediastinal lymph nodes (Fig. 2).

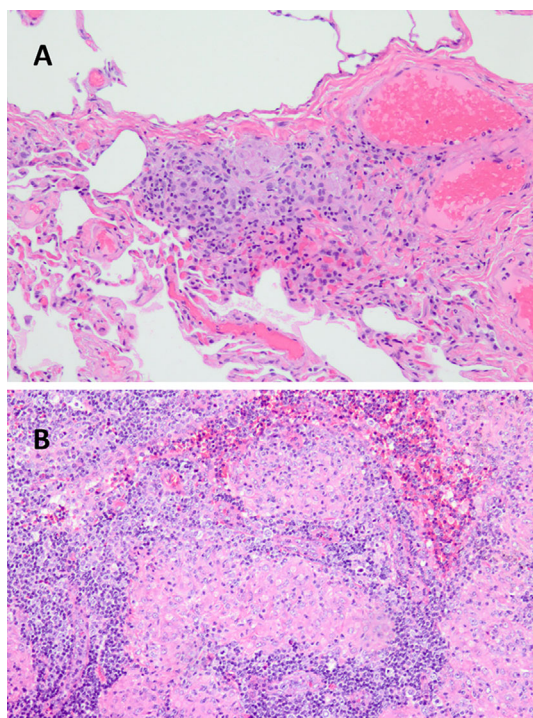
A bronchoalveolar lavage fluid (BALF) analysis showed a cell count of  $2.43 \times 10^5$  mL, with a cell differential of 68.0% macrophages, 25.0% lymphocytes, and 1.0% neutrophils, and a CD4/CD8 ratio of 99.0. No microorganisms, including *Mycobacteria* and *Propionibacterium acnes*, were detected on BALF culture. A transbronchial lung biopsy specimen obtained from the right upper lobe showed no significant findings.

On suspicion of sarcoidosis associated with an anti-TNF- $\alpha$  agent and to exclude malignancies such as anti-TNF- $\alpha$  agent-associated malignant lymphoma, since she had systemic symptoms that are not usually seen in sarcoidosis, and uveitis is known to be an ocular manifestation of malignant lymphoma, a video-assisted thoracoscopic biopsy was performed. Specimens obtained from the right upper lobe (Fig. 3A) and a right hilar lymph node (Fig. 3B) showed noncaseous epithelioid cell granulomas consistent with sarcoidosis. Gram staining of lung and hilar lymph node specimens did not show any bacteria. Tissue cultures of lung and hilar lymph node specimens grew no microorganisms, including *Mycobacteria* and *P. acnes*. While awaiting the pathological results of the video-assisted thoracoscopic biopsy, she noticed a subcutaneous nodule in her right knee; a biopsy specimen obtained of the subcutaneous nodule also showed noncaseous epithelioid cell granulomas.

Based on the diagnosis of sarcoidosis associated with an anti-TNF- $\alpha$  agent, CZP was discontinued, and systemic corticosteroid therapy with oral prednisolone (20 mg per day)



**Figure 2.** Gallium (Ga) scintigraphy showing an increased uptake of  $^{68}\text{Ga}$  in the bilateral hilar and mediastinal lymph nodes.



**Figure 3.** Biopsy specimens obtained from the right upper lobe (A, Hematoxylin and Eosin staining,  $\times 200$ ) and a right hilar lymph node (B,  $\times 100$ ) showing noncaseous epithelioid cell granulomas.

was started because she was exhausted due to prolonged systemic symptoms, although discontinuation of CZP without systemic corticosteroid therapy was considered first. She then became asymptomatic, and the radiological findings and restrictive and gas transfer impairments on respiratory

function testing improved, as well as the ophthalmic findings and the subcutaneous nodule of her right knee. Six months later, prednisolone was tapered to 10 mg daily without recurrence of sarcoidosis. Her RA is controlled with abatacept treatment. While paying attention to worsening of her RA, we are considering further prednisolone tapering.

## Discussion

Recently, anti-TNF- $\alpha$  agents have been used for the treatment of severe/refractory sarcoidosis despite potential adverse effects and the lack of unequivocal evidence of their efficacy in clinical trials (1, 2). However, cases of sarcoidosis in patients with autoimmune diseases who were receiving anti-TNF- $\alpha$  agents have been reported (3-68). TNF- $\alpha$ , which is released by alveolar macrophages, is known to play an important role in promoting inflammation and Th1-driven granuloma formation and propagation (1). The pathogenesis by which anti-TNF- $\alpha$  agents induce sarcoidosis and the clinical features of anti-TNF- $\alpha$  agent-induced sarcoidosis have not been fully clarified. Therefore, previously reported cases of anti-TNF- $\alpha$  agent-induced sarcoidosis were identified using the PubMed search term “sarcoidosis, sarcoid reaction, tumor necrosis factor, and TNF” and reviewed.

A total of 85 previously reported cases of anti-TNF- $\alpha$  agent-induced sarcoidosis were found (3-68). The clinical features of these cases are summarized in Table. The subjects included 30 men and 55 women, with a mean age of 49.5 years old, ranging in age from 6 to 81 years old. Most underlying diseases for which anti-TNF- $\alpha$  agents were administered were RA, followed by PsA, AS, and IBD. More than half of the patients had been receiving etanercept, fol-

**Table. Reported Cases of Anti-TNF- $\alpha$  Agents-induced Sarcoidosis.**

Age (y)	49.5 (6-81)*
Sex (male/female)	30/55**
Underlying diseases (RA/PsA/AS/IBD/JRA/Others)	38/14/11/8/6/6**
Anti-TNF- $\alpha$ agents (etanercept/adalimumab/infliximab/certolizumab pegol)	45/21/17/2**
Duration of anti-TNF- $\alpha$ agent treatment (months)	18 (1-84)*
Involved organs	
One organ (lung:L/hilar and mediastinal lymphnodes:H/skin:S/eye:E/other site:O)	2/ 4/ 9/ 1/4**
Two organs (L+H/L+S/H+S/H+E/H+O/S+E/S+O/E+O/O)	21/ 2/ 5/ 3/ 1/ 3/1/1/2**
Three organs (L+H+S/ H+S+E/ L+O/ L+H+Heart/ L+H+O/ H+E+O/ H+O/ H+S+O/O)	9/ 1/ 1/ 1/ 1/1/ 3/ 1/ 2**
Four or more organs (L+H+S+E/ L+H+S+O/ H+O/ H+S+O/ O)	2/ 2/ 1/ 1**
Treatment (discontinuation of anti-TNF- $\alpha$ agent without SC/ discontinuation of anti-TNF- $\alpha$ agent with SC/continuation of anti-TNF- $\alpha$ agent with SC/switching to other anti-TNF- $\alpha$ agent/NA)	38/ 33/ 9/ 2/ 3**
Outcome (resolved/stable/NA)	81/3/1**

TNF: tumor necrosis factor, RA: Rheumatoid arthritis, PsA: Psoriatic arthritis, AS: Ankylosing spondylitis, IBD: Inflammatory bowel diseases, JRA: Juvenile rheumatoid arthritis, Others: spondyloarthropathy, psoriasis vulgaris, SAPHO syndrome, polymyalgia rheumatica, plaque psoriasis, other site: lymphnodes except hilar and mediastinal lymphnodes, muscle, kidney, nervous system, bone marrow, parotid gland, salivary gland, tongue, pharynx, liver, colon, SC: systemic corticosteroid treatment, NA: not available, \*: data expressed as means (range), \*\*: data expressed as numbers of cases

lowed by adalimumab and infliximab. Only two patients had been receiving CZP. Patients who had CZP-induced sarcoidosis had single-organ involvement, such as uveitis and cutaneous lesions (52, 67). The present case is the first case of CZP-induced typical systemic sarcoidosis.

The mean duration of anti-TNF- $\alpha$  agent treatment before the onset of sarcoidosis was 18 months, ranging from 1 to 84 months. In the present case, sarcoidosis developed six years after switching from etanercept to CZP. The differences in the characteristics of these two drugs, such as their immunogenicity (70), which are described below, may have been involved in the development of sarcoidosis in the present case. Thirty-six of the 85 patients with anti-TNF- $\alpha$  agent-induced sarcoidosis had cutaneous involvement, while only 1 of the 85 patients had cardiac involvement (55). In ordinary sarcoidosis, which is not related to anti-TNF- $\alpha$  agent treatment, cutaneous involvement is seen in up to one-third of patients, and the frequency of cardiac involvement ranges from 1% to 23% (2). It appears that cutaneous involvement is more common and cardiac involvement less common in anti-TNF- $\alpha$  agent-induced sarcoidosis than in ordinary sarcoidosis. However, because the reported number of anti-TNF- $\alpha$  agent-induced sarcoidosis cases is too small compared to ordinary sarcoidosis cases, these observations remain inconclusive.

In 71 of the 85 cases with anti-TNF- $\alpha$  agent-induced sarcoidosis, the anti-TNF- $\alpha$  agents were discontinued, and the sarcoidosis resolved in 36 cases, but it remained stable in 2 cases. The other 33 cases required systemic corticosteroid treatment, and the sarcoidosis resolved in 32 cases, but it remained stable in 1 case. In 9 of the 85 patients, the anti-TNF- $\alpha$  agents were continued with systemic corticosteroid treatment, and the sarcoidosis improved in all 9 cases (7, 12, 18, 22, 24, 39, 46, 50, 57). In two cases in which sarcoidosis developed during etanercept treatment, switching from etanercept to adalimumab resulted in regression of sarcoido-

sis (36, 45). Given these observations, anti-TNF- $\alpha$  agent-induced sarcoidosis appears to be manageable with discontinuation of the anti-TNF- $\alpha$  agents with or without systemic corticosteroid treatment in most cases. If anti-TNF- $\alpha$  agents are indispensable for the treatment of underlying autoimmune diseases, anti-TNF- $\alpha$  agents can be continued with systemic corticosteroid treatment, and etanercept-induced sarcoidosis may be resolved by switching to other anti-TNF- $\alpha$  agents. However, further investigations are needed to confirm this notion, as the number of such cases is too small.

The pathogenesis of anti-TNF- $\alpha$  agent-induced sarcoidosis is not fully understood. However, several mechanisms based on the different biological properties of anti-TNF- $\alpha$  agents have been suggested. First, etanercept consists of soluble TNF- $\alpha$  receptors, while other anti-TNF- $\alpha$  agents are monoclonal antibodies. Soluble TNF- $\alpha$  receptors bind only to the soluble form and do not induce cytotoxic complement-induced lysis of cells expressing membrane-linked TNF- $\alpha$ , whereas anti-TNF- $\alpha$  antibodies bind to both soluble and membrane forms of TNF- $\alpha$  and can cause cytotoxic complement-induced cell lysis. In addition, the partial neutralization of TNF- $\alpha$  by etanercept results in the redistribution of bioavailable TNF- $\alpha$  into sites with lower concentrations, such as the lung (61), because synovial macrophages, which do not lyse under etanercept treatment, can continue to secrete TNF- $\alpha$ . Thus, the concentration of TNF- $\alpha$  in uninvolved sites may reach the same degree as in involved sites, resulting in granuloma formation on etanercept treatment. Furthermore, infliximab inhibits interferon (IFN)- $\gamma$  expression, which is important in granuloma formation, as well as TNF- $\alpha$ , while etanercept does not (71). The facts that most cases of anti-TNF- $\alpha$  agent-induced sarcoidosis are induced by etanercept and that switching from etanercept to adalimumab resulted in regression of sarcoidosis in two cases support these hypotheses. In addition, cases of sarcoidosis induced by golimumab, which has higher affinity for

TNF- $\alpha$  and lower rates of neutralizing antibodies formation and can neutralize it more completely than other anti-TNF- $\alpha$  antibodies (70, 72), have never been reported.

Second, TNF- $\alpha$  can activate nuclear factor (NF)- $\kappa$ B in leukocytes, which results in leukocyte recruitment during the onset of inflammation and the induction of apoptosis during the resolution of inflammation. Reduced apoptosis caused by anti-TNF- $\alpha$  agents such as infliximab may lead to the development of sarcoidosis (70). Furthermore, it has been reported that TNF- $\alpha$  usually inhibits transforming growth factor (TGF)- $\beta$ , which can inhibit the production of Th1 cytokines such as IFN- $\gamma$  and interleukin-12, but inhibition of NF- $\kappa$ B by anti-TNF- $\alpha$  agents can paradoxically suppress the production of TGF- $\beta$ , leading to increased Th1 cytokines and, causing sarcoidosis (70). CZP is a recombinant, polyethylene glycolylated, antigen-binding fragment of a humanized monoclonal antibody that selectively targets and neutralizes TNF- $\alpha$ , and it is essentially different from other anti-TNF- $\alpha$  agents because it is not a full antibody and does not include an Fc portion that may be immunogenic (52). Therefore, CZP cannot induce cytotoxic complement-induced cell lysis, similar to etanercept. This phenomenon may be involved in the mechanisms underlying the development of sarcoidosis induced by CZP. As another possibility, it is thought that neutralizing antibodies to CZP may be involved in the development of sarcoidosis through insufficient TNF- $\alpha$  blockade (70), although serum titers of neutralizing antibodies to CZP were not measured in the present case. However, further investigations will be needed to clarify the precise pathogenesis of CZP-induced sarcoidosis.

This case study has some limitations. First, in this article, single case reports and case series of anti-TNF- $\alpha$  agents-induced sarcoidosis were reviewed. Therefore, the actual situation of anti-TNF- $\alpha$  agents-induced sarcoidosis may differ from the results of the literature review due to reporting bias. The actual number of cases of anti-TNF- $\alpha$  agent-induced sarcoidosis is thought to be more than the number of reported cases (73, 74). Second, immunohistochemical staining of lung and hilar lymph node tissue for *P. acnes* was not performed in the present case. Therefore, possible involvement of *P. acnes* in the development of sarcoidosis in the present case cannot be fully excluded, although *P. acnes* did not grow from BALF and lung and hilar lymph node tissue cultures.

In conclusion, the first case of typical systemic sarcoidosis during CZP treatment for RA was reported. A review of English-language case reports of anti-TNF- $\alpha$  agent-induced sarcoidosis showed that the clinical features of anti-TNF- $\alpha$  agent-induced sarcoidosis, such as the frequency of involved organs, may be different from those of ordinary sarcoidosis, and discontinuation of anti-TNF- $\alpha$  agents with or without systemic corticosteroid treatment will result in regression of sarcoidosis in most cases. To clarify the precise pathogenesis of anti-TNF- $\alpha$  agent-induced sarcoidosis, further investigations are needed.

**The authors state that they have no Conflict of Interest (COI).**

## References

- Patterson KC, Chen ES. The pathogenesis of pulmonary sarcoidosis and implications for treatment. *Chest* **53**: 1432-1442, 2018.
- Ungprasert P, Ryu JH, Matteson EL. Clinical manifestations, diagnosis, and treatment of sarcoidosis. *Mayo Clin Proc Innov Qual Outcomes* **3**: 358-375, 2019.
- Peno-Green L, Lluberas G, Kingsley T, Brantley S. Lung injury linked to etanercept therapy. *Chest* **122**: 1858-1860, 2002.
- Hashkes PJ, Shajrawi I. Sarcoid-related uveitis occurring during etanercept therapy. *Clin Exp Rheumatol* **21**: 645-646, 2003.
- González-López MA, Blanco R, González-Vela MC, Fernández-Llaca H, Rodríguez-Valverde V. Development of sarcoidosis during etanercept therapy. *Arthritis Rheum* **55**: 817-820, 2006.
- O'Shea FD, Marras TK, Inman RD. Pulmonary sarcoidosis developing during infliximab therapy. *Arthritis Rheum* **55**: 978-981, 2006.
- Almodóvar R, Izquierdo M, Zarco P, Javier Quirós F, Mazzucchelli R, Steen B. Pulmonary sarcoidosis in a patient with ankylosing spondylitis treated with infliximab. *Clin Exp Rheumatol* **25**: 99-101, 2007.
- Bachmeyer C, Blum L, Petitjean B, Kemiche F, Pertuiset E. Granulomatous tattoo reaction in a patient treated with etanercept. *J Eur Acad Dermatol Venereol* **21**: 550-552, 2007.
- Kudrin A, Chilvers ER, Ginawi A, et al. Sarcoid-like granulomatous disease following etanercept treatment for RA. *J Rheumatol* **34**: 648-649, 2007.
- Farah RE, Shay MD. Pulmonary sarcoidosis associated with etanercept therapy. *Pharmacotherapy* **10**: 1446-1448, 2007.
- Verschueren K, Van Essche E, Verschueren P, Taelman V, Westhovens R. Development of sarcoidosis in etanercept-treated rheumatoid arthritis patients. *Clin Rheumatol* **26**: 1969-1971, 2007.
- Sturfelt G, Christensson B, Bynke G, Saxne T. Neurosarcoidosis in a patient with rheumatoid arthritis during treatment with infliximab. *J Rheumatol* **34**: 2313-2314, 2007.
- Toussiroit E, Pertuiset E, Kantelip B, Wendling D. Sarcoidosis occurring during anti-TNF-alpha treatment for inflammatory rheumatic diseases: report of two cases. *Clin Exp Rheumatol* **26**: 471-475, 2008.
- Dubosc AE, Perroud AM, Bagot M, et al. Cutaneous granulomas during infliximab therapy for spondyloarthropathy. *J Rheumatol* **35**: 1222-1223, 2008.
- Ishiguro T, Takayanagi N, Kurashima K, et al. Development of sarcoidosis during etanercept therapy. *Intern Med* **47**: 1021-1025, 2008.
- Metyas SK, Tadros RM, Arkfeld DG. Adalimumab-induced non-caseating granuloma in the bone marrow of a patient being treated for rheumatoid arthritis. *Rheumatol Int* **29**: 437-439, 2009.
- Suzuki J, Goto H. Uveitis associated with sarcoidosis exacerbated by etanercept therapy. *Jpn J Ophthalmol* **53**: 439-440, 2009.
- Daïen CI, Monnier A, Claudepierre P, et al. Sarcoid-like granulomatosis in patients treated with tumor necrosis factor blockers: 10 cases. *Rheumatology (Oxford)* **48**: 883-886, 2009.
- Samimi M, Lorette G, Machel L, de Muret A, Watier H, Maruani A. Facial granulomatous nodules during etanercept treatment for psoriasis. *Int J Dermatol* **48**: 1025-1027, 2009.
- van der Stoep D, Braunstahl GJ, van Zeben J, Wouters J. Sarcoidosis during anti-tumor necrosis factor-alpha therapy: no relapse after rechallenge. *J Rheumatol* **36**: 2847-2848, 2009.
- Josse S, Klemmer N, Moreno-Swirc S, Goëb V, Lequerré T, Vittecoq O. Infliximab induced skin and pulmonary sarcoidosis in a rheumatoid arthritis patient. *Joint Bone Spine* **76**: 718-719,

- 2009.
22. Takatori S, Kamata Y, Murosaki T, Iwamoto M, Minota S. Abrupt development of sarcoidosis with a prodromal increase in plasma osteopontin in a patient with rheumatoid arthritis during treatment with etanercept. *J Rheumatol* **37**: 210-211, 2010.
  23. Massara A, Cavazzini L, La Corte R, Trotta F. Sarcoidosis appearing during anti-tumor necrosis factor alpha therapy: a new “class effect” paradoxical phenomenon. Two case reports and literature review. *Semin Arthritis Rheum* **39**: 313-319, 2010.
  24. Dhaille F, Viseux V, Caudron A, et al. Cutaneous sarcoidosis occurring during anti-TNF-alpha treatment: report of two cases. *Dermatology* **220**: 234-237, 2010.
  25. Takahashi H, Kaneta K, Honma M, et al. Sarcoidosis during infliximab therapy for Crohn’s disease. *J Dermatol* **37**: 471-474, 2010.
  26. Clementine RR, Lyman J, Zakem J, Mallepalli J, Lindsey S, Quinet R. Tumor necrosis factor-alpha antagonist-induced sarcoidosis. *J Clin Rheumatol* **16**: 274-279, 2010.
  27. Pink AE, Fonia A, Smith CH, Barker JN. The development of sarcoidosis on antitumor necrosis factor therapy: a paradox. *Br J Dermatol* **163**: 648-649, 2010.
  28. Cuchacovich R, Hagan J, Khan T, Richert A, Espinoza LR. Tumor necrosis factor-alpha (TNF- $\alpha$ )-blockade-induced hepatic sarcoidosis in psoriatic arthritis (PsA): case report and review of the literature. *Clin Rheumatol* **30**: 133-137, 2011.
  29. Kanellopoulou T, Filiotou A, Kranidioti H, Dourakis SP. Sarcoid-like granulomatosis in patients treated with anti-TNF $\alpha$  factors. A case report and review of the literature. *Clin Rheumatol* **30**: 581-583, 2011.
  30. Salvatierra J, Magro-Checa C, Rosales-Alexander JL, Raya-Alvarez E. Acute sarcoidosis as parotid fever in rheumatoid arthritis under anti-tumor necrosis factor-alpha therapy. *Rheumatology (Oxford)* **50**: 1346-1348, 2011.
  31. Haroon M, Ryan JG, Harney S. Development of sarcoidosis 6-month post discontinuation of etanercept: coincidence or real association? *Clin Rheumatol* **30**: 1095-1098, 2011.
  32. Marcella S, Welsh B, Foley P. Development of sarcoidosis during adalimumab therapy for chronic plaque psoriasis. *Australas J Dermatol* **52**: e8-e11, 2011.
  33. Tong D, Manolios N, Howe G, Spencer D. New onset sarcoid-like granulomatosis developing during anti-TNF therapy: an under-recognized complication. *Intern Med J* **42**: 89-94, 2012.
  34. Fonollosa A, Artaraz J, Les I, et al. Sarcoid intermediate uveitis following etanercept treatment: a case report and review of the literature. *Ocul Immunol Inflamm* **20**: 44-48, 2012.
  35. Seve P, Varron L, Broussolle C, Denis P, Kodjikian L. Sarcoid-related uveitis occurring during adalimumab therapy. *Ocul Immunol Inflamm* **20**: 59-60, 2012.
  36. Burns AM, Green PJ, Pasternak S. Etanercept-induced cutaneous and pulmonary sarcoid-like granulomas resolving with adalimumab. *J Cutan Pathol* **39**: 289-293, 2012.
  37. Skoie IM, Wildhagen K, Omdal R. Development of sarcoidosis following etanercept treatment: a report of three cases. *Rheumatol Int* **32**: 1049-1053, 2012.
  38. Cathcart S, Sami N, Elewski B. Sarcoidosis as an adverse effect of tumor necrosis factor inhibitors. *J Drugs Dermatol* **11**: 609-612, 2012.
  39. Fok KC, Ng WW, Henderson CJ, Connor SJ. Cutaneous sarcoidosis in a patient with ulcerative colitis on infliximab. *J Crohns Colitis* **6**: 708-712, 2012.
  40. Lamrock E, Brown P. Development of cutaneous sarcoidosis during treatment with tumour necrosis alpha factor antagonists. *Australas J Dermatol* **53**: e87-e90, 2012.
  41. Bhamra K, Stevens R. Pulmonary sarcoidosis following etanercept treatment. *Case Rep Rheumatol* **2012**: 724013, 2012.
  42. Vigne C, Tebib JG, Pacheco Y, Coury F. Sarcoidosis: an underestimated and potentially severe side effect of anti-TNF-alpha therapy. *Joint Bone Spine* **80**: 104-107, 2013.
  43. Mao-Draayer Y, Cash T. Neurosarcoidosis in a patient treated with tumor necrosis factor alpha inhibitors. *J Neurol* **260**: 651-653, 2013.
  44. Christoforidou A, Goudakos J, Bobos M, Lefkaditis E, Vital V, Markou K. Sarcoidosis-like granulomatosis of the hypopharynx as a complication of anti-TNF therapy. *Am J Otolaryngol* **34**: 268-272, 2013.
  45. Dragnev D, Barr D, Kulshrestha M, Shanmugalingam S. Sarcoid panuveitis associated with etanercept treatment, resolving with adalimumab. *BMJ Case Rep* Forthcoming.
  46. Bhargava S, Perlman DM, Allen TL, Ritter JH, Bhargava M. Adalimumab induced pulmonary sarcoid reaction. *Respir Med Case Rep* **10**: 53-55, 2013.
  47. Santos G, Sousa LE, João AM. Exacerbation of recalcitrant cutaneous sarcoidosis with adalimumab—a paradoxical effect? A case report. *An Bras Dermatol* **88**: 26-28, 2013.
  48. Unterstell N, Bressan AL, Serpa LA, Fonseca e Castro PP, Gripp AC. Systemic sarcoidosis induced by etanercept: first Brazilian case report. *An Bras Dermatol* **88**: 197-199, 2013.
  49. Durel CA, Feurer E, Pialat JB, Berthoux E, Chapurlat RD, Confavreux CB. Etanercept may induce neurosarcoidosis in a patient treated for rheumatoid arthritis. *BMC Neurol* **13**: 212, 2013.
  50. Kotze PG, de Barcelos IF, da Silva Kotze LM. Sarcoidosis during therapy with adalimumab in a Crohn’s disease patient: a paradoxical effect. *J Crohns Colitis* **7**: e599-e600, 2013.
  51. Alhajri M, Aljumaah S, Aleyouni Y, Al-Qahtani F, Alhazzaa S, Al-Mayouf SM. Granulomatous disease in a child treated with etanercept. *Int J Rheum Dis* **16**: 472-474, 2013.
  52. Moisseiev E, Shulman S. Certolizumab-induced uveitis: a case report and review of the literature. *Case Rep Ophthalmol* **5**: 54-59, 2014.
  53. Chaowattanapanit S, Aiempakit K, Silpa-Archa N. Etanercept-induced sarcoidosis presented with scrotal lesion: a rare manifestation in genital area. *J Dermatol* **41**: 267-268, 2014.
  54. Au S, Mirsaeidi M, Aronson IK, Sweiss NJ. Adalimumab induced subcutaneous nodular sarcoidosis; a rare side effect of tumor necrosis factor- $\alpha$  inhibitor. *Sarcoidosis Vasc Diffuse Lung Dis* **31**: 249-251, 2014.
  55. Miyagi R, Ideguchi H, Soga T, et al. Development of pulmonary and cardiac sarcoidosis during etanercept therapy. *Int J Rheum Dis* **17**: 810-812, 2014.
  56. McDonnell MJ, Rutherford RM, O’Regan A. Sarcoidosis complicating treatment with adalimumab for Crohn’s disease. *J Crohns Colitis* **8**: 1140-1141, 2014.
  57. Villemaire M, Cartier JC, Mathieu N, et al. Renal sarcoid-like granulomatosis during anti-TNF therapy. *Kidney Int* **86**: 215, 2014.
  58. Korta DZ, Ochieng P, Fishman D, Katz SE. Pulmonary sarcoidosis and latent tuberculosis in a patient with psoriasis treated with adalimumab. *Dermatol Online J*. Forthcoming.
  59. Baha A, Hanazay C, Kokturk N, Turktas H. A case of sarcoidosis associated with anti-tumor necrosis factor treatment. *J Investig Med High Impact Case Rep* **3**: 2324709615571366, 2015.
  60. Simonetto DA, Papadakis KA. New-onset paresthesias in inflammatory bowel disease. *Gastroenterology* **148**: 906-907, 2015.
  61. Akiyama M, Kaneko Y, Hanaoka H, Kuwana M, Takeuchi T. Acute kidney injury due to renal sarcoidosis during etanercept therapy: a case report and literature review. *Intern Med* **54**: 1131-1134, 2015.
  62. Berrios I, Jun-O’Connell A, Ghiran S, Ionete C. A case of neurosarcoidosis secondary to treatment of etanercept and review of the literature. *BMJ Case Rep*. 2015.
  63. Vieira MA, Saraiva MI, Silva LK, Fraga RC, Kakizaki P, Valente NY. Development of exclusively cutaneous sarcoidosis in patient

- with rheumatoid arthritis during treatment with etanercept. *Rev Assoc Med Bras* (1992) **62**: 718-720, Forthcoming.
64. Mengi G, Göğüş F. A rare adverse effect of anti-tumor necrosis factor alpha therapy: sarcoidosis. *Arch Rheumatol* **32**: 67-70, 2017.
65. Park SK, Hwang PH, Yun SK, Kim HU, Park J. Tumor necrosis factor alpha blocker-induced erythrodermic sarcoidosis in with juvenile rheumatoid arthritis: a case report and review of the literature. *Ann Dermatol* **29**: 74-78, 2017.
66. Decock A, Van Assche G, Vermeire S, Wuyts W, Ferrante M. Sarcoidosis-like lesions: another paradoxical reaction to anti-TNF therapy? *J Crohns Colitis* **11**: 378-383, 2017.
67. Sakai H, Nomura W, Sugawara M. Certolizumab pegol-induced folliculitis-like lichenoid sarcoidosis in a patient with rheumatoid arthritis. *Case Rep Dermatol* **9**: 158-163, 2017.
68. Isshiki T, Matsuyama H, Sakamoto S, et al. Development of propionibacterium acnes-associated sarcoidosis during etanercept therapy. *Intern Med* **58**: 1473-1477, 2019.
69. Chopra A, Nautiyal A, Kalkanis A, Judson MA. Drug-induced sarcoidosis-like reactions. *Chest* **154**: 664-677, 2018.
70. Vermeire S, Gils A, Accossato P, Lula S, Marre A. Immunogenicity of biologics in inflammatory bowel disease. *Ther Adv Gastroenterol* **11**: 1-13, 2018.
71. Shin JI, Kim DS. Development of sarcoidosis during anti-TNF-alpha treatment: what is the mechanism? *Clin Exp Rheumatol* **27**: 1054, 2009.
72. Shealy D, Kai A, Staquet K, et al. Characterization of golimumab, a human monoclonal antibody specific for human tumor necrosis factor  $\alpha$ . *mAbs* **2**: 428-439, 2010.
73. Ramos-Casals M, Brito-Zerón P, Muñoz S, Soto M-J. A systematic review of the off-label use of biological therapies in systemic autoimmune diseases. *Medicine (Baltimore)* **87**: 345-364, 2008.
74. Ramos-Casals M, Perez-Alvarez R, Diaz-Lagares C, Cuadrado MJ, Khamashta MA. Autoimmune diseases induced by biological agents: a double-edged sword? *Autoimmun Rev* **9**: 188-193, 2010.

The Internal Medicine is an Open Access journal distributed under the Creative Commons Attribution-NonCommercial-NoDerivatives 4.0 International License. To view the details of this license, please visit (<https://creativecommons.org/licenses/by-nc-nd/4.0/>).