

## Original Article

# IDH1, ATRX, and BRAFV600E mutation in astrocytic tumors and their significance in patient outcome in north Indian population

Debajyoti Chatterjee, Bishan Dass Radotra, Narendra Kumar<sup>1</sup>, Rakesh Kumar Vasishta, Sunil Kumar Gupta<sup>2</sup>

Departments of Histopathology, <sup>1</sup>Radiotherapy, <sup>2</sup>Neurosurgery, Post Graduate Institute of Medical Education and Research (PGIMER), Chandigarh, India

E-mail: Debajyoti Chatterjee - devchat1984@gmail.com; \*Bishan Dass Radotra - bishanradotra@gmail.com; Narendra Kumar - drnarendra74@gmail.com; Rakesh Kumar Vasishta - r\_vasishta@yahoo.com; Sunil Kumar Gupta - drguptasunil@gmail.com

\*Corresponding author

Received: 02 August 17 Accepted: 14 November 17 Published: 14 February 18

## Abstract

**Background:** According to the current World Health Organization (WHO) classification of central nervous system (CNS) tumors (2016), histological diagnosis of gliomas should be supplemented by molecular information. This study was carried out to determine the frequency of isocitrate dehydrogenase 1 (*IDH1*), *ATRX*, and *BRAFV600E* mutations in different grade astrocytomas and their prognostic value.

**Methods:** Eighty cases of astrocytoma (15 pilocytic astrocytoma, 25 diffuse astrocytoma, 15 anaplastic astrocytoma, and 25 glioblastoma) with follow-up information were analyzed using immunohistochemistry for *IDH1* mutant protein, *ATRX*, p53, and *BRAF*. Sanger sequencing was carried out for *IDH1* exon 4 and *BRAF* exon 15.

**Results:** All pilocytic astrocytoma and primary glioblastoma cases were negative for *IDH1* mutation. *IDH1* mutation was detected in 80% (20/25) DA and 87% (13/15) AA cases. *IDH1* R132H was the commonest *IDH1* mutation (94.1%) and immunohistochemistry showed 100% sensitivity and specificity to detect this mutation. Loss of nuclear *ATRX* expression was found in 87% (20/23) and 100% (14/14) DA and AA cases, respectively. *IDH1* mutant DA patients had longer overall survival than *IDH1* wild cases, although this difference was not significant (79.5 months vs. 42.5 months, *P* value 0.417). *BRAF* V600E mutation was not detected in any astrocytic tumor.

**Conclusions:** *IDH1* and *ATRX* mutations are very common in diffuse astrocytoma and anaplastic astrocytoma, while they are rare in pilocytic astrocytoma and glioblastoma. Immunohistochemistry for *IDH1* and *ATRX* can successfully characterize the diffuse gliomas into molecularly defined groups in majority of the cases. *BRAF* V600E mutation is rare in astrocytic tumors in Indian population.

**Key Words:** Astrocytoma, *ATRX*, *BRAF*, glioblastoma, isocitrate dehydrogenase

### Access this article online

**Website:**

[www.surgicalneurologyint.com](http://www.surgicalneurologyint.com)

**DOI:**

10.4103/sni.sni\_284\_17

**Quick Response Code:**

This is an open access article distributed under the terms of the Creative Commons Attribution-NonCommercial-ShareAlike 3.0 License, which allows others to remix, tweak, and build upon the work non-commercially, as long as the author is credited and the new creations are licensed under the identical terms.

**For reprints contact:** [reprints@medknow.com](mailto:reprints@medknow.com)

**How to cite this article:** Chatterjee D, Radotra BD, Kumar N, Vasishta RK, Gupta SK. *IDH1*, *ATRX*, and *BRAFV600E* mutation in astrocytic tumors and their significance in patient outcome in north Indian population. *Surg Neurol Int* 2018;9:29.

<http://surgicalneurologyint.com/IDH1,-ATRX,-and-BRAFV600E-mutation-in-astrocytic-tumors-and-their-significance-in-patient-outcome-in-north-Indian-population/>

## INTRODUCTION

Gliomas are the commonest brain tumors, both in adults as well as in children. According to the World Health Organization (WHO) classification of central nervous system (CNS) tumors 2007, gliomas were divided into astrocytomas, oligodendrogliomas, and mixed oligoastrocytomas.<sup>[16]</sup> The molecular features of low grade gliomas were relatively less known. However, in recent years, the molecular features of low grade gliomas have been better revealed.

The most important and well described molecular alteration in the pathogenesis of grade glioma is isocitrate dehydrogenase (*IDH*) mutation. It is now believed that *IDH* mutation is responsible for initiation of glioma genesis. *IDH1* or *IDH2* mutation is seen in >90% of astrocytomas and oligodendrogliomas.<sup>[8]</sup> Oligodendrogliomas are characterized by 1p/19q co-deletion, whereas *ATRX* mutation has been recently described in astrocytic tumors.<sup>[3,9]</sup> *ATRX* gene mutation can be detected using immunohistochemistry as loss of nuclear *ATRX* expression. *IDH* and *ATRX* mutations are rarely seen in glioblastomas (GB) and pilocytic astrocytomas (PA). The most commonly described genetic alteration in PA is *KIAA-BRAF* fusion, while *BRAF* V600E mutation is observed in <10% cases of PA.<sup>[19]</sup> According to the molecular signature of these tumors, diffuse astrocytoma is believed to be more closely related to oligodendroglioma, rather than PA. Based upon these information, glial tumors are now classified into three basic categories - pilocytic astrocytoma (WHO grade I), glioblastoma (WHO grade IV), and diffuse gliomas, which include astrocytomas and oligodendrogliomas (WHO grade II and III), and this was adopted in the 2016 update of WHO classification of CNS tumors.<sup>[17]</sup>

These molecular markers not only help to classify the glial tumors into different molecular subgroups, but also provide prognostic information. It has been observed that *IDH* mutant gliomas carry better prognosis than *IDH* wild-type tumors. Gliomas with 1p/19q co-deletion behave better than cases that do not show this deletion. Glioblastomas with *IDH* mutation also show longer survival than *IDH* wild type GBs. According to the recommendation of ISN-Haarlem 2014 consensus, only histological diagnosis with a WHO grade is no longer sufficient.<sup>[18]</sup> It is advisable to offer integrated diagnosis, which includes both histological and molecular information. These recommendations have been reflected in the 2016 update of WHO classification of CNS tumors.<sup>[17]</sup>

Most of the information regarding molecular alterations in gliomas is available from the western literature. There is limited data involving these molecules in glial tumors in the Indian population.<sup>[14,20,28]</sup> The frequencies of

*IDH1*, *BRAF*, and *ATRX* mutations in gliomas and their prognostic significance in Indian population has not been published so far. This study was undertaken to determine the frequency of these molecular alterations in different grades of astrocytic tumors and to correlate with disease outcome.

## MATERIALS AND METHODS

A retrospective study was performed. Patients of different grades of astrocytoma (grade I to IV) diagnosed in the year 2011 were evaluated for the molecular alterations. The clinical detail of the patients was obtained from the database of Department of Radiotherapy. Those patients who underwent near total or gross total excision with available follow-up information were included in this study. Cases diagnosed on stereotactic biopsy, cases for which the blocks were not available or patients who were lost to follow up were excluded. Other astrocytic tumors like pleomorphic xanthoastrocytoma (PXA) and other glioneuronal tumors were excluded from the study. Archival material from the Department of Histopathology was used for histopathological, immunohistochemical, and molecular analyses.

The follow-up information for patients with grade II–IV tumor was obtained from the department of Radiotherapy. For the patients with grade I tumor, follow up information was obtained by personal communication.

Slides of all these cases were reviewed. All the cases were classified and graded according to the existing 2016 WHO criteria.<sup>[17]</sup>

### Immunohistochemistry

IHC was carried out at least on one representative block in all the cases. IHC was performed using primary antibody against the following antigens- *IDH1* R132H (Dianova, dilution 1:40), *ATRX* (Sigma, dilution 1:300), p53 (Dako, dilution 1:50), Ki-67 (OSB, dilution 1:300), and *BRAF* (VE1 clone, Ventana).

Cases showing cytoplasmic positivity for *IDH1* in >10% tumor cells were considered positive.<sup>[24,25]</sup> Loss of nuclear *ATRX* staining in the tumor cells was calculated in a semi-quantitative way. Near total loss of nuclear staining for *ATRX* in tumor cells (>90%) was considered positive for *ATRX* mutation.<sup>[13]</sup> Cases showing negative tumor cells with negative internal control (endothelial cells, neurons) were not evaluated for further analysis. In cases with heterogeneous immunoreactivity, areas with strongest staining were evaluated.<sup>[31]</sup> Nuclear positivity for p53 in >50% tumor cells was considered positive. Ki-67 proliferation index was determined by counting 10 high power fields (400× magnification) at the highest proliferating area and was expressed in percentage. For *BRAF*, cytoplasmic positivity in >10% cells was considered positive. A case of papillary thyroid carcinoma

with proven *BRAF* V600E mutation was used as external control for immunohistochemistry.

### Molecular analysis

DNA was extracted from the formalin-fixed, paraffin-embedded (FFPE) tissue by commercially available (Qiagen) kit as per manufacturer's instruction.

For *IDH1* mutation analysis, exon 4 of the *IDH1* gene was amplified using following sets of primers -

Forward primer: 5'-TCACCAAATGGCACCATACGA-3'

Reverse primer: 5'-TCATACCTTGCTTAATGGGTGT-3'

Using this pair of primers, a product of 255bp was amplified. In brief, the initial reaction was at 95°C, followed by denaturation at 95°C, annealing at 54°C, and amplification at 72°C. This cycle was repeated for 36 times.

For *BRAF* V600E mutation, exon 15 of the *BRAF* gene was amplified using following set of primers -

Forward primer: 5'-TCTTCATAATGCTTGCTCTGATAGG-3'

Reverse primer: 5'-CTAGTAACTCAGCAGCATCTCAGG-3'.

Using this set of primers, a product of 250 bp was amplified. In brief, the initial reaction was at 95°C, followed by denaturation at 95°C, annealing at 58°C, and amplification at 72°C. This cycle was repeated for 38 times.

The amplification products were purified using commercially available DNA purification kit (Qiagen) and subjected to Sanger sequencing.

### Fluorescent in-situ hybridization

FISH for 1p/19q was carried out in 10 selective astrocytoma cases (as discussed subsequently). It was carried out on formalin-fixed, paraffin-embedded tissue using commercially available probes (Vysis 1p36/LSI 1q25 and LSI 19q13/19p13 dual color probe). For analysis, 200 nonoverlapping interphase nuclei were counted. Ratio of red to green signal was calculated and ratio <0.8 was taken as deleted.

### Control

Twenty cases of oligodendroglioma (ODG), 10 each for WHO grade II and grade III were included for comparison of the molecular findings. We performed immunohistochemistry for *IDH1*, *ATRX*, *p53*, *Ki-67* and *BRAF* as well as sequencing for *IDH1* exon 4 and *BRAF* exon 15 in all these cases. FISH for 1p/19q was also performed in 8 selective cases (as described subsequently). DNA extracted from peripheral blood of a normal donor was subjected to sequencing to obtain the normal sequence (*IDH1* exon 4 and *BRAF* exon 15) for purpose of comparison. DNA of one case of hairy cell leukemia was used as a positive control for *BRAF* V600E mutation.

### Follow-up of patients

Clinical details including treatment history were noted from the patient's file. The patients were followed up till December, 2015. Outcome in terms of death, recurrence or disease-free survival was recorded.

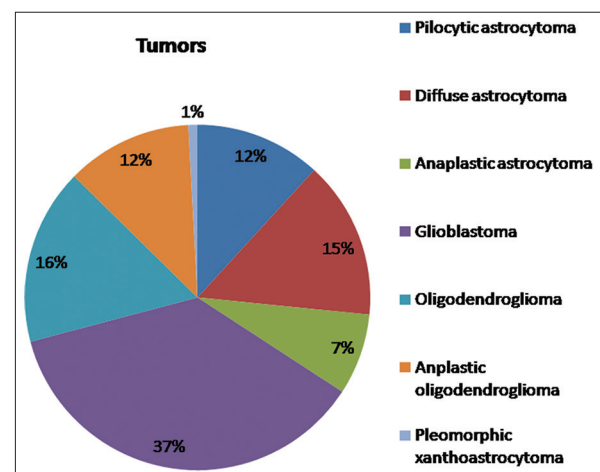
### Statistical analysis

All statistical analyses were carried out using SPSS software, version 21 (SPSS Inc; Chicago, IL, USA). For normally distributed parametric data, student's *t* test and analysis of variance (ANOVA) were used. For non-parametric data, Kruskal Wallis test followed by Mann-Whitney tests were applied. Statistical significance was considered if *P* value is <0.05. Kaplan-Meier estimator and Cox proportional hazards regression were performed to assess survival data.

This study was approved by the institute ethics committee.

## RESULTS

Within this study period, a total of 28 pilocytic astrocytoma, grade I (PA), 35 diffuse astrocytoma, grade II (DA), 18 anaplastic astrocytoma, grade III (AA), and 87 glioblastoma, grade IV (GB) cases were diagnosed on histopathology examination [Figure 1] in our tertiary care academic hospital. In addition, two cases of pleomorphic xanthoastrocytomas (PXA) were also diagnosed within this period; however, they were not included in the study. Sixty-seven cases of oligodendroglioma (ODG) (39 grade II and 28 grade III) were also diagnosed within this time period. No case of anaplastic pilocytic astrocytoma or oligoastrocytoma was diagnosed. Two DA, one AA, and six GB cases were diagnosed on stereotactic biopsy, and they were excluded. Blocks were not available for one case of DA and 8 cases of GB since they were issued to the patients when they opted to shift to another hospital for post-operative care.



**Figure 1:** Pie diagram showing distribution of glial tumors diagnosed within the study period

Follow up information could not be obtained for 13 PA, 7 DA, 2 AA, and 28 GB cases, and were thus excluded from the study.

We finally included 15 PA, 25 DA, 15 AA, and 45 cases of GB in this study. There were 44 primary GB cases and one secondary GB case, which developed in the background of AA diagnosed 22 months earlier. The age of the patients ranged from 11–68 years (mean 46.4 years), and there was male predominance (65% males). All cases of DA, AA, and GB were located supratentorially with frontal lobe being the commonest site (67.7%), while 60% of the PA ( $n = 9$ ) were infratentorial in location. All cases underwent near total or gross total excision. Twenty cases of ODG (10 grade II and 10 grade III) were randomly selected for molecular analysis (as control group).

### Post-operative therapy

None of the PA cases received any post operative therapy. All DA cases received 54Gy radiotherapy (RT) and none received chemotherapy (CT). All AA patients received 60 Gy, while one patient was given 54Gy radiation. One case of AA received six cycles of temozolomide chemotherapy. All cases of GB received RT. Majority (43 cases) received 60Gy radiation. One young boy of 16 years and one 62-year-old male with poor general health received lower dose (40Gy and 54Gy, respectively). Thirteen cases received temozolomide chemotherapy ranging from 2 to 23 cycles.

### Molecular analysis [Table 1]

A. Pilocytic astrocytoma [Figure 2a–d]: None of the PA cases showed *IDH1* mutation by immunohistochemistry or sequencing. All cases showed retained ATRX nuclear staining and p53 was negative in all cases. None of the PA cases showed *BRAF* V600E mutation either by IHC or sequencing.

B. Diffuse astrocytoma: Out of 25 cases of DA, 18 showed positivity for *IDH1* IHC [Figure 2e–i]. On performing sequencing, all these 18 cases showed heterozygous *IDH1*R132H mutation (G to A at nucleotide position 395, CGT to CAT). Two additional cases showed *IDH1* mutation by sequencing, which were negative by IHC. One case showed heterozygous R132G (C to G at nucleotide position 394, CGT to GGT) and one showed

heterozygous R132C (C to T at nucleotide position 394, CGT to TGT) mutation [Figure 3a–c]. Thus, overall 20 cases (80%) showed *IDH1* mutation. ATRX could not be interpreted in 2 DA cases. Out of the rest 23 cases, 20 (87%) showed loss of nuclear ATRX staining. p53 over-expression was detected in 44% (11/25) DA cases. All cases of DA were negative for *BRAF* V600E mutation (both by IHC and sequencing).

Fluorescent in-situ hybridization (FISH): five DA cases (*IDH1*-mutant and ATRX lost), three *IDH1*-mutant DA cases with retained nuclear ATRX expression, and two *IDH1*-mutant DA cases where ATRX staining could not be interpreted were subjected to fluorescent in-situ hybridization (FISH) analysis for 1p/19q co-deletion. All ten cases were 1p/19q non-deleted, thus confirming astrocytic nature of these tumors.

C. Anaplastic astrocytoma [Figure 3d–f]: Thirteen out of 15 AA cases (86.7%) showed *IDH1* immunopositivity, which were confirmed to be due to heterozygous *IDH1* R132H mutation by sequencing. No additional *IDH1* mutation was detected in AA cases on sequencing. ATRX was not interpretable in one case. The rest of 14 AA cases (100%) showed loss of nuclear ATRX expression. p53 over-expression was observed in 80% (12/15) AA cases. All AA were negative for *BRAF* V600E mutation both by IHC and sequencing.

D. Primary glioblastoma: All cases of primary GB were negative for *IDH1* mutation by both IHC and sequencing. All primary GB cases showed retained nuclear ATRX expression. p53 over-expression was found in 13.6% (6/44) primary GBs. *BRAF* V600E mutation was consistently negative in GB cases, both by IHC and sequencing.

E. Secondary glioblastoma [Figure 3g–i]: Secondary GB showed *IDH1* immunopositivity, which was confirmed by sequencing. This case was previously operated in our institute 22 months back and diagnosed as AA. The previous biopsy also showed diffuse *IDH1* positivity. This case showed loss of ATRX expression, p53 over-expression and was negative for *BRAF* V600E mutation.

### Correlation of IHC and sequencing

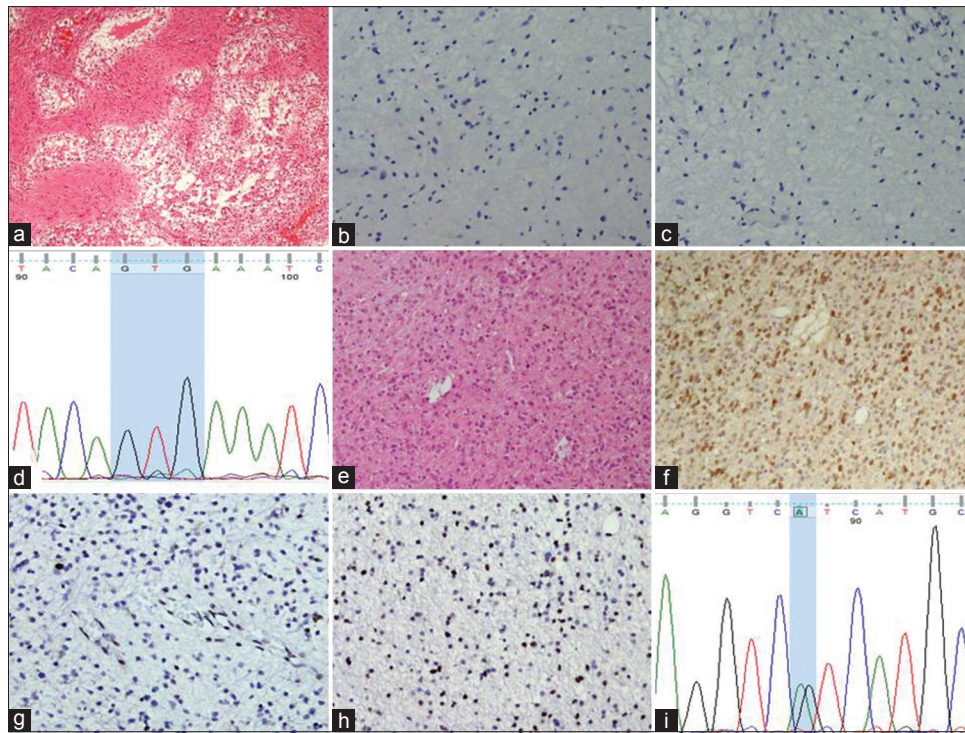
There were total 34 *IDH1*-mutant cases in this series, out of which 32 (94.1%) showed *IDH1*

**Table 1: Clinical and immunohistochemical findings in astrocytoma patients**

Features	Pilocytic astrocytoma	Diffuse astrocytoma	Anaplastic astrocytoma	Primary glioblastoma	Secondary glioblastoma
No. of cases	15	25	15	44	1
Mean age (years)	12.1	34.5	33	54.3	49
<i>IDH1</i> mutation (%)	0 (0)	20 (80)	13 (86.7%)	0 (0)	1 (100)
ATRX loss (%)	0 (0)	20/23 (87)	14/14 (100)	0 (0)	1 (100)
p53 over-expression (%)	0 (0)	11 (44)	12 (80)	6 (13.6)	1 (100)
<i>BRAF</i> V600E mutation (%)	0 (0)	0 (0)	0 (0)	0 (0)	0 (0)

ATRX could not be interpreted in 2 diffuse astrocytoma and 1 anaplastic astrocytoma cases





**Figure 2:** (a) Photomicrograph showing pilocytic astrocytoma (HE,  $\times 100$ ). This case is negative for IDH1 (b, immunohistochemistry,  $\times 200$ ) and BRAF (c, immunohistochemistry,  $\times 200$ ). (d) Chromatogram featuring BRAF exon 15 sequencing from pilocytic astrocytoma showing normal sequence. (e) Photomicrograph showing diffuse astrocytoma with infiltrative pattern of growth (HE,  $\times 100$ ). The tumor cells of the same case show IDH1 positivity (f, immunohistochemistry,  $\times 100$ ), loss of nuclear ARTX expression (g, immunohistochemistry,  $\times 100$ ) and p53 expression (h, immunohistochemistry,  $\times 100$ ). (i) Chromatogram of IDH1 exon 4 from the same tumor shows heterozygous mutation at nucleotide position 395 (G to A) producing IDH1 R132H mutation

immunopositivity (18 DA, 13 AA and 1 secondary GB). All these immunopositive cases showed heterozygous IDH1 R132H mutation by sequencing. None of the IDH immunonegative cases showed this mutation by sequencing. Thus, IHC showed 100% sensitivity and specificity for detecting IDH1 R132H mutation. However, two DA cases showed different IDH1 exon 4 mutations, which were not detected by this mutation specific antibody.

#### Molecular analysis in the control group

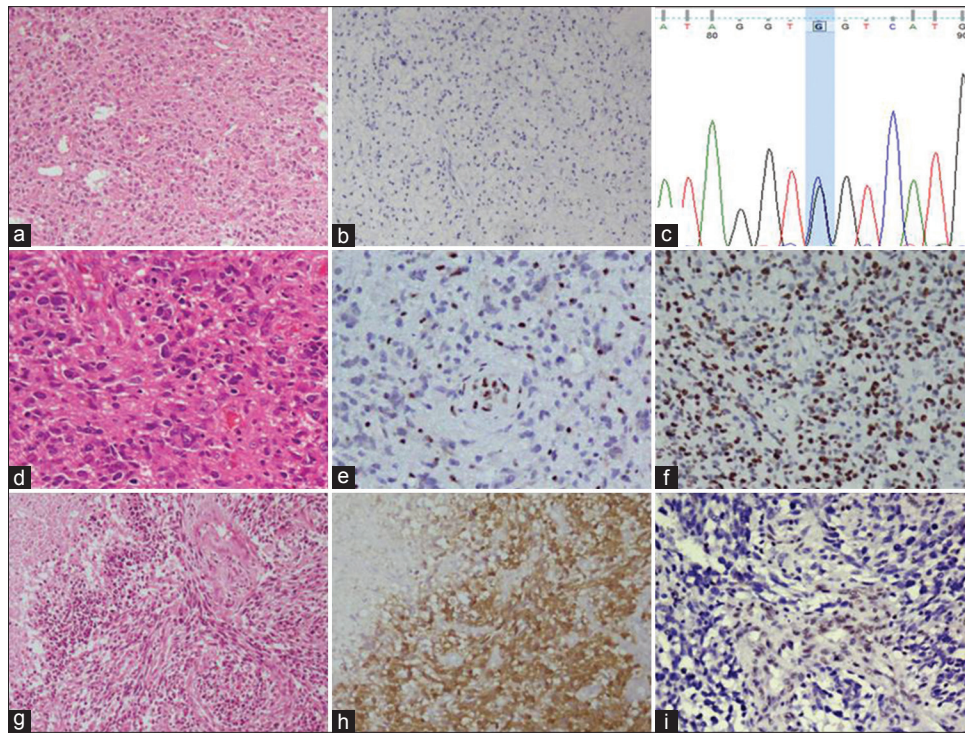
IDH1 immunopositivity was observed in 90% (9/10) grade II and 80% (8/10) grade III ODG. Sequencing confirmed heterozygous IDH1 R132H mutation in these cases. No additional IDH1 mutation was detected on sequencing. Nuclear ATRX staining was retained in 90% (9/10) grade II and 100% (10/10) grade III ODGs. All cases were negative for p53, except one grade II ODG, which had shown loss of ATRX nuclear staining. All cases were negative for BRAF V600E mutation. FISH for 1p/19q was performed on 4 grade II and 4 grade III ODGs. Three grade II and all 4 grade III ODG showed 1p/19q co-deletion, thus confirming their oligodendroglial nature. However, one IDH1 immunopositive grade II ODG, which revealed over-expression of p53 and loss of nuclear ATRX staining, was 1p/19q non co-deleted. Thus, based on

molecular findings, this case was re-categorized as diffuse astrocytoma, IDH1-mutant.

#### Survival analysis [Table 2]

All cases of PA were alive and there was no recurrence except in one case, which recurred 23 months after the surgery. Among the DA patients, 6 passed away (24%). The median survival period was 70.27 months. In the AA group, 7 patients expired (46.7%). Among the living patients, 2 experienced recurrence. The mean survival time was 46.17 months. For the primary GB patients, 39 (88.6%) expired with median survival 19.7 months. One case of secondary GBM was alive at 44 months follow up. The difference of mean survival among different grades was statistically significant ( $P$  value 0.003) [Figure 4a].

The mean survival time of IDH1-mutant and IDH1-wild DA were 79.5 and 42.5 months respectively [Figure 4b]. Although the mean survival of IDH1-mutant DA was higher, this difference was not statistically significant ( $P$  value 0.417). The mean survival time of IDH1-mutant and IDH1-wild AA were 41.2 and 46 months, respectively ( $P$  value 0.913) [Figure 4c]. The mean survival of IDH1-mutant DA (79.5 months) was higher than IDH1-mutant AA (41.2 months), and this difference was statistically significant ( $P$  value 0.041).



**Figure 3:** (a) Photomicrograph of a diffuse astrocytoma (HE,  $\times 100$ ) which is negative for IDH1 immunohistochemistry (b,  $\times 100$ ). (c) Chromatogram of *IDH1* exon 4 from the same tumor shows heterozygous mutation at nucleotide position 394 (c-g) producing IDH1 R132G mutation. (d) Photomicrograph of anaplastic astrocytoma (HE,  $\times 200$ ). The tumor cells show loss of nuclear ATRX expression, whereas the endothelial cells are positive (e, immunohistochemistry,  $\times 200$ ) and they show strong p53 expression (f, immunohistochemistry,  $\times 200$ ). (g) Photomicrograph showing secondary glioblastoma with area of necrosis (HE,  $\times 100$ ). The same case showing diffuse IDH1 positivity (h, immunohistochemistry,  $\times 100$ ) and loss of ATRX expression (i, immunohistochemistry,  $\times 200$ )

**Table 2: Effect of IDH1 and ATRX mutation and p53 positivity on survival in diffuse and anaplastic astrocytomas**

Features	IDH1 mutated	IDH1 wild	P	ATRAX lost	ATRAX retained	P	p53 positive	p53 negative	P
DA cases	20	5	0.417	20	3	0.649	11	14	0.89
Death	4	2		5	1		3	3	
Overall survival (months)	79.5	42.5		53.1	53		57.1	68.4	
AA cases	13	2	0.913	14	0	-	12	3	0.78
Death	6	1		7	-		5	2	
Overall survival (months)	41.2	46		46.17	-		45.9	27.6	

DA: Diffuse astrocytoma; AA: Anaplastic astrocytoma

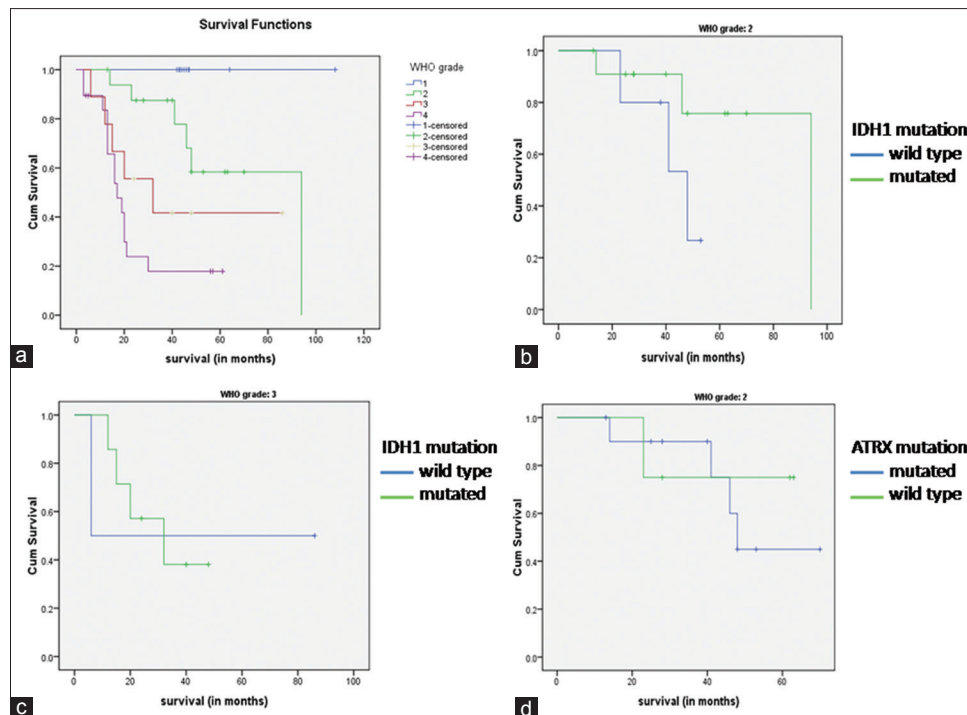
ATRAX lost and ATRAX retained DA cases had median survival time of 53.1 and 53 months, respectively ( $P$  value 0.649) [Figure 4d]. Since all AA cases were ATRAX lost, no effect on survival could be analyzed.

## DISCUSSION

The understanding about the pathogenesis and biology of gliomas has undergone revolutionary changes in the recent years. The incorporation of molecular information has helped categorization of glial tumors into different prognostic groups, which assists the individualization and optimization of the treatment. It is now considered that diffuse astrocytoma and anaplastic astrocytoma share similar genetic profile and they are characterized by *IDH* and *ATRAX* mutation. Isocitrate dehydrogenase (*IDH*) is

one of the most well recognized and widely described molecular markers in glial tumors, both with astrocytic and oligodendroglial differentiation. The frequency of *IDH* mutation in diffuse glioma is variable, ranging from 54% to 90%.<sup>[12,29,34]</sup> *IDH* mutation is rare in pilocytic astrocytoma and primary GB (<10%).<sup>[29]</sup> In this study, none of the pilocytic astrocytoma or primary glioblastoma cases showed *IDH* mutation, whereas it was seen in 80% DA and 86.7% AA. *IDH* mutation has been described more frequently in DA compared to AA. This discrepancy can be due to relatively smaller sample size and selection bias, as only the cases with available follow-up information were included in this study. Among the different *IDH* mutations, the commonest is R132H mutation at codon position 132.<sup>[29]</sup> Other mutations in this position are less frequent.<sup>[32]</sup> We found R132H mutation in 94.1%





**Figure 4: (a) Kaplan–Meier curves showing overall survival in different grades of astrocytoma. (b) Kaplan–Meier curves showing overall survival in diffuse astrocytoma with and without *IDH1* mutation. (c) Kaplan–Meier curves showing overall survival in *IDH1* mutant and *IDH1* wild type anaplastic astrocytoma. (d) Kaplan–Meier curves showing overall survival in diffuse astrocytoma with and without *ATRX* mutation**

of all *IDH1* mutated cases. Although sequencing is the gold standard to detect *IDH1* mutation, commercially available antibody against *IDH1* R132H mutant protein shows high sensitivity, specificity, and correlates very well with sequencing results.<sup>[6,7]</sup> We found 100% sensitivity and specificity of this antibody to detect *IDH1* R132H mutation. For a small biopsy, immunohistochemistry is considered superior to the molecular analysis.<sup>[6]</sup> As *IDH1* mutation is not seen in reactive conditions, IHC is extremely useful in distinguishing diffuse glioma from reactive gliosis and therapy induced changes, especially in a small biopsy.<sup>[5]</sup> *IDH2* mutation is restricted in codon position 172 (*IDH2* R172), and is much less frequent than *IDH1* mutation, and is more commonly seen in oligodendroglial tumors compared to astrocytomas.<sup>[2,4,10,33]</sup> In a large series, Hartmann *et al.* found *IDH2* mutation in 0.9%, 0.9%, 4.7% and 5.2% in grade II astrocytoma, grade III astrocytoma, grade II oligodendrogloma, and grade III oligodendrogloma, respectively.<sup>[10]</sup> Thus, *IDH2* mutation is extremely rare in astrocytic tumors, and is more often associated with an oligodendroglial phenotype. Hence, *IDH2* sequencing can be avoided in diffuse gliomas with astrocytic morphology for routine diagnostic purpose. *IDH2* mutation has not been reported yet from India. We did not perform *IDH2* gene sequencing in this study. Since we included only astrocytic tumors and majority was *IDH1*-mutant, there was less chance that *IDH2* sequencing could have altered the results significantly.

*IDH1* mutation is also associated with favorable outcome in high grade gliomas.<sup>[26,30]</sup> Weller *et al.* examined *IDH1* mutation in 301 GB patients, and demonstrated that *IDH1* mutation in GB is associated with better progression free and overall survival.<sup>[30]</sup> While the prognostic role of *IDH* mutation in high grade glioma is unequivocally established, there is confusion regarding its prognostic value in the low grade glial tumors. Sanson *et al.* observed that *IDH1* mutated DA show longer overall survival than *IDH1* wild cases (150.9 vs. 60.1 months).<sup>[24]</sup> Other studies have also demonstrated that *IDH* mutation in grade II gliomas predicts better overall and progression free survival.<sup>[11,34]</sup> However, some studies found no association of *IDH* mutation with progression free or overall survival in low grade gliomas.<sup>[2,27]</sup> In this study, we found *IDH1* mutant DA patients had better overall survival compared to *IDH1* wild cases, although this difference was not statistically significant. We found no prognostic difference between *IDH1* mutated and wild type AA, which may be due to very low number of *IDH1* wild DA and AA cases in this study. We also found *IDH1* mutant DA patients had a significantly better survival compared to *IDH1* mutant AA patients. This indicates that despite *IDH1* mutation, WHO grading still has its own significance in determining the prognosis. Thus, it remains important to determine the lineage and the grade of the tumors accurately based on the histomorphological features. This finding differs from the observation of Ruess *et al.* (2015) who found that *IDH* mutant DA and

AA had little difference in survival.<sup>[22]</sup> IDH wild DA and AA are provisional entities in current WHO classification. They are considered as a heterogeneous group of tumors and majority of these cases show molecular features of glioblastoma.<sup>[21]</sup> However, prognosis in this group is determined by other molecular alterations like *TERT* promoter mutation, EGFR amplification, MYB amplification, and *H3F3A* mutation.<sup>[1]</sup> Further studies are required to better characterize and understand the nature of IDH wild type diffuse gliomas.

*ATRX* mutation is a feature of astrocytic differentiation, which can be determined by loss of nuclear *ATRX* expression on immunohistochemistry. It occurs more frequently in DA (60–70%) and AA (70–80%) and is very rare in primary GB (4–6%).<sup>[15,31]</sup> We found *ATRX* loss in 87% of DA and 100% of AA cases. None of the primary GBs in our study showed loss of *ATRX* expression. *ATRX* mutation and 1p/19q co-deletion are almost mutually exclusive.<sup>[15]</sup> Thus, presence of *ATRX* mutation as detected by loss of nuclear *ATRX* expression is very sensitive for determining astrocytic differentiation. *ATRX* status combined with 1p/19q and *IDH1/IDH2* mutation status has been used to generate a molecular diagnostic algorithm for diffuse gliomas, which has been shown to be superior to conventional morphological classification. Diffuse glioma with *IDH* mutation, 1p/19q co-deletion, and retained *ATRX* expression has been diagnosed as oligodendroglioma and tumors with *IDH* mutation, intact 1p/19q and loss of nuclear *ATRX* expression has been classified as astrocytomas.<sup>[31]</sup> Since *ATRX* mutation and 1p/19q co-deletion are almost mutually exclusive, all diffuse gliomas should be screened by IHC for *IDH1* and *ATRX*. Cases showing astrocytic morphology but retained *ATRX* expression should be subjected to 1p/19q co-deletion status. On the other hand, cases showing ODG like morphology, but showing loss of *ATRX* with or without p53 over-expression, should also be subjected to 1p/19q FISH to confirm their oligodendroglial nature. This algorithm also shows high sensitivity and specificity to classify diffuse gliomas into molecular subgroups.<sup>[23]</sup> In this study, all five *IDH1* mutant DA cases with loss of

*ATRX* showed intact 1p and 19q, thus confirming that FISH can be avoided in *ATRX* mutated cases. Three DA cases with retained nuclear *ATRX* expression and two DA cases where *ARTX* could not be interpreted showed intact 1p/19q by FISH, thus confirming their astrocytic nature. One case in the control group, which was initially diagnosed as ODG, on molecular analysis showed *IDH1* expression, loss of nuclear *ATRX* and p53 over-expression. This case also showed intact 1p/19q by FISH. Based on these molecular findings, this case was reclassified as diffuse astrocytoma. This approach is more suitable for developing countries like India as FISH for 1p/19q status is expensive and not widely available. A few previous studies from India have evaluated the frequency of these molecular alterations in different grades of astrocytoma, however, none of the studies have classified gliomas according to WHO 2016 classification using the entire panel of markers and correlated with patient outcome.<sup>[14,20,28]</sup> A comparison of previously published studies with the current one has been shown in Table 3. A small number of referral medical centres in India have started using these markers in routine glioma reporting; however, evaluation of the results from all the centres may give a better picture.

## CONCLUSION

Diffuse astrocytoma and anaplastic astrocytoma are characterized by frequent *IDH1* mutation, which can be efficiently detected by *IDH1* immunohistochemistry. Combined *IDH1* and *ATRX* IHC can accurately confirm the molecular nature of most of the DA and AA cases, thus avoiding the need of expensive investigations like FISH. p53 can act as a surrogate marker for astrocytic differentiation. *IDH1* mutation was not found in any pilocytic astrocytoma and primary glioblastoma cases. Although *IDH1* mutant and p53 negative DA cases had a longer survival than *IDH1* wild and p53 positive DA cases, respectively, these differences were not statistically significant. *BRAF* V600E mutation is extremely rare in astrocytic tumors in our population.

**Table 3: Comparison of previous Indian studies on molecular aspects of glioma in the context of current WHO classification**

Author and year	Study population	Parameters analyzed	Observations	Difference from the current study
Jha <i>et al.</i> (2011) <sup>[14]</sup>	Different grades of glioma	<i>IDH1</i> mutation, p53 mutation, 1p/19q deletion, EGFR amplification, PTEN deletion	High frequency of <i>IDH1</i> mutation in oligodendroglioma and diffuse astrocytoma	Did not include <i>ATRX</i> and outcome was not analyzed
Thota <i>et al.</i> (2012) <sup>[28]</sup>	Infiltrating astrocytomas (DA, AA and GB)	<i>IDH1</i> mutation	High frequency of <i>IDH1</i> mutation in DA and AA	Did not include other markers (like <i>ATRX</i> , p53, 1p/19q) and prognosis was not analyzed
Rajeswari <i>et al.</i> (2017) <sup>[20]</sup>	Diffuse glioma, grade II and III (astrocytoma and oligodendroglioma)	<i>IDH1</i> and <i>ATRX</i> immunohistochemistry and 1p/19q deletion in selective cases	<i>IDH1</i> and <i>ATRX</i> immunohistochemistry are highly useful in categorizing diffuse glioma into histomolecular groups	Did not include <i>IDH1</i> sequencing, p53 expression and outcome was not analyzed

AA: Anaplastic astrocytoma; DA: Diffuse astrocytoma; GB: Glioblastoma; *IDH*: Isocitrate dehydrogenase; WHO: World Health Organization



## Financial support and sponsorship

Nil.

## Conflicts of interest

There are no conflicts of interest.

## REFERENCES

- Abudumijiti A, Chan AK, Shi Z, Li Y, Zhang R, Yang R, et al. Adult IDH Wild-type Lower-grade Gliomas Should Be Further Stratified. *Neuro Oncol* 2017;19:1327-37.
- Ahmadi R, Stockhammer F, Becker N, Hohlen K, Misch M, Christians A, et al. No prognostic value of *IDH1* mutations in a series of 100 WHO grade II astrocytomas. *J Neurooncol* 2012;109:15-22.
- Aldape K, Burger PC, Perry A. Clinicopathologic aspects of 1p/19q loss and the diagnosis of oligodendroglioma. *Arch Pathol Lab Med* 2007;131:242-51.
- Cahill DP, Sloan AE, Nahed BV, Aldape KD, Louis DN, Ryken TC, et al. The role of neuropathology in the management of patients with diffuse low grade glioma: A systematic review and evidence-based clinical practice guideline. *J Neurooncol* 2015;125:531-49.
- Capper D, Sahm F, Hartmann C, Meyermann R, von Deimling A, Schittenhelm J. Application of mutant *IDH1* antibody to differentiate diffuse glioma from nonneoplastic central nervous system lesions and therapy-induced changes. *Am J Surg Pathol* 2010;34:1199-204.
- Capper D, Weissert S, Balss J, Habel A, Meyer J, Jäger D, et al. Characterization of R132H mutation-specific *IDH1* antibody binding in brain tumors. *Brain Pathol* 2010;20:245-54.
- Capper D, Zentgraf H, Balss J, Hartmann C, von Deimling A. Monoclonal antibody specific for *IDH1* R132H mutation. *Acta Neuropathol* 2009;118:599-601.
- Cohen AL, Holmen SL, Colman H. *IDH1* and *IDH2* mutations in gliomas. *Curr Neurol Neurosci Rep* 2013;13:345.
- Haberler C, Wohrer A. Clinical Neuropathology practice news 2-2014: *ATRX*, a new candidate biomarker in gliomas. *Clin Neuropathol* 2014;33:108-11.
- Hartmann C, Meyer J, Balss J, Capper D, Mueller W, Christians A, et al. Type and frequency of *IDH1* and *IDH2* mutations are related to astrocytic and oligodendroglial differentiation and age: A study of 1,010 diffuse gliomas. *Acta Neuropathol* 2009;118:469-74.
- Houillier C, Wang X, Kaloshi G, Mokhtari K, Guillemin R, Laffaire J, et al. *IDH1* or *IDH2* mutations predict longer survival and response to temozolomide in low-grade gliomas. *Neurology* 2010;75:1560-6.
- Ichimura K, Pearson DM, Kocalkowski S, Bäcklund LM, Chan R, Jones DT, et al. *IDH1* mutations are present in the majority of common adult gliomas but rare in primary glioblastomas. *Neuro Oncol* 2009;11:341-7.
- Ikemura M, Shibahara J, Mukasa A, Takayanagi S, Aihara K, Saito N, et al. Utility of *ATRX* immunohistochemistry in diagnosis of adult diffuse gliomas. *Histopathology* 2016;69:260-7.
- Jha P, Suri V, Sharma V, Singh G, Sharma MC, Pathak P, et al. *IDH1* mutations in gliomas: First series from a tertiary care centre in India with comprehensive review of literature. *Exp Mol Pathol* 2011;91:385-93.
- Jiao Y, Killela PJ, Reitman ZJ, Rasheed AB, Heaphy CM, de Wilde RF, et al. Frequent *ATRX*, *CIC*, *FUBP1* and *IDH1* mutations refine the classification of malignant gliomas. *Oncotarget* 2012;3:709-22.
- Louis DN, Ohgaki H, Wiestler OD, Cavenee WK, editors. In: WHO Classification of Tumours of the Central Nervous System. International Agency for Research on Cancer (IARC): Lyon; 2007.
- Louis DN, Ohgaki H, Wiestler OD, Cavenee WK, editors. In: WHO Classification of Tumours of the Central Nervous System. International Agency for Research on Cancer (IARC): Lyon; 2016.
- Louis DN, Perry A, Burger P, Ellison DW, Reifenberger G, von Deimling A, et al. International Society Of Neuropathology--Haarlem consensus guidelines for nervous system tumor classification and grading. *Brain Pathol* 2014;24:429-35.
- Myung JK, Cho H, Park CK, Kim SK, Lee SH, Park SH. Analysis of the *BRAF* (V600E) Mutation in Central Nervous System Tumors. *Transl Oncol* 2012;5:430-6.
- Rajeswarie RT, Rao S, Nandeesh BN, Yasha TC, Santosh V. A simple algorithmic approach using histology and immunohistochemistry for the current classification of adult diffuse glioma in a resource-limited set-up. *J Clin Pathol* 2017 [Epub ahead of print].
- Reuss DE, Kratz A, Sahm F, Capper D, Schrimpf D, Koelsche C, et al. Adult IDH wild type astrocytomas biologically and clinically resolve into other tumor entities. *Acta Neuropathol* 2015;130:407-17.
- Reuss DE, Mamatjan Y, Schrimpf D, Capper D, Hovestadt V, Kratz A, et al. IDH mutant diffuse and anaplastic astrocytomas have similar age at presentation and little difference in survival: A grading problem for WHO. *Acta Neuropathol* 2015;129:867-73.
- Reuss DE, Sahm F, Schrimpf D, Wiestler B, Capper D, Koelsche C, et al. *ATRX* and *IDH1*-R132H immunohistochemistry with subsequent copy number analysis and *IDH* sequencing as a basis for an "integrated" diagnostic approach for adult astrocytoma, oligodendroglioma and glioblastoma. *Acta Neuropathol* 2015;129:133-46.
- Sanson M, Marie Y, Paris S, Idbah A, Laffaire J, Ducray F, et al. Isocitrate dehydrogenase I codon 132 mutation is an important prognostic biomarker in gliomas. *J Clin Oncol* 2009;27:4150-4.
- Takano S, Ishikawa E, Sakamoto N, Matsuda M, Akutsu H, Noguchi M, et al. Immunohistochemistry on *IDH1/2*, *ATRX*, p53 and Ki-67 substitute molecular genetic testing and predict patient prognosis in grade III adult diffuse gliomas. *Brain Tumor Pathol* 2016;33:107-16.
- Takano S, Tian W, Matsuda M, Yamamoto T, Ishikawa E, Kaneko MK, et al. Detection of *IDH1* mutation in human gliomas: Comparison of immunohistochemistry and sequencing. *Brain Tumor Pathol* 2011;28:115-23.
- Thon N, Eigenbrod S, Kretschmar H, Lutz J, Tonn JC, Kretschmar H, et al. *IDH1* mutations in grade II astrocytomas are associated with unfavorable progression-free survival and prolonged postrecurrence survival. *Cancer* 2012;118:452-60.
- Thota B, Shukla SK, Srividya MR, Shwetha SD, Arivazhagan A, Thennarasu K, et al. *IDH1* mutations in diffusely infiltrating astrocytomas: Grade specificity, association with protein expression, and clinical relevance. *Am J Clin Pathol* 2012;138:177-84.
- Watanabe T, Nobusawa S, Kleihues P, Ohgaki H. *IDH1* mutations are early events in the development of astrocytomas and oligodendrogliomas. *Am J Pathol* 2009;174:1149-53.
- Weller M, Felsberg J, Hartmann C, Berger H, Steinbach JP, Schramm J, et al. Molecular predictors of progression-free and overall survival in patients with newly diagnosed glioblastoma: A prospective translational study of the German Glioma Network. *J Clin Oncol* 2009;27:5743-50.
- Wiestler B, Capper D, Holland-Letz T, Korshunov A, von Deimling A, Pfister SM, et al. *ATRX* loss refines the classification of anaplastic gliomas and identifies a subgroup of *IDH* mutant astrocytic tumors with better prognosis. *Acta Neuropathol* 2013;126:443-51.
- Yan H, Parsons DW, Jin G, McLendon R, Rasheed BA, Yuan W, et al. *IDH1* and *IDH2* mutations in gliomas. *N Engl J Med* 2009;360:765-73.
- Zhang CB, Bao ZS, Wang HJ, Yan W, Liu YW, Li MY, et al. Correlation of *IDH1/2* mutation with clinicopathologic factors and prognosis in anaplastic gliomas: A report of 203 patients from China. *J Cancer Res Clin Oncol* 2014;140:45-51.
- Zou P, Xu H, Chen P, Yan Q, Zhao L, Zhao P, et al. *IDH1/IDH2* mutations define the prognosis and molecular profiles of patients with gliomas: A meta-analysis. *PLoS One* 2013;8:e68782.