


Atypical Tibial Fracture Treated with Osteosynthesis Associated with Total Knee Arthroplasty: Case Report

Fratura atípica de tíbia tratada com osteossíntese associada a artroplastia total do joelho: Relato de caso

Márcio Bezerra Gadelha Lopes¹  Leonardo Heráclio do Carmo Araújo² Leonardo Miranda Lustosa³
Jonatas Brito de Alencar Neto⁴ Marcos Rainier de Brito Felipe⁵

¹ Member of the group of Orthopedics and Sports Medicine, Hospital Geral de Fortaleza, Fortaleza, CE, Brazil

² Member of the Orthopedics and Knee Surgery Group, Hospital Geral de Fortaleza, Fortaleza, CE, Brazil

³ Academic at the Universidade Federal do Ceará, Fortaleza, CE, Brazil

⁴ Member of the Traumatology-Orthopedics Group, Instituto Dr. José Frola, Fortaleza, CE, Brazil

⁵ Resident at the Orthotics Department, Hospital Walter Cantídio, Universidade Federal do Ceará, Fortaleza, CE, Brazil

Address for correspondence Márcio Gadelha Bezerra Lopes, Hospital Geral de Fortaleza, Rua Leonardo Mota, 1515, 1301A, CEP 60140-041, Fortaleza, CE, Brazil (e-mail: drmarciogadelha@gmail.com).

Rev Bras Ortop 2023;58(6):e964–e967.

Abstract

Bisphosphonates are widely used in the treatment of osteoporosis but predispose the patient to the appearance of atypical fractures. The femoral subtrochanteric region is usually affected, but other bones can be as well. Atypical tibia fractures in patients with severe gonarthrosis is a therapeutic challenge. The present work reports the case of an elderly patient with advanced gonarthrosis who presented atypical tibial fracture. The patient made prolonged use of bisphosphonates for osteoporosis, presenting with pain and functional limitation resulting from gonarthrosis, which progressed to sudden pain in the right tibial metaphysis, preventing ambulation. The radiographs showed bilateral severe arthrosis; marked varism; tibial and femoral medial erosion; and fracture in the proximal third of the right tibial diaphysis. The fracture and arthrosis on the right side were treated by osteosynthesis with blocked plaque and total knee arthroplasty with posterior stabilization and fixed base. After physical rehabilitation, significant improvement of pain and function was reported, independent gait was reacquired and a range of motion of 0 to 100° was reached. After one year, the radiographs showed fracture consolidation and satisfactory alignment of the lower limbs' axes. The coexistence of severe arthrosis and atypical fracture made treatment difficult. However, the result was satisfactory and the approach with simultaneous osteosynthesis and arthroplasty proved to be adequate.

Keywords

- ▶ bisphosphonate
- ▶ bone fractures
- ▶ arthroplasty
- ▶ knee

Work developed at Hospital Geral de Fortaleza. Fortaleza, CE, Brazil.

received
September 3, 2020
accepted after revision
August 13, 2021

DOI <https://doi.org/10.1055/s-0041-1739301>.
ISSN 0102-3616.

© 2021. Sociedade Brasileira de Ortopedia e Traumatologia. All rights reserved.

This is an open access article published by Thieme under the terms of the Creative Commons Attribution-NonDerivative-NonCommercial-License, permitting copying and reproduction so long as the original work is given appropriate credit. Contents may not be used for commercial purposes, or adapted, remixed, transformed or built upon. (<https://creativecommons.org/licenses/by-nc-nd/4.0/>)

Thieme Revinter Publicações Ltda., Rua do Matoso 170, Rio de Janeiro, RJ, CEP 20270-135, Brazil

Resumo

Bifosfonatos são amplamente usados no tratamento da osteoporose; porém, predisõem ao surgimento de fraturas atípicas. A região subtrocantérica femoral é usualmente acometida, mas outros ossos também são afetados. Fraturas atípicas da tíbia em pacientes portadores de gonartrose grave são um desafio terapêutico. O presente trabalho relata o caso de uma paciente idosa com gonartrose avançada que apresentou fratura atípica tibial. A paciente fazia uso prolongado de bifosfonatos para osteoporose, com quadro de dor e limitação funcional decorrentes da gonartrose, que progrediu para dor súbita na metáfise tibial à direita, impedindo a deambulação. Radiografias evidenciaram artrose grave bilateral; varismo acentuado; erosão medial tibial e femoral; e fratura no terço proximal da diáfise tibial direita. Trataram-se a fratura e a artrose à direita por osteossíntese com placa bloqueada e artroplastia total do joelho com estabilização posterior e base fixa. Após reabilitação física, relatou-se melhora significativa da dor e da função, readquiriu-se a marcha independente e alcançou-se arco de movimento de 0 a 100°. Após um ano, as radiografias mostraram consolidação da fratura e alinhamento satisfatório dos eixos dos membros inferiores. A coexistência de artrose grave e fratura atípica dificultou o tratamento. Contudo, o resultado foi satisfatório e a abordagem com osteossíntese e artroplastia simultâneas mostrou-se adequada.

Palavras-chave

- ▶ bifosfonato
- ▶ fraturas ósseas
- ▶ artroplastia
- ▶ joelho

Introduction

Osteoporosis is characterized by reduced mineral density and deterioration of bone microarchitecture. Bisphosphonates are first-line drugs for their treatment. However, its prolonged action may favor the occurrence of atypical fractures (AFs).¹ Atypical fractures occur most frequently in the subtrocanteric and diaphysary region of the femur.² We report the case of an elderly patient with advanced arthrosis of the knees and osteoporosis, using bisphosphonates for 3 and a half years, who presented with AFs in the proximal third of the tibia, being treated with osteosynthesis associated with total knee arthroplasty (TKA) at once.

Case Report

This case report is about a 70-year-old female patient with osteoporosis and arthrosis of the knees with varus deformity, using alendronate for 3 years, followed by 6 months of ibandronate. Without a report of trauma, she presented change in the degree of pain in the right knee, which was also located in the metaphyseal-diaphysary transition of the tibia, accompanied by increased varism and intolerance to the load, forcing her to use a wheelchair. After 6 months, she was referred to our service. Radiographs showed severe gonarthrosis, varism, marked medial tibial and femoral erosion, as well as tibial and fibular fracture on the right side, in the proximal third of the diaphysis (► Fig. 1). It was

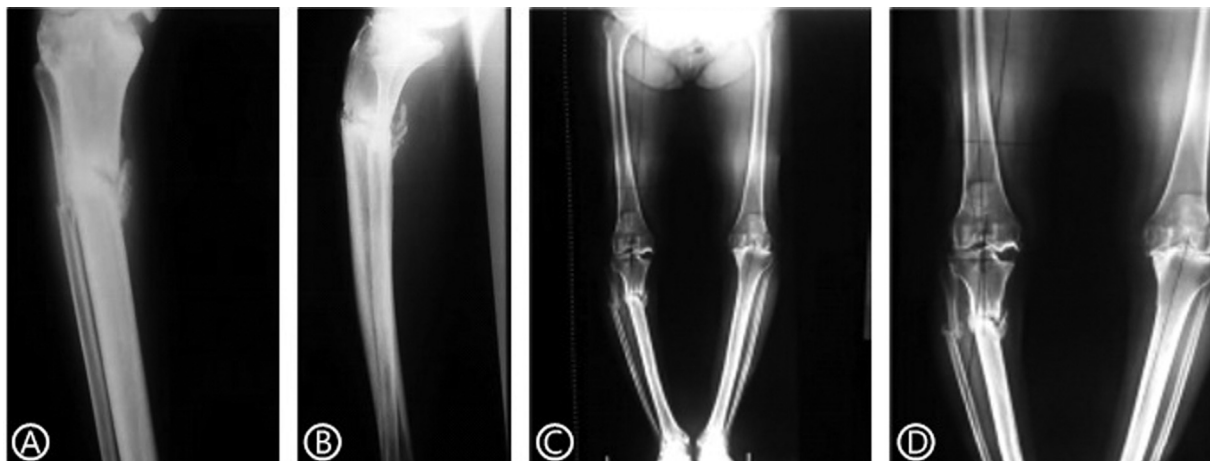


Fig. 1 (A and B) Radiographs of the leg showing the atypical fracture at the level of the tibial diaphysis. (C and D) Panoramic radiography of the lower limbs evidencing the associated gonarthrosis.

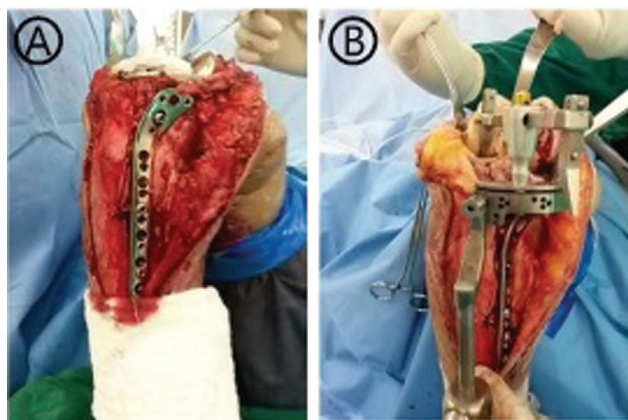


Fig. 2 (A) Osteosynthesis of atypical fracture with blocked plaque in the first surgical time. (B) Extramedullary guide for tibial cutting for arthroplasty in the second surgical time.

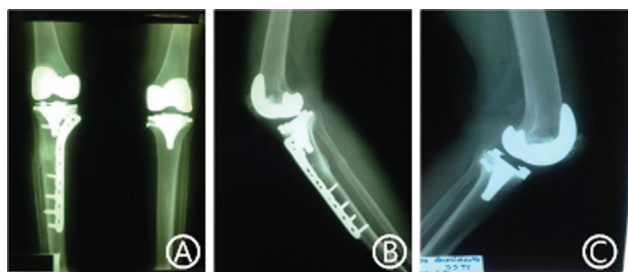


Fig. 3 (A) Anteroposterior radiography of the two total knee arthroplasties performed in the patient. Notice the atypical fracture already consolidated. (B) Radiography in profile of the right knee evidencing the consolidation of the atypical fracture also in profile. (C) Radiography in profile of the left knee.

decided to treat the fracture and right arthrosis simultaneously by osteosynthesis with a blocked plaque and TKA (–Fig. 2). Primary prosthesis was used with posterior cruciate ligament replacement and fixed base (Vanguard, Zimmer Biomet, Warsaw, IN, USA). The procedure was performed with a single anterior incision extended to the knee, osteosynthesis of the tibial fracture following the principle of relative stability with a bridge locked anteromedial plate and slightly anteriorized proximal screws to allow the positioning of the prosthetic tibial component. Total knee arthroplasty was carried out, and femoral erosion was fully incorporated into the distal cut of the femur and tibial erosion compensated with autograft removed from the bone cuts themselves and fixed with screws of small fragments.

The patient reported significant improvement in terms of pain and functional complaints, abandoned the wheelchair, and presented an arc movement of 0 to 105° in the right knee (–Fig. 3).

Discussion

Bisphosphonates are among the most prescribed drugs for the treatment of osteoporosis. They decrease the risk of vertebral fractures by more than 50%, hip by 40 to 50%,

and other fractures by 20 to 25%.³ However, an association between AFs and their prolonged use was found.^{4,5}

The prolonged action of bisphosphonates can lead to the accumulation of microdamage and increase the risk of fractures.¹ Bisphosphonates may hinder the fracture consolidation process because they interfere in the bone remodeling phase and slow the maturation of the bone callus.

Few cases have been published in the literature. We do not know if more cases were reported but we couldn't find them in the performed literary review. This case presents the same epidemiological characteristics as others previously reported: middle-aged or older women, using bisphosphonates who suffered AFs, either atraumatically or with low-energy traumas.^{6–8}

In all cases, the radiological pattern follows that described by the American Society for Bone and Mineral Research (ASBMR) for femoral AFs (FAFs), except for localization.² In the tibia, primary involvement occurs in the anterior cortical, while, in the femur, it occurs in the lateral cortical. This may be related to the fact that the anterior cortical of the tibia is the region of tension concentration.⁶

Regarding the treatment of FAFs, the guidelines were defined by the ASBMR.² Bisphosphonates should be suspended, and the administration of calcium and vitamin D maintained. Prophylactic fixation is recommended for incomplete fractures accompanied by pain. In the absence of pain or radiographic radiolucency, treatment with analgesia and load removal should be adopted. In the absence of clinical improvement, surgical fixation should be considered for the possibility of progression to complete fracture. Regarding the risk of recurrence, Schilcher et al.⁹ observed that the risk of FAF dropped by 70%/year after bisphosphonate suspension. The tendency to worse results of conservative treatment in symptomatic incomplete FAF and with radiolucency was proven in the study by Saleh et al.¹⁰ Due to the scarcity of reported cases, there is no pattern for tibial fractures. However, since it is a load bone, it is suggested that the guidelines mentioned should be valid.

From the three previous cases already reported (one of them bilateral), two were treated conservatively. The third was performed by osteosynthesis with intramedullary tibia nail. In none of the cases it was chosen to perform TKA simultaneously, although there was associated gonarthrosis.

In the present case, the patient also had advanced gonarthrosis. This association increased the complexity of the case, because the treatment of AF would have implications in the surgical programming of the knee. We opted for a single-time approach and fracture fixation before arthroplasty to provide support for the tibial prosthetic component. The principle of relative stability in fracture management was respected, but the use of intramedullary nail becomes impossible due to the occupation of the medullary canal. The bridge plate, then, is a good alternative, but with the need for a certain anteriorization of the proximal locking screws, to allow the passage of the tibial component of the prosthesis without deviation from it, which would modify the prosthesis axis. Despite increasing the morbidity

of the procedure and the surgical time, the patient underwent only one anesthetic intervention and a single postoperative recovery.

The progressive aging of the population and the consequent increase in the number of individuals with osteoporosis undergoing treatment with bisphosphonates can lead to an increase in the incidence of AFs. Studies of how to best approach these fractures become important due to their particular difficulty in consolidation. Comorbidities of the musculoskeletal system increase the degree of treatment difficulty and require the surgeon to be rigorous in the choice, planning, and execution of treatment. In this case, the association of AF during treatment with bisphosphonates associated with joint degeneration with great bone erosion increased the degree of treatment difficulty. We considered that the result obtained was satisfactory and the approach of tibial osteotomy and TKA with primary prosthesis and use of autograft for tibial bone failures was adequate, avoiding exposure to sequential surgeries and thus reducing convalescence time.

Financial Support

There was no financial support from public, commercial, or non-profit sources.

Conflict of Interests

The authors declare that there is no conflict of interests.

References

- 1 Donnelly E, Saleh A, Unnanuntana A, Lane JM. Atypical femoral fractures: epidemiology, etiology, and patient management. *Curr Opin Support Palliat Care* 2012;6(03):348–354
- 2 Shane E, Burr D, Abrahamsen B, et al. Atypical subtrochanteric and diaphyseal femoral fractures: second report of a task force of the American Society for Bone and Mineral Research. *J Bone Miner Res* 2014;29(01):1–23
- 3 Geusens P. New insights into treatment of osteoporosis in postmenopausal women. *RMD Open* 2015;1(Suppl 1):e000051
- 4 Odvina CV, Zerwekh JE, Rao DS, Maalouf N, Gottschalk FA, Pak CY. Severely suppressed bone turnover: a potential complication of alendronate therapy. *J Clin Endocrinol Metab* 2005;90(03):1294–1301
- 5 Rodan GA, Fleisch HA. Bisphosphonates: mechanisms of action. *J Clin Invest* 1996;97(12):2692–2696
- 6 Bissonnette L, April PM, Dumais R, Boire G, Roux S. Atypical fracture of the tibial diaphysis associated with bisphosphonate therapy: a case report. *Bone* 2013;56(02):406–409
- 7 Imbuldeniya AM, Jiwa N, Murphy JP. Bilateral atypical insufficiency fractures of the proximal tibia and a unilateral distal femoral fracture associated with long-term intravenous bisphosphonate therapy: a case report. *J Med Case Reports* 2012;6:50
- 8 Breglia MD, Carter JD. Atypical insufficiency fracture of the tibia associated with long-term bisphosphonate therapy. *J Clin Rheumatol* 2010;16(02):76–78
- 9 Schilcher J, Koeppen V, Aspenberg P, Michaëlsson K. Risk of atypical femoral fracture during and after bisphosphonate use. *N Engl J Med* 2014;371(10):974–976
- 10 Saleh A, Hegde VV, Potty AG, Schneider R, Cornell CN, Lane JM. Management strategy for symptomatic bisphosphonate-associated incomplete atypical femoral fractures. *HSS J* 2012;8(02):103–110