

Contents lists available at [ScienceDirect](http://www.sciencedirect.com)

International Journal of Surgery Case Reports

journal homepage: www.casereports.com

Successful treatment of a chronic abdominal wall seroma with the polysaccharide 4DryField® PH – A case report



Andreas Kuthe (Dr., MD)

Department of General Surgery and Traumatology, DRK-Krankenhaus, Clementinenhaus, Lützerodestr. 1, 30161 Hannover, Germany

ARTICLE INFO

Article history:

Received 13 June 2016

Accepted 7 August 2016

Available online 11 August 2016

Keywords:

Starch based medical device

Chronic

Subcutaneous

Seroma

Liposuction

ABSTRACT

INTRODUCTION: Seroma formation is one of the most prevalent complications after liposuction, abdominoplasty, mastectomy or hernia repair. They can disappear without treatment, but also may persist and require complex therapy. This report describes how 4DryField® PH polysaccharide powder successfully was applied for chronic seroma therapy.

PRESENTATION OF THE CASE: An 80 year old male patient presented with a persistent seroma (1000 cm³ volume) resulting from liposuction about 15 years ago. In a first approach he was treated using en bloc excision without opening the capsule. Three month later the patient presented with a recurrent seroma of the same size. This time 1100 cm³ bloody discolored fluid was aspirated. The skin was lifted using a redon tubing drawn through the whole length of the wound cavity. This allowed even distribution of 4DryField® PH powder (10 g) within the former seroma cavity. Computed Tomography (CT) imaging after 4.5 month and sonographic examination after an additional year confirmed treatment success.

DISCUSSION: Besides conventional methods for hemos-/lymphostasis several adjunct measures like fibrin sealants, medication with corticoids and diurectics have been proposed for seroma prevention/therapy, unfortunately, with conflicting evidence. In an experimental study seroma prevention with a polysaccharide was demonstrated; however, clinical proof is missing. This case provides first clinical evidence that 4DryField® PH polysaccharide powder evenly distributed in the former seroma cavity can prevent its recurrence.

CONCLUSION: 4DryField® PH powder treatment of seroma is a promising new approach for prevention and treatment of chronic seroma.

© 2016 The Author. Published by Elsevier Ltd on behalf of IJS Publishing Group Ltd. This is an open access article under the CC BY-NC-ND license (<http://creativecommons.org/licenses/by-nc-nd/4.0/>).

1. Introduction

The superficial layers in the subcutaneous tissues are supplied by the vascular and lymphatic structures lying above the anterior rectus sheath and external oblique aponeurosis. [1]

During liposuction these blood and lymph vessel can get injured resulting in a risk of hematoma, lymphedema and/or seroma formation. [2]

Hematoma/seroma formation are common complications after liposuction. [3,4] Normally they disappear without treatment, however, in some cases they become persistent and a burden for patient and physician. Treatment is complex, can be unsuccessful and associated with complications. [5] This report describes a new technique for seroma therapy. Here 4DryField® PH polysaccharide powder successfully was applied to treat a chronic seroma.

2. Case report

An 80 year old male patient presented with an old symptomatic combined seroma/hematoma. The seroma/hematoma had resulted from liposuction approximately 15 years ago and had been unsuccessfully revised twice during postoperative course. Clinical examination revealed a subcutaneous sac in the right lower quadrant of the anterior abdominal wall. Magnetic Resonance Imaging (MRI) showed a multi-chambered liquid mass with a volume of 1000 cm³ (Fig. 1a).

The specimen was approached via a 20 cm incision. Having a dense fibrous capsule, it was resected en bloc without capsule opening. In the areas of rectus sheath and fascia of the external oblique muscle significant lacerations were induced which necessitated

extensive electro cautery and suturing. At the end of the procedure 2 redon drains were placed.

Histologic work-up revealed a 1000 g specimen containing fibrous sclerotized and hyalinized pseudo-cysts with old fibrin in organization and fluid in the lumen resembling with the residua of an old hematoma.

E-mail address: AKuthe@clementinenhaus.de

<http://dx.doi.org/10.1016/j.ijscr.2016.08.012>

2210-2612/© 2016 The Author. Published by Elsevier Ltd on behalf of IJS Publishing Group Ltd. This is an open access article under the CC BY-NC-ND license (<http://creativecommons.org/licenses/by-nc-nd/4.0/>).

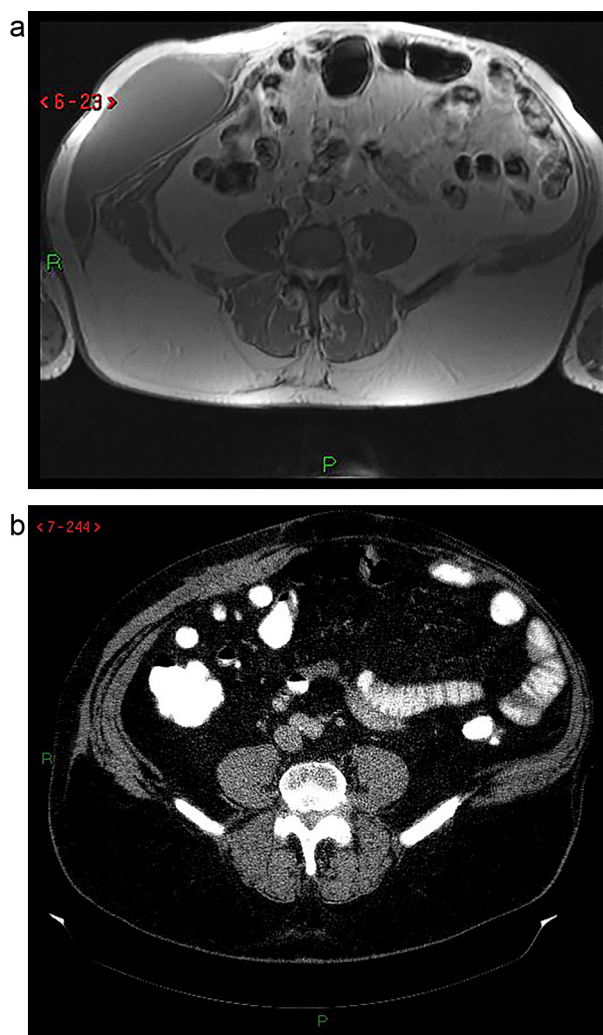


Fig. 1. Right abdominal wall chronic hematoma/seroma. a) MRI before treatment. b) CT 4.5 month after treatment with 10 g of 4DryField® PH powder.

At day 13 the amount of drain loss was <50 ml per day. Drains were removed. Due to lower leg edema and to reduce risk of seroma development the patient received Torasemid 5 mg per day and was discharged with this diuretic medication.

One week later he presented with 250 ml of fluid in the wound cavity. Unfortunately he had not taken the recommended diuretic. The fluid was drained with puncture. The patient was advised to take the subscribed diuretic.

Three months later the patient revealed a recurrent subcutaneous seroma, again having a volume of 1000 cm³ and the shape of the initial finding (Fig. 1a).

The patient was operated again in local anesthesia. Both ends of the old incision were infiltrated with local anesthetic. The cranial one incised and 1100 cm³ of bloody discolored serous fluid was removed. Now, the lower end was incised, too. A redon tube (16F) was pulled from one entry point to the other. By pulling up both ends of the redon tubing the skin was lifted tent shaped. With this action the cavity filled with air being essential for equal distribution of 4DryField® PH powder in the former seroma cavity (Fig. 2b). To access the central part of the cavity the 4DryField® PH applicator was extended with a 12F anesthetic tube (Fig. 2a). A total of 10 g 4DryField® PH powder were applied. Subsequently a redon drain was placed into the cavity. Suction was started a few hours later.

The patient was discharged on the following day and had daily check-ups. At day three drain loss was less than 30 ml with no liquid

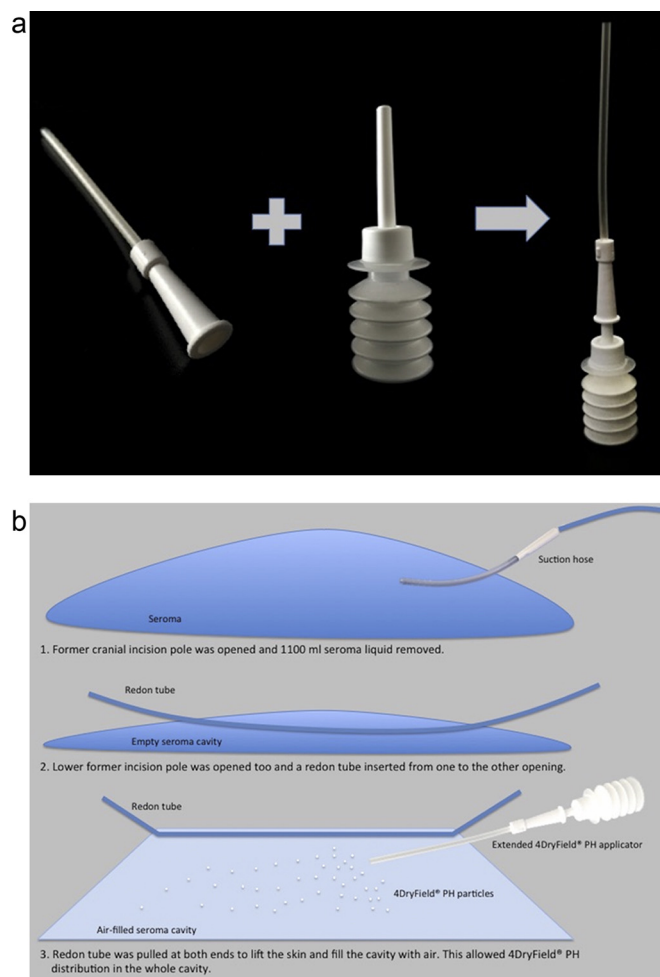


Fig. 2. Application strategy. a) 4DryField® PH applicator extended with shortened 12F anesthetic tube to access seroma cavity center. b) A redon drain was inserted from one pole of original incision to the other to lift the skin. Tent-shaped lifting of skin allowed for even distribution of 4DryField® PH in the wound cavity.

inside the former seroma cavity. The drain was removed after one week.

CT imaging after 4.5 month revealed subcutaneous scar tissue as a result of long chronic disease. There was minimal fluid left over indicating that 4DryField® PH was highly effective in preventing seroma reformation (Fig. 1b). One additional year later the patient was still free of clinical symptoms. No resistance, no fluctuation was found and the seroma was not visible from the outside. Sonographically a small oval shaped residual of 32 ml was identified directly on top of the fascia deep inside the subcutis smaller than at CT imaging.

3. Discussion

Seromas are exudative fluid accumulations occurring as post-surgical complications due to transection of blood and lymphatic vessels responsible for fluid absorption. In addition undermining of the dermis, shearing force between underlying tissues and flaps and dead space formation are risk factors. [6]

When seroma become persistent they impair the patients' quality of life and can be very difficult to treat. [7] Thus, prophylactic measures are advised.

Conventional preventive actions include compression, moderate electro-cautery, quilting/tension sutures, ligation of vessels and adequate drainage. Furthermore, corticosteroids, diuretics, and

intra-operative adhesive use (e.g. fibrin sealant) has been proposed. However, for many of these measures conflicting evidence exists. [8] In a study by Azoury et al., 2015 [9] on 250 patients with hernia repair for instance fibrin sealant did not reduce incidence of seroma formation. Bercial et al., 2012 [6] reported unsuccessful use of fibrin sealant while drainage reduced seroma incidence. In another study drainage was shown to reduce post-operative hematoma but not seroma formation [10]. In an experimental study in rats polysaccharide powder has been found to prevent seroma formation [11]. However, this was not confirmed clinically yet.

Our patient had suffered from a persistent hematoma/seroma since 1,5 decades. The presence of a severe fibrous capsule, scarring and pseudo-bursa formation like in our case is known to be associated with adverse outcome and frequently necessitates surgery. [8] This might explain its early recurrence after initial conventional therapy with capsulectomy, drainage and diuretic medication. Since 4DryField® PH certified [12] and effective hemostat [13] recently has been reported to be lymphostatic and also reduce the incidence of lymphocela in prostate cancer surgery [14] it was decided to use the polysaccharide powder for treatment of the chronic seroma. Essential for the success is our skin lifting technique since it made it possible to evenly distribute 4DryField® PH powder in whole wound cavity.

The rapidly ceasing drain loss after 4DryField® PH treatment allowed an early discharge. The long-term (>1 year) beneficial outcome underlines the sustainability of its beneficial effect.

4. Conclusion

We can conclude that 4DryField® PH polysaccharide can be applied for seroma prevention even in recurrent chronic cases. This promising new approach for seroma prophylaxis/therapy is worth investigating with prospective, randomized clinical trials.

Conflict of interest statement

None.

Funding

None.

Ethical approval

Retrospective case report. No ethics approval required. Patient gave informed consent for publication of his case (see Consent).

Consent

Patient consent form is attached to the submitted documents.

Author contribution

I, Andreas Kuthe am the only author and performed the related work.

Guarantor

Andreas Kuthe, MD.

References

- [1] M.A. Grevious, M. Cohen, S.R. Shah, P. Rodriguez, Structural and functional anatomy of the abdominal wall, *Clin. Plast. Surg.* 33 (2) (2006) 169–179, v.
- [2] J.S. You, Y.E. Chung, S.E. Baek, S.P. Chung, M.J. Kim, Imaging findings of liposuction with an emphasis on postsurgical complications, *Korean J. Radiol.* 16 (6) (2015) 1197–1206.
- [3] Y.H. Kim, S.M. Cha, S. Naidu, W.J. Hwang, Analysis of postoperative complications for superficial liposuction: a review of 2398 cases, *Plast. Reconstr. Surg.* 127 (2) (2011) 863–871.
- [4] Stephan PJ, Kenkel JM. Updates and advances in liposuction, *Aesthetic Surg. J./Am. Soc. Aesthetic Plast. Surg.* 30 (1) (2010) 83–97, quiz 8–100.
- [5] Z. Roje, Z. Roje, N. Karanovic, I. Utrobicic, Abdominoplasty complications: a comprehensive approach for the treatment of chronic seroma with pseudobursa, *Aesthetic Plast. Surg.* 30 (5) (2006) 611–615.
- [6] M.E. Bercial, M. Sabino Neto, J.A. Calil, L.A. Rossetto, L.M. Ferreira, Suction drains, quilting sutures, and fibrin sealant in the prevention of seroma formation in abdominoplasty: which is the best strategy? *Aesthetic Plast. Surg.* 36 (2) (2012) 370–373.
- [7] J. Lopez-Monclus, M.A. Garcia-Urena, L.A. Blazquez, D.A. Melero, C. Jimenez-Ceinós, Persistent inguinal seroma managed with sprinkling of talcum powder: a case report, *J. Med. Case Rep.* 6 (2012) 391.
- [8] M.A. Singer, K. Aliano, S. Stavrides, T. Davenport, Lymphatic mapping in the treatment of chronic seroma- a case series, *Eplasty* 15 (2015) 47–53.
- [9] S.C. Azoury, N. Rodriguez-Unda, K.C. Soares, C.W. Hicks, P.A. Baltodano, K.E. Poruk, et al., The effect of TISSEEL fibrin sealant on seroma formation following complex abdominal wall hernia repair: a single institutional review and derived cost analysis, *Hernia* 19 (6) (2015) 935–942.
- [10] M. Chaouat, P. Levan, B. Lalanne, T. Buisson, P. Nicolau, M. Mimoun, Abdominal dermolipectomies: early postoperative complications and long-term unfavorable results, *Plast. Reconstr. Surg.* 106 (7) (2000) 1614–1618.
- [11] T. Egeli, A.I. Sevinc, S. Bora, M.C. Yakut, T. Cevizci, T. Canda, et al., Dporous polysaccharide hemospheres and seroma formation after mastectomy and axillary dissection in rats, *Balkan Med. J.* 29 (2) (2012) 179–183.
- [12] PlantTec Medical GmbH, 4DryField® PH –provides hemostasis–prevents adhesions: instructions for use, rev. 6.0, 30.03.2015, Bad Bevensen, 76 pp., 2015. Available at <http://www.planttec-medical.de/produkte/> (last accessed 13.06.16).
- [13] A.A. Hanke, F. Flöricke, L. Sieg, K. Johanning, N. Rahe-Meyer, Effects of a new microporous polysaccharide powder on viscoelastic characteristics of clot formation, in: *Proceedings of the American Society of Anesthesiologists Annual Meeting (Anesthesiology '11)*, Chicago, Illinois, USA, 2011.
- [14] J. Karsch, M. Berthold, J. Breul, Evaluation of lymphorrhoea and incidence of lymphocele –4DryField® PH in radical retropubic prostatectomy, *Adv. Urol.* (2016).

Open Access

This article is published Open Access at sciedirect.com. It is distributed under the [IJSCR Supplemental terms and conditions](#), which permits unrestricted non commercial use, distribution, and reproduction in any medium, provided the original authors and source are credited.