

# Second-line antitubercular therapy with ethionamide and pyrazinamide causing pellagroid dermatitis presenting as diffuse palmoplantar keratoderma



Mahendra M. Kura, MD, DNB, Manjeet Naresh Ramteke, MD, and Supreet Kaur Dhillon, MBBS  
Mumbai, Maharashtra, India

**Key words:** dyssebacia; ethionamide; neuropsychiatry symptoms; palmoplantar keratoderma; pellagroid dermatitis.

## INTRODUCTION

Pellagra is a systemic disorder due to the deficiency of niacin and/or tryptophan, leading to the skin, gastrointestinal, and neuropsychiatric symptoms, presenting with the classical 4 Ds (dermatitis, diarrhea, dementia, and death).<sup>1,2</sup> The fifth D in pellagra has been identified, that is, dyssebacia, which is observed in approximately one-fifth of the patients.<sup>3</sup> Rarely, it can be secondary to antitubercular drugs, including isoniazid, ethionamide, and pyrazinamide, in which case it is referred to as pellagroid dermatitis (PD). The classical mucocutaneous manifestations include photosensitive dermatitis, Casal necklace, oral ulcers, cheilitis, glossitis, and scrotal/vulval dermatitis.<sup>4</sup> Rarer presentations include PD simulating lichen simplex chronicus.<sup>5</sup> We report a case of PD presenting with diffuse palmoplantar keratoderma (PK), which is hitherto unreported.

## CASE REPORT

A 26-year-old man presented with diffuse PK (Figs 1, A, and 2, A), with dyssebacia over the face and neck since the past 2 months. Examination revealed well-demarcated hyperpigmented plaques over the central portion of the face (Fig 3, A), palatal erosions, and scrotal dermatitis. He also experienced insomnia, irritability, hallucinations, and swaying while walking since the past 6 months. There was no history of diarrhea. He had received a

### Abbreviations used:

PD: pellagroid dermatitis  
PK: palmoplantar keratoderma

6-drug second-line antitubercular treatment with kanamycin, cycloserine, clofazimine, ethionamide, pyrazinamide, and linezolid along with pyridoxine for the past 15 months. The skin lesions developed in the penultimate month of his treatment. He also had a past history of levofloxacin-induced peripheral sensory neuropathy, which had started before the second-line antitubercular treatment and therefore discontinued. A detailed neurologic examination revealed impaired vibration and joint position and patchy hypoesthesia over both feet and legs with exaggerated deep tendon reflexes. Findings of the Romberg test were positive with swaying when asked to perform tandem walking, all suggestive of peripheral sensory neuropathy. Complete blood cell count and renal and liver function tests were unremarkable, except for mild hypoalbuminemia. The serum vitamin B12 level was normal (258 pg/mL). A skin biopsy (Fig 4) from the palm revealed hyperkeratosis, parakeratosis, and hypergranulosis without any inflammatory infiltrate. A nerve conduction study and magnetic resonance imaging of the brain were unremarkable, whereas magnetic resonance imaging of the spinal cord revealed diffuse disc bulges at the C5-C6 and C6-C7 levels, indenting

From the Department of Dermatology, Venereology and Leprosy, Grant Government Medical College, Mumbai.

Funding sources: None.

IRB approval status: Not applicable.

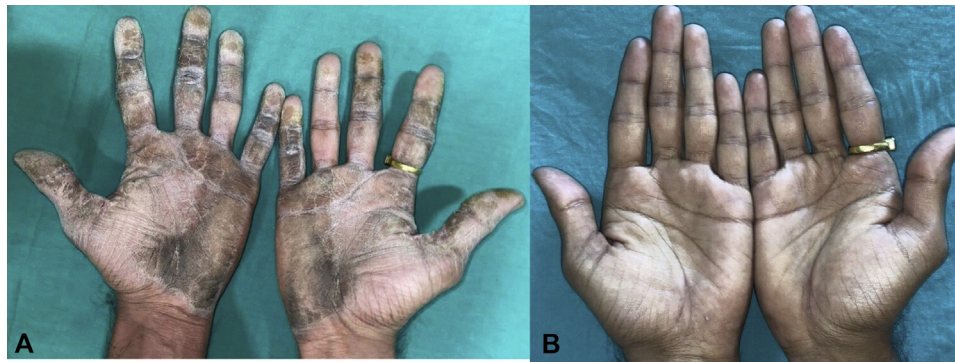Correspondence to: Manjeet Naresh Ramteke, MD, Department of Dermatology, Venereology and Leprosy, Grant Government Medical College, JJ Marg, Nagpada-Mumbai Central, Near Sandhurst Road and JJ Police Station, Mumbai, Maharashtra 400008, India. E-mail: [manjeetramteke@gmail.com](mailto:manjeetramteke@gmail.com).

JAAD Case Reports 2021;17:77-80.

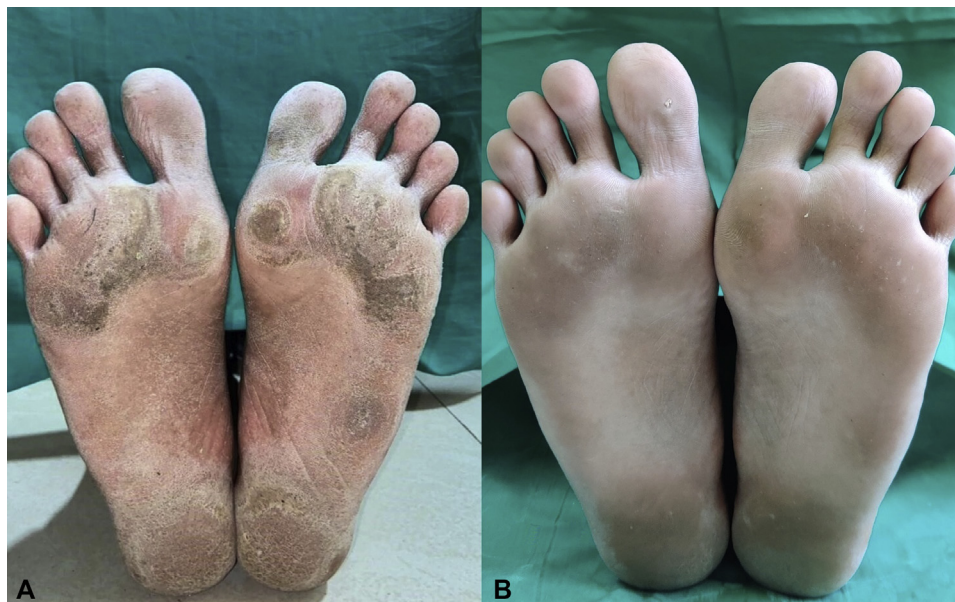2352-5126

© 2021 Published by Elsevier on behalf of the American Academy of Dermatology, Inc. This is an open access article under the CC BY-NC-ND license (<http://creativecommons.org/licenses/by-nc-nd/4.0/>).

<https://doi.org/10.1016/j.jidcr.2021.09.021>



**Fig 1.** Photographs before and after treatment. **A**, Hyperpigmented hyperkeratotic plaques with scaling present on both palms. **B**, Lesions resolved completely after treatment.



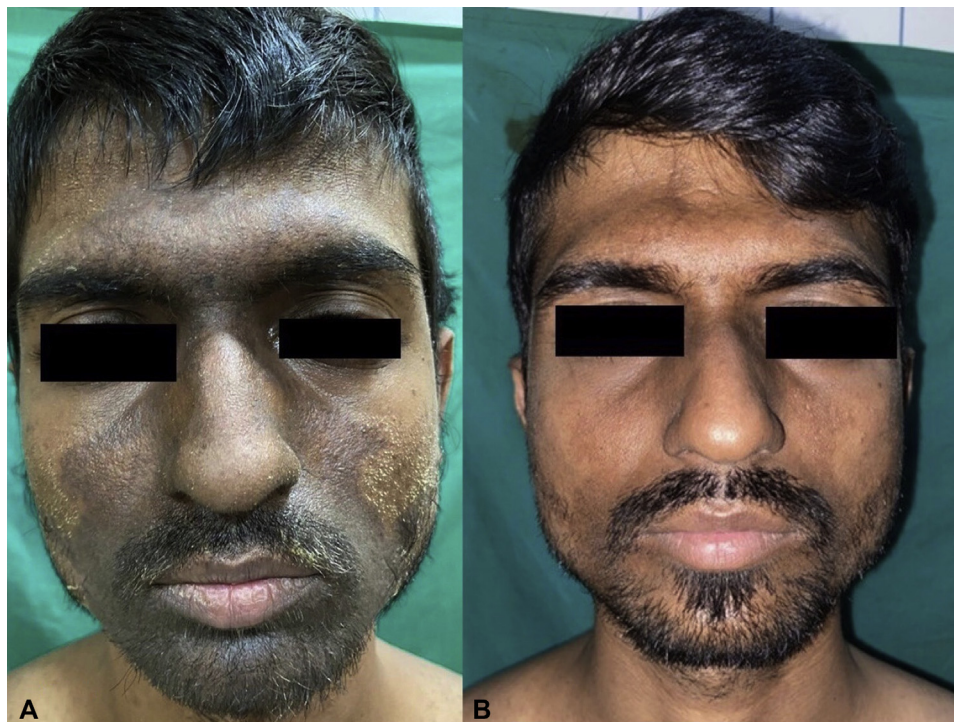**Fig 2.** Photographs before and after treatment. **A**, Hyperpigmented hyperkeratotic plaques with scaling present on both soles. **B**, Lesions resolved completely after treatment.

the ventral subarachnoid space. A diagnosis of PD secondary to second-line antitubercular therapy, ethionamide, and/or pyrazinamide was made. He was treated with oral nicotinamide 250 mg thrice a day with a multivitamin complex containing 50-mg nicotinamide, 2 tablets thrice a day, which resulted in the complete resolution of skin lesions (Figs 1, B; 2, B; and 3, B) as well as neuropsychiatric symptoms 12 weeks later.

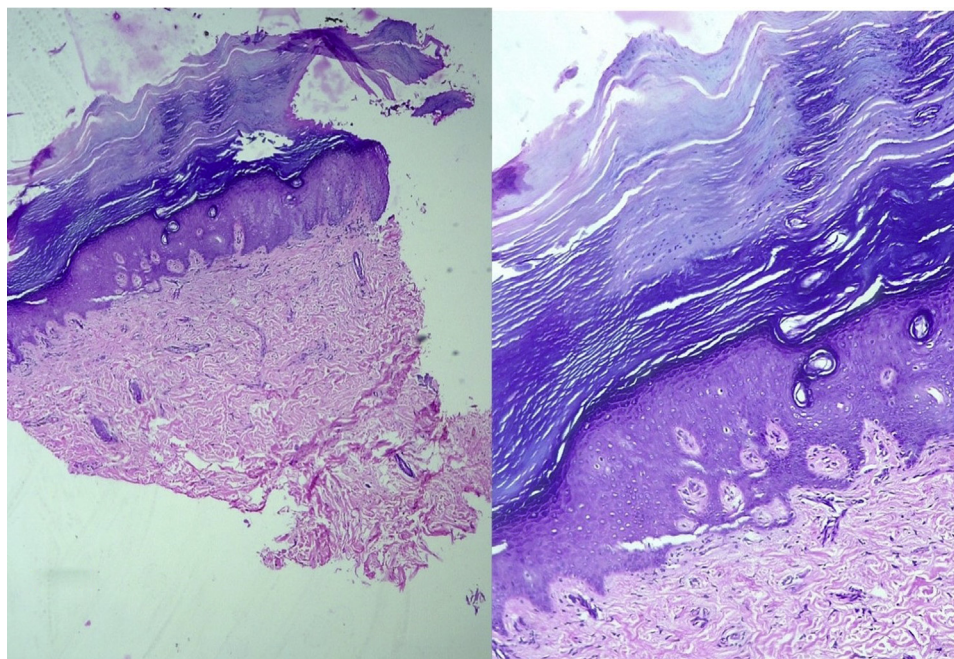
## DISCUSSION

Pellagra has been classically described using the 4 Ds of dermatitis, diarrhea, dementia, and death, although 33% of patients have dermatitis alone.<sup>6</sup> The dermatitis is characteristic and pathognomonic, distributed in photoexposed and pressure-prone areas. It includes a photosensitive eruption,

thickening with pigmentation of the skin over bony prominences,<sup>7,8</sup> and symmetrical erythema over the dorsal portions of the hands and forearm (pellagra gloves), front and back of the leg (boot), V area of the chest (Casal necklace), and over the nose and cheeks in a butterfly distribution. Later, the skin becomes dry, scaly, and hyperkeratotic, resembling the goose skin. Follicular hyperkeratosis on the face, porphyrinuria, funicular spinal syndrome, polyneuritis, and peripheral edema may also be present.<sup>9</sup> Recently, an atypical presentation of PD resembling lichen simplex chronicus has been described.<sup>5</sup> Mucosal findings include angular stomatitis, cheilitis, and glossitis. Dyssebacia is considered an early cutaneous marker of niacin deficiency and manifests as plugs of inspissated sebum projecting from dilated orifices of sebaceous glands.<sup>3</sup> It looks like



**Fig 3.** Photographs before and after treatment. **A**, Well-defined hyperpigmented plaque on the face with dyssebacia. **B**, Lesions healed completely after treatment.



**Fig 4.** Biopsy of the palm. **A**, Scanner view shows hyperplastic epidermis and normal dermis and subcutaneous tissue. **B**, Higher magnification shows hyperkeratosis, parakeratosis, and hypergranulosis in the epidermis.

seborrheic dermatitis confined to the face but is not related to sunlight. The gastrointestinal features include soreness of the tongue and mouth initially, with chronic gastritis and diarrhea later leading to

malabsorption.<sup>2</sup> Neuropsychiatric manifestations include headache, irritability, poor concentration, anxiety, delusions, hallucinations, stupor, apathy, tremors, ataxia, spastic paresis, and depression.

Occasionally, peripheral neuritis and myelitis may occur.<sup>9</sup>

Dyssebacia was very evident in our case; however, in contrast, our patient did not have classical photosensitive dermatitis. In addition, he had thickened, hyperpigmented plaques over the palms and soles, simulating diffuse PK, which is a novel manifestation. There was no involvement of the gastrointestinal system. Neuropsychiatric symptoms of insomnia, irritability, hallucinations, and ataxia were present.

There are various drugs causing PD, and these drugs act through different mechanisms, the most common ones being antitubercular drugs.

Among such antitubercular drugs, isoniazid is the most commonly implicated. They are structurally similar to nicotinamide adenine dinucleotide and thus competitively suppress endogenous niacin production. The hepatotoxicity of these drugs also adds to the decreased utilization of absorbed niacin and tryptophan.<sup>10,11</sup> A literature search on PubMed retrieved 40 cases of PD due to isoniazid, 3 cases due to ethionamide, and 1 case of pyrazinamide-related PD.

Drug-related keratoderma has also been described with the use of lithium, quinacrine, and chemotherapeutic agents such as bleomycin and hydroxyurea.<sup>12</sup>

The diagnosis of pellagra is based on the clinical presentation and response to niacin therapy. However, it can be supported with decreased levels of serum niacin, tryptophan, nicotinamide adenine dinucleotide, and nicotinamide adenine dinucleotide phosphate.<sup>8,9</sup> The recommended daily intake of niacin for adults is 14 mg to 16 mg per day, whereas the therapeutic dosage of nicotinamide or nicotinic acid is 500 mg/d over several weeks, followed by 50 mg to 100 mg daily for maintenance.<sup>4</sup> Patients with neuropsychiatric and gastrointestinal symptoms require higher dosages of 1 g, 3 to 4 times a day.<sup>9</sup> Nicotinamide is preferred because nicotinic acid can cause headache and flushing. Neuropsychiatric symptoms improve within the first 24 hours to

48 hours of treatment, whereas cutaneous disease may require weeks to remit.<sup>8</sup> Therapy should also include other B vitamins, zinc, magnesium, and a calorie-rich diet.

This case has been reported for its atypical presentation of PD secondary to second-line antitubercular therapy containing ethionamide and pyrazinamide, which was simulating acquired diffuse PK. Pellagra should be considered a cause of acquired diffuse PK in clinical practice, especially in the context of the increasing prevalence of multidrug-resistant tuberculosis.

#### Conflicts of interest

None disclosed.

#### REFERENCES

1. Brahmaiah U, Parveda AR, Hemalatha R, Laxmaiah A. Pellagra: a forgotten entity. *Clin Dermatol Rev*. 2019;3(2):126-129.
2. Pellagra and its prevention and control in major emergencies. World Health Organization. 2000. Accessed February 2, 2021. <https://www.who.int/publications/i/item/WHO-NHD-00.10>
3. Fred HL. "Dyssebacia"—a fifth D of pellagra. *Pract Gastroenterol*. 2003;27:41-42.
4. Christopher B, Vincent P. Nutritional disorders affecting the skin. In: Griffiths C, Barker J, Blieker T, Chalmers R, Creamer D, eds. *Rook's Textbook of Dermatology*. 9th ed. Blackwell Publishing; 2016:63.15-63.17.
5. Garg G, Khopkar U. Ethionamide-induced pellagroid dermatitis resembling lichen simplex chronicus: a report of two cases. *Indian J Dermatol Venereol Leprol*. 2011;77(4):534.
6. MacDonald A, Forsyth A. Nutritional deficiencies and the skin. *Clin Exp Dermatol*. 2005;30(4):388-390.
7. Dhawan AK, Grover C, Sharma S. Phenytoin induced pellagroid dermatitis. *Indian J Dermatol*. 2014;59(5):520-521.
8. Karthikeyan K, Thappa DM. Pellagra and skin. *Int J Dermatol*. 2002;41(8):476-481.
9. Hegyi J, Schwartz RA, Hegyi V. Pellagra: dermatitis, dementia, and diarrhea. *Int J Dermatol*. 2004;43(1):1-5.
10. Li R, Yu K, Wang Q, Wang L, Mao J, Qian J. Pellagra secondary to medication and alcoholism: a case report and review of the literature. *Nutr Clin Pract*. 2016;31(6):785-789.
11. Sinha P, Sood A, Baveja S, Pathania V. Docetaxel induced pellagroid dermatitis. *Indian J Dermatol Venereol Leprol*. 2018; 84(6):723-725.
12. Patel S, Zirwas M, English JC III. Acquired palmoplantar keratoderma. *Am J Clin Dermatol*. 2007;8(1):1-11.