

Syphilis, The Great Mimicker, Presents As a Rare Case of Concurrent Hepatitis and Gastroparesis

Brianna Shinn, MD¹, Charles Kistler, MD, PharmD², Raja Koteswar Dhanekula, MD², and Jesse Civan, MD²

¹Department of Medicine, Thomas Jefferson University Hospital, Philadelphia, PA

²Department of Medicine, Division of Gastroenterology and Hepatology, Thomas Jefferson University Hospital, Philadelphia, PA

ABSTRACT

Syphilis has been called “the great mimicker” given its ability to affect a wide variety of organs and subsequently present with a vast array of symptoms. The variability in clinical presentation seen in syphilis can make the diagnosis challenging. We describe a unique presentation of syphilis manifesting as hepatitis and gastroparesis. To our knowledge, this is the first case report with simultaneous hepatic and gastric involvement.

INTRODUCTION

Syphilis is a systemic disease caused by *Treponema pallidum*. Clinical manifestations of syphilis can vary greatly because it can involve almost every organ. Specifically, in the gastrointestinal tract, syphilis can lead to hepatitis, gastritis, colitis, proctitis, and gastroparesis.¹ We present a case that to our knowledge is the first case of syphilis leading to simultaneous hepatitis and gastroparesis.

CASE REPORT

A 44-year-old woman with no significant medical history presented to an outpatient gastroenterology clinic with a complaint of epigastric abdominal pain for a 1-month duration. Her abdominal pain was preceded by a week of fever, sore throat, body aches, and a diffuse pruritic rash involving the palms. She was treated with azithromycin but developed worsening abdominal pain, nausea, and early satiety days later. She denied use of any other medications, herbal supplements, high-risk behaviors, or alcohol use.

Laboratory work demonstrated abnormal liver function tests including aspartate aminotransferase (AST) 61 U/L, alanine aminotransferase (ALT) 173 U/L, alkaline phosphatase (ALP) 284 U/L, and total bilirubin 1.2 mg/dL. Abdominal ultrasound showed nonspecific peripancreatic and portacaval lymphadenopathy, confirmed on subsequent abdominal computed tomography scan (Figure 1). A magnetic resonance imaging with contrast of the abdomen was relatively unrevealing with no suspicious liver masses or hepatic steatosis and a persistently reactive 2.2 cm portacaval lymph node.

She subsequently underwent a gastric emptying study that showed markedly delayed gastric emptying with half time clearance of 369 minutes, consistent with gastroparesis. An esophagogastroduodenoscopy at the same time showed a few linear nonbleeding erosions less than 5 mm in the lower third of the esophagus and patchy erythema in the antrum consistent with gastritis on biopsy and negative for *Helicobacter pylori*. Repeat liver function tests a few weeks later demonstrated persistently elevated AST (58 U/L), ALT (72 U/L), and ALP (892 U/L). Additional laboratory tests were performed as well and revealed elevated antimitochondrial antibody to 57.3 U/L, antismooth muscle antibody to 36 U/L, and IgG to 2,005 mg/dL. Hepatitis B, C, and cytomegalovirus serologies were nonreactive, and mononucleosis, human immunodeficiency virus, antinuclear antibody, and antineutrophil cytoplasmic antibodies were negative.

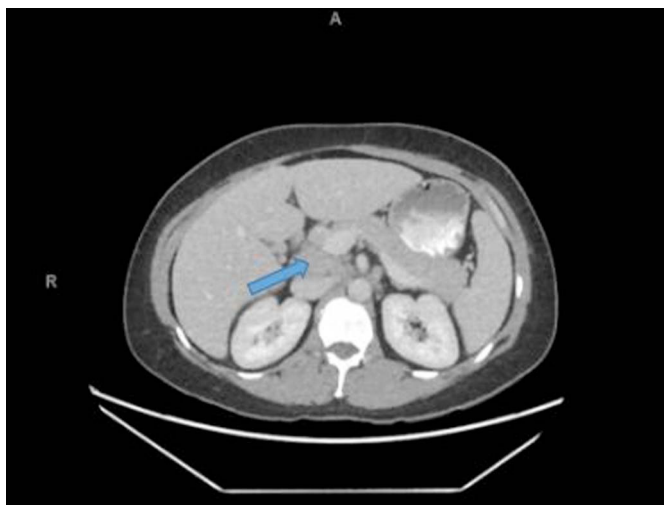

Figure 1. Abdominal computed tomography with an arrow pointing to the enlarged portacaval lymph node.

She then underwent percutaneous liver biopsy that demonstrated cholestatic hepatitis with prominent bile duct injury with inflammation and increased fibrosis (stage 1/4) (Figure 2). She was started on prednisone 20 mg once daily for possible autoimmune hepatitis and ursodiol 300 mg 3 times daily for possible primary biliary cholangitis, neither of which led to an improvement in symptoms.

Two weeks after the liver biopsy, the patient saw her gynecologist for vaginal irritation. She was screened for sexually transmitted diseases and was found to have a reactive RPR with a titer of 1:128 and *T. pallidum* antibodies consistent for secondary syphilis. Warthin-Starry stains of both the gastric and liver biopsy were completed but showed no evidence of spirochetes. The patient was treated with doxycycline 100 mg twice daily for 2 weeks because she had a penicillin allergy. Her rash, abdominal pain, and bloating resolved, liver enzymes normalized (AST 31 U/L

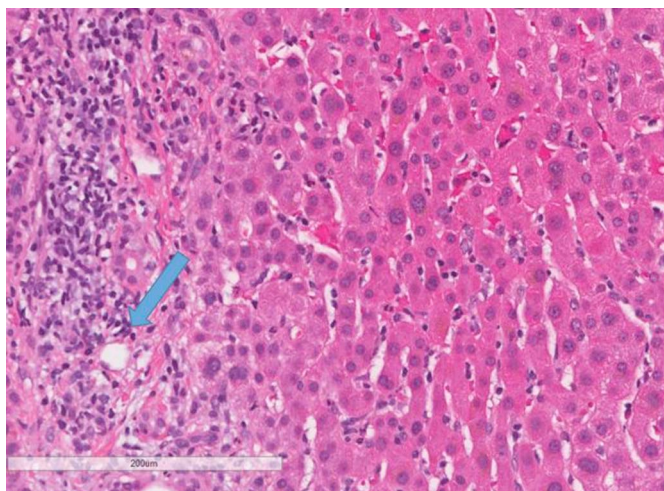


Figure 2. Liver biopsy showing cholestatic hepatitis, bile duct with prominent injury (arrow), inflammation, and increased fibrosis (stage 1/4).

and ALT 33 U/L), and ALP improved (120 U/L). ASMA and elevated total IgG levels normalized as well.

DISCUSSION

T. pallidum is a Gram-negative spirochete bacterium responsible for syphilis infections.² Most cases of syphilis are sexually acquired, and the clinical manifestations depend on the stage of the disease and the organs involved. Our patient specifically had secondary syphilis, manifestations of which include generalized symptoms of fever, headache, malaise, anorexia, sore throat, myalgias, and weight loss as well as rash, gastrointestinal and hepatic disease, headache, and vision changes.³ Gastric involvement is a rare presentation of syphilis that most commonly presents as gastritis. Our case was an even more rare presentation of gastric syphilis given the clinical presentation of gastroparesis.

As seen in our case, it is not uncommon to have negative gastric biopsies in gastric syphilis. A report published in 2005 reviewed documented cases of gastric syphilis since 1990 and found that only in 22 of the 33 cases spirochetes was detected on gastric biopsy.⁴ Reasons for negative biopsies include antibiotic administration before biopsy and abundant elastic and reticulum fibers in the stomach, making it difficult to detect spirochetes with silver stain.⁵ The cases of gastric syphilis in the literature with negative biopsy results diagnosed their patients based on positive RPR titer and/or *T. pallidum* antibodies and resolution of symptoms after treatment.⁶

In addition to gastric syphilis, we propose that our patient also had syphilitic hepatitis. Similar to gastric syphilis, syphilitic hepatitis is a rare finding and sporadically published in the literature. The clinical manifestations of syphilitic hepatitis include a rash, hepatomegaly, mild increase in transaminases and bilirubin, and marked elevation in ALP.¹ As seen in our patient, elevations in IgG and IgM as well as positive anti-mitochondrial antibody and ASMA can be seen because of cross-reactivity of these antibodies with membranous structures of *T. pallidum*.⁷⁻⁹ Similar to gastric syphilis, spirochetes are difficult to detect on liver biopsy. This is thought to be because of technical factors involved in the storage and staining of the biopsy as well as Kupffer cell phagocytosis of spirochetes.¹ The characteristic histological findings seen in syphilitic hepatitis include nonspecific periportal hepatocyte necrosis, pericholangiolar inflammation, and inconsistent demonstration of spirochetes.¹⁰ Despite the lack of spirochetes detected on our patient's liver biopsy, our case was very similar to previous cases of syphilitic hepatitis in that the patient had serological evidence for syphilis with improvement in liver function tests and resolution of symptoms after appropriate antimicrobial therapy.¹⁰

Our case is unique because it is the first report of simultaneous syphilitic hepatitis and gastroparesis. This case highlights the varied manifestations of syphilis and the importance of testing for sexually transmitted diseases in patients with risk factors.

DISCLOSURES

Author contributions: B. Shinn wrote the manuscript. C. Kistler, RK Dhanekula, and J. Civan edited and reviewed the manuscript. J. Civan is the article guarantor.

Financial disclosure: None to report.

Informed consent was obtained for this case report.

Received June 19, 2018; Accepted March 5, 2019

REFERENCES

1. Noto P, Del Nonno F, Licci S, et al. Early syphilitic hepatitis in an immunocompetent patient: Really so uncommon? *Int J STD AIDS* 2008;19:65–6.
2. Kim K, Kim EJ, Kim M, et al. Clinicopathological features of syphilitic gastritis in Korean patients. *Pathol Int* 2009;59:884–9.
3. Golden MR, Marra CM, Holmes KK. Update on syphilis: Resurgence of an old problem. *JAMA* 2003;290(11):1510.
4. Guerrero AF, Straight TM, Eastone J, et al. Gastric syphilis in an HIV-infected patient. *AIDS Patient Care STDS*. 2005;19:281–5.
5. Inagaki H, Kawai T, Miyata M, et al. Gastric syphilis: Polymerase chain reaction detection of treponemal DNA in pseudolymphomatous lesions. *Hum Pathol* 1996;27:761–5.
6. Gamenthaler A, Moon N, Lucero S. Colitis and gastroparesis associated with syphilis in an HIV infected person with an undetectable viral load. *AIDS Read* 2009;19(6):230–44.
7. Feher J, Somogyi T, Timmer M, et al. Early syphilitic hepatitis. *Lancet* 1975; 2:896–9.
8. Berg PA, Klein R. Antimitochondrial antibodies in primary biliary cirrhosis and other disorders: Definition and clinical relevance. *Dig Dis* 1992;10: 85–101.
9. Husby G, Pierce P, Williams RC. Smooth muscle antibody in heroin addicts. *Ann Intern Med*. 1975;83(6):801–5.
10. Mullick CJ, Liappis AP, Benator DA, et al. Syphilitic hepatitis in HIV-infected patients: A report of 7 cases and review of the literature. *Clin Infect Dis* 2004;39(10):100–5.

Copyright: © 2019 The Author(s). Published by Wolters Kluwer Health, Inc. on behalf of The American College of Gastroenterology. This is an open-access article distributed under the terms of the Creative Commons Attribution-Non Commercial-No Derivatives License 4.0 (CCBY-NC-ND), where it is permissible to download and share the work provided it is properly cited. The work cannot be changed in any way or used commercially without permission from the journal.