



Case Series

Double central ray amputation of the third and fourth digits for recurrent giant cell tumors of the hand: A case report



Muhammad Phetrus Johan^{a,*}, Dario Agustino Nelwan^b, Imeldy Prihatni Purnama^c, Ira Nong^a, Khrisna Yudha^a, Vicky William Paundanan^a

^a Department of Orthopaedics and Traumatology, Dr. Wahidin Sudirohusodo General Hospital - Faculty of Medicine Hasanuddin University, Makassar, Indonesia

^b Department of Radiology, Dr. Wahidin Sudirohusodo General Hospital - Faculty of Medicine Hasanuddin University, Makassar, Indonesia

^c Department of Pathology Anatomy, Dr. Wahidin Sudirohusodo General Hospital - Faculty of Medicine Hasanuddin University, Makassar, Indonesia

ARTICLE INFO

Article history:

Received 12 January 2021

Received in revised form 28 January 2021

Accepted 29 January 2021

Available online 1 February 2021

Keywords:

Case report

Recurrent giant cell tumors hand

Recurrent GCT

GCT hand

Double central ray amputation

Ray amputation third fourth digits

ABSTRACT

INTRODUCTION AND IMPORTANCE: Recurrent giant cell tumor of the bone (GCTB) of the hand is very rare to be encountered. Our aim is to alert the surgeons to such condition and double central ray amputation of the third and fourth digits could be an option which may reduce the chance of a re-recurrence and provide an acceptable functional outcome.

CASE PRESENTATION: We presented a 25-year-old woman with a recurrent GCTB of the proximal phalanx of the middle finger of the right hand. Considering the recurrent case, a high suspicion of malignancy, and apparent soft tissue extension, the lesion was treated with double central ray amputation of the third and fourth digits through metacarpals.

CLINICAL DISCUSSION: Extrasosseous soft tissue invasion of recurrent GCTB of the hand had an important role in the treatment recommendation. A balance must be considered between the risk of re-recurrence and the impact of radical resection on function. Double central ray amputation surgery was performed in order to decrease the risk of additional recurrences. Acceptable functionality of the hand as she scored 26/30 (86 % rating) evaluated by Musculoskeletal Tumor Society (MSTS) Scoring System and no signs of local re-recurrence were found for 6 months follow up.

CONCLUSION: Double central ray amputation of the third and fourth digits is a good option for management of recurrent GCTB of proximal phalanx of the third digits with gross soft tissue extension to adjacent fourth digits region.

© 2021 The Authors. Published by Elsevier Ltd on behalf of IJS Publishing Group Ltd. This is an open access article under the CC BY-NC-ND license (<http://creativecommons.org/licenses/by-nc-nd/4.0/>).

1. Introduction

Giant cell tumor (GCT) in the small bones of the hand is a benign but locally aggressive osteolytic bone tumor [1]. The tumors generally arise in the metaphyseal regions with an incidence of 1%–5% in the hand [1–4]. GCT of the phalangeal bones is very rare. It develops at a younger age and tends to be more aggressive compared with those who had the tumors in the long bones [5–7].

The recurrence rate of GCT of the bones (GCTB) of the hand is higher than for other location [8,9]. Local recurrences resulting from inadequate treatment after curettage and bone grafting

have been reported to be as high as 90% [5,8,10,11]. Few studies have analyzed treatment guidelines in the management of recurrent GCTB of the hand particularly when they include extensive soft tissue involvement.

Our aim is to alert the surgeons to such condition and double central ray amputation of the third and fourth digits could be an option which may reduce the chance of a re-recurrence and provide an acceptable functional outcome. The work has been reported in line with SCARE 2020 criteria [12].

2. Presentation of case

An otherwise healthy 25-year-old right hand dominant woman first noticed a mass at the proximal phalanx of the middle finger of the right hand in 2015. An intralesional curettage and bone grafting had been performed elsewhere initially. Pathology report proved the diagnosis of GCTB. Review of the previous imaging revealed

* Corresponding author at: Department of Orthopaedics and Traumatology, Dr. Wahidin Sudirohusodo General Hospital - Faculty of Medicine Hasanuddin University, Jl. Perintis Kemerdekaan Km 10, Hasanuddin University Hospital 3rd Floor, Makassar, Indonesia.

E-mail address: muhpjo@gmail.com (M.P. Johan).

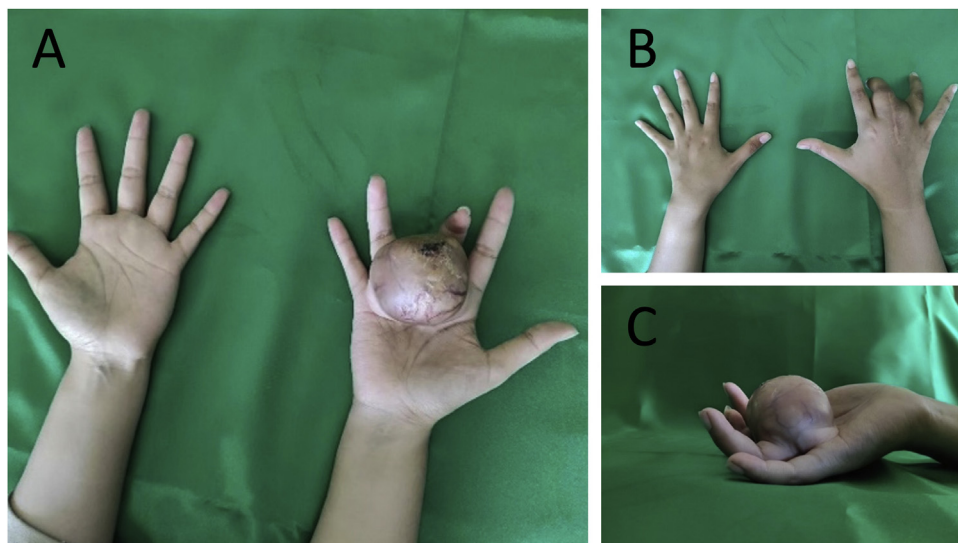


Fig. 1. Clinical images of the swelling in the hand from the (A) volar, (B) dorsal, (C) lateral aspects.

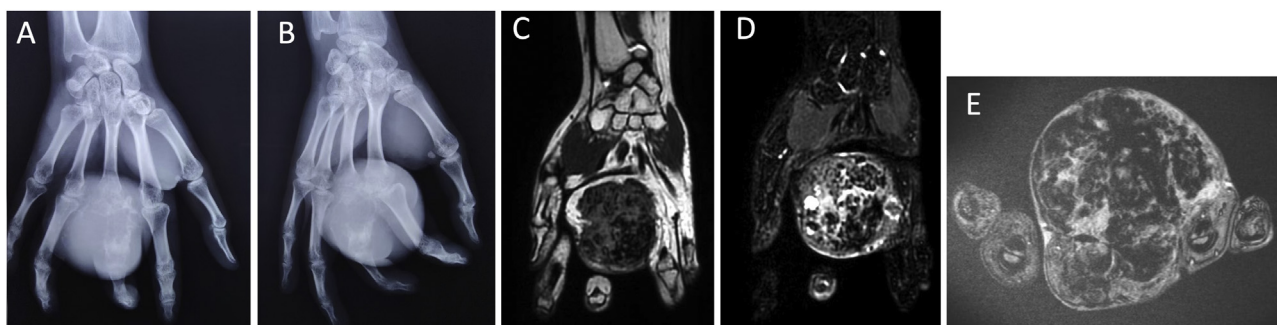


Fig. 2. Hand radiographs from (A) posteroanterior and (B) oblique revealed an expansile lytic lesion involving the proximal phalanx of the third digit with cortical breach and gross soft tissue extension as well as extension into metacarpophalangeal joint. MRI images show a heterogenous mass appearing hypointense on coronal T1-weighted image (C), hyperintense on coronal (D) and axial (E) T2-weighted images.

a lesion of Campanacci stage 3. About 1.5 years after the surgery, follow-up Magnetic Resonance Imaging (MRI) showed a definite enhancing soft tissue mass around the surgical tumor area that was considered as a local recurrence of GCTB. From then on, she noted a fairly progressive swelling in the right hand at base of 3rd digit but had been hesitant to seek care. She presented to our outpatient clinic 5 years following the index procedure when the pain and swelling became unbearable. She denied any history of trauma, constitutional symptoms and familial heritable disease. Physical examination revealed a diffuse tender mass with venectasia and firm consistency of approximately $6 \times 5 \times 6$ cm size on the dorsoventral aspect leading to subsequent restriction of movement of metacarpophalangeal (MCP) joint of 3rd and 4th digits (Fig. 1). The overlying skin on the volar aspect was stretched with adherence to the underlying mass. There was a post operation scar of 5 cm in length on the dorsal aspect. Regional lymph nodes were not palpable. Blood biochemistry values were unremarkable. A radiograph of the hand showed a large expansile lytic lesion involving the whole proximal phalanx of the third digit with an associated soft tissue extension and destruction of MCP joint. MRI revealed a mass of $66 \times 56 \times 66$ mm on the proximal phalanx of middle finger extended into the third web space and region of third and fourth MCP joints. The lesion was heterogeneously hypointense on T1W images and hyperintense on T2W images (Fig. 2). Chest CT scan revealed no sign of metastasis. Considering the recurrent case, a high suspicion of malignancy, and apparent soft tissue extension, the lesion was treated with double central ray amputation of the

third and fourth digits through metacarpals in order to decrease the risk of additional recurrences. The patient understood the potential risk of local re-recurrence of the tumor and hand dysfunction.

Under general anesthesia, the patient was laid in the supine position. Operation was done by an orthopedic oncology surgeon assisted with a general orthopedic surgeon and two residents of general orthopedic surgery. We performed a V-shaped incision incorporating the volar and the dorsal incision. We continued our dissection in layers and did osteotomy at the base of 3rd and 4th metacarpal bones. We isolated and divided the digital nerves and digital vessels supplying the 3rd and 4th digits. Afterwards, the remaining area was entirely removed by en bloc resection and was sent for definitive pathology evaluation. We also sent tissue samples for frozen section to evaluate our margins. The result showed that the mass was completely excised with negative margins all around. Under no tension, we approximated the skin edge, and the skin graft was used to cover the soft tissue defect. The temporary kirschner wire transfixations were applied to maintain the 2nd and 5th metacarpophalangeal joints at the functional position for 4 weeks (Fig. 3). A standard post-operative regimen including antibiotics, analgetic and wound dressings was provided.

Histological evaluation of excised tumor reconfirmed the diagnosis of a GCTB, showing osteoclastic giant cells with stromal cells in the background with areas of hemorrhage (Fig. 4). Post-operative period was uneventful. Upon subsequent post-operative follow-up for the last 6 months, she is able to use her fingers for pinching, writing and grasping without any pain and significant stiffness (Fig. 5).

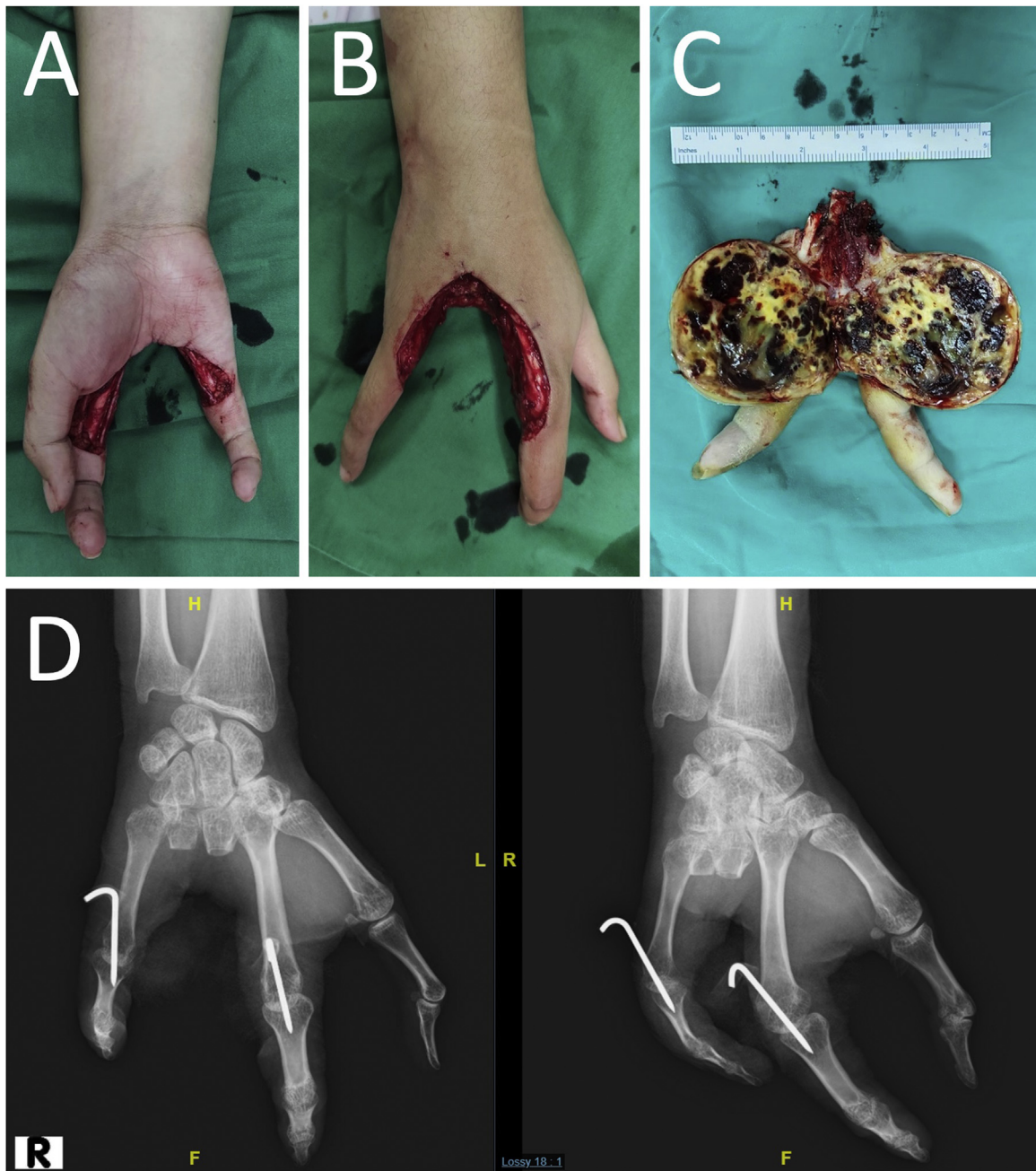

Fig. 3. Intraoperative after metacarpal ray resection of the third and fourth digits from the (A) volar and (B) dorsal aspects; (C) Gross appearance of Giant Cell Tumor atypically involving the proximal phalanx of the middle finger with soft tissue extension; (D) Post-operative X rays.

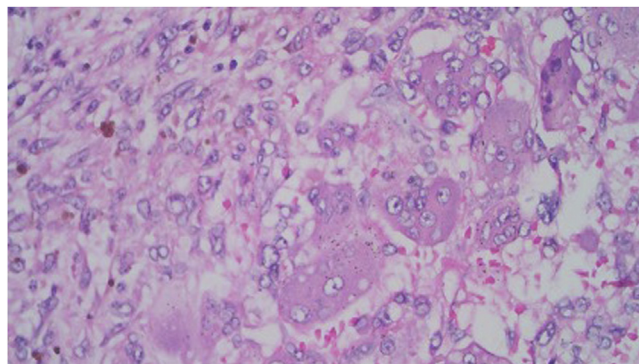


Fig. 4. Histological picture shows multinucleated giant cells with stromal cells in the background with areas of hemorrhage. The nuclei of giant cells and the mononuclear stromal cells have the same appearance. (H & E, original magnification X 400).

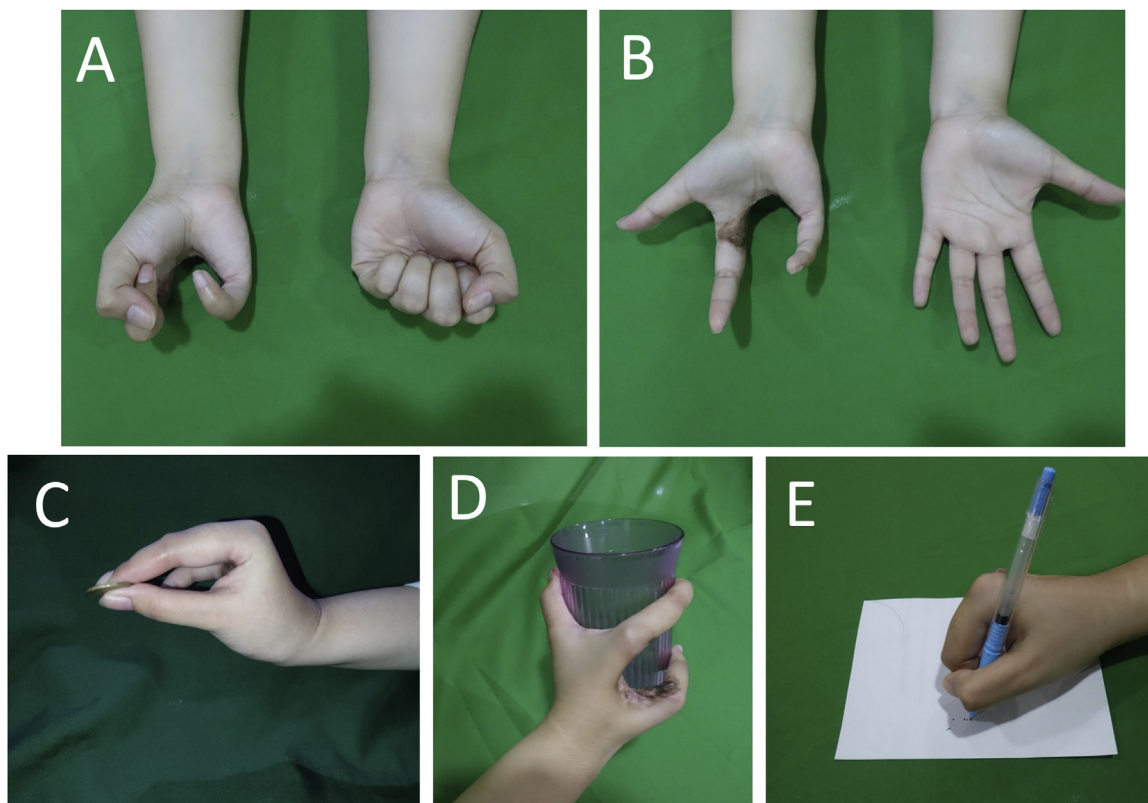


Fig. 5. Clinical photograph at 6-month follow-up with (A) fingers flexion and (B) fingers extension. No sign of re-recurrence was seen. For manual dexterity, the patient is able to perform (C) pinching, (D) grasping, and (E) writing.

There were no signs of local recurrence or any metastasis until the last follow up (6 months post-surgery). The patient was pleased with the end results and was able to maintain acceptable function of her hand in activities of daily living. A written consent was obtained to submit her clinical case report.

3. Discussion

Only 2 % of the reported GCTs are found in the hand and a primary lesion in the phalanges has been rarely encountered. Review of the literature revealed that of greater than 2400 cases of GCT, not more than 50 lesions were discovered involving the phalanges of the hand [11]. In two studies of 108 and 124 skeletal GCT, Coley et al. and Sakia et al. found only two cases of phalangeal involvement [13,14]. Goldenberg et al. in their evaluation of 218 cases of skeletal GCTs, described six cases involving the phalanges [15]. Another large series of 327 and 407 cases of GCTs, the authors reported only 1 and 3 instances of GCT arising from the phalanges, respectively [16,17].

Surgical treatment for phalanges-based tumors ranges from salvage procedure such as intralesional curettage filling with bone graft, en-bloc resection along with reconstruction to ray amputation [5,14,18,19]. Management of primary GCTs of the phalanges is demanding due to its high rates of recurrence. Patel et al. described two out of three patients of GCT involving the phalanges of the hand that initially treated with curettage and bone grafting had recurrence within 1 year [11].

Due to the fact that the web spaces do not have any fascial layer, there are no anatomic compartmental borders among proximal phalanges [11]. A concern should therefore be considered in the recurrent lesion arising from proximal phalanges, since it can occur as an extensive soft tissue involvement as seen in the present case. Digits salvaging procedure of recurrent GCTs of the

hand was proposed only when sufficient surgical margins could be achieved, otherwise amputation or ray resection has usually been recommended to achieve optimal eradication of the lesions [9]. Furthermore, extraosseous soft tissue invasion had an important role in our treatment recommendation. This is particularly complicated in the hand since it increases the risk of re-recurrence and vital structures or adjacent bones involvement. Athanasian et al. described 5 patients with GCTs of bone involving the hand with extraosseous extension had a 100 % recurrence after treated with curettage, therefore the authors suggested en bloc resection or amputation in stage 3 lesions when soft tissue are invaded [9]. Another author recommended resection of both rays in case reports of GCTs involving proximal phalanges related with extraosseous extension as well as encroachment onto adjacent ray [11]. The patient was free of disease at 2-year follow-up. A balance must be considered between the risk of re-recurrence and the impact of radical resection on function. After thoughtful consideration and discussion with the patient in the present case to obtain a tumor-free margin, we recommended a double ray resection surgery of the third and fourth digits due to initial treatment failure as well as the gross extraosseous extension proximally into the third webspace and the region of the third and fourth MCP joints.

Functional outcomes after partial hand amputations depend on the number of structures that is preserved, with worse outcomes for more radical amputations such as double ray amputations. Nevertheless, it still provides a function that is better than hand amputation or prosthesis [20]. In the present case, after the patient went through central double ray amputation of the third and fourth digits of the hand, he was still capable of maintaining a good functional ability of the hand to perform activities of daily living, as she scored 26/30 (86 % rating) (Table 1) on the MSTS scoring system at 6 months after surgery. To our knowledge, this is the second

Table 1
Musculoskeletal Tumor Society (MSTS) scoring system for the upper extremity.

| Score | Pain | Functional Activity | Hand Positioning | Dexterity | Lifting Ability (muscle power) | Emotional Acceptance |
|-------|-------------------------------------|--|---|---|--|----------------------|
| 5 | No pain | No restriction (No disability) | Unlimited (can be elevated 180°) | No limitations | Normal load (muscle power 5) | Enthusied |
| 3 | Modest / Non-disabling | Recreational restriction (Minor disability) | Not above shoulder or no pronation supination (can be elevated 90°) | Loss of fine movements (buttoning, writing, eating) | Minor load (muscle power 3) | Satisfied |
| 1 | Moderate / Intermittently disabling | Partial Occupational restriction (Major disability) | Not above waist (can be elevated 30°) | Cannot pinch | Cannot overcome gravity (muscle power 2) | Accepts |
| 0 | Severe / Continuously disabling | Total Occupational restriction (Complete disability) | None (0° elevation) | Cannot grasp | Cannot move (muscle power 0,1) | Dislikes |

Outcome measure was done 6 months after the operation at outpatient clinic. The patient reported no pain, minor disability and was able to elevate the hand 180° in frontal plane without restriction in pronation/supination; pinch, grasp and fine movements can be performed; muscle power grade 5 and was satisfied with the end results, scoring 26/30 points (86 % rating) (marked in bold fonts).

case report of double central ray amputation of the third and fourth digits with acceptable hand function.

4. Conclusion

In conclusion, surgical treatment of recurrent GCTB of the proximal phalanx of the middle finger with extensive soft tissue extension into the third web space using double central ray amputation of the third and fourth digits is a good option since it decreases the possibility of re-recurrence and show an acceptable hand function.

Declaration of Competing Interest

The authors declare that there are no conflicts of interest regarding the publication of this article.

Funding

The research did not receive any specific grant from funding agencies in the public, commercial, or not-for-profit sectors.

Ethical approval

All investigators ensure that the conduct of this study is in accordance with the ethical standards of their respective institution as laid down in the 1964 Declaration of Helsinki.

Consent

Written informed consent was obtained from the patient for publication of this case report and accompanying images. A copy of the written consent is available for review by the Editor-in-Chief of this journal on request.

Author contribution

MPJ contributed to perform the surgery, conceptualization, methodology, clinical data investigation, curation and interpretation; DAN contributed to radiological data curation and interpretation; IPP contributed to pathological data curation and interpretation; IN contributed to assist the surgery, clinical data interpretation; KY contributed to clinical data curation and interpretation. VWP contributed to assist the surgery, clinical data

curation and interpretation. All authors: writing – original draft, review, editing and approved the final manuscript for publishing.

Registration of research studies

Not Applicable.

Guarantor

Muhammad Phetrus Johan, MD., PhD.

Provenance and peer review

Not commissioned, externally peer-reviewed.

Acknowledgment

None.

References

- [1] U. Meena, Y. Sharma, N. Saini, D. Meena, N. Gahlot, Giant cell tumours of hand bones: a report of two cases, *J. Hand Microsurg.* 7 (2015) 177–181, <http://dx.doi.org/10.1007/s12593-014-0145-3>.
- [2] W.T. Payne, G. Merrell, Benign bony and soft tissue tumors of the hand, *J. Hand Surg.* 35 (2010) 1901–1910, <http://dx.doi.org/10.1016/j.jhnsa.2010.08.015>.
- [3] A.F. Mavrogenis, G.N. Panagopoulos, A. Angelini, J. Lesenský, C. Vottis, P.D. Megalioikonos, Z.T. Kokkalis, V. Kontogeorgakos, P. Ruggieri, P.J. Papagelopoulos, Tumors of the hand, *Eur. J. Orthop. Surg. Traumatol.* 27 (2017) 747–762, <http://dx.doi.org/10.1007/s00590-017-1984-y>.
- [4] K.L.C. Yue, J. Lans, R.M. Castelein, D.I. Suster, G.P. Nielsen, N.C. Chen, S.A. Lozano-Calderón, Benign hand tumors (Part I): cartilaginous and bone tumors, *Hand* (2020), <http://dx.doi.org/10.1177/1558944720922921>.
- [5] E.A. Athanasian, L.E. Wold, P.C. Amadio, Giant cell tumors of the bones of the hand, *J. Hand Surg.* 22 (1997) 91–98, [http://dx.doi.org/10.1016/S0363-5023\(05\)80187-X](http://dx.doi.org/10.1016/S0363-5023(05)80187-X).
- [6] R. Biscaglia, P. Bacchini, F. Bertoni, Giant cell tumor of the bones of the hand and foot, *Cancer* 88 (2000) 2022–2032, [http://dx.doi.org/10.1002/\(SICI\)1097-0142\(20000501\)88:9<2022::AID-CNCR6>3.0.CO;2-Y](http://dx.doi.org/10.1002/(SICI)1097-0142(20000501)88:9<2022::AID-CNCR6>3.0.CO;2-Y).
- [7] M. Yanagisawa, K. Okada, T. Tajino, T. Torigoe, A. Kawai, J. Nishida, A clinicopathological study of giant cell tumor of small bones, *Ups. J. Med. Sci.* 116 (2011) 265–268, <http://dx.doi.org/10.3109/03009734.2011.596290>.
- [8] R.M. Averill, R.J. Smith, C.J. Campbell, Giant-cell tumors of the bones of the hand, *J. Hand Surg.* 5 (1980) 39–50, [http://dx.doi.org/10.1016/S0363-5023\(80\)80042-6](http://dx.doi.org/10.1016/S0363-5023(80)80042-6).
- [9] E. Athanasian, *Bone and soft tissue tumors*, in: D. Green, R. Hotchkiss, W. Pederson, S. Wolfe (Eds.), *Green's Operative Hand Surgery*, Vol. 5, 5th ed., 2005, pp. 2255–2256.
- [10] L.E. Wold, R.G. Swee, Giant cell tumor of the small bones of the hands and feet, *Semin. Diagn. Pathol.* 1 (1984) 173–184, <http://dx.doi.org/10.1302/0301-620x.95b6.30876>.
- [11] M.R. Patel, S.S. Desai, S.L. Gordon, G.A. Nimberg, S.J. Sclafani, V.J. Vigorita, J.H. Mirra, H.W. Sung, Management of skeletal giant cell tumors of the phalanges

- of the hand, *J. Hand Surg.* 12 (1987) 70–77, [http://dx.doi.org/10.1016/S0363-5023\(87\)80163-6](http://dx.doi.org/10.1016/S0363-5023(87)80163-6).
- [12] R.A. Agha, T. Franchi, C. Sohrabi, G. Mathew, A. Kerwan, The SCARE 2020 guideline: updating consensus surgical Case REport (SCARE) guidelines, *Int. J. Surg.* 84 (2020) 226–230, <http://dx.doi.org/10.1016/j.ijssu.2020.10.034>.
- [13] B.L. Coley, N.L. Higinbotham, T. Kogure, Giant cell tumor of bone, *Am. J. Surg.* 96 (1958) 479–491, [http://dx.doi.org/10.1016/0002-9610\(58\)90963-2](http://dx.doi.org/10.1016/0002-9610(58)90963-2).
- [14] K.C. Saikia, S.K. Bhuyan, S. Goswami, A. Bora, Rare site giant cell tumors: report of two cases on phalanges of the finger and review of literature, *J. Orthop. Traumatol.* 10 (2009) 193–197, <http://dx.doi.org/10.1007/s10195-009-0067-1>.
- [15] R.R. Goldenberg, C.J. Campbell, M. Bonfiglio, Giant-cell tumor of bone. An analysis of two hundred and eighteen cases, *J. Bone Joint Surg. Am.* 52 (1970) 619–664, <http://dx.doi.org/10.2106/00004623-197052040-00001>.
- [16] M. Campanacci, N. Baldini, S. Boriani, A. Sudanese, Giant-cell tumor of bone, *J. Bone Jt. Surg. - Ser. A.* 69 (1987) 106–114, <http://dx.doi.org/10.2106/00004623-198769010-00018>.
- [17] D.C. Dahlin, Giant cell tumor of bone: highlights of 407 cases, *Am. J. Roentgenol.* 144 (1985) 955–960, <http://dx.doi.org/10.2214/ajr.144.5.955>.
- [18] M. Ropars, R. Kaila, S.R. Cannon, T.W.R. Briggs, Primary giant cell tumours of the digital bones of the hand, *J. Hand Surg.* 32 (2007) 160–164, <http://dx.doi.org/10.1016/j.jhsb.2006.11.009>.
- [19] M.J. DeRogatis, J. Reid, S. Vuu, P. Issack, J. Andersen, C. Chen, G. Chen, Primary giant cell tumors in the proximal phalanx of the left ring finger, *Open Access, World J Surg Surg. Res.* 2 (2019) 1154 <http://surgeryresearchjournal.com>.
- [20] M.K. Abou Chaar, W. Asha, S. Abdel Al, Novel double central ray amputation of the third and fourth digits: case report and literature review, *Case Rep. Oncol.* 13 (2020) 91–99, <http://dx.doi.org/10.1159/000504934>.

Open Access

This article is published Open Access at [sciencedirect.com](https://www.sciencedirect.com). It is distributed under the [IJSCR Supplemental terms and conditions](#), which permits unrestricted non commercial use, distribution, and reproduction in any medium, provided the original authors and source are credited.