




Since January 2020 Elsevier has created a COVID-19 resource centre with free information in English and Mandarin on the novel coronavirus COVID-19. The COVID-19 resource centre is hosted on Elsevier Connect, the company's public news and information website.

Elsevier hereby grants permission to make all its COVID-19-related research that is available on the COVID-19 resource centre - including this research content - immediately available in PubMed Central and other publicly funded repositories, such as the WHO COVID database with rights for unrestricted research re-use and analyses in any form or by any means with acknowledgement of the original source. These permissions are granted for free by Elsevier for as long as the COVID-19 resource centre remains active.



Contents lists available at ScienceDirect

Auris Nasus Larynx

journal homepage: www.elsevier.com/locate/anl

Original Article

A multicenter study to investigate the positive rate of SARS-CoV-2 in middle ear and mastoid specimens from otologic surgery patients

Hiroshi Yamazaki^{a,b,c,*}, Norio Yamamoto^d, Toru Sonoyama^e, Hayato Maruoka^f, Seiko Nasu^f, Akiko Makino^g, Keizo Tomonaga^g, Norifumi Shigemoto^h, Hiroki Ohge^h, Keizo Fujiwara^a, Shogo Shinohara^a, Sachio Takeno^e, Koichi Omori^d, Yasushi Naito^a

^aDepartment of Otolaryngology, Kobe City Medical Center General Hospital, Kobe, Japan

^bHearing Research Division, Center for Clinical Research and Innovation, Kobe City Medical Center General Hospital, Kobe, Japan

^cFoundation for Biomedical Research and Innovation at Kobe, Kobe, Japan

^dDepartment of Otolaryngology, Head and Neck Surgery, Graduate School of Medicine, Kyoto University, Kyoto, Japan

^eDepartment of Otorhinolaryngology, Head and Neck Surgery, Graduate School of Biomedical and Health Sciences, Hiroshima University, Hiroshima, Japan

^fDepartment of Clinical Laboratory, Kobe City Medical Center General Hospital, Kobe, Japan

^gLaboratory of RNA Viruses, Department of Virus Research, Institute for Life and Medical Sciences, Kyoto University, Kyoto, Japan

^hDepartment of Infectious Diseases, Hiroshima University Hospital, Hiroshima, Japan

ARTICLE INFO

Article history:

Received 8 April 2022

Accepted 25 July 2022

Available online xxx

Keywords:

Otologic surgery

Mastoidectomy

Aerosol transmission

SARS-CoV-2

COVID-19

ABSTRACT

Objective: Severe acute respiratory syndrome coronavirus-2 (SARS-CoV-2), a novel coronavirus, causes coronavirus disease 2019 (COVID-19). Otologic surgeries with drilling by powered instruments induce significant aerosols, which may induce SARS-CoV-2 transmission to medical staff if SARS-CoV-2 exists in the middle ear and mastoid cavity. During a COVID-19 pandemic, therefore, confirming a negative COVID-19 test prior to otologic surgery is recommended. However, previous coronavirus studies demonstrated that coronavirus was detected in the middle ear in some patients even though the polymerase chain reaction (PCR) test using their nasopharyngeal swab was negative. This study aimed to elucidate the probability of a positive SARS-CoV-2 PCR test in the middle ear or mastoid specimens from otologic surgery patients in whom SARS-CoV-2 was not detected by preoperative PCR test using a nasopharyngeal swab.

Methods: We conducted a prospective, multicenter clinical study. Between April 2020 and December 2021, during the COVID-19 pandemic, 251 ears of the 228 participants who underwent otologic surgery were included in this study. All participants had no symptoms suggesting COVID-19 or close contact with a confirmed COVID-19 patient two weeks prior to the surgery. They were also negative in the SARS-CoV-2 PCR tests using a nasopharyngeal swab before surgery. We collected mucosa, granulation, bone dust with mucosa or fluid from the middle ear or mastoid for the SARS-CoV-2 PCR tests during each otologic surgery.

Abbreviations: SARS-CoV-2, severe acute respiratory syndrome coronavirus-2; COVID-19, coronavirus disease 2019; RT-PCR, reverse transcription polymerase chain reaction; AOM, acute otitis media; OME, otitis media with effusion.

* Corresponding author at: Hearing Research Division, Center for Clinical Research and Innovation, Kobe City Medical Center General Hospital, 2-1-1 Minatogijimaminamimachi, Chuo-ku, Kobe City 650-0047, Japan.

E-mail address: h_yamazaki@ent.kuhp.kyoto-u.ac.jp (H. Yamazaki).

<https://doi.org/10.1016/j.anl.2022.07.007>

0385-8146/© 2022 Japanese Society of Otorhinolaryngology-Head and Neck Surgery, Inc. Published by Elsevier B.V. All rights reserved.

Please cite this article as: H. Yamazaki, N. Yamamoto, T. Sonoyama et al., A multicenter study to investigate the positive rate of SARS-CoV-2 in middle ear and mastoid specimens from otologic surgery patients, *Auris Nasus Larynx*, <https://doi.org/10.1016/j.anl.2022.07.007>

Results: The median age of the participants at surgery was 31.5 years old. Mastoidectomy using a powered instrument was conducted in 180 of 251 otologic surgeries (71.8%). According to intraoperative findings, active inflammation in the middle ear or mastoid cavities was evident in 20 otologic surgeries (8.0%), while minor inflammation was observed in 77 (30.7%). All SARS-CoV-2 PCR tests of otologic specimens showed a negative result. No patient suffered from COVID-19 within two months after otologic surgery. Furthermore, no hospital-acquired infections associated with otologic surgery occurred in our institutions.

Conclusions: Our results showed that PCR testing did not detect SARS-CoV-2 in middle ear and mastoid specimens, suggesting that the risk of transmission of SARS-CoV-2 is not high in otologic surgeries even using powered instruments when both clinical and laboratory tests are confirmed to be negative for COVID-19.

© 2022 Japanese Society of Otorhinolaryngology-Head and Neck Surgery, Inc. Published by Elsevier B.V. All rights reserved.

1. Introduction

Severe acute respiratory syndrome coronavirus-2 (SARS-CoV-2), a novel coronavirus, causes coronavirus disease 2019 (COVID-19), an infectious disease that shows the upper respiratory system symptoms such as fever, cough, tiredness, loss of taste or smell, and sore throat. SARS-CoV-2 is transmitted mainly by respiratory fluids, especially aerosol particles from people infected by this virus [1–3]. The middle ear and mastoid connect to the nasopharynx via the Eustachian tube, and the middle ear mucosa is anatomically classified as a respiratory epithelium [4]. Therefore, the middle ear and mastoid are considered part of the upper airway. Virological studies revealed that common respiratory viruses, such as rhinovirus, respiratory syncytial (RS) virus, or coronavirus, were detected from a middle ear specimen in 48% of children with acute otitis media (AOM) and 30% of children with otitis media with effusion (OME), respectively [5,6]. Among these viruses, coronavirus was identified in 8% and 3% of the AOM and OME populations, respectively [5,6]. Considering that SARS-CoV-2 belongs to the family Coronaviridae [7], it is plausible that COVID-19 patients have SARS-CoV-2 virus in the middle ear and mastoid. Otology guidelines recommended postponing non-urgent mastoid surgeries during the COVID-19 pandemic [8,9] because mastoid drilling by powered instruments induces significant bone and other tissue aerosols [10], which may contain a viable virus when the SARS-CoV-2 virus infects the patients. Autopsy studies of deceased COVID-19 patients proved the SARS-CoV-2 virus in the middle ear [11,12] and mastoid [13], indicating that this recommendation is reasonable. The guidelines also recommend that if ear surgery is required during a COVID-19 pandemic, a negative test for COVID-19 should be confirmed before surgery [8,9,14]. Reverse transcription PCR (RT-PCR) using nasopharyngeal or oropharyngeal swabs are the gold standards for identifying the SARS-CoV-2 in the upper respiratory system [15,16]. It should be noted that in a previous large cohort study, 2–3% of patients with AOM tested positive for coronavirus in PCR of middle ear specimens, but no coronavirus was detected in concurrent PCR of nasopharyngeal specimens [6,17]. Considering that coronaviruses are detected in middle ear specimens in 8% of patients with AOM

[6], as mentioned above, these studies imply that PCR testing of the nasopharyngeal swab alone may not be sufficient to prove the absence of coronaviruses, including the SARS-CoV-2, in the middle ear and mastoid cavity.

This study aimed to elucidate the probability of a positive SARS-CoV-2 result in PCR test using the middle ear or mastoid specimens in otologic surgery patients in whom SARS-CoV-2 was not detected by preoperative PCR test using nasopharyngeal swabs. We included otologic surgery patients who met the following criteria: (1) no COVID-19 symptom nor close contact with a confirmed COVID-19 patient for two weeks before ear surgery and (2) negative SARS-CoV-2 PCR test of nasopharyngeal swabs on the day or a couple of days before surgery. Our results will be valuable in establishing guidelines for safe otologic surgery if the COVID-19 pandemic persists for a long time.

1.1. Participants and methods

We conducted a prospective, multicenter clinical study involving three tertiary hospitals from different regions in Japan. Among the patients who underwent otologic surgery under general anesthesia at our hospitals between April 2020 and December 2021, we recruited 228 patients who gave written consent to this study by themselves or their guardians. This study period was determined because COVID-19 outbreaks, including those in healthcare institutions, have started since January 2020 in Japan. Three of 228 patients (1.3%) had suffered from COVID-19 more than one month prior to the surgery. Before hospital admission for otologic surgery, all participants were clinically and laboratory-confirmed to be negative for COVID-19. That is, we performed SARS-CoV-2 real-time RT-PCR testing using a nasopharyngeal swab [18] on the admission day or 1–2 business days before admission, in addition to confirming the absence of any symptoms suggesting COVID-19 nor close contact with a confirmed COVID-19 patient in the two weeks prior to admission. The N2 primer-probe set defined by the CDC was used in our SARS-CoV-2 real-time RT-PCR testing [19]. In one of our hospitals (Kobe City Medical Center General Hospital (KCGH)), during the same period as this study, all patients scheduled for surgery in any departments underwent the same examinations for COVID-19 symptoms and SARS-CoV-

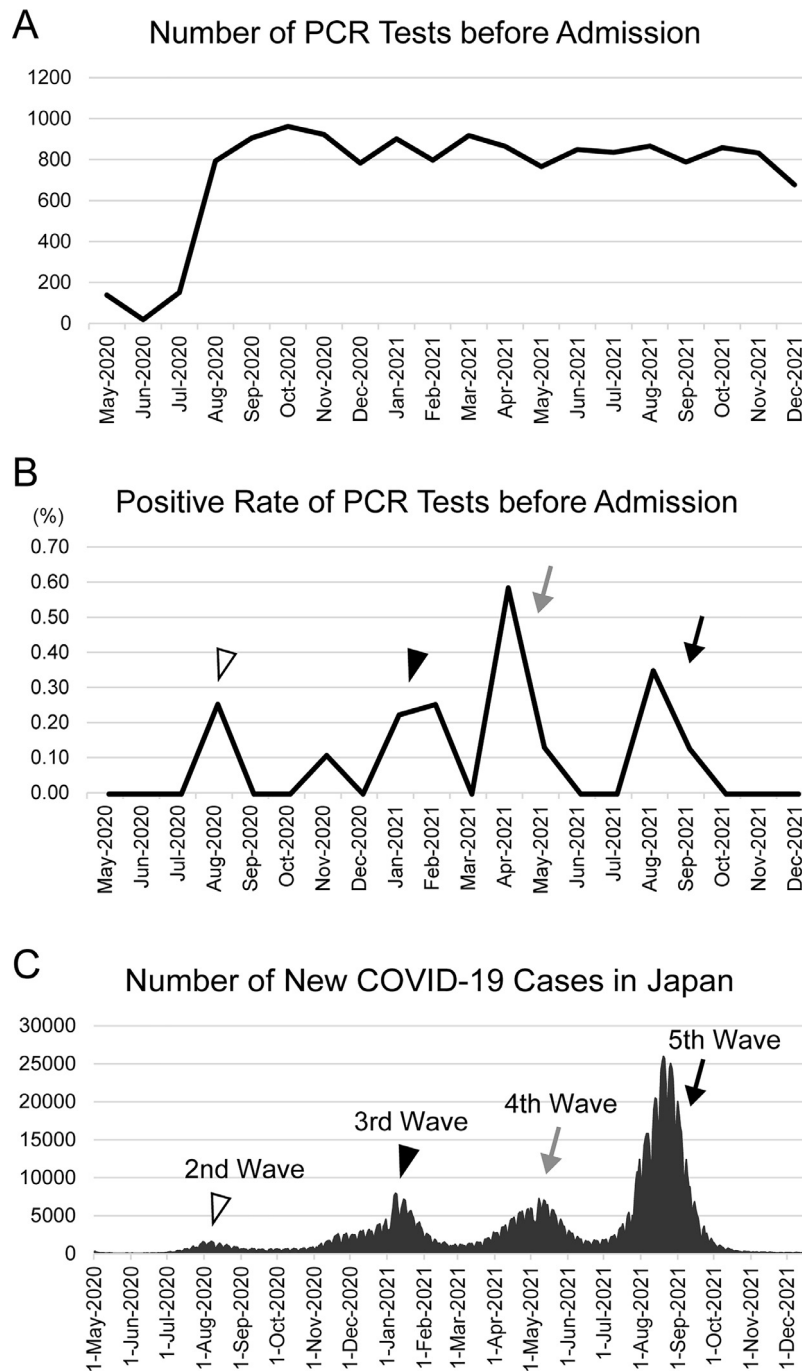


Fig. 1. Results of SARS-CoV-2 PCR tests. (A) In one of our hospitals, 14,266 scheduled surgical patients in any departments underwent a SARS-CoV-2 PCR test using a nasopharyngeal swab before their hospital admission during the study period. (B) The temporal changes in the positive rate of the pre-admission PCR test. Seventeen out of the 14,266 patients (0.12%) had no symptoms suggesting COVID-19 but tested positive in the SARS-CoV-2 PCR. (C) The number of new COVID-19 cases in Japan, released by the Ministry of Health, Labour and Welfare (<https://www.mhlw.go.jp/stf/covid-19/kokunainohasseijoukyou.html>). The white arrowhead, black arrowhead, gray arrow, and black arrow indicate the 2nd, 3rd, 4th, and 5th waves of COVID-19, respectively. Each wave was synchronized with each peak in Fig 1B, indicated by the same type of arrowhead or arrow.

2 PCR of nasopharyngeal swab before their hospital admission (Fig. 1A). Except for patients immediately after COVID-19 recovery, 17 out of the 14,266 scheduled surgical patients (0.12%) had no symptoms suggesting COVID-19 but showed positive for the SARS-CoV-2 PCR test. These 17 positive patients were scheduled non-otologic surgeries, and all surgeries except for urgent ones were postponed. The temporal changes

in the positive rate of the pre-admission PCR test are closely related to waves of COVID-19 in Japan [20] (Figs. 1B and C). One of these 17 PCR-positive patients developed COVID-19 soon after the test, and four complained of minor symptoms, such as rhinorrhea, fatigue, or sore throat. The remaining 12 patients had no symptoms throughout two weeks after the PCR.

Table 1. Details in otologic surgeries and patients.

	Number of Ears	Number of Patients	Median Age at Surgery (y.o.) (Min-Max)	With Mastoidectomy
Cochlear Implantation	119	99	9 (0-91)	119 (100.0%)
Tympanoplasty	109	109	51 (3-81)	52 (47.7%)
Stapes Surgery	8	8	50 (7-70)	0 (0.0%)
Tympanostomy Tube Insertion	7	4	7 (1-39)	1 (14.3%)
Others	8	8	20 (1-78)	8 (100.0%)
Total	251	228	31.5 (0-91)	180 (71.7%)

The 251 ears from the 228 participants underwent otologic surgeries in our hospitals. All medical staff in the operation room used the standard personal protective equipment against aerosol-generating interventional procedures, including an N95 mask, goggle or face shield, gown, and double gloves [21]. In some cases, standard surgical masks were used due to an insufficient supply of N95 masks. We investigated types of surgeries, the age at operation, with and without mastoidectomy, and the degree of inflammation of the middle ear and mastoid cavity based on the intraoperative findings. In each otologic surgery, we collected a PCR test specimen from the tympanic or mastoid cavity. We selected PCR specimens according to previous studies [12,13]. Mastoidectomy using a powered instrument is considered the highest risk of aerosol production. Therefore, when mastoidectomy was performed, otologic specimens were collected from the mastoid. Mucosa and granulation around the aditus of the antrum were our first choice, and if these were not available, the mucosa and granulation in the mastoid air cells were usually collected. A mixture of bone dust and mucosa fragments after drilling was obtained as otologic specimens in a few cases. The mucosa, granulation, or fluid in the tympanic cavity was collected as PCR specimens in patients without mastoidectomy. The method for the SARS-CoV-2 PCR test of these otologic specimens was the same as for the PCR test of nasopharyngeal swabs. The PCR tests were performed in the same institute where the specimens were collected.

At Kyoto University, the otologic specimens were soaked in RNA stabilization solution (RNAlater[®], Invitrogen, Carlsbad, USA) immediately after their collection and stored at 4°C up to 4 days before RNA purification. In the other two institutes (Hiroshima University and KCGH), the collected otologic specimens were stored at 4°C in normal saline or in a sealed sterile container to prevent drying up to 24 hours before RNA purification. Viral RNA was purified by NucleoSpin[®] RNA Virus (Takara Bio Inc., Shiga, Japan) at Kyoto University, Takara SARS-CoV-2 Direct PCR detection kit (Takara Bio Inc., Shiga, Japan) at Hiroshima University, and Maxwell RSC Viral Total Nucleic Acid Purification Kit (Promega, Madison, USA) at KCGH. Tissue specimens such as mucosa and granulation were minced and incubated in lysis buffer containing proteinase K at 56 °C for 10-30 minutes at the first step of the RNA purification, equal to or longer than that for the nasal swab. Then, RT-PCR products amplified by One Step PrimeScript[™] III RT-qPCR Mix (Takara Bio Inc., Shiga, Japan) with the N2 primer-probe set were quantified by Bio-Rad CFX96 Touch Real-Time PCR Detec-

tion System (Bio-Rad, Hercules, USA) at Kyoto University and KCGH. At Hiroshima University, Takara SARS-CoV-2 Direct PCR detection kit with the N2 primer-probe set was used for RT-PCR, and the amplified PCR products were quantified by Thermal Cycler Dice[®] Real Time System III (Takara Bio Inc., Shiga, Japan). The cut-off cycle threshold value for real-time RT-PCR was determined as 40 cycles in all institutes.

The ethics committees of each institute approved the study protocols (zn200719 for KCGH, E-2105 for Hiroshima University, and R2600 for Kyoto University).

2. Results

At the median age of 31.5 years old, 228 patients underwent 251 otologic surgeries, including 119 cochlear implantations, 109 tympanoplasties, eight stapes surgeries, seven tympanostomy tube insertions, and eight other types of surgeries. Cochlear implantation and tympanostomy tube insertion were performed simultaneously at both sides in 20 and 3 patients, respectively. Most cochlear implantation and tympanostomy tube insertion were done in pediatric patients. Therefore, the median ages of these surgeries were less than ten years old. On the other hand, the median ages of tympanoplasties and stapes surgeries are around 50 years old, indicating that these were mainly for adults. All cochlear implantations and 52 of the 109 tympanoplasties (47.7%) were performed concurrently with mastoidectomy. In total, mastoidectomy using a powered instrument was conducted in 180 of 251 otologic surgeries (71.7%) (Table 1).

Intraoperative findings showed that active inflammation was evident in 20 otologic surgeries (8.0%), while minor inflammation, including post-inflammatory changes, such as mucosal edema, granulation, or microabscesses, was observed in 77 surgeries (30.7%). This active or minor inflammation was found in 17 of 119 cochlear implantations (14.3%), 68 of 109 tympanoplasties (62.4%), 7 of 7 tympanostomy tube insertions (100%), and 5 of 8 other types of surgeries (62.5%) (Table 2).

Regarding otologic PCR specimens, mucosa and granulation, fluid, and bone dust with mucosa fragments during mastoidectomy account for 239 (95.2%), 10 (4.0%), and 2 (0.8%), respectively. All SARS-CoV-2 PCR tests for middle ear and mastoid specimens showed a negative result. No patient suffered from COVID-19 at least within one month after otologic surgery. Furthermore, no hospital-acquired infections associated with otologic surgery occurred in our institutions.

Table 2. Inflammation observed during surgery.

	Number of Ears	Inflammation		
		Active	Minor	No
Cochlear Implantation	119	2	15	102
Tympanoplasty	109	10	58	41
Stapes Surgery	8	0	0	8
Tympanostomy Tube Insertion	7	4	3	0
Others	8	4	1	3
Total	251 (100.0%)	20 (8.0%)	77 (30.7%)	154 (61.4%)

3. Discussion

In this study, during the COVID-19 pandemic, we focused on 251 otologic surgeries on patients who had no symptoms suggesting COVID-19 and were confirmed negative for SARS-CoV-2 PCR tests using a nasopharyngeal swab. Our results showed that RT-PCR did not detect SARS-CoV-2 in any middle ear and mastoid specimens, implying that the risk of SARS-CoV-2 transmission via aerosols is not high in otologic surgeries with powered instruments when both clinical and laboratory tests are confirmed to be negative for COVID-19 before surgery.

Cochlear implantations and tympanoplasties consisted of most of the 251 otologic surgeries. In particular, cochlear implantations accounted for the highest percentage at 47.4%, although tympanoplasties had been more common than cochlear implantations before the COVID-19 pandemic in our institutes. As indicated by the categories of otologic surgical priorities after the first peek of the pandemic [14], cochlear implantations for pediatric patients with pre-lingual deafness, cochlear implantations for patients with post-lingual deafness, and tympanoplasty without complications of acute or chronic otitis media were prioritized in this decreasing order, which resulted in a high proportion of cochlear implantation in this study. In 71.7% of the otologic surgeries, we performed mastoidectomy with powered instruments (Table 1), which might increase the risk of SARS-CoV-2 transmission via aerosols [8,9,14]. Therefore, if the possibility of the existence of SARS-CoV-2 in the middle ear or mastoid cavities is not negligible, otologic surgeries with mastoidectomy, especially cochlear implantation, should be performed with the appropriate protection against viral transmissions, such as personal protective equipment, a protective drape tent, and a powered air-purifying respirator [22,23].

A couple of decades ago, virological studies showed that coronavirus PCR tests showed inconsistent results between nasopharyngeal and middle ear specimens. That is, in 2-3% of ≤ 7 -year-old children with AOM, the coronavirus PCR test showed negative for nasopharyngeal swabs but positive for middle ear specimens [6,17]. Although the populations of the participants in this study and these previous studies are different, there is some overlap. Among our 251 otologic surgeries, 72 were performed in ≤ 7 -year-old children, and 97 showed some inflammation. It is, therefore, noteworthy that in the present study, all otologic specimens were tested negative by PCR, as were the nasopharyngeal specimens. In previous studies, all patients suffered from acute otitis media, while

only 8% of the ears in the present study had active inflammation. Coronaviruses may be transiently present in the middle ear only during the acute phase of otitis media. Alternatively, the inclusion criteria for our study may have lowered the possibility of SARS-CoV-2 infection because each patient had no clinical symptoms suggestive of COVID-19 and no close contact with COVID-19 patients in the two weeks before admission. The combination of clinical and laboratory-based PCR tests may help to minimize the possibility of SARS-CoV-2 infection in the middle ear and mastoid cavity.

Mucosa and granulation accounted for 95.2% of the middle ear and mastoid specimens that we collected for PCR testing. Previously, SARS-CoV-2 was detected from bone and mucosa in confirmed COVID-19 patients by RT-PCR [13]. The transmission electron microscopy study identified structures suggestive of SARS-CoV-2 in the epithelial cells of middle ear mucosa obtained from deceased COVID-19 patients. Therefore, we thought epidermal cells might carry the SARS-CoV-2 for a long time in the middle ear and used mucosal tissue for a PCR test. Since the accuracy of the PCR test for SARS-CoV-2 using mucosal tissue specimens has not been investigated, it cannot be ruled out that our PCR results with otological tissue were false-negative, which may be considered a limitation of this study. We emphasize here that all patients who underwent otologic surgery in this study did not develop COVID-19 at least within one month after surgery. In addition, no hospital-acquired infections related to otologic surgery occurred in our institutions. Therefore, although the accuracy of the test to detect SARS-CoV-2 has not been proven, the probability of the existence of SARS-CoV-2 in the middle ear and mastoid is sufficiently low in patients without symptoms who show negative PCR test of nasopharyngeal swabs before surgery.

The accuracy of the SARS-CoV-2 PCR test using a nasopharyngeal swab has been investigated in COVID-19 patients [24] but not in asymptomatic people infected by SARS-CoV-2. Fig. 1B shows that in one of our hospitals, 17 out of the 14,266 surgical patients, including those from departments other than otolaryngology, were positive in the SARS-CoV-2 PCR test using nasopharyngeal swabs before admission. Since no patients with negative PCR test developed COVID-19 within two weeks after the test, the negative predictive value of our SARS-CoV-2 PCR of a nasopharyngeal swab in people without COVID-19 symptoms is high enough. Five of the 17 PCR-positive patients later developed COVID-19 or showed minor upper respiratory symptoms. On the other hand, the remaining 12 showed no symptoms related to COVID-19, suggesting asymptomatic infection or a false positive of our

SARS-CoV-2 PCR test. Since the positive rate of the pre-admission PCR test is clearly synchronized with the waves of new COVID-19 cases (Figs. 1B and C), it is reasonable to assume that our SARS-CoV-2 PCR test successfully detected asymptomatic SARS-CoV-2 infection or colonization in the nasopharynx.

The results of the present study suggest that a considerably low rate of SARS-CoV-2 PCR positivity in the middle ear cavity would be expected in patients with no symptoms suggestive of COVID-19 and a negative nasal swab SARS-CoV-2 PCR test prior to the surgery. However, these findings do not guarantee the absence of SARS-CoV-2 infection in the middle ear. Thus, in the aerosol-generating otologic surgery during the COVID-19 pandemic, it is preferable to use the personal protective equipment, including an N95 mask, goggles or face shield, gown, double gloves, and microscope drape tent, to minimize the risk of infection to medical staff, especially the surgeon [22,23]. However, goggles and face shields can reduce the surgeon's field of vision, and microscope drape tents can interfere with fine surgical manipulation. Thus, excessive infection protection against minimal infection risk can potentially disadvantage the patient due to longer operating time and inaccurate surgical manipulation. Therefore, in periods when the number of SARS-CoV-2 infection patients is maintained low, otologic surgery using conventional infection protection techniques prior to the COVID-19 pandemic may be acceptable if the patient and surgical staff have received multiple doses of vaccine against SARS-CoV-2 and the patient shows no symptoms suggestive of COVID-19 and negative SARS-CoV-2 PCR test using a nasal swab. However, when downgrading infection protection protocols, we need careful monitoring for the emergence of a COVID-19 patient among the surgical staff.

4. Conclusion

This prospective multicenter clinical study recruited 228 patients who underwent otologic surgery during the COVID-19 pandemic. These patients had no symptoms suggesting COVID-19 and were confirmed negative for SARS-CoV-2 PCR tests using a nasopharyngeal swab. Our results demonstrated that RT-PCR did not detect SARS-CoV-2 in any middle ear or mastoid specimens, suggesting that the risk of transmission of SARS-CoV-2 is not high in otologic surgeries even using powered instruments when both clinical and laboratory tests are confirmed to be negative for COVID-19 preoperatively.

Acknowledgments

The authors would like to thank Dr. Yasuki Kihara, Director of Kobe City Medical Center General Hospital, and all members of our departments and hospitals for their efforts to conduct this clinical study. The authors are grateful to Dr. Chisato Miyakoshi for helpful discussions about the study design. We also thank Dr. Asako Doi for useful information about SARS-CoV-2 and COVID-19. This work is supported by KAKENHI Grant-in-Aid for Scien-

tific Research (C) JP20K09709 (H.Y.), AMED grant number JP20wm0325011h0001 (A.M.), and Kyoto University Medical Student Support-Fund (KMS-Fund) donated from Securite ACADEMIA (N.Y. and K.O.).

References

- [1] Wang CC, Prather KA, Sznitman J, Jimenez JL, Lakdawala SS, Tufekci Z, et al. Airborne transmission of respiratory viruses. *Science* 2021;373:eabd9149.
- [2] Meyerowitz EA, Richterman A, Gandhi RT, Sax PE. Transmission of SARS-CoV-2: a review of viral, host, and environmental factors. *Ann Intern Med* 2021;174:69–79.
- [3] Greenhalgh T, Jimenez JL, Prather KA, Tufekci Z, Fisman D, Schooley R. Ten scientific reasons in support of airborne transmission of SARS-CoV-2. *Lancet* 2021;397:1603–5.
- [4] Hentzer E. Histologic studies of the normal mucosa in the middle ear, mastoid cavities and Eustachian tube. *Ann Otol Rhinol Laryngol* 1970;79:825–33.
- [5] Pitkäranta A, Jero J, Arruda E, Virolainen A, Hayden FG. Polymerase chain reaction-based detection of rhinovirus, respiratory syncytial virus, and coronavirus in otitis media with effusion. *J Pediatr* 1998;133:390–4.
- [6] Pitkäranta A, Virolainen A, Jero J, Arruda E, Hayden FG. Detection of rhinovirus, respiratory syncytial virus, and coronavirus infections in acute otitis media by reverse transcriptase polymerase chain reaction. *Pediatrics* 1998;102:291–5.
- [7] Coronaviridae Study Group of the International Committee on Taxonomy of Viruses. The species severe acute respiratory syndrome-related coronavirus: classifying 2019-nCoV and naming it SARS-CoV-2. *Nat Microbiol* 2020;5:536–44.
- [8] Givi B, Schiff BA, Chinn SB, Clayburgh D, Iyer NG, Jalisi S, et al. Safety recommendations for evaluation and surgery of the head and neck during the COVID-19 pandemic. *JAMA Otolaryngol Head Neck Surg* 2020;146:579–84.
- [9] ENTUK. Guidance for undertaking otological procedures during COVID-19 pandemic. <https://www.entuk.org/guidance-undertaking-otological-procedures-during-covid-19-pandemic>. Accessed Mar. 8, 2022.
- [10] Jewett DL, Heinsohn P, Bennett C, Rosen A, Neuilly C. Blood-containing aerosols generated by surgical techniques a possible infectious hazard. *Am Ind Hyg Assoc J* 1992;53:228–31.
- [11] Heikkinen T, Thint M, Chonmaitree T. Prevalence of various respiratory viruses in the middle ear during acute otitis media. *N Engl J Med* 1999;340:260–4.
- [12] Jeican II, Aluș M, Lazăr M, Barbu-Tudoran L, Gheban D, Inișca P, et al. Evidence of SARS-CoV-2 virus in the middle ear of deceased COVID-19 patients. *Diagnostics* 2021;11:1535.
- [13] Frazier KM, Hooper JE, Mostafa HH, Stewart CM. SARS-CoV-2 virus isolated from the mastoid and middle ear: implications for COVID-19 precautions during ear surgery. *JAMA Otolaryngol Head Neck Surg* 2020;146:964–6.
- [14] ENTUK. A Graduated return to elective ent within the COVID-19 pandemic. <https://www.entuk.org/graduated-return-elective-ent-within-covid-19-pandemic-0>.
- [15] Tsang NNY, So HC, Ng KY, Cowling BJ, Leung GM, Ip DKM. Diagnostic performance of different sampling approaches for SARS-CoV-2 RT-PCR testing: a systematic review and meta-analysis. *Lancet Infect Dis* 2021;21:1233–45.
- [16] Organization WH. Laboratory testing for coronavirus disease (COVID-19) in suspected human cases: interim guidance, 19 March 2020. Organization WH, editor: World Health Organization; 2020.
- [17] Nokso-Koivisto J, Pitkäranta A, Blomqvist S, Kilpi T, Hovi T. Respiratory coronavirus infections in children younger than two years of age. *Pediatr Infect Dis J* 2000;19:164–6.
- [18] Ito J, Seo R, Kawakami D, Matsuoka Y, Ouchi K, Nonami S, et al. Clinical characteristics and outcomes of critically ill patients with COVID-19 in Kobe, Japan: a single-center, retrospective, observational study. *J Anesth* 2021;35:213–21.

- [19] Centers for Disease Control and Prevention. 2019-novel coronavirus (2019-nCoV) real-time RT-PCR panel primers and probes. <https://www.cdc.gov/coronavirus/2019-ncov/downloads/rt-pcr-panel-primer-probes.pdf>, 2020.
- [20] Ministry of Health Labour and Welfare. Coronavirus (COVID-19). Available at: https://www.mhlw.go.jp/stf/covid-19/kokunainohassei_joukyou.html.
- [21] Couloigner V, Schmerber S, Nicollas R, Coste A, Barry B, Makeieff M, et al. COVID-19 and ENT surgery. *Eur Ann Otorhinolaryngol Head Neck Dis* 2020;137:161–6.
- [22] Kozin ED, Remenschneider AK, Blevins NH, Jan TA, Quesnel AM, Chari DA, et al. American Neurotology Society, American Otological Society, and American Academy of otolaryngology–head and Neck Foundation guide to enhance Otologic and Neurotologic care during the COVID-19 pandemic. *Otol Neurotol* 2020;41:1163–74.
- [23] Lawrence RJ, O'Donoghue G, Kitterick P, O'Donoghue K, Hague R, Mitchell L, et al. Recommended personal protective equipment for cochlear implant and other mastoid surgery during the COVID-19 era. *Laryngoscope* 2020;130:2693–9.
- [24] Tsujimoto Y, Terada J, Kimura M, Moriya A, Motohashi A, Izumi S, et al. Diagnostic accuracy of nasopharyngeal swab, nasal swab and saliva swab samples for the detection of SARS-CoV-2 using RT-PCR. *Infect Dis* 2021;53:581–9.