

X-ray and Computed Tomography Scan-Based Morphometric Analysis of Skull Baselines in Indian Population

Abstract

Introduction: The study aims at providing an overview of morphometric measurements of the skull baselines in normal Indian population and compares these dimensions with those of other races and ethnicities. This study will help in defining “normal” baseline values for Indian population. It will also compare dimensions as measured on X-ray and computed tomography (CT) scan to assess the reliability of X-ray as a diagnostic modality for the assessment of the skull baselines in Indian population. **Materials and Methods:** Retrospective study with a sample size of 116 patients and duration of 30 months. **Results:** The mean value for distance between dens tip and Chamberlain line on CT was 0.498 mm and on X-ray was 0.528 mm and for the distance between dens tip and McGregor line on CT was 0.213 mm and on X-ray was 0.228 mm. The mean distance between the dens tip and McRae line was 4.67 1.69 mm on CT scan and 4.7 1.76 mm on X-ray. **Conclusion:** There was not a single patient in whom the dens tip crossed the McRae line. Any protrusion of the dens tip beyond the foramen magnum is abnormal. Hence, the McRae line is easiest to understand and remember. Furthermore, the Chamberlain and McGregor lines rely on identifying the hard palate, which may not be included in routine X-ray, CT, and magnetic resonance imaging studies depend on the field of view. Hence, we recommend the use of McRae line for screening purposes while evaluating pathologies of the craniovertebral junction. X-ray is a reliable diagnostic technique for assessing morphometry of the skull baselines in an emergency or rural setting if facility for CT scan is not available.

Keywords: Basilar invagination, Chamberlain, McGregor, McRae

Introduction

The craniovertebral junction (CVJ) is a complex region consisting of vital structures, including the brainstem and spinal cord. A number of congenital and acquired etiologies can lead to basilar invagination, which is a common pathology involving the CVJ. Conventionally, X-ray of the skull with the cervical spine was the imaging modality used for the assessment of basilar impression. CVJ can now be visualized much better using modern-day imaging modalities including computed tomography (CT) and magnetic resonance imaging (MRI) which offer a three-dimensional visualization of this region with a relatively complex anatomy. CT scan can provide good spatial resolution combined with speed and ability to perform high-quality multiplanar imaging. It provides details of the bony anatomy which are superior to that of plain X-ray and

MRI studies. CT is a reliable diagnostic modality for the accurate assessment of the classical lines and angles, transverse and anteroposterior (AP) diameters of the foramen magnum and spinal canal. The skull-base lines namely Chamberlain's, McGregor's, and McRae's lines [Figure 1] are the standard reference measurements used for the evaluation of basilar impression, in defining anatomy of the CVJ, in pre- and post-operative assessment and follow-up of any CVJ pathology.

Chamberlain's line^[1] is drawn from the posterior end of the hard palate to the posterior margin of the foramen magnum. In normal patients, the tip of the dens should be 3.3 mm around this line. McGregor line^[2] is drawn from the posterosuperior margin of the hard palate to the lowest point of the midline occipital curve. Usually, the tip of the dens does not project more than 4.5 mm above this line. McRae's line^[3] is the foramen magnum line joining the basion and opisthion. The normal position

This is an open access journal, and articles are distributed under the terms of the Creative Commons Attribution-NonCommercial-ShareAlike 4.0 License, which allows others to remix, tweak, and build upon the work non-commercially, as long as appropriate credit is given and the new creations are licensed under the identical terms.

For reprints contact: reprints@medknow.com

Nandan Amrit Marathe, Aditya A. Dahapute, Jigar Rajesh Desai, Kiran P. Dhole¹, Shubhanshu Bhaladhare¹, Swapneel Shah

Department of Orthopaedics, Seth GS Medical College and KEM Hospital, ¹Department of Orthopaedics, BYL Nair Hospital, Mumbai, Maharashtra, India

Address for correspondence:

*Dr. Jigar Rajesh Desai,
Plot No. 381/0005,
Flat No. 508, Mangal Murti
Apartment, Sector 12E,
Bonkade, Kopar Khairane,
Navi Mumbai - 400 709,
Maharashtra, India.
E-mail: jigar2112902@gmail.com*

Access this article online

Website: www.asianjns.org

DOI: 10.4103/ajns.AJNS_201_19

Quick Response Code:



How to cite this article: Marathe NA, Dahapute AA, Desai JR, Dhole KP, Bhaladhare S, Shah S. X-ray and computed tomography scan-based morphometric analysis of skull baselines in Indian population. Asian J Neurosurg 2019;14:1116-21.

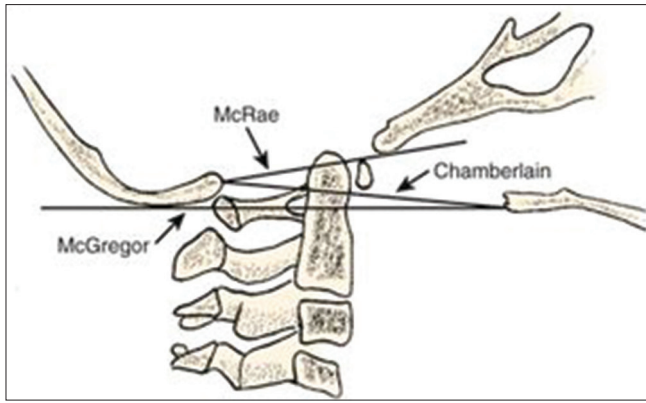


Figure 1: Schematic diagram showing the three skull baselines

of the tip of the odontoid process is around 5 mm below this line. Any protrusion of the tip of dens above this line indicates the presence of basilar invagination.

These skull-base lines were first defined on plain lateral X-ray of the cervical spine^[4] over 5 decades ago and have never been measured on sagittal CT images in Indian Population. The dimensions of the CVJ and the vertebrae differ significantly in Indian and other population groups. Previously published studies show that the dimensions of the cervical pedicle diameter differ between Indian and western population.^[5] Such a difference in dimensions of the skull baselines is also expected.

The present study aims at providing an up to date overview of morphometric measurements of the skull baselines in the normal Indian population as these are subject to racial and ethnic variability^[5] and compare the dimensions with those of other races and population groups. This study will help in defining “normal” baseline values for the Indian population. This study will also compare dimensions as measured on X-ray and CT scan to assess whether X-ray is a reliable diagnostic tool to evaluate the CVJ in an emergency setting.

Materials and Methods

This study was conducted within the premises of a tertiary care center. Approval of the institutional ethics committee was taken before commencement. Patients with a history of head injury and thereby requiring CT scan and X-ray of the cervical spine who presented to the tertiary care center from May 2015 to December 2017 were included. Two orthopedic surgeons independently assessed each value, and a consensus was reached. Patients above 18 years of age, of either gender, with a head injury but normal cervical spine anatomy were included in the study. Patients <18 years of age or those with altered anatomy (cervical spine fracture and dislocation, rheumatoid arthritis, a previous history of cervical spine surgery, tumors) were excluded from the study.

The CT scans were done by CT Phillips Brilliance 64 machine (Equipment no 52952467) 64 slice machine. 1-mm thickness cuts were taken by this machine. The CT scan images were analyzed by Phillips Extended Workspace

Brilliance TM Version no 4.5.5.51035 (Horosv 2.0.2). The distance between the tip of the odontoid process and the skull baselines was measured on the sagittal image of the CT scan with the coronal section centered on the dens. The X-rays were taken by ST S1012004 Varian medical system (manufacturer date: September 2014 Housing model no B1304 Varian Tube A 292 Insert serial # 7669743). The X-ray images were analyzed by SITEC Feel 2.0 version 2.1.211.0 × Maru 1717 (Horosv 2.0.2.). For analyzing X-ray, a spherical marker of known dimensions was kept in the field for comparison above the thyroid cartilage in the midline.

For taking X-ray, the patient was positioned in a supine position with the patient’s shoulder pulled down with the neck lying against a vertical cassette holder. The mid-coronal plane (the plane that passes through the mastoid tips) was in the midline of the cassette. The patient was asked to elevate the chin to prevent superimposition of the upper cervical spine by the mandible. The central ray was perpendicular to the cassette and was directed horizontally to C-4 (level of upper margin of thyroid cartilage). C-1 to C-7 cervical vertebral bodies, intervertebral discs, articular pillars, spinous processes, and apophyseal joints were demonstrated. The cervicothoracic junction was seen. The neutral rotation was ensured by superimposition of both rami of mandible, both side apophyseal joints and posterior borders of the vertebral bodies.

We magnified all of the original images three-fold to select the most accurate measuring points and made the measurements with the electronic cursor of the PACS workstation. Although the values were figured to the hundredth of a millimeter in the PACS station, we calculated the resolution of the images provided by the 2K monitors to be above 0.1 mm. The calculated in-plane resolution achievable from the technical parameters was limited to 0.3 mm in multiple detector CT and 0.5 mm in MRI, based on the pixel number and field of view (FOV). Measured values were rounded to the nearest tenth of a millimeter.

The distance the odontoid tip extends above the Chamberlain and McGregor line was measured on the sagittal cut of the CT scan [Figures 2 and 3] in the coronal section centered on the dens. If the tip of the odontoid process was below, the Chamberlain or McGregor line the distance was designated as (–) __mm; and if the tip of the odontoid process extends, above the Chamberlain or McGregor line, it was designated as (+) __mm. The distance between the dens tip and the McRae line was measured on the sagittal cut of the CT scan [Figure 4] in the coronal section centered on the dens.

Statistical analysis

The data used for the calculation was based on the previously published studies on suggested mean values,

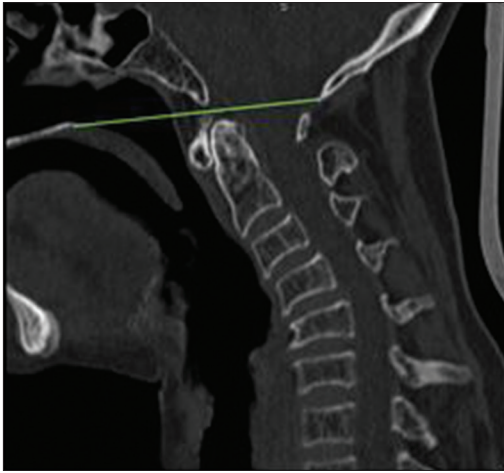


Figure 2: Sagittal section of computed tomography scan showing the Chamberlain line

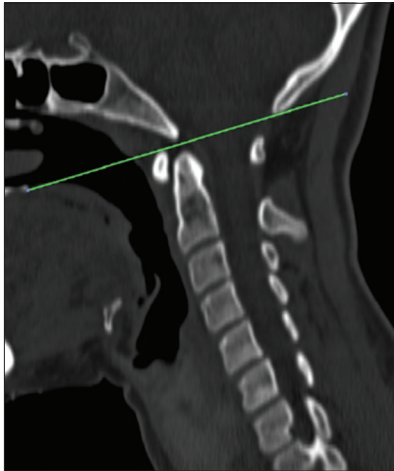


Figure 3: Sagittal section of computed tomography scan showing the McGregor line

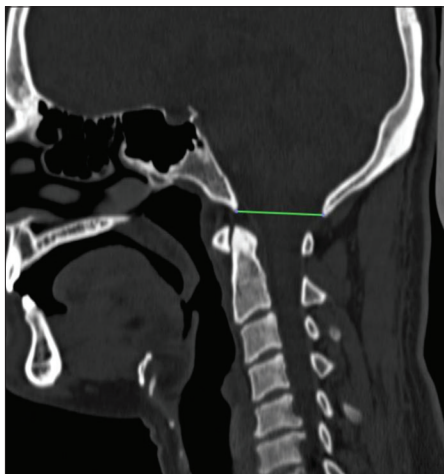


Figure 4: Sagittal section of computed tomography scan showing McRae line

standard deviations (SDs) and population variance with respect to plain X-ray and CT-based morphometric study of the foramen magnum in normal Indian population. The

study did measurements of AP and transverse diameter of the foramen magnum in patients presenting to a tertiary care center in India.^[6] From the estimation of previous data, the mean value of maximum diameter (which was AP) in sample of Indian population was $33.90 + 2.61$ mm assuming they were completely normal anatomically. The allowable difference was up to 1.6 mm ($\mu - \mu_0$). Then, the result of sample size at 95% confidence interval ($\alpha = 0.05$) with population variance of 6.7 for having 80% power ($\beta = 0.2$) is 116 ($N = 116$).^[7] Hence, the sample size for this study was taken as 116.

Two orthopedic surgeons measured the distance between the tip of the odontoid process and the three skull baselines on the 116 plain X-rays and CT scans independently. These were completely deidentified and presented in random order. With this data, we evaluated the interobserver and intraobserver agreement. For comparing intra- and inter-observer agreement, we used the intraclass correlation coefficient as described by Shrout and Fleiss.^[8] These consensus measures were used in all the analyses. We calculated the mean values, SD of the distance between the dens tip and the three skull baselines values using one-way analysis of variance, and Pearson's correlation methods. SPSS Statistical Package for the Social Sciences 17.0 (SPSS Inc., IBM, Chicago, Illinois, USA) was used to analyze data, and a $P \leq 0.05$ was considered as statistically significant. Finally, we used Microsoft Office Excel (2013) software to draw graphs of the collected data to detect any differences between the values obtained by the two modalities.

Results

Chamberlain line

The percentage of population with the tip of the odontoid process above the Chamberlain line was 55.12% (64 out of 116 patients). Seven cases out of 116 (6.03%) had the tip of the odontoid process extending more than 3 mm above the Chamberlain line. The range of values for the Chamberlain line on CT scan was from -7.865 to $+6.237$ and on lateral X-ray of the skull was from -7.851 to $+6.175$ (all values in millimeters) [Table 1]. Sixty-four patients had a value in positive and 52 in negative for both X-ray and CT scan. The negative mean was 2.512, positive mean was 2.014 with effective mean -0.498 mm on CT scan. The negative mean was 2.641, positive mean was 2.113 with effective mean -0.528 on X-ray. Thus, the mean value for distance between dens tip and Chamberlain line on CT was 0.498 mm and on X-ray was 0.528 mm. Using the Mann-Whitney test, as the data were not normally distributed, the difference between the male and female values and difference between the parameters as measured on X-ray and CT scan was not statistically significant.

McGregor line

The percentage of population with the tip of the odontoid process above the McGregor line was 58.620% (68 out of 116 patients). Nine cases out of 116 (7.558%) had the tip of the odontoid process extending more than 3 mm above the McGregor line. The range of values for the McGregor line on CT scan was from -6.065 to +7.237 and on lateral X-ray of the skull was from -6.051 to +7.175 (all values in millimeters) [Table 1]. Sixty-eight patients had a value in positive and 48 in negative for both X-ray and CT scan. The negative mean was 2.311, positive mean was 2.098 with effective mean -0.213 mm on CT scan. Negative mean was 2.241, positive mean was 2.013 with effective mean -0.228 mm on X-ray. Thus, the mean value for distance between dens tip and McGregor line on CT was 0.213 mm and on X-ray was 0.228 mm. The Mann-Whitney test was used for statistical analysis as the data was not normally distributed. It was found that the difference between the male and female values and difference between the parameters as measured on X-ray and CT scan was not statistically significant.

McRae line

Mean distance between the tip of the odontoid process and McRae line was 4.67 ± 1.69 mm on CT scan and

4.7 ± 1.76 mm on X-ray with a range of 1.212–9.347 mm on CT scan and 0.982–9.351 on X-ray [Table 2]. Using the Mann-Whitney test as the data were not normally distributed, the difference between the male and female values and difference between the parameters as measured on X-ray and CT scan was not statistically significant. There was not a single patient in whom the odontoid tip crossed the McRae line.

Discussion

The CVJ is a collective term that refers to the occiput, atlas, axis along with the supporting ligaments. It represents a transition zone between a mobile cranium and the relatively rigid spinal column which encloses the soft-tissue structures of the cervicomedullary junction (medulla, spinal cord, and lower cranial nerves). The majority of the spine’s movements (rotation, flexion, and extension) occur between the occiput, the atlas, and axis. The biomechanics of motion and stability at the CVJ are unique for every vertebral level and segment. An understanding of the complex CVJ anatomy and biomechanics is needed to effectively evaluate and treat the various pathological processes that affect this vital region. Advances in surgical fixation modalities and minimally invasive surgical approaches to the CVJ have encouraged further characterization of its anatomy. However, majority of the studies on this region have been conducted on dried cadaveric specimens^[9,10] and radiological studies are lacking. Dry skull measurements cannot be relied on because they may mislead surgeons due to effects of shrinkage and demineralization.

CT imaging represents a feasible, reproducible, and accurate method for the measurements of craniometry and vertebral body dimensions of the CVJ due to the high contrast resolution and good visualization of the bony anatomy. The dimensions of various parameters of the CVJ and the vertebrae differ significantly in Indian and other population groups. Previously published studies show that the dimensions of the cervical pedicle diameter differ between Indian and western population. Such a difference in dimensions of the skull baselines is also expected. There is a high incidence of CVJ anomalies in Indian population and apart from tuberculosis, trauma, and tumors, these form

Table 1: Findings of measurements for Chamberlain line and McGregor line

Measurement	On X-ray (mm)	On CT scan (mm)
Distance of odontoid tip from Chamberlain line		
Minimum	-7.851	-7.865
Maximum	+6.175	+6.237
Mean	0.528	0.498
Distance of odontoid tip from McGregor line		
Minimum	-6.051	-6.065
Maximum	+7.175	+7.237
Mean	0.228	0.213

CT – Computed tomography

Table 2: McRae line measurement (all values in millimeters)

Set of patients	Distance between the dens tip and McRae line by CT	Distance between the dens tip and McRae line by X-ray
All cases	4.67±1.69	4.7±1.76
Only male cases	4.74±1.51	4.81±1.6
Only female cases	4.57±1.92	4.56±1.97
All measurements mentioned above are in mean±SD		
	Minimum	Maximum
Distance between the dens tip and McRae line by CT	1.212	9.347
Distance between the dens tip and McRae line by X-ray	0.982	9.351

Range (all values in millimeters). No significant difference between the two groups as $P=0.89$ on using unpaired *t*-test. CT – Computed tomography; SD – Standard deviation

a common cause of spinal cord compression. Furthermore, tubercular involvement of the CVJ is not uncommon in India.

The purpose of this narrative review was to provide an up to date overview of anatomy and morphometric measurements of the commonly evaluated skull baselines in the normal Indian population as these are subject to racial and ethnic variability and compare the dimensions with those of other races and population groups. This study will also compare dimensions of the skull baselines as measured on X-ray and CT scan to assess whether X-ray is a reliable diagnostic tool to evaluate the CVJ in an emergency setting.

Batista *et al.*^[11] studied the craniometric relationship of the normal craniocervical junction based on the CT scan measurements done in 100 asymptomatic adult subjects with a mean age of 50.6 years (SD of 18.80 median 51 years, range 18–82 years). This included 52 men (52%) and 48 women (48%) patients. The mean distance of the tip of the dens from the Chamberlain line was -1.5 mm (below the line; median of -1.8 mm, SD 2.2), ranging from -7.6 (below the line) to $+5.2$ mm (above the line). In 5 patients (5%), the tip of the odontoid process was more than 2 mm above the Chamberlain line, and in one of these 5 patients (1% of the overall group), the tip of the odontoid process was more than 5 mm above the Chamberlain line. The authors concluded that because of variations in anatomy, some asymptomatic individuals would be diagnosed with basilar impression. Based on a normal distribution, the normal accepted range (± 2 SD from the mean) of the distance of dens tip in their subject population was from 5.9 mm below to 2.9 mm above the Chamberlain line. Patients with the dens tip extending more than 2.9 mm above the Chamberlain line would be considered abnormal as per this study.

Kwong *et al.*^[12] aimed to give precise values for parameters to evaluate craniovertebral settling on CT to enable early diagnosis of this condition. The authors hypothesized that the normal ranges of these parameters in the assessment of basilar invagination would differ on cross-sectional imaging because of improved visualization of the bony landmarks. One hundred men and 100 women who underwent CT that included imaging of the craniocervical junction were retrospectively identified. Patients between the ages of 18 and 49 years were included in their study. Parameters studied included Wackenheim line, McRae line, Chamberlain line, and McGregor line and measurements obtained using the Redlund–Johnell method and modified Ranawat method. There were significant differences between the CT values and previously accepted X-ray measurements for the Wackenheim, Chamberlain, and McGregor lines. The dens tip extended higher above the Chamberlain and McGregor lines than what is accepted as normal in the previously published radiographic literature. For the Chamberlain line, the odontoid tip of four patients was beyond 3 mm of the

line, with the maximum range between the Chamberlain line and odontoid tip being 6.2 mm range being -6.2 – 9.6 with a mean value of 2.3 and standard deviation of 2.6. The CT values of the Chamberlain and McGregor line were different from the X-ray values. Kwong *et al.*^[12] proposed that the McRae line should be used over other parameters for assessing basilar invagination because it is conceptually the easiest to understand and remember. The authors concluded that the Chamberlain line and McGregor line be disregarded in favor of the McRae line while evaluating basilar invagination by CT scans.

Cronin *et al.*^[13] carried out a study based on CT scans to evaluate the mean distance from the tip of the dens to the standard skull-base lines (Chamberlain's, McGregor's, and McRae's lines) and to compare these measurements to previously published data based on plain X-rays and MRI measurements. Sagittal CT images centered on the midline in the coronal section of 150 adult subjects were evaluated retrospectively. The shortest perpendicular distance between the tip of the dens and Chamberlain's, McGregor's, and McRae's baselines was measured for each subject. Statistical analysis was performed to compare the CT data with the previously obtained MRI and plain film data. The subjects included in the study consisted of those undergoing CT imaging of the neck for ear, nose, and throat conditions, CT angiography of the aortic and carotid vessels in whom the CT scans were essentially normal. Thus, there was no additional radiation exposure or cost for imaging. The mean position of the dens was 1.4 mm below Chamberlain's line (median 1.2 mm, SD 2.4 mm), 0.8 mm (median 0.9 mm, SD 3 mm) below McGregor's line, and 5 mm (median 5 mm, SD 1.8 mm) below McRae's line. There was no significant difference between these parameters as measured in male and female patients ($P > 0.05$) or between the CT and previous MRI measurements ($P > 0.05$). The authors concluded that these results will provide the mean and range of normal distance from the dens to the most frequently used skull-base lines in the current population on CT scan imaging.

Cronin *et al.*^[14] carried out MRI-based assessment and measurement of the normal position of the tip of the odontoid process. This study evaluated the distances between the tip of the odontoid process and different baselines used for the evaluation of the CVJ anatomy. The sample size included in the study was 200 and midline sagittal MRI brain images were evaluated retrospectively. Individuals included in the study did not have symptoms or signs suggestive of basilar invagination, history of spinal trauma, vertebral collapse or disease. These findings were then compared with previous values as evaluated on plain X-ray. The mean position of the odontoid peg was 1.2 mm (median 1.5 mm, SD 3 mm) below Chamberlain's line; 0.9 mm (median 1.1, SD 3 mm) below McGregor's line; and 4.6 mm (median 4.8, SD 2.6) below McRae's line. The authors concluded that these results will provide the mean

and range of normal distances from the tip of the odontoid process to the most frequently used skull baselines using MRI.

There was not a single patient in our study in whom the odontoid tip crossed the McRae line. The McRae line is conceptually the easiest measurement to understand and remember. Any protrusion of the tip of the odontoid process beyond the foramen magnum is considered to be abnormal. This finding is supported by our study. Furthermore, the Chamberlain and McGregor lines rely on the identification of the hard palate as a bony landmark. However, the hard palate may not always be included in the plain X-ray, CT, or MRI studies depending on the FOV. For these reasons, we recommend that these two measures (Chamberlain line and McGregor line) be disregarded in favor of the McRae line for screening purposes while dealing with pathologies of the CVJ.

Conclusion

There are certain differences in the parameters of the skull baselines in the Indian population when compared to other races and ethnicities. These dimensions will provide a baseline normal value for all parameters in Indian population and will be useful in categorizing Indian patients as normal and affected. In addition, these parameters can be used before surgical procedures for preoperative planning.

There is no significant difference between measurements as made on X-ray and CT scan. Hence, X-ray is a reliable diagnostic technique for assessing morphometry of the skull baselines in an emergency setting and in peripheral areas where facilities for CT scan and MRI imaging are not available.

Financial support and sponsorship

Nil.

Conflicts of interest

There are no conflicts of interest.

References

1. Chamberlain WE. Basilar impression (Platybasia): A bizarre developmental anomaly of the occipital bone and upper cervical spine with striking and misleading neurologic manifestations. *Yale J Biol Med* 1939;11:487-96.
2. McGregor M. The significance of certain measurements of the skull in the diagnosis of basilar impression. *Br J Radiol* 1948;21:171-81.
3. McRae DL, Barnum AS. Occipitalization of the atlas. *Am J Roentgenol Radium Ther Nucl Med* 1953;70:23-46.
4. Tassanawipas A, Mokkhavea S, Chatchavong S, Worawittayawong P. Magnetic resonance imaging study of the cranio-cervical junction. *J Ortho Surg* 2005;13:228-231.
5. Patwardhan AR, Nemade PS, Bhosale SK, Srivastava SK. Computed tomography-based morphometric analysis of cervical pedicles in Indian population: A pilot study to assess feasibility of transpedicular screw fixation. *J Postgrad Med* 2012;58:119-22.
6. Gopalrao SR, Solanke P, Ugale M, Balsurkar S. Computed tomographic scan study of morphometry of foramen magnum. *Int J Curr Res Rev* 2013;5:41-8.
7. Chow SC, Chow J, Wang H, Lokhnygina Y. Sample size calculations. In: *Clinical Research*. New York: Taylor & Francis; 2003. p. 50-2.
8. Shrout PE, Fleiss JL. Intraclass correlations: Uses in assessing rater reliability. *Psychol Bull* 1979;86:420-8.
9. Chethan P, Prakash KG, Murlimanju BV, Prashanth KU, Prabhu LV, Saralaya VV, *et al.* Morphological analysis and morphometry of the foramen magnum: An anatomical investigation. *Turk Neurosurg* 2012;22:416-9.
10. Kumar A, Dave M, Anwar S. Morphometric evaluation of foramen magnum in dry human skulls. *Int J Anat Res* 2015;3:1015-23.
11. Batista UC, Joaquim AF, Fernandes YB, Mathias RN, Ghizoni E, Tedeschi H. Computed tomography evaluation of the normal craniocervical junction craniometry in 100 asymptomatic patients. *Neurosurg Focus* 2015;38:E5.
12. Kwong Y, Rao N, Latief K. Craniometric measurements in the assessment of craniovertebral settling: Are they still relevant in the age of cross-sectional imaging? *AJR Am J Roentgenol* 2011;196:W421-5.
13. Cronin CG, Lohan DG, Mhuirheartigh JN, Meehan CP, Murphy J, Roche C. CT evaluation of chamberlain's, McGregor's, and McRae's skull-base lines. *Clin Radiol* 2009;64:64-9.
14. Cronin CG, Lohan DG, Mhuirheartigh JN, Meehan CP, Murphy JM, Roche C, *et al.* MRI evaluation and measurement of the normal odontoid peg position. *Clin Radiol* 2007;62:897-903.