



Rare case of acute renal failure secondary to Erdheim-Chester disease

Joshua Makary^{a,b,*}, Prem Rathore^b

^a The University of Sydney, Australia

^b Campbelltown Hospital, Australia

ARTICLE INFO

Keywords:

Erdheim-Chester disease
Non-langerhans histiocytosis
Renal failure
Renal manifestation

ABSTRACT

In this report we describe the clinical journey of a 62-year-old male that presented with acute kidney injury secondary to Erdheim-Chester disease, a non-Langerhans variant of histiocytosis rarely encountered by urological surgeons. ECD can uncommonly cause acute renal failure and management includes decompression of the collecting system. A multi-disciplinary approach is required to facilitate adequate investigation to determine the specific ECD subtype and most appropriate treatment options, particularly as the available targeted therapies have only recently been utilised.

1. Introduction

In this report we describe the clinical journey of a 62-year-old male that presented with acute kidney injury secondary to Erdheim-Chester disease (ECD). ECD is a non-Langerhans variant of histiocytosis rarely encountered by urological surgeons.

2. Case presentation

2.1. Background

The first manifestation of ECD in this patient was in early 2018 when he presented to the local emergency department with dyspnoea and pleuritic chest pain. A CT (computed tomography) chest done at the time revealed a left sided pleural effusion and an unusual rind-like structure surrounding both kidneys (often referred to as “hairy kidney”). Renal function tests ordered by the emergency physician revealed an abnormally high serum creatinine of 150 μmol/L. After the patient was discharged, he received outpatient input from the respiratory, renal and urology departments to determine the underlying cause of his condition. A pleural biopsy done in late 2018 to investigate the cause of pleural effusion showed focal lymphoid aggregates and fibrinous granulation tissue. A renal biopsy done in 2019 revealed “foamy histiocytes” which are characteristic of ECD. The patient was then referred to a haematologist and immunologist to guide management. Up until a recent acute deterioration in December 2021 the patient was managed with annual ureteric stent exchanges and commenced on prednisolone and later mycophenolate.

2.2. Acute presentation with renal failure

In December 2021, the patient presented with lethargy, anuria and acute kidney injury, with a creatinine level of 550 μmol/L (routine serum creatinine levels a month prior were 150 μmol/L). A CT KUB was done, which again revealed the “hairy kidney” appearance and appropriately positioned ureteric stents (Fig. 1). The radiologist also reported the appearance of both kidneys as hydronephrotic. A discussion between the urology and renal teams resulted in the patient undergoing urgent cystoscopy and bilateral ureteric stent exchange with 6 Fr black silicone stents. Retrograde pyelograms done at the time revealed non dilated renal pelvises bilaterally (Fig. 2). The patient was managed in the intensive care unit with haemodialysis until the urine output normalised. The renal function returned to baseline levels over a one-week period.

3. Discussion

Less than 600 cases of ECD have been reported in the literature and of these, the most commonly reported site of disease are the long bones.¹ Extra-osseous manifestations are not unusual and as such the symptomatology and clinical presentation are dependent on the site and severity of disease. Renal manifestations of ECD are seen in up to 80% of patients and often lead to compression of the renal parenchyma or ureteric obstruction secondary to retroperitoneal fibrosis.² Investigations required to confirm the diagnosis include imaging and biopsy of the disease site. CT abdomen/pelvis classically reveals a rind-like perinephric structure. Histopathological evaluation of tissue sample may

* Corresponding author. Campbelltown Hospital, Therry rd, Campbelltown, NSW, 2560, Australia.

E-mail address: Joshua.Makary@health.nsw.gov.au (J. Makary).

<https://doi.org/10.1016/j.eucr.2022.102062>

Received 22 February 2022; Received in revised form 17 March 2022; Accepted 23 March 2022

Available online 25 March 2022

2214-4420/Crown Copyright © 2022 Published by Elsevier Inc.

(<http://creativecommons.org/licenses/by-nc-nd/4.0/>).

This is an open access article under the CC BY-NC-ND license

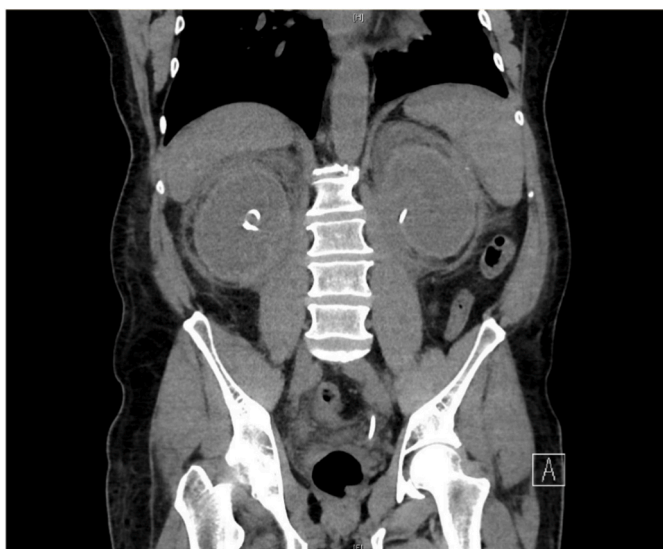

Fig. 1. CT KUB December 2021. Bilateral rind like perinephric structure, ‘hairy kidney’. Ureteric stents insitu bilaterally.

also demonstrate ‘foamy histiocytes’, which are diagnostic of ECD.³

When ECD is asymptomatic and disease progression is indolent, patients can be managed conservatively. However, patients such as the

one in this case report often deteriorate despite medical therapy due to delays in diagnosis and a lack of effective treatment options. Treatment with prednisolone and mycophenolate was of unclear benefit in our patient. To assess the response of medical therapy, serial fluorodeoxyglucose positron emission tomography (FDG PET) (Fig. 3) can be used to monitor changes in tracer uptake, which correspond to the degree of metabolic activity.⁴ Additionally, serum creatinine and inflammatory markers can be monitored to assess clinical improvement.

In the acute setting there is a role for urgent decompression of the collecting system to address the post renal cause of acute kidney injury. Both retrograde ureteric stent and nephrostomy tube insertion are options in the emergency setting and both are associated with unique risk profiles. When assessing these risks, the severity of hydronephrosis is a factor in determining the difficulty of nephrostomy tube insertion. In our patient, although the CT KUB in Dec 2021 reported both kidneys appeared hydronephrotic, the opposite was found during the bilateral retrograde pyelogram study done at the time of stent exchange, which revealed completely non-dilated collecting systems. This discrepancy, highlights the importance of clinical history when reviewing imaging. For urological surgeons, a review of prior retrograde pyelogram studies and CT KUB is paramount to determining the safest procedural approach.

A concerning feature of the patient’s condition was that ureteric stents were insitu at the time of his acute presentation and inserted 12 months prior. The rapid improvement with stent exchange suggests that stent obstruction was likely a contributing factor to the patient’s presentation.

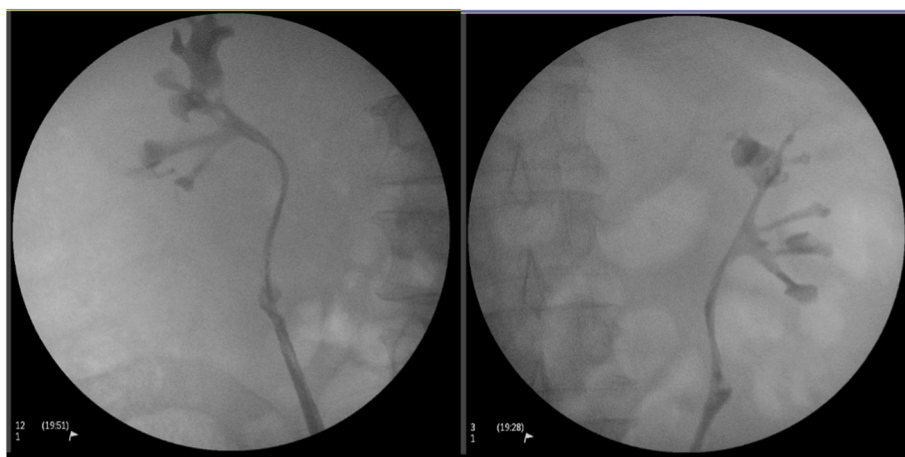


Fig. 2. Right and left retrograde pyelogram December 2021. Showing non dilated renal pelvis bilaterally.

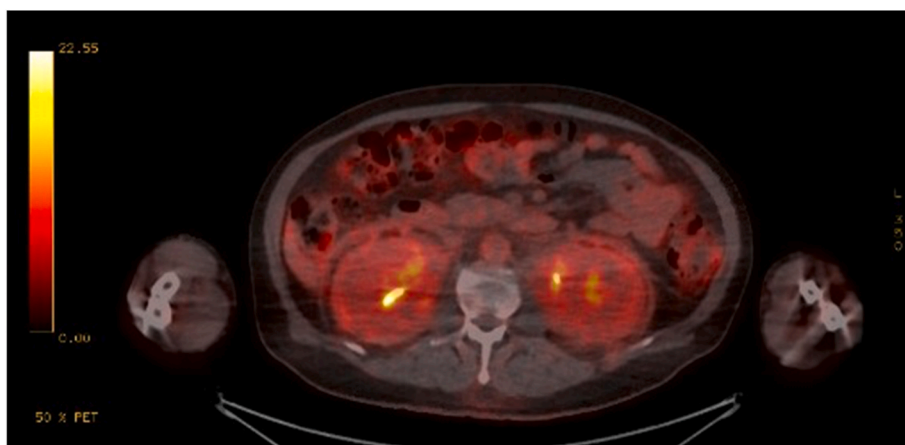


Fig. 3. FDG PET CT May 2021. Displaying increased metabolic activity in kidneys bilaterally.

The acute presentation of the patient triggered a multi-disciplinary team (MDT) discussion which resulted in a re-examination of the renal and pleural biopsy specimens taken in 2019, specifically for molecular genetic testing. Subsequently, the patient was diagnosed with “BRAF wild-type ECD” and commenced on Cobimetinib, which has recently shown some promise in halting disease progression and inducing remission.⁵

4. Conclusion

ECD can uncommonly cause acute renal failure. Management includes decompression of the collecting system. A multi-disciplinary approach is required to facilitate adequate investigation to determine the specific ECD subtype and most appropriate treatment options, particularly as the available targeted therapies have only recently been utilised.

Funding

Nil source of funding to declare.

Declaration of competing interest

The authors declare that they have no conflict of interest.

References

1. Yoo J, Gunsteen C, Patel S, et al. Kidney transplantation for Erdheim-Chester disease. *Case Rep Transplant.* 2020, 3954165.
2. Yelfimov DA, Lightner DJ, Tollefson MK. Urologic manifestations of Erdheim-Chester disease. *Urology.* 2014;84(1):218–221.
3. Graziani G, Podestà MA, Cucchiari D, Reggiani F, Ponticelli C. Erdheim–Chester disease: from palliative care to targeted treatment. *Clinical Kidney J.* 2014;7(4): 339–343.
4. Young JR, Johnson GB, Murphy RC, Go RS, Broski SM. (18)F-FDG PET/CT in Erdheim-Chester disease: imaging findings and potential BRAF mutation biomarker. *J Nucl Med.* 2018;59(5):774–779.
5. Cohen Aubart F, Emile J-F, Maksud P, et al. Efficacy of the MEK inhibitor cobimetinib for wild-type BRAF Erdheim-Chester disease. *Br J Haematol.* 2018;180(1):150–153.