

This is an Open Access article licensed under the terms of the Creative Commons Attribution-NonCommercial-NoDerivs 3.0 License (www.karger.com/OA-license), applicable to the online version of the article only. Distribution for non-commercial purposes only.

Long-Term Therapy of a Patient with Summerskill-Walshe-Tygstrup Syndrome by Applying Prometheus® Liver Dialysis: A Case Report

Mikolaj Walensi^{a, b} Ali Canbay^a Oliver Witzke^c
Guido Gerken^a Alisan Kahraman^a

Departments of ^aGastroenterology and Hepatology, ^bAngiology and ^cNephrology, University Hospital Essen, Essen, Germany

Key Words

Benign recurrent intrahepatic cholestasis · Cholestasis · Prometheus® dialysis · Summerskill-Walshe-Tygstrup syndrome

Abstract

Summerskill-Walshe-Tygstrup syndrome is a rare benign chronic liver disease characterized by recurring cholestasis with jaundice and severe pruritus. Due to insufficient conservative treatment, liver dialysis by Prometheus® was applied to a 45-year-old female patient with resistant pruritus. Initially, other possible liver diseases were excluded and the patient was treated symptomatically since the diagnosis of Summerskill-Walshe-Tygstrup was stated in 1998. As conservative and endoscopic methods progressively failed to relieve the patient's suffering, Prometheus® liver dialysis was performed regularly since 2006 at 3-month intervals and successfully led to a decrease in the patient's symptoms. Cholestatic liver enzymes and also serum bile acids could be lowered significantly from an average of 22.5 ± 2.7 to 7.3 ± 1.7 $\mu\text{mol/l}$. Consequently, Prometheus® liver dialysis may be a beneficial option for patients with benign recurrent intrahepatic cholestasis suffering from therapy-resistant symptoms and may be used as well as other extracorporeal liver support devices which have already been reported to improve cholestatic pruritus.

Introduction

Benign recurrent intrahepatic cholestasis (BRIC) is an autosomal-recessive cholestatic disorder [1] which was first described by Summerskill and Walshe in 1959 in two patients with recurring cholestasis [2, 3]. Ten years later, Tygstrup and Jensen [4] formulated the defining criteria as: (1) several episodes of pronounced jaundice with severe pruritus separated by symptom-free intervals lasting several months or years, (2) absence of a factor known to produce intrahepatic cholestasis (e.g. drug intake, pregnancy, intoxication), (3) biomechanical signs of obstructive jaundice but with normal intrahepatic and extrahepatic bile ducts (visualized by cholangiography), and finally (4) bile plugs within ducts in histological specimens [1, 2, 4, 5].

Previously, Summerskill-Walshe-Tygstrup syndrome has been regarded as an idiopathic disease [1, 2]. Meanwhile it is known that BRIC displays a genetic heterogeneity and is associated with mutations in the ATP8B1 (BRIC 1) and ABCB11 (BRIC 2) genes and belongs to the ‘canalicular transport defects’ [1]. As it typically does not lead to liver cirrhosis, it is considered as a benign liver disease [5]. For the right diagnosis, both clinical and pathological features are pivotal [5, 6]. Therapeutically, in moderate cases, conservative treatment with cholestyramine, rifampicin [6–8], steroids, phenobarbital, ursodeoxycholic acid or 5-adenosylmethionine [5] may be applied. In more severe cases, a nasobiliary drainage tube can be inserted, or surgical interventions such as partial biliary diversion or ileal bypass may be performed to relieve the patient’s suffering [7]. Despite these various possibilities, in some patients symptoms – mostly pruritus – may still be resistant [5, 9]. For such severe cases, new therapeutic approaches are required to avoid liver transplantation as the ultimate required therapy. In 1988, several attempts succeeded in lowering bile acids by plasmapheresis [10, 11]. Additionally, since 2001, albumin dialysis (Molecular Adsorbent Recirculation System, MARS®) has been successfully applied to improve these patients’ medical condition and to significantly reduce serum bilirubin and bile acid levels [8, 12, 13].

In the case of our patient, the extracorporeal liver assist device Prometheus® (Fresenius Medical Care, Bad Homburg, Germany), which is frequently used in patients with severe cholestasis or liver failure as a bridging procedure to transplantation [14, 15], has been applied to resolve therapy-resistant pruritus.

Case Report

We report a 45-year-old Caucasian woman with Summerskill-Walshe-Tygstrup syndrome which was first diagnosed in 1998. Despite extensive conservative therapy with prednisolone (5–10 mg/day), ursodeoxycholic acid (3 × 500 mg/day) and cholestyramine (3 × 4 g/day), she suffered from intermittent attacks of cholestatic jaundice, severe pruritus and anxious nervousness. On clinical examination, she had never had any evidence of hepatomegaly, ascites or encephalopathy. Usually, serum bile acids were elevated at $22.5 \pm 2.7 \mu\text{mol/l}$ (normal $<6 \mu\text{mol/l}$), while transaminases as well as γ -glutamyltransferase (γ -GT) and alkaline phosphatase (AP) remained at approximately normal values ($<35 \text{ U/l}$), respectively. Virology (hepatitis A–E, CMV, EBV and HSV) and immunological serology (ANA, AMA, ANCA, SMA, SLA, LKM, γ -globulin and IgG/IgM) were all negative. The patient denied any alcohol or drug abuse. No liver diseases were known in the family history. However, both the patient’s grandmother and mother suffered from cholecystolithiasis.

In March 2008 the patient presented with profound pruritus and agitation. Bile acids were highly elevated at $35.3 \mu\text{mol/l}$ (normal $<6 \mu\text{mol/l}$). Ultrasound examination revealed normal liver morphology without signs of obstructive cholestasis (diameter of the common bile duct 3 mm). Additionally, a liver biopsy was performed which demonstrated normal hepatocyte architecture without inflammatory cells or bile plugs within the canaliculi ([fig. 1](#)). Following endoscopic retrograde cholangiopancreatography, a 7 Fr nasobiliary drainage tube was inserted ([fig. 2](#)), unfortunately without sustained clinical benefit. Therefore, indication for Prometheus® liver dialysis was stated. The first 3 dialysis cycles were performed in April 2008, followed by another 5 cycles in June 2008, leading to complete recovery and decreasing laboratory parameters. In the following years, Prometheus® liver dialysis was performed in regular intervals as demonstrated in [fig. 3](#). After these sessions, bile acids were lowered significantly by 78% from an average of 22.5 ± 2.7 to $7.3 \pm 1.7 \mu\text{mol/l}$ ($p = 0.003$). Due to cicatrization of the dialysis catheter, a Cimino-Brescia fistula was finally applied in January 2011.

Discussion

We here report a patient with characteristic features of BRIC, occurring frequently with insistent symptoms. She suffered from intermitting severe pruritus as well as infrequent jaundice. This disease is remarkable for its discrepancy between a rise in serum bile acids at the onset of each attack and a later rise in total serum bilirubin levels. Due to conservative treatment with prednisolone (5–10 mg/day), ursodeoxycholic acid ($3 \times 500 \text{ mg/day}$) and cholestyramine ($3 \times 4 \text{ g/day}$), the icteric episodes could be reduced and only appeared rarely. In contrast, conservative treatment did not have any positive effects on agonizing pruritus. During this stage, laboratory parameters revealed the typical periodic elevation of total serum bilirubin and bile acids. However, transaminases, AP and γ -GT were less affected ($<35 \text{ U/l}$). Whenever intractable pruritus appeared, liver dialysis using the Prometheus® system was performed. The first cycle was set after worsening of the patient's condition when a 7 Fr nasobiliary drainage tube dislocated in March 2008. In the following years, 3 up to 5 cycles of liver dialysis per session were necessary to normalize laboratory parameters and relieve the patient's suffering.

This range for dialysis sessions is in accordance with other studies describing the application of Prometheus® in patients with insistent pruritus [16–18]. The pathogenesis of cholestatic pruritus is not completely clear. Besides bile acids, which apparently seem to play a major role as pruritogens, elevated levels of endogenous opioids and amphiphilic lysophosphatidic acid (LPA) were also found in patients with cholestatic pruritus [16]. In contrast to bile acids, LPA and autotaxin (the enzyme responsible for the transformation of lysophosphatidylcholine into LPA) plasma levels were demonstrated to correlate significantly with the severity of patients' pruritus [19]. This indicates a crucial role of LPA and autotaxin in the pathophysiology of pruritus.

Conservative treatment is based upon this knowledge as e.g. the bile acid sequestrate cholestyramine is recommended as the first-line treatment by EASL and AASLD [17]. Involvement of the opioid system furthermore allows the application of opioid antagonists [5] such as naltrexone to resolve pruritus. Reported positive effects of the serotonin re-uptake inhibitor sertraline actually indicate an involvement of the serotonin system [16]. Despite these numerous mechanisms by which the pathogenesis of pruritus can already be affected therapeutically to relieve the majority of patients from pruritus, some of them remain resistant to these therapies. As severe pruritus

may lead to reduced quality of life and even to suicide [16, 17], the necessity for an effective therapy becomes obvious. In these patients, e.g. with primary biliary cirrhosis [20], liver transplantation may become the ultimate therapeutic option [17].

Until now, several studies have provided evidence for extracorporeal liver support systems, first for MARS® and later for Prometheus®, to be an effective and safe therapeutic alternative for patients with cholestatic pruritus [8, 12, 13, 16, 17]. With regard to the elimination of albumin-bound molecules such as bilirubin (strongly albumin-bound) or bile acids (less tightly albumin-bound), there are slight differences between these two methods [18]. Krisper and Stauber [18] characterized the dialysis performance of Prometheus® as less selective to albumin-bound molecules and more efficient at the same time as compared to MARS®. Concerning bile acid removal, Stadlbauer et al. [21] found similar efficiency for both Prometheus® and MARS®, while a change in the particular bile acid profile towards hydrophobic bile acids was observed only under Prometheus® treatment. Besides changes in white blood cell count, no adverse effects have been reported so far [18, 22]. Furthermore, Leckie et al. [17] described decreasing hemoglobin and thrombocyte levels, however not requiring further treatment.

Conclusion

Because of its rareness Summerskill-Walshe-Tygstrup syndrome is first considered in the differential diagnosis of cholestasis after many years of extensive investigations. Treatment is difficult, purely symptomatic, and unfortunately often without marked effects. However, in some cases, Prometheus® liver dialysis appears to be a beneficial alternative for patients with BRIC-related symptoms – mainly intractable pruritus – resistant to conservative treatment.

Disclosure Statement

The authors have no conflicts of interest to declare.

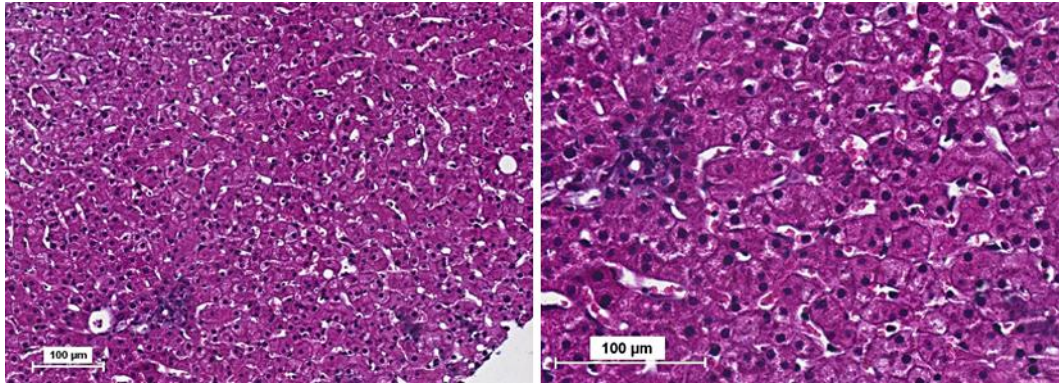


Fig. 1. Liver biopsy revealed normal hepatocyte architecture without accumulation of inflammatory cells or bile infarcts after H&E staining. Left panel: scale bar = 100 μ m, magnification 20 \times . Right panel: scale bar = 100 μ m, magnification 100 \times .

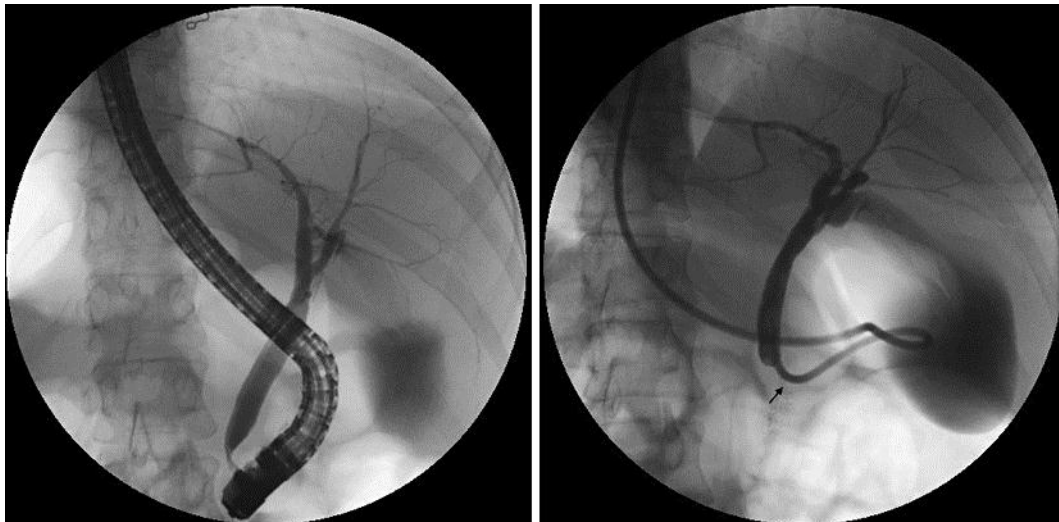


Fig. 2. Following endoscopic retrograde cholangiopancreatography, a 7 Fr nasobiliary drainage tube (marked by the arrow) was inserted. The intrahepatic bile ducts were not extended.

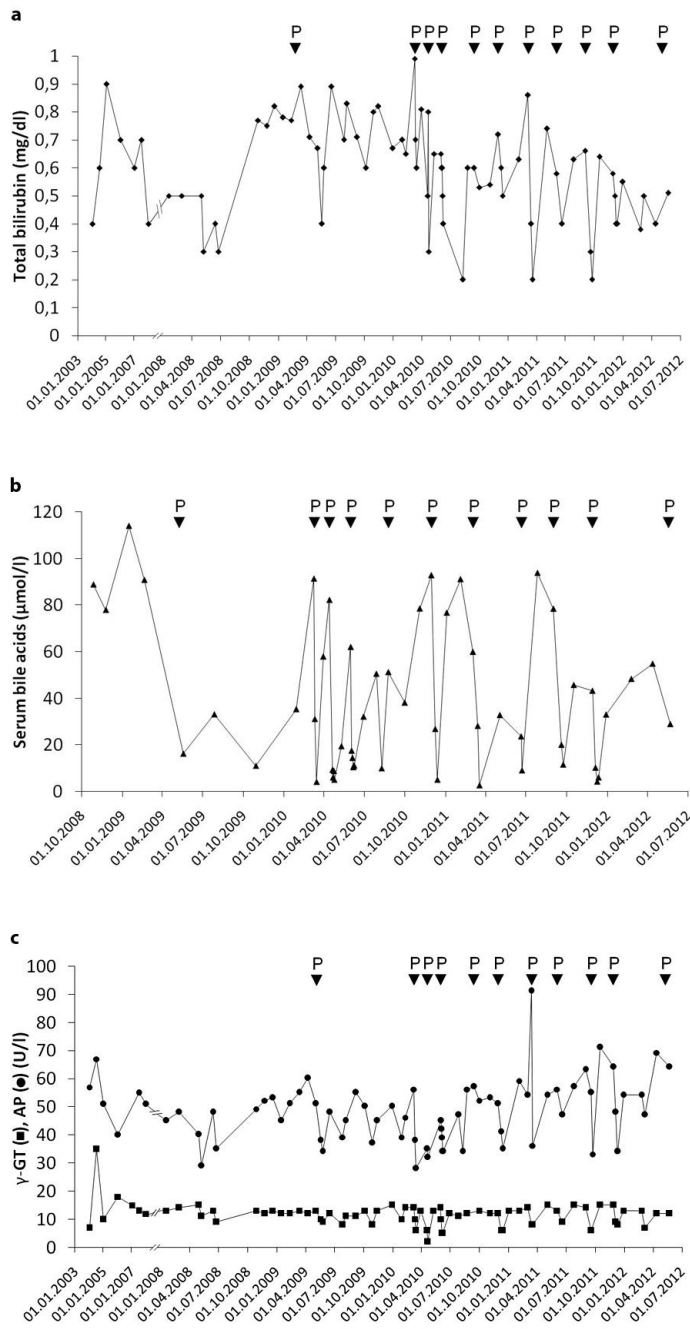


Fig. 3. Effect of Prometheus® liver dialysis on cholestatic liver parameters. In general, P indicates the date liver dialysis was performed. Course of total serum bilirubin (a), bile acid levels (b), and finally γ-GT and AP (c) are shown following liver dialysis.

References

- 1 van Mil SW, Houwen RH, Klomp LW: Genetics of familial intrahepatic cholestasis syndromes. *J Med Genet* 2005;42:449–463.
- 2 Summerskill WH, Walshe JM: Benign recurrent intrahepatic ‘obstructive’ jaundice. *Lancet* 1959;2:686–690.
- 3 Wareham NJ, Dickson CJ, Baskerville PA: Benign recurrent intrahepatic cholestasis. *J R Soc Med* 1985;78:955–956.
- 4 Tygstrup N, Jensen B: Intermittent intrahepatic cholestasis of unknown etiology in five young males from the Faroe Islands. *Acta Med Scand* 1969;185:523–530.
- 5 Westermann G, Lügering N, August C, Rahn KH, Kisters K: Classic case of benign recurrent intrahepatic cholestasis (Summerskill-Walshe-Tygstrup syndrome) (in German). *Med Klin (Munich)* 2000;95:349–354.
- 6 Spiegel EL, Schubert W, Perrin E, Schiff L: Benign recurrent intrahepatic cholestasis, with response to cholestyramine. *Am J Med* 1965;39:682–688.
- 7 Stapelbroek JM, van Erpecum KJ, Klomp LW, Houwen RH: Liver disease associated with canalicular transport defects: current and future therapies. *J Hepatol* 2010;52:258–271.
- 8 Sturm E, Franssen CF, Gouw A, Staels B, Boverhof R, De Knegt RJ, Stellaard F, Bijleveld CM, Kuipers F: Extracorporeal albumin dialysis (MARS) improves cholestasis and normalizes low apo A-I levels in a patient with benign recurrent intrahepatic cholestasis (BRIC). *Liver* 2002;22(suppl 2):72–75.
- 9 Summerfield JA, Scott J, Berman M, Ghent C, Bloomer JR, Berk PD, Sherlock S: Benign recurrent intrahepatic cholestasis: studies of bilirubin kinetics, bile acids, and cholangiography. *Gut* 1980;21:154–160.
- 10 Nakad A, Geubel AP, Lejeune D, Delannoy A, Bosly A, Dive C: Plasmapheresis: an effective therapy for cholestatic episodes related to benign recurrent intrahepatic cholestasis? *Ann Med Interne (Paris)* 1988;139:128–130.
- 11 Sanderson F, Quaranta JF, Cassuto-Viguiere E, Grimaldi C, Troin D, Dujardin P, Delmont J: The value of plasma exchange during flare-ups of benign recurrent intrahepatic cholestasis (in French). *Ann Med Interne (Paris)* 1988;139(suppl 1):35–37.
- 12 Huster D, Schubert C, Achenbach H, Caca K, Mössner J, Berr F: Successful clinical application of extracorporeal albumin dialysis in a patient with benign recurrent intrahepatic cholestasis (BRIC). *Z Gastroenterol* 2001;39(suppl 2):13–14.
- 13 Saich R, Collins P, Ala A, Standish R, Hodgson H: Benign recurrent intrahepatic cholestasis with secondary renal impairment treated with extracorporeal albumin dialysis. *Eur J Gastroenterol Hepatol* 2005;17:585–588.
- 14 Kribben A, Gerken G, Haag S, Herget-Rosenthal S, Treichel U, Betz C, Sarrazin C, Hoste E, Van Vlierberghe H, Escorsell A, Hafer C, Schreiner O, Galle PR, Mancini E, Caraceni P, Karvellas CJ, Salmhofer H, Knotek M, Ginès P, Kozik-Jaromin J, Rifai K; HELIOS Study Group: Effects of fractionated plasma separation and adsorption on survival in patients with acute-on-chronic liver failure. *Gastroenterology* 2012;142:782–789.e3.
- 15 Hassanein TI, Schade RR, Hepburn IS: Acute-on-chronic liver failure: extracorporeal liver assist devices. *Curr Opin Crit Care* 2011;17:195–203.
- 16 Fuhrmann V, Drolz A, Traune M: Extracorporeal artificial liver support systems in the management of intractable cholestatic pruritus. *Liver Int* 2011;31(suppl 3):31–33.
- 17 Leckie P, Tritto G, Mookerjee R, Davies N, Jones D, Jalan R: ‘Out-patient’ albumin dialysis for cholestatic patients with intractable pruritus. *Aliment Pharmacol Ther* 2012;35:696–704.
- 18 Krisper P, Stauber RE: Technology insight: artificial extracorporeal liver support – how does Prometheus compare with MARS? *Nat Clin Pract Nephrol* 2007;3:267–276.
- 19 Kremer AE, Martens JJ, Kulik W, Ruëff F, Kuiper EM, van Buuren HR, van Erpecum KJ, Kondrackiene J, Prieto J, Rust C, Geenes VL, Williamson C, Moolenaar WH, Beuers U, Oude Elferink RP: Lysophosphatidic acid is a potential mediator of cholestatic pruritus. *Gastroenterology* 2010;139:1008–1018, 1018.e1.
- 20 Beuers U, Gerken G, Pusch T: Biliary drainage transiently relieves intractable pruritus in primary biliary cirrhosis. *Hepatology* 2006;44:280–281.
- 21 Stadlbauer V, Krisper P, Beuers U, Haditsch B, Schneditz D, Jung A, Putz-Bankuti C, Holzer H, Trauner M, Stauber RE: Removal of bile acids by two different extracorporeal liver support systems in acute-on-chronic liver failure. *ASAIO J* 2007;53:187–193.
- 22 Heemann U, Treichel U, Loock J, Philipp T, Gerken G, Malago M, Klammt S, Loehr M, Liebe S, Mitzner S, Schmidt R, Stange J: Albumin dialysis in cirrhosis with superimposed acute liver injury: a prospective, controlled study. *Hepatology* 2002;36:949–958.