

# PROLONGED OZURDEX-MACULAR CONTACT FOLLOWING VITRECTOMY FOR MACULAR HOLE

Aditya S. Kelkar, FRCS, Jai A. Kelkar, FRCS, Aanchal A. Agarwal, MBBS, Hetal M. Mehta, MS, DNB, FVRS, Shreekant B. Kelkar, MS

**Purpose:** To evaluate the outcome of prolonged ozurdex-macular contact following vitrectomy for macular hole.

**Methods and Patients:** A 63-year-old woman with subtle vitreomacular traction and macula edema in the left eye underwent femto laser-assisted cataract surgery with lens implant and ozurdex injection. Postoperatively, patient developed macular hole for which she underwent vitrectomy.

**Results:** The steroid implant that remained in contact with the fovea for 16 weeks disappeared on its own without causing any retinal toxicity, and the best-corrected visual acuity improved to 6/9.

**Conclusion:** Vitreomacular traction with edema may worsen after cataract surgery and ozurdex injection. Ophthalmologists should keep in mind this rare possible complication and make patients aware of the same.

RETINAL CASES & BRIEF REPORTS 16:168–169, 2022

*From the Department of Ophthalmology, National Institute of Ophthalmology, Pune, India.*

Amacular hole formation, secondary to cataract surgery and intravitreal injection of a steroid implant, is rare. Following vitrectomy for the same, the macular hole closed; however, the steroid implant (Ozurdex; Allergan Inc, Irvine, CA) was noted lying in contact with the macula for nearly 16 weeks. The prolonged contact with fovea did not result in any adverse outcome in our case.

## Case Report

A 63-year-old, hypertensive woman, presented with decrease in vision in the left eye. Best-corrected visual acuity was 6/24 in the

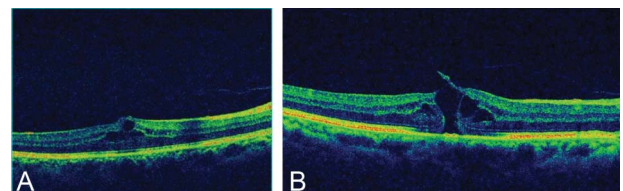
None of the authors has any financial/conflicting interests to disclose.

This is an open-access article distributed under the terms of the Creative Commons Attribution-Non Commercial-No Derivatives License 4.0 (CCBY-NC-ND), where it is permissible to download and share the work provided it is properly cited. The work cannot be changed in any way or used commercially without permission from the journal.

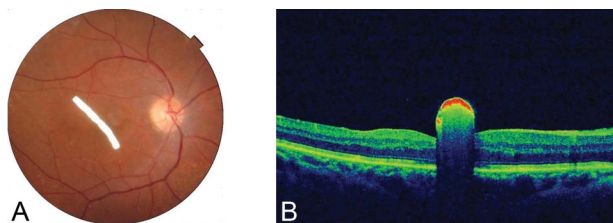
Reprint requests: Aditya S. Kelkar, FRCS, National Institute of Ophthalmology, 1187/30, Off Ghole Road, Near, Mahatma Phule Museum, Shivajinagar, Pune, Maharashtra 411005, India; e-mail: adityapune4@gmail.com

left eye and 6/9 in the right eye. On slit-lamp examination, both eyes had immature cataract. Intraocular pressure was 16 mmHg and 18 mmHg in the right eye and left eye respectively, by applanation tonometry. Biomicroscopic fundus examination was normal in right eye, but a branched retinal venular occlusion with macular edema was noted in the left. Optical coherence tomography (OCT) confirmed the presence of macular edema associated with subtle vitreomacular traction (Figure 1A). Patient underwent uneventful femto laser-assisted cataract surgery with lens implant and Ozurdex injection under topical anesthesia after obtaining an informed written consent.

Postoperatively, the best-corrected visual acuity improved to 6/12 by the end of first week. However, three weeks later, she presented with decrease in vision and metamorphopsia. On examination visual acuity in left eye was 6/24. On slit-lamp examination, there was good pseudophakia, Ozurdex implant was seen floating in the vitreous cavity, and on fundus examination, a full-thickness macular hole was noted and confirmed on OCT (Figure 1B). Patient underwent pars plana vitrectomy, internal



**Fig. 1.** A. Shows presence of macular edema with subtle vitreomacular traction before Ozurdex injection. B. Shows presence of macular hole after Ozurdex injection.



**Fig. 2.** A. Fundus image and (B) OCT 2 weeks postvitrectomy showing Ozurdex implant at the macula.

limiting membrane peeling with forceps performed after staining with Brilliant Blue G dye and fluid–gas exchange (20% SF6) after obtaining an informed written consent for the same. The surgery was uneventful. At the end of fluid–air exchange, the steroid implant was seen lying in contact with the retina between the optic disk and the fovea.

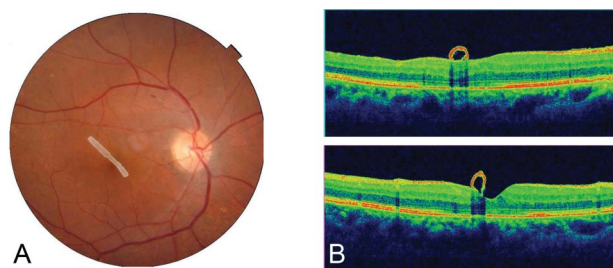
Day 1, postoperatively, the best-corrected visual acuity was counting finger 1 m, gas bubble present, retina attached, and the steroid implant was on the fovea. One week later, the gas bubble reduced but the implant remained in contact with the retina at the same site (Figure 2A and B). On subsequent follow-ups, implant was seen to be reducing in size (Figure 3A and B), and by the end of 16 weeks postoperatively, it had completely disappeared. Fundus and OCT imaging showed no traces of the implant, and macular hole was closed (Figure 4A and B). Best-corrected visual acuity improved to 6/9, and multifocal erg was normal.

### Discussion

Combined cataract surgery with intravitreal Ozurdex implant is safe and effective in cases with coexisting cataract and retinal pathologies such as diabetic macular edema and vascular occlusions.<sup>1</sup>

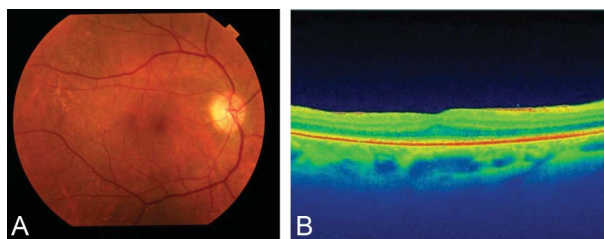
The macular hole formation after cataract surgery or Ozurdex implant is rare.<sup>2,3</sup>

Although exact mechanism is not known, in our



**Fig. 3.** A. Fundus image and (B) OCT of the macular area 8 weeks postvitrectomy showing Ozurdex implant at the macula with sealed macular hole.

case, the pre-existing subtle vitreomacular traction seems to be the predisposing factor for the development of macular hole after uneventful combined



**Fig. 4.** A. Fundus image and (B) OCT of the macular area 16 weeks postvitrectomy showing complete dissolution of the Ozurdex implant and sealed macular hole.

cataract surgery and injection of intravitreal Ozurdex implant.

Interestingly, in our case, even after the disappearance of gas bubble following vitrectomy for macular hole, the Ozurdex implant remained firmly attached to the macula for 16 weeks till complete dissolution without any retinal toxicity or damage.

Previously, Esenulku and Gunay<sup>4</sup> reported no adverse outcomes following the direct contact of ozurdex implant with macula in silicone oil–filled eye.

### Conclusion

Macular hole formation after cataract surgery or intravitreal steroid implant is rare.<sup>2,3</sup> Ophthalmologists should keep in mind this rare possible complication and at the same time make patients aware of it. Patients should be reassured that the steroid implant that is for intravitreal use causes no toxicity or damage to the retina even if it is in contact with it for months and will dissolve on its own.

**Key words:** cystoid macular edema, intravitreal steroid implant, macular hole, Ozurdex, vitreomacular traction.

### References

1. Furino C, Boscia F, Niro A, et al. Combined phacoemulsification and intravitreal dexamethasone implant (Ozurdex®) in diabetic patients with coexisting cataract and diabetic macular edema. *J Ophthalmol* 2017;2017:4896036.
2. Bakri S, Omar A. Evolution of vitreomacular traction following the use of the dexamethasone intravitreal implant (Ozurdex) in the treatment of macular edema secondary to central retinal vein occlusion. *J Ocul Pharmacol Ther* 2012;28:547–549.
3. Patterson JA, Ezra E, Gregor ZJ. Acute full-thickness macular hole after uncomplicated phacoemulsification cataract surgery. *Am J Ophthalmol* 2001;131:799–800.
4. Esenulku CM, Gunay M. Location of a dexamethasone implant at the macula after intravitreal injection in a silicone oil-filled eye. *Case Rep Ophthalmol Med* 2016;2016:5107652.