

Small incision cataract surgery: Complications and mini-review

Parikshit M Gogate

This article reviews the literature on manual small incision cataract surgery (MSICS) and its complications. Various articles on MSICS published in indexed journals were reviewed, as well as the sections on complications of MSICS. The Pubmed search engine on the Internet was used to find out articles published since 1985 on MSICS in any language in indexed journals. Books published by Indian authors and the website of Indian Journal of Ophthalmology were also referred to. MSICS has become very popular technique of cataract surgery in India, and it is often used as an alternative to phacoemulsification. Studies on its efficacy and safety for cataract surgery show that, being a variant of extracapsular cataract surgery, MSICS also has similar intraoperative and postoperative complications. The considerable handling inside the anterior chamber during nucleus delivery increase the chances of iris injury, striate keratitis, and posterior capsular rupture. The surgeon has to be extra careful in the construction of the scleral tunnel and to achieve a good capsulorrhexis. Postoperative inflammation and corneal edema are rare if surgeons have the expertise and patience. The final astigmatism is less than that in the extracapsular cataract surgery and almost comparable to that in phacoemulsification. There is, however, a concern of posterior capsular opacification in the long term, which needs to be addressed. Although MSICS demands skill and patience from the cataract surgeon, it is a safe, effective, and economical alternative to competing techniques and can be the answer to tackle the large backlog of blindness due to cataract.

Key words: Cataract surgery, intraoperative and postoperative complications, manual small incision cataract surgery, phacoemulsification

Indian J Ophthalmol. 2009;57:45-9

Introduction

Manual small incision cataract surgery (MSICS) has become popular in India in the last decade. Cataract is the leading cause of avoidable blindness in India,^[1] and cataract surgery forms the major workload of most ophthalmic units in the country. An estimated 4 million people become blind because of cataract every year,^[2] which is added to a backlog of 10 million operable cataracts in India, whereas only 5 million cataract surgeries are performed annually in the country.^[3] Thus, a technique of cataract surgery that is not only safe and effective but also economical and easy for the majority of ophthalmologists to master is the need of the hour.

Conventional extracapsular cataract surgery (ECCE), MSICS, and phacoemulsification (phaco) are the three most popular forms of cataract surgery in India and rest of the world.^[4] Phaco is the technique of choice in the Western world and tertiary eye care centers in India.

A literature search was performed using the Pubmed (www.pubmed.gov) for articles on small incision cataract surgery published from 1985 onwards. The search was done for articles in all languages, although most results were in

English only. Additionally, books on MSICS by Indian authors, the *Indian Journal of Ophthalmology* website, the *British Journal of Ophthalmology* website, and the *Journal of Cataract and Refractive Surgery* websites were also used.

A randomized controlled trial in the United Kingdom had found phaco to be more effective than ECCE for the rehabilitation of cataract patients.^[5] Two randomized, controlled trials in Pune, India, had found MSICS to be more effective^[6] and economical⁷ than ECCE and almost as effective as^[8] and more economical than phacoemulsification.^[9] MSICS is also cost effective and prevents the expenses for the purchase and maintenance of the phaco machine.^[9] MSICS has similar advantages of phaco in the rehabilitation of the cataract blind. It is also easier for a surgeon trained in ECCE surgery to master MSICS than phacoemulsification. There is no dependence on the phaco machine, and the learning curve is less steep than that of phaco. Surgeons who have mastered MSICS also show a better learning curve for phaco, as the tunnel construction and capsulorrhexis are common to both. Thus, among small incision surgeries, MSICS is ideal for developing countries. It was propagated for high-quality, high-volume cataract surgery at the Aravind Eye Hospital, India,^[10,11] and in Nepal.^[12] An expert trial in Nepal comparing phaco with MSICS published this year, each done by a surgeon most proficient in that technique, gave similar results.^[13] The MSICS patients had less corneal edema on the first postoperative day and similar uncorrected visual acuity. The surgical time for MSICS was also much shorter. Some experts were skeptical about the Pune trials,^[6,8] as the same surgeons were randomized to both the techniques, and doubts were raised that they may not be equally proficient in the different techniques.^[14] The Nepal study had the results of

Departments of Pediatric Ophthalmology, Community Eye Care, H.V. Desai Eye Hospital, Mohommadwadi, Hadapsar, Pune-411 028, India

Correspondence to Departments of Pediatric Ophthalmology, Community Eye Care, H.V. Desai Eye Hospital, Mohommadwadi, Hadapsar, Pune-411 028, India. E-mail: parikshitgogate@hotmail.com

Manuscript received: 21.02.07; Revision accepted: 16.08.07

an accomplished phaco surgeon in the United States compared with an expert manual small incision surgeon in Nepal.^[13]

The MSICS techniques have the nucleus prolapsed into the anterior chamber as a common step. The nucleus may be rotated,^[15] tumbled (flipped so that the posterior surface faces the cornea and the anterior one is towards the iris) into the anterior chamber, or may be simple picked up by a bent cystitome, usually a 26-gauge needle. The nucleus may then be removed by any of the following techniques:

- Nucleus delivery using an irrigating vectis,^[6,8,10,11] or a curved cystitome—the fish hook^[12]
- Using two instruments to sandwich the nucleus between them^[4,16,17]
- Bisecting the nucleus into two using two instrument, one as the “cutter” and another, usually a vectis, as the board^[4,18,19]
- By using a snare similar to the tonsillar snare^[4]
- Dividing the nucleus into three parts (trisection) using a triangular instrument and a vectis^[20]
- Using an anterior chamber maintainer and a Sheet’s glide (the Blumenthal technique).^[4,21]
- Viscoexpression of nucleus.

Intraoperative complications

Because MSICS is also a type of ECCE surgery, the complications are similar, although there are certain unique ones. MSICS involves more maneuvers in the anterior chamber, first the capsulotomy, then dislodging the nucleus from the posterior to the anterior chamber, and finally removing the nucleus from the scleral tunnel. The surgeon has to enter again for cortical aspiration and intraocular lens implantation. The maneuvers have to be done manually, unlike phacoemulsification where it is done with the machine equipped with ultrasonic power and vacuum. As such the techniques are more demanding in terms of manual dexterity and skill. However, the maneuvering is similar to ECCE rather than phaco, and thus, MSICS is easier for an ECCE-trained surgeon to master. Excessive corneal handling, iris injury, posterior capsular rent, and zonulodialysis are also seen with MSICS. The principles of a good ECCE surgery, such as not to handle the cornea, to touch the iris rarely, and to preserve the posterior capsule, all hold good for MSICS (and phaco), as they are all variants of the conventional ECCE technique.

Improper construction of the scleral tunnel can lead to either button holing [Fig. 1], if the tunnel is too shallow, and premature entry, if the tunnel is too deep [Fig. 1]. There was a single incidence of scleral tunnel button holing amongst 168 cases in an MSICS series from Pune.^[22] This happens if the crescent knife is blunt or the surgeon has entered a superficial plane. A poorly constructed tunnel with premature entry causes trauma to the iris base and may result in iridodialysis and subsequent hemorrhage in the anterior chamber. The dialysis can be further extended during nucleus delivery. The premature entry into the anterior chamber makes the tunnel less self-sealing, and a box or cross suture may be required at the end. The continual iris prolapse during the surgery may predispose to superior iris injury and chaffing, and even iridodialysis in extreme cases. There would be a greater difficulty in nucleus delivery. To prevent premature entry, the crescent blade should extend the tunnel into the cornea beyond the blue line, and the

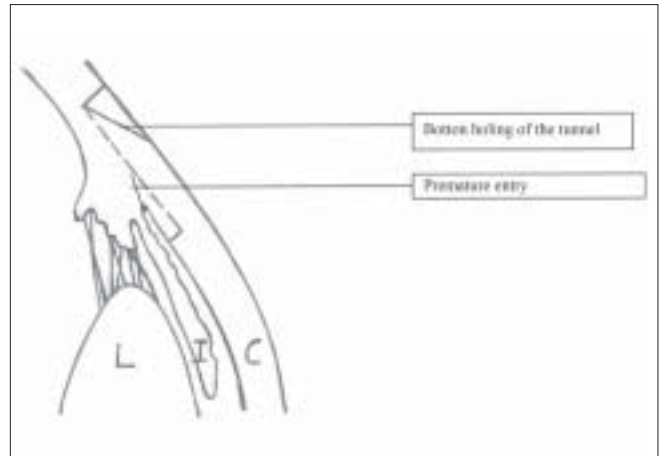


Figure 1: (A) Buttonholing of the tunnel (B) Premature entry

2.8- or 3.2-mm entry keratome should make the inner lip of the incision at the extreme anterior portion of the tunnel. As the MSICS tunnels are horizontally longer than those needed for phaco, the vertical width should be more than 2.5 mm. An unfortunate superior iridodialysis can be managed by suturing it into the posterior lip of the incision at the end of surgery.

Rotation or tumbling of the nucleus can put stress on zonules during its delivery into the anterior chamber especially through a small capsulotomy.^[4] It is also difficult to maneuver the nucleus through a small pupil and can result in sphincter damage. The surgeon must take extra care to fully dilate the pupil before surgery. The anterior chamber should be prevented from becoming shallow, as that would decrease the dilatation of the pupil.^[4,21]

If the capsulotomy is small (6 mm or less), at least two relaxing incisions should be placed on the superotemporal and superonasal part of the continuous curvilinear capsulorhexis (CCC) to facilitate nucleus delivery into the anterior chamber and for the subsequent 12 o’clock cortex aspiration. A can-opener capsulotomy can also be used but may have been responsible for an increased incidence of posterior capsular rents in the Pune study (12/200, 6% in MSICS group *vs* 7/200, 3.5% in the phaco group).^[8] Another series of MSICS had 2/168 posterior capsular rents,^[22] while another series of a 100 cases on white cataracts from South India did not have a single rent.^[23]

As prolapsing the nucleus into the anterior chamber is the key step in almost all the MSICS techniques, pupillary dilation during surgery is a key facilitator. Small pupils make the nucleus delivery difficult and increase the chances of manipulation of the iris and resultant iritis. Inability to prolapse the nucleus may lead to frustration, increased handling, sphincter tears, and even abandoning the technique. MSICS should be tried with caution in cases of iritis, rigid pupil, and pseudoexfoliation. Beginners are advised to exclude these cases for MSICS, and ECCE may be a safer alternative. Liberal use of viscoelastic and patience is recommended even for experts. Tumbling the nucleus into the anterior chamber is easier through a small pupil than rotation, but it puts more stress on the capsular rim and the zonules. Therefore, tumbling the nucleus should be avoided in incomplete capsulorhexis, weak zonules, and

pseudoexfoliation. In conditions of weak zonules like minimal subluxation, pseudoexfoliation, and hypermature cataracts, it is better to gently lift the nucleus into the anterior chamber with a bent cystitome rather than tumble or rotate it.^[12,15] Hypermature and black cataracts have capsules that are already stretched out and thin, with stress on the zonules. ECCE may be a safer alternative,^[4,24] although a study on phacolytic glaucoma has shown MSICS to be safe and effective.^[25] Pseudoexfoliation with its rigid small pupil and weak zonules offers a special situation. Trypan blue dye may be used to get a complete large capsulorrhexis and the nucleus gently rotated or lifted into the anterior chamber.^[23,25]

Another very rare complication that is unique to viscoexpulsion or phacosandwich technique of MSICS is inferior iridodialysis.^[10,16,23] In the irrigating vectis technique, if the irrigating vectis is inadvertently placed below the pupillary margin rather than between the margin and the nucleus, the inferior part of the pupillary sphincter gets caught between the vectis and the nucleus during nucleus delivery. This causes a tear at the 6 o'clock iris base [Fig. 2], which was seen in a single case (1%) in a series from South India.^[23] The resultant bleeding and the difficulty in suturing the large inferior iridodialysis can be frustrating.

A posterior capsular rent in MSICS does not cause a lot of vitreous loss like the ECCE, as the chamber is closed. However, aspiration of the epinucleus or sheets of cortex becomes difficult. In the event of capsular rent, dry aspiration can be done by a Simcoe canula if the rent is small, or by an automated vitrectomy cutter if it is larger.^[4,24] If the rent is small, the posterior chambers intraocular lens (PCIOL) can be implanted in the bag or on the anterior capsular flap for a large rent. If the PCIOL is not stable or the rent is too large, the only option is to perform a good vitrectomy and put in an anterior chamber intraocular lens implant (ACIOL). A peripheral button hole iridectomy must be done in all cases of the posterior capsular rupture. If there is a slightest doubt about the integrity of the tunnel, it is always wiser to suture. In case of doubt, it is better to suture and be safe, than hope to be lucky.

Striate keratitis is common during MSICS if enough care is not taken to place the viscoelastic between the nucleus and the cornea [Figs. 3 and 4]. The side-port is an excellent route to ensure this. Delivery is facilitated through a trapezoidal tunnel [Fig. 5]. Delivery of the nucleus through a small tunnel or rectangular tunnel can cause damage to the corneal endothelium [Fig. 6] and long-standing corneal edema, which is recalcitrant to treatment. The phacofracture,^[18,19] phacosandwich,^[16,17] and

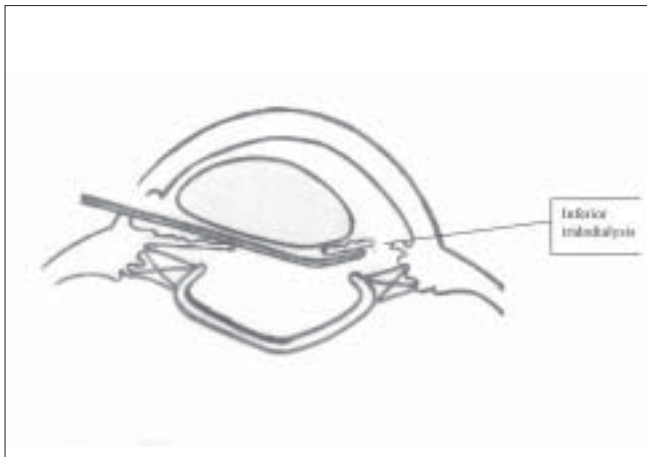


Figure 2: Inferior iridodialysis during nucleus extraction

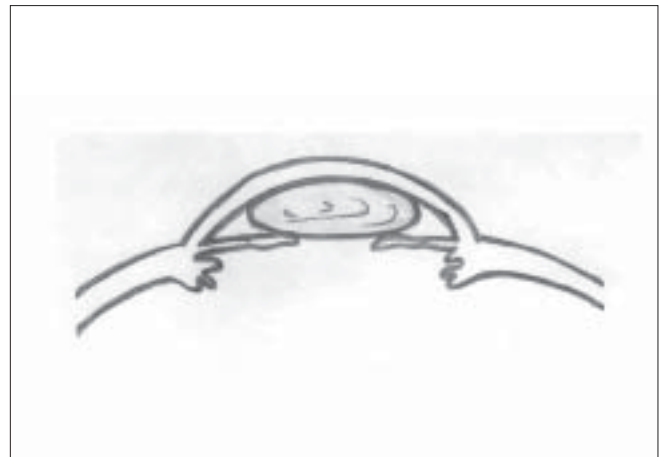


Figure 3: Nucleus touching the endothelium

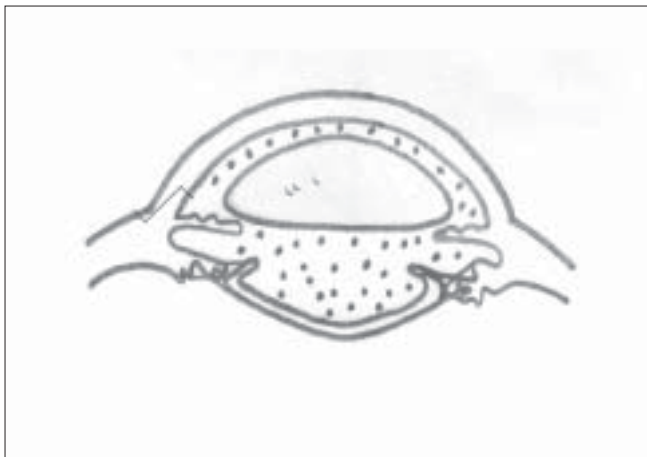


Figure 4: Nucleus surrounded by viscoelastic all around in the anterior chamber

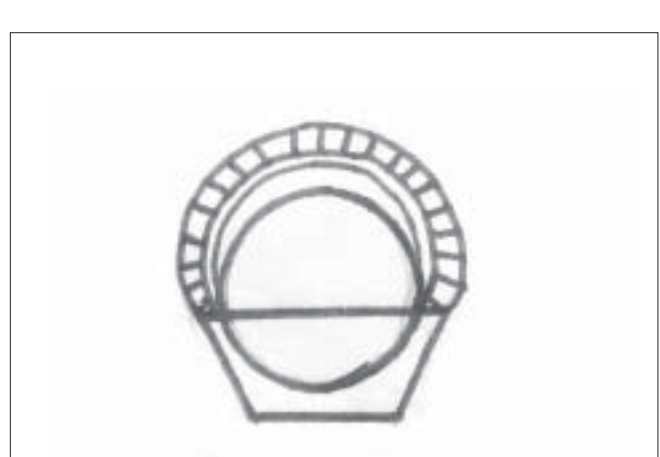

Figure 5: Trapezoid tunnel for better nucleus delivery

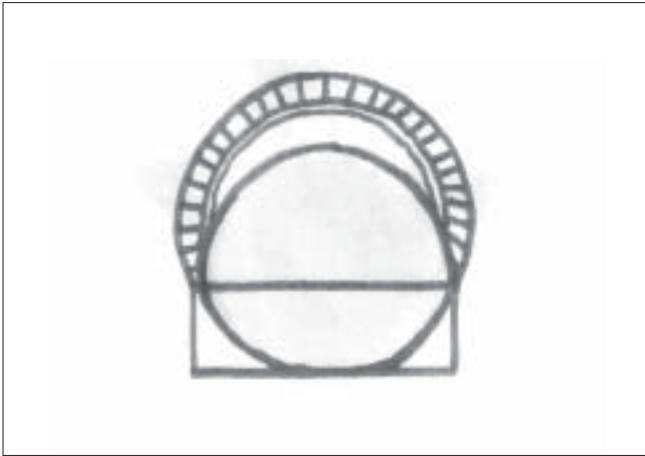


Figure 6: Nucleus gets caught in a rectangle tunnel

trisection^[20] techniques popularized in the 1990s did not gain wide acceptance, as they involved considerable manipulation into the anterior chamber with two instruments in addition to the nucleus. This made the technique very demanding on expertise and patience, and chances of corneal edema after surgery were very high in the learning phase. It was all the more difficult for very hard and white cataracts, which form the bulk of work in India.^[4,24] The two techniques were easier for softer cataracts, but paradoxically the softer cataract nucleus could be delivered out without such intense manipulations by viscoexpression alone.

Postoperative complications

If proper wound integrity was not maintained, shallowing of the anterior chamber will be seen during the first dressing. A cross suture or box suture during learning phase and for larger tunnels for hard nuclei would be helpful. Wound gape and iris prolapse in the scleral tunnel increase the chance of endophthalmitis and astigmatism. Postoperative corneal edema and potential corneal decompensation are common in poorly performed MSICS. The trial in Pune had nine (4.5%) cases of postoperative corneal edema on the first day in the phaco arm and four (2%) cases in the MSICS arm.^[8] A series of white cataracts had 65 eyes with corneal edema of >10 descemets folds and 7% with corneal edema of <10 descemets folds.^[23] In the Nepal study, both groups had an average increase in the central corneal thickness on the first day, but the MSICS group had less corneal edema ($P = 0.0039$).^[13] The edema had decreased to 29 and 4 mm in the phaco and MSICS group, respectively, on the fifth day, and by the third month, it had returned to baseline in both groups. Most studies of MSICS report a transient corneal edema, which clears off by the first week,^[8,17,19,20,24,26] but a series from Ghana had a single case (0.5%) of bullous keratopathy.^[26] A clinical audit of more than 8000 cataract surgeries done in Pune had found 12 cases of corneal decompensation, all of which were due to MSICS.^[27] However they were performed by surgeons in the learning phase of MSICS. MSICS should be done with caution in very old patients, those with very hard cataracts, and those with not so clear corneas.^[4,24,27]

The MSICS involves touching the iris at some point of time. This may lead to higher incidence of postoperative iritis and cystoid macular edema.^[13,23] Nevertheless, the studies so far have not shown any difference or increase in these

complications.^[8,9,25] The series from south India had mild iritis in 6% and moderate iritis in 3% in the first postoperative week.^[23] The large self-sealing tunnel may increase the chances of endophthalmitis, although further studies would be needed to support or refute the hypothesis. A study from Trichy, India, had demonstrated no significant anterior chamber contamination in MSICS.^[28]

A large systematic review of posterior capsular opacification (PCO) rates in 1998 had put it at 11.8% at one year and 28.4% at five years.^[29] Advances in surgical techniques and improvement in intraocular lens material and design have reduced the rates of PCO or, at least, have prolonged its onset.^[30] The slight superiority of phacoemulsification may be due to the lower incidence of PCO. In the Nepal study, 20/46 (43.5%) patients of MSICS had grade 1 PCO, and 8/46 (17.4%) had grade 2 PCO at the 6-month follow-up. For the phaco group, 7/48 (14.6%) had grade 1, and none had grade 2 PCO at the 6-month follow-up.^[13] The automated irrigation aspiration and the capsular polish mode in phaco may give it a small edge over MSICS. Also, the foldable lenses used in phaco had a square edge as compared with the polymethyl methacrylate (PMMA) lenses used in MSICS. A good cortex aspiration and polishing the capsule are necessary after MSICS. If a can-opener or V-shaped capsulorrhexis is used in MSICS rather than the CCC, there may be increased chances of PCIOL decentration later.

The average astigmatism was 0.7 diopter (D) in the phaco and 0.88 D in the MSICS ($P = 0.12$) in the Nepal study.^[13] The Pune study had the mode of astigmatism of 0.5 D for phaco and 1.5 D for MSICS, though the average was 1.1 and 1.2 D, respectively.^[8] Both the studies had used a foldable lens in the phaco arm, though diamond knife and silicone lenses were used in the Nepal study and stainless steel keratome blades and hydrophilic acrylic lenses in the Pune study. A prospective trial comparing 3.2-mm incisions with 5.5-mm incisions in Japan had found the difference in astigmatism of 0.3D.^[31] A study from Mumbai, India had found temporal and superotemporal tunnels to induce less astigmatism as compared with superior tunnels for MSICS.^[32] The mean astigmatism was 1.28 D at 2.9 degrees for superior incisions, 0.20 D at 23 degrees for superotemporal incisions, and 0.37 D at 90 degrees for temporal ones. The authors believed that temporal incisions were the farthest from the visual axis, and gravity and eyelid blink would create a drag on the superior incisions. They recommended duplicating the study with a larger sample size.

A study comparing endothelial cell loss and surgically induced astigmatism among ECCE, MSICS, and phaco had found the induced astigmatism slightly more in MSICS than phaco but much less than ECCE.^[33] There was no significant difference in the endothelial cell loss among the three techniques.^[33]

Conclusion

MSICS is a safe surgery.^[6,8,11-13,23,24] The surgeon has to be extra diligent in tunnel construction as the tunnel size is larger. An excellent self-sealing incision is vital for wound architecture on which the safety and lowered astigmatism potential rests. The incidence of posterior capsular rent and iridodialysis is low, and in case of such an eventuality, it is easier to manage the vitreous loss. In MSICS, the prolapse of nucleus into the anterior chamber and its delivery through the tunnel involve

manipulations very close to the iris and the cornea. The surgeon has to be extra careful with these structures, as postoperative inflammation and corneal edema can be all too common. More attention needs to be paid to cortical wash and capsular polishing, as PCO may be the only factor for suboptimal visual acuity in the future.

Acknowledgments

I am thankful to the editorial board of the *Indian Journal of Ophthalmology* for giving me the opportunity to write this article. Prof. Col. Madan Deshpande helped with his valuable inputs, and Dr. Roma Deshpande, Dr. Anita Bhargava and Dr. Prachi Amberdekar with the illustrations.

References

- Thylefors B, Negrel AD, Pararajasegaram R, Dadzie KY. Global data on blindness. *Bull World Health Organ* 1995;73:115-21.
- Minasian DC, Mehera V. 3.8 million blinded by cataract each year: Projections of the first epidemiological study of incidence of cataract blindness in India. *Br J Ophthalmol* 1990;74:341-3.
- Jose R. National programme for the control of blindness. *Indian J Comm Health* 1997;3:5-9.
- Basti S, Vasavada AR, Thomas R, Padmanabhan P. Extracapsular cataract extraction: Surgical techniques. *Indian J Ophthalmol* 1993;41:19-21.
- Minassian DC, Rosen P, Dart JK, Reidy A, Desai P, Sidhu M. Extracapsular cataract extraction compared with small incision surgery by phacoemulsification: A randomised trial. *Br J Ophthalmol* 2001;85:822-9.
- Gogate PM, Wormald RP, Deshpande M, Deshpande R, Kulkarni SR. Extracapsular cataract surgery compared with manual small incision cataract surgery in community eye care setting in Western India: A randomized controlled trial. *Br J Ophthalmol* 2003;87:673-9.
- Gogate PM, Wormald RP, Deshpande M. Is manual small incision cataract surgery affordable in the developing countries? A cost comparison with extracapsular cataract extraction. *Br J Ophthalmol* 2003;87:841-4.
- Gogate PM, Kulkarni SR, Krishnaiah S, Deshpande RD, Joshi SA, Palimkar A, *et al.* Safety and efficacy of phacoemulsification compared with manual small incision cataract surgery by a randomized controlled clinical trial: Six weeks results. *Ophthalmology* 2005;112:869-74.
- Gogate PM, Deshpande MD, Nirmalan P. Why do phacoemulsification? Manual small incision cataract surgery is almost as effective and more economical. *Ophthalmology* 2007;114:965-8.
- Venkatesh R, Muralikrishnan R, Balent LC, Prakash SK, Prajna V. Outcomes of high volume cataract surgeries in a developing country. *Br J Ophthalmol* 2005;89:1079-83.
- Natchiar G. Manual small incision cataract surgery: An alternative technique to instrumental phacoemulsification. Madurai: Aravind Publication; Dec 2000.
- Henning A, Kumar J, Yorston D, Foster A. Sutureless cataract surgery with nucleus extraction: Outcome of a prospective study in Nepal. *Br J Ophthalmol* 2003;87:266-70.
- Ruit S, Tabin G, Chang D, Bajracharya L, Kline DC, Richeimer R, *et al.* A prospective randomized clinical trial of phacoemulsification vs. manual sutureless small incision extracapsular cataract surgery in Nepal. *Am J Ophthalmol* 2007;143:32-8.
- Wormald RP. Phacoemulsification vs. small incision manual cataract surgery: An expert trial. *Am J Ophthalmol* 2007;143:143-4.
- Rao SK, Lam DS. A simple technique for nucleus extraction in capsular bag in manual small incision cataract surgery. *Indian J Ophthalmol* 2005;53:214-5.
- Fry LL. The phacosandwich technique. In: Rozakis GW, Anis AY, *et al.*, editors. *Cataract surgery: Alternative small incision techniques*. Thorofare, NJ: Slack Inc; 1990. p. 71-110.
- Bayramlar H, Cekic O, Totan Y. Manual tunnel incision extra capsular cataract extraction using the sandwich technique. *J Cataract Refract Surg* 1999;25:312-5.
- Kansas P. Phacofracture. In: Rozakis GW, Anis AY, *et al.*, editors. *Cataract surgery: Alternative small incision techniques*. Thorofare, NJ: Slack Inc.; 1990. p. 45-70.
- Duch Mestres F, Mathieu A, Torres F, Lillo J, Castilla M. Intra-operative complications of planned extra capsular cataract extraction versus manual nucleofragmentation. *J Cataract Refract Surg* 1996;22:1113-5.
- Hepsen IF, Cekic O, Bayramlar H, Totan Y. Small incision extracapsular cataract surgery with manual phaco trisection. *J Cataract Refract Surg* 2000;26:1048-51.
- Blumenthal M, Ashkenazi I, Fogel R, Assia EI. The gliding nucleus. *J Cataract Refract Surg* 1993;19:435-7.
- Maske A, Parker T, Gogate PM, Deshpande M, Adenwalla A, Verappa K. Comparison of subtenon anesthesia versus peribulbar block for manual small incision cataract surgery. *Indian J Ophthalmol* 2005;53:255-9.
- Venkatesh R, Das M, Prasanth S, Muralikrishnan R. Manual small incision cataract surgery in eyes with white cataracts. *Indian J Ophthalmol* 2005;53:173-6.
- Thomas R, Kuriakose T, George R. Towards achieving small incision cataract surgery 99.8% of the time. *Indian J Ophthalmol* 2000;48:145-51.
- Venkatesh R, Tan CS, Kumar TT, Ravindran RD. Safety and efficacy of manual small incision cataract surgery for phacolytic glaucoma. *Br J Ophthalmol* 2007;91:279-81.
- Guzek JP, Ching A. Manual small incision extracapsular cataract surgery in Ghana, West Africa. *J Cataract Refract Surg* 2003;29:57-64.
- Gogate PM, Deshpande M, Maske A, Jagdale SJ. Surgical audit at HV Desai Eye Hospital, Pune: Causes of poor post-operative visual outcome. *Community Eye Health* 2004;17:53-4.
- Parmar P, Salman A, Kaliaumurthy J, Prasanth DA, Thomas PA, Jesudasan CA. Anterior chamber contamination during phacoemulsification and manual small incision cataract surgery. *Am J Ophthalmol* 2006;141:1160-1.
- Shaumberg DA, Dana MR, Christen WG, Glynn RJ. A systemic overview of the incidence of posterior capsular opacification. *Ophthalmology* 1998;105:1213-21.
- Wilson E M, Trivedi RH. The ongoing battle against posterior capsular opacification. *Arch Ophthalmol* 2007;125:555-6.
- Oshika T, Nagahara K, Yaguchi S, Emi K, Takenaka H, Tsuboi S, *et al.* Three year prospective randomized evaluation of intraocular lens implantation through 3.2 and 5.5 mm incisions. *J Cataract Refract Surg* 1998;24:509-14.
- Gokhale NS, Sawhney S. Reduction in astigmatism in manual MSICS through change in astigmatism site. *Indian J Ophthalmol* 2005;53:201-3.
- George R, Rapauliha P, Sripriya AV, Rajesh PS, Vahan PV, Praveen S. Comparison of endothelial cell loss and surgically induced astigmatism following conventional extracapsular cataract surgery, manual small incision surgery and phacoemulsification. *Ophthalm Epidemiol* 2005;12:293-7.

Source of Support: Nil, Conflict of Interest: None declared.