

# Management of Oral Myiasis Caused by *Chrysomya bezziana* - A Case Series

Ramakrishna Sheno, Vrinda Kolte, Pranav Ingole, Jignesh Rajguru, Jui Karmarkar, Sunil Kolte<sup>1</sup>, Kunal Patankar<sup>2</sup>

Department of Oral and Maxillofacial Surgery, VSPM Dental College and Research Centre, <sup>1</sup>Department of Parasitology, Nagpur Veterinary College, <sup>2</sup>Department of Medicine, NKPSIMS and LMH, Nagpur, Maharashtra, India

## Abstract

Myiasis is a rare disease caused by infestation of tissue by larvae of flies. Oral myiasis is still rare and unique owing to the fact that the oral cavity rarely provides a necessary habitat for a larval life cycle. We discuss the definition, etiology, predisposing factors, classification, and management of myiasis. We hereby report a rare case of oral myiasis in a 75-year-old female with a history of maxillofacial trauma. She complained of pain in the lower lip and commissure region on the left side through which numerous live maggots (larvae) were seen crawling out. Postremoval of approximate seventy maggots resulted in lower lip defect along its commissure which was repaired by Bernard's modification of Gillies flap. Another case was an 18-year-old girl, a known case of congenital cerebral palsy with pain and swelling in the upper vestibule region. Prevention of myiasis involves addressing open wounds, maintaining good oral and personal hygiene, control of fly population, basic cleanliness of surrounding areas, and provision for basic sanitation and health education.

**Keywords:** *Chrysomya bezziana*, maggots, myiasis, oil of turpentine

## INTRODUCTION

Myiasis is derived from a Latin word "muia" which means fly and "iasis" which means disease<sup>[1]</sup> and a term derived from the Greek word "myia," meaning invasion of fly larvae into vital tissue of humans or other mammals. They can infest vertebrate animals including humans and feed on living or dead tissue as well as on body fluids.<sup>[2]</sup> The term was coined by F. W. Hope in 1840.<sup>[3]</sup>

The dipterous larvae that feed on the host living or dead tissues, liquid body substances, or ingested food causes myiasis. Oral myiasis is a rare pathology and is associated with poor oral hygiene, alcoholism, senility, and suppurating lesions and is well documented in maxillofacial trauma.

In humans, the most common sites of myiasis are the nose, eye, ear, vagina, skin, nasopharynx, and rarely, the oral cavity. The oral cavity does not provide the habitat conducive for life cycle of these larvae. Hence, incidence of oral myiasis is comparatively lesser than that of cutaneous myiasis.<sup>[4]</sup>

The predominant portions of the lower third of the face which serve an important esthetic unit of the face are lips.<sup>[5]</sup> They

serve as the focal point for communication and expression and maintain the competence of the oral cavity preventing the drooling of saliva and further predisposing to other infections such as candidiasis. The biggest challenge faced by the surgeon is reconstruction of large defects of the lower lip with good functional and esthetic outcomes.

## CASE REPORTS

### Case report 1

An 18-year-old girl, a known case of congenital cerebral palsy, reported to the department of oral and maxillofacial surgery with complaints of pain and swelling in the upper front region of the jaw for 1 week. Intra-oral examination revealed a diffuse erythematous cavitation that was tender on palpation

**Address for correspondence:** Dr. Jignesh Rajguru,  
Department of Oral and Maxillofacial Surgery, VSPM Dental College and  
Research Centre, Nagpur, Maharashtra, India.  
E-mail: jignesh.rajguru19@gmail.com

**Received:** 15-05-2020

**Revised:** 25-06-2020

**Accepted:** 03-08-2020

**Published:** 23-12-2020

This is an open access journal, and articles are distributed under the terms of the Creative Commons Attribution-NonCommercial-ShareAlike 4.0 License, which allows others to remix, tweak, and build upon the work non-commercially, as long as appropriate credit is given and the new creations are licensed under the identical terms.

**For reprints contact:** WKHLRPMedknow\_reprints@wolterskluwer.com

**How to cite this article:** Sheno R, Kolte V, Ingole P, Rajguru J, Karmarkar J, Kolte S, *et al.* Management of oral myiasis caused by *Chrysomya bezziana* - A case series. *Ann Maxillofac Surg* 2020;10:521-4.

### Access this article online

#### Quick Response Code:



**Website:**  
www.amsjournal.com

**DOI:**  
10.4103/ams.ams\_177\_20

with worm-like organisms moving out of the defect in the upper labial vestibule. Larvae recovered from the wound were preserved in formaldehyde (40%) and sent to an entomologist for identification.

### Case report 2

A 75-year-old female patient reported to the emergency room of Lata Mangeshkar Hospital, Nagpur, with chief complaints of pain and swelling in the lower lip and discomfort in the left cheek region for 5 days. The patient gave an alleged history of fall at home 5 days back. Since then, she had an open wound involving the lower lip and left commissural region. The patient reported to a government hospital 2 days back where approximately thirty maggots were removed. The patient was carrying relevant documents stating the same.

On extraoral examination, a diffuse swelling of approximately 4 cm × 3 cm in size involving the lower lip was noted. The examination also revealed incompetence involving the left corner of the mouth with overlying skin tense and shiny with multiple fenestrations [Figure 1]. The swelling was soft and edematous in consistency and tender to palpation with no suppuration. Intraoral examination revealed complete upper and lower edentulous arches.

Several cavitations with deep burrows were noted. Multiple larvae were noted crawling within the lower lip and left cheek region. Ultrasonography (USG) of the lower lip and left cheek region was advised. On USG, multiple linear tubular echogenic moving structures were noted in a subcutaneous plane in the left cheek and lower lip. In view of history of the removal of maggots, the above features are likely suggestive of multiple maggots in the present scan [Figure 2].

Cotton gauze impregnated with oil of turpentine was placed in the deeply burrowed cavitation in the lower lip and left cheek region for approximately 10–12 min. Around 15 Maggots were removed manually with the help of curved artery forceps and were collected in a sample bottle as shown in Figure 3. The same procedure was

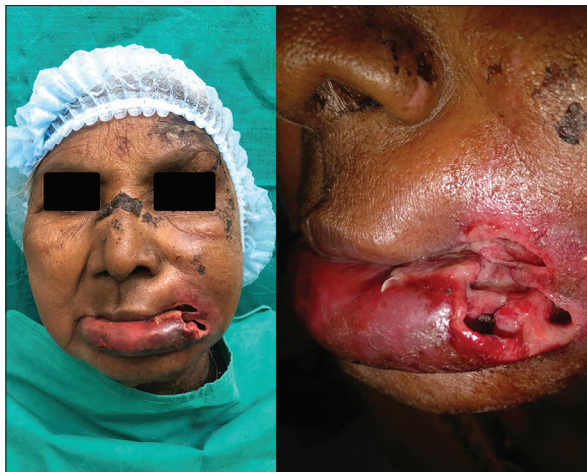carried out for the next 3–4 consecutive days with exploration, curettage and irrigation with warm saline, hydrogen peroxide, povidone-iodine and metronidazole till no further larvae could be found. A total of 73 maggots were removed in a span of 3–4 days. The patient was administered injection ceftriaxone, injection pantoprazole, and injection metronidazole for 5 days. No attempt of administering the antiparasitic drug ivermectin was made.

On the 7<sup>th</sup> postoperative day, there was no evidence of maggots on repeat USG. A magnetic resonance imaging of the oral cavity (plain + contrast) was suggestive of minimally enhancing mucosal thickening along the gingivobuccal and gingivolabial sulcus on the left side likely of inflammatory etiology postoperative changes. However, the clinical examination confirmed a serious loss of the lip tissue with necrosed margins. Competence involving left commissure was lost and constant drooling of saliva was visible [Figure 4a].

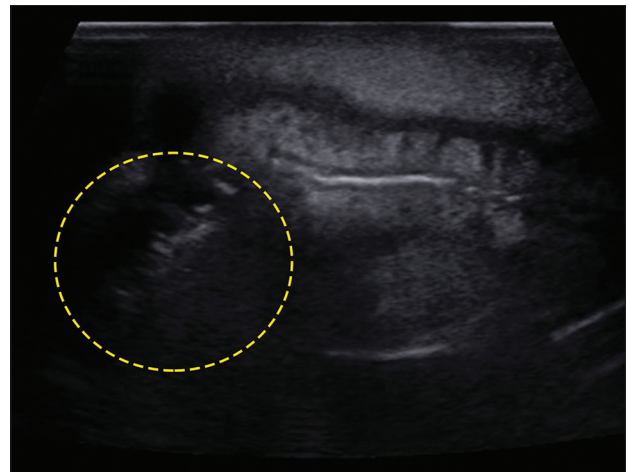
The defect was reconstructed with Bernard’s modification of Gillies flap. The flap consists of an incision along the perioral area around nasolabial fold [Figure 4b and c]. The flap viability was maintained by preserving the vascular bundle. After accomplishing sufficient mobilization, the flaps were medially oriented to allow closure in three planes, namely oral mucosa, orbicularis muscle and skin maintaining the integrity of oral sphincter. However, there is some microstomia with minimal impact on function [Figure 4d].

Diagnosis of myiasis causing larvae was done based on the form of spiracles, cephalon-pharyngeal skeleton, shape and size of developed larvae as shown in Figure 5. The posterior spiracles, a distinct button, and the number of lobes on the anterior spiracles are six, which would give a definitive identification of *Chrysomya bezziana*. The robust spine bands are other indicative criteria of *C. bezziana*.

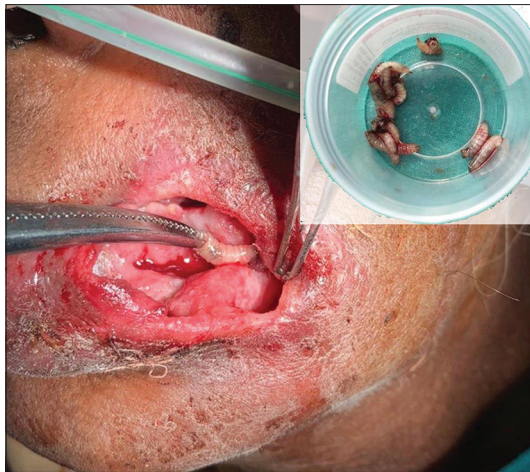
Based on the mentioned diagnostic keys and comparing the whole shape of the larvae, posterior spiracles and cephalopharyngeal skeleton, the larvae were diagnosed as *C. bezziana* (Diptera: Calliphoridae).



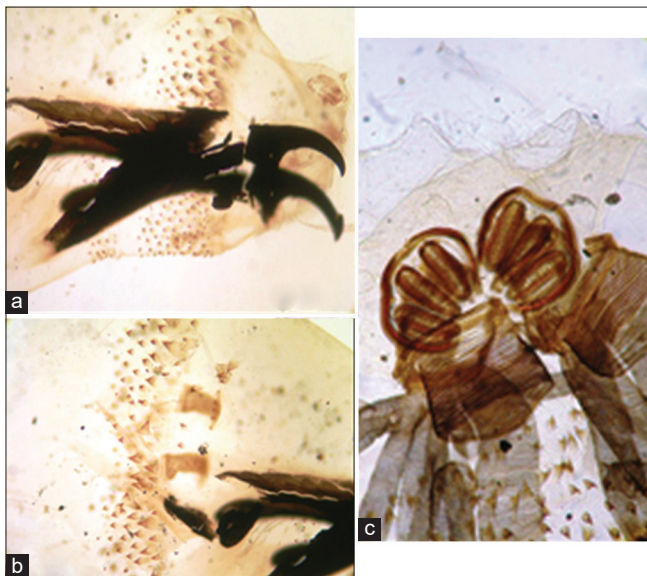
**Figure 1:** Multiple abrasions over the face with swollen lower lip and numerous cavitations



**Figure 2:** Suggestive of multiple linear tubular echogenic structures (circled)



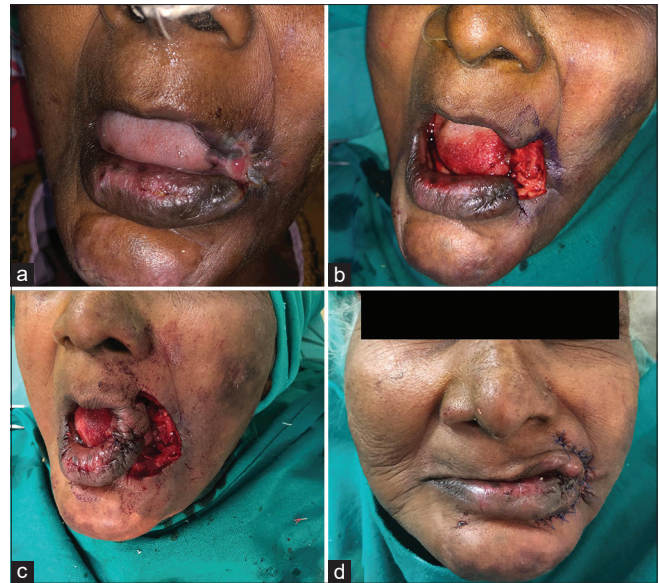**Figure 3:** Manual removal of maggots with the help of hemostat and collecting in sample bottle



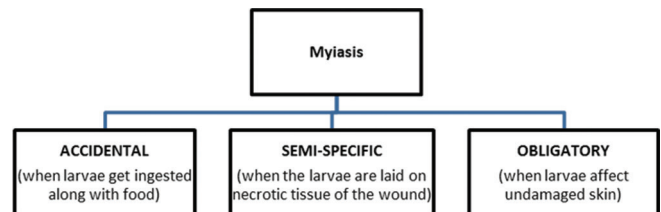
**Figure 5:** Photomicrograph suggestive of the parasite: (a) Anterior cephalopharyngeal skeletal end, (b) anterior spiracle, (c) posterior spiracle of *Chrysomya bezziana*

## DISCUSSION

Myiasis defined by Zumpt as “the infestation of live human and vertebrate animals with dipterous larvae which at least for a certain period feed on the host’s dead or living tissue, liquid body substance, or ingested food.”<sup>[6]</sup> According to the documented cases in literature, myiasis occurs more in rural than urban areas. The predisposing factors could be Diabetes mellitus, leprosy, psychiatric illness with impaired manual dexterity, poor oral hygiene, open wounds due to maxillofacial trauma or patients who are senile, mouth breathers or hemiplegic.<sup>[7]</sup> In the abovementioned case, the patient belonged to a low socioeconomic status residing in a rural area and a history of trauma to the face due to fall which was not addressed are thought to be as the predisposing and contributing factors to myiasis.



**Figure 4:** Reconstruction of the defect with Bernard’s modification of Gillies flap: (a) Necrosed margins surrounding the defect, (b and c) after removal of necrosed margins and fibrosis, the upper lip was rotated in a medial direction, (d) lip commissure anatomy was restored



**Illustration 1:** Classification of myiasis

Myiasis can be classified as following as primary when larvae feed on living tissue and secondary when larvae feed on dead tissues.

Myiasis is also classified as shown in Illustration 1.<sup>[8]</sup>

The treatment modality for myiasis comprises local and systemic measures. Local measures consist of topical application of oil of turpentine, mineral oil, ether, chloroform, ethyl chloride, mercuric chloride, creosote, saline, phenol, calomel, olive oil, iodoform, or other such comparable solvents as advocated in the literature.<sup>[9]</sup> These local measures irritate the maggots causing larval asphyxia and force them out of the deeply burrowed cavitations. Topical application of placentrex aids in granulation.<sup>[10]</sup> Systemic treatment includes broad-spectrum antibiotics. In the present patient, debridement with oil of turpentine along with copious irrigation with normal saline, povidone-iodine, hydrogen peroxide, and metronidazole followed by mechanical removal of maggots and injectable antibiotic coverage was used for the treatment.

## CONCLUSION

Oral myiasis is an uncommon entity. The clinician should be aware of this disease and should take appropriate measures for

its prevention. Prevention of myiasis involves addressing open wounds, maintaining good oral and personal hygiene, control of fly population, basic cleanliness of surrounding areas and provision for basic sanitation and health education. An intimate care needs to be taken in patients who lack manual dexterity in maintaining oral hygiene.

#### **Declaration of patient consent**

The authors certify that they have obtained all appropriate patient consent forms. In the form, the patients have given their consent for images and other clinical information to be reported in the journal. The patients understand that their names and initials will not be published and due efforts will be made to conceal identity but anonymity cannot be guaranteed.

#### **Financial support and sponsorship**

Nil.

#### **Conflicts of interest**

There are no conflicts of interest.

## **REFERENCES**

1. Ali FM, Patil K, Kar S, Patil AA, Ahamed S. Oral myiasis affecting gingiva in a child patient: An uncommon case report. *Case Rep Dent* 2016;2016:2197450.
2. Huang YL, Liu L, Liang H, He J, Chen J, Liang QW, *et al.* Orbital myiasis: A case report and literature review. *Medicine (Baltimore)* 2020;99:e18879.
3. Sharma MK, Yadav SK, Kumar R, Jain S. Furuncular myiasis in a 6-year-old boy. *Indian J Paediatric Dermatol* 2018;19:167.
4. Rossi-Schneider T, Cherubini K, Yurgel LS, Salum F, Figueiredo MA. Oral myiasis: A case report. *J Oral Sci* 2007;49:85-8.
5. deAzevedo DM, Nagasaki E. Lower lip reconstruction using the Karapandzic technique. *Rev Bras Cir Plást* 2013;28:168-71.
6. Saravanan T, Mohan MA, Thinakaran M, Ahammed S. Oral myiasis. *Indian J Palliat Care* 2015;21:92-4.
7. Poon TS. Oral myiasis in Hong Kong: A case report. *Hong Kong Pract* 2006;28:388-93.
8. Candamourty R, Venkatachalam S, Yuvaraj V, Sujee C. Oral myiasis in an adult associated with filariasis and Hansen's disease. *J Nat Sci Bio Med* 2013;4:259-262.
9. Sunny B, Sulthana L, James A, Sivakumar T. Maggot infestation: Various treatment modalities. *J Am Coll Clin Wound Spec* 2016;8:51-3.
10. Shukla AD, Kamath AT, Kudva A, Pai D, Patel N. Our experience in the management of traumatic wound myiasis: Report of 3 cases and review of the literature. *Case Rep Dent* 2016;2016:7030925.