

[Orthopaedic Surgery]

Medial Impingement of the Ankle in Athletes

Arthur Manoli II, MD^{†‡§}

Context: Medial impingement syndrome of the ankle is common in the athletic population. A marginal osteophyte on the leading edge of the medial talar facet and a corresponding “kissing” osteophyte on the tibia, in front of the medial malleolus, may abut and cause pain and limited dorsiflexion.

Background: Palpation of the talar osteophyte and standard imaging—especially, the oblique view of the foot—are useful in making the diagnosis. Surgical removal of the osteophyte may be necessary.

Conclusions: Ankle impingement is commonly seen in running and jumping sports, especially if the athlete has a subtle cavus foot. It may be associated with ankle instability, osteochondritis dissecans of the talus, and stress fractures of the foot.

Keywords: ankle; impingement; sports injuries; talus; medial malleolus

Impingement syndromes of the ankle have been of major interest since Don O’Donoghue described anterior tibiotalar impingement spurs in 1957.⁹ He said, “This same type of condition may develop in other areas about the ankle, particularly in front of the medial malleolus or lateral malleolus, and in rare instances it has also developed posteriorly.” The paucity of work mentioning the other spurs may be a result of their more difficult diagnosis in comparison to that of anterior spurs, which are easily seen on standard lateral radiographs of the ankle. Spurs resulting in “footballer’s ankle” have drawn the most attention, and numerous articles have been written describing their removal.^{4,6,8-12,15,16}

PATHOANATOMY OF MEDIAL IMPINGEMENT

Young female athletes—particularly, gymnasts—have drawn attention to the relatively common medial impingement syndrome.^{1,19} In addition to gymnastics, the syndrome is seen in basketball, soccer, football, and track distance running. It can also be seen after nonsporting injuries—especially,

fractures—about the ankle and foot. There appears to be an association with a subtle cavus foot and ankle instability⁶ (Figure 1).

Medial impingement syndrome develops with spur formation along the most anterior portion of the medial talar facet and a corresponding “kissing” osteophyte just anterior to the corner of the medial ankle mortise and the front of the medial malleolus. The 2 spurs abut during ankle dorsiflexion (Figure 2).

The talar osteophyte is usually a deposition of new bone at the leading edge of the medial talar facet. This spur may cause pain along the superior portion of the anterior tibiotalar fascicle of the deltoid ligament.⁷ The talar osteophyte can generally be palpated clinically, and oftentimes, the patient can identify it as a source of pain (Figure 3). A clicking sensation may be palpable. An oblique radiograph of the foot will usually reveal the talar and medial tibial spurs^{14-16,18} (Figure 1C and 1D; see also figures in Associated Lesions section).

Ankle stress radiographs can help diagnose associated ankle instability. A computed tomography scan can be useful to rule

From [†]Michigan International Foot and Ankle Center, Pontiac, Michigan, [‡]Orthopaedic Surgery, Wayne State University, Detroit, Michigan, and [§]Michigan State University, East Lansing, Michigan

Address correspondence to Arthur Manoli II, MD, Michigan International Foot and Ankle Center, St Joseph Mercy Hospital—Oakland, 44555 Woodward Avenue, Suite 503, Pontiac, MI 48341 (e-mail: arthurmanoli@hotmail.com).

No potential conflict of interest declared.

DOI:10.1177/1941738110384570

© 2010 The Author(s)

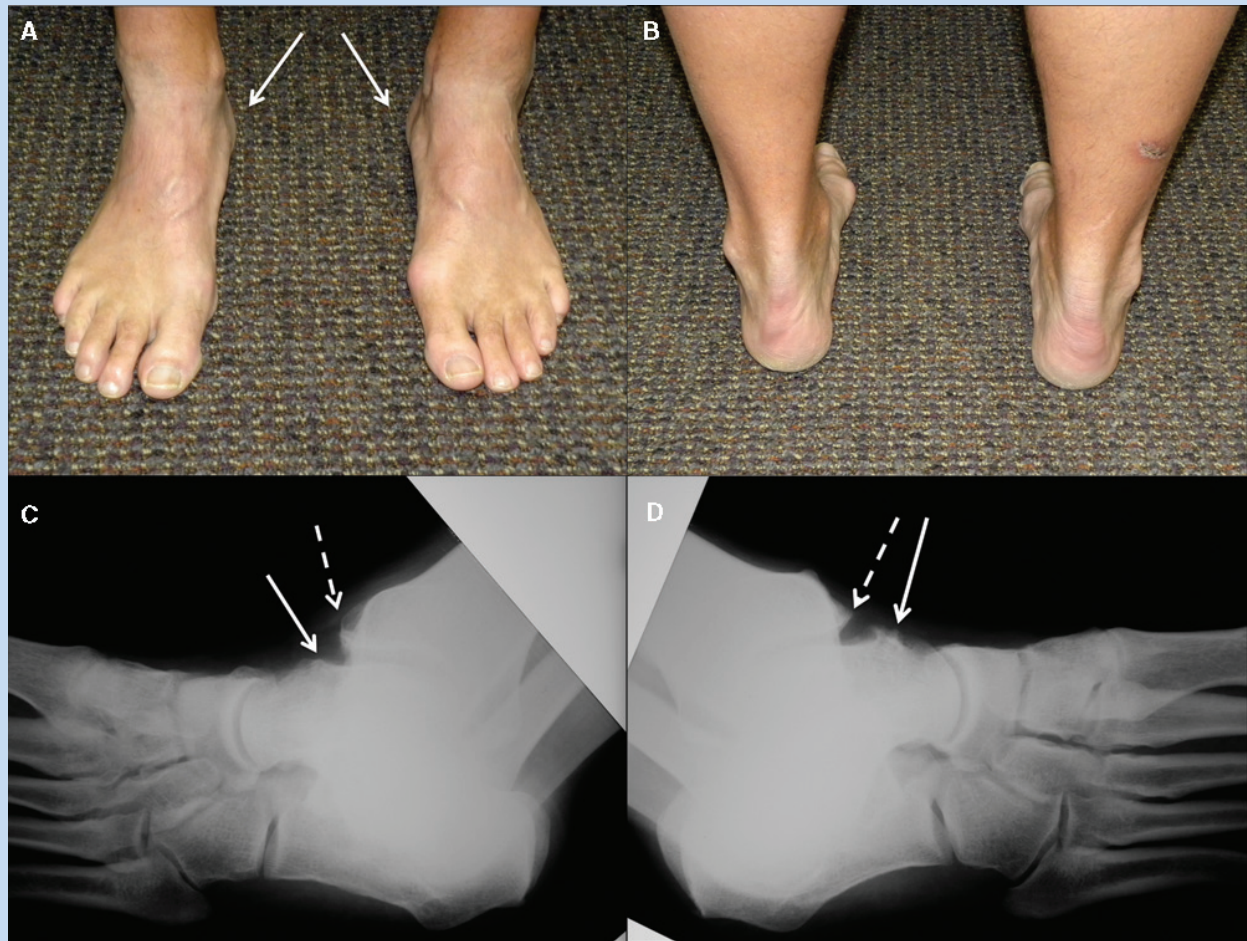

Figure 1. A, middle-aged distance runner with moderate subtle cavus feet—note the peek-a-boo heels bilaterally (arrows); B, rear view showing typical heel varus bilaterally; C, oblique radiograph of the left foot—note the talar and tibial impingement spurs (solid arrow and broken arrow, respectively); D, oblique radiograph of the right foot—note the medial impingement spurs on the talus and tibia (solid arrow and broken arrow, respectively).

out other joint pathology, such as an osteochondritis dissecans (OCD) lesion, especially medially (M. Ghalambor, J. Anhalt, M. M. Chilvers, A. Manoli II, unpublished data, 2006). Standing radiographs of the ankle can identify significant medial joint arthritis, which frequently accompanies medial impingement syndrome.³ With asymmetric ankle loading from the subtle cavus foot, medial degeneration may follow along with spur formation.⁵ In fact, many medial spurs are a manifestation of early degenerative joint disease of the medial ankle above a subtle cavus foot, hastened by instability and repeated injury (Figure 1).^{2,3,5,12,13,17}

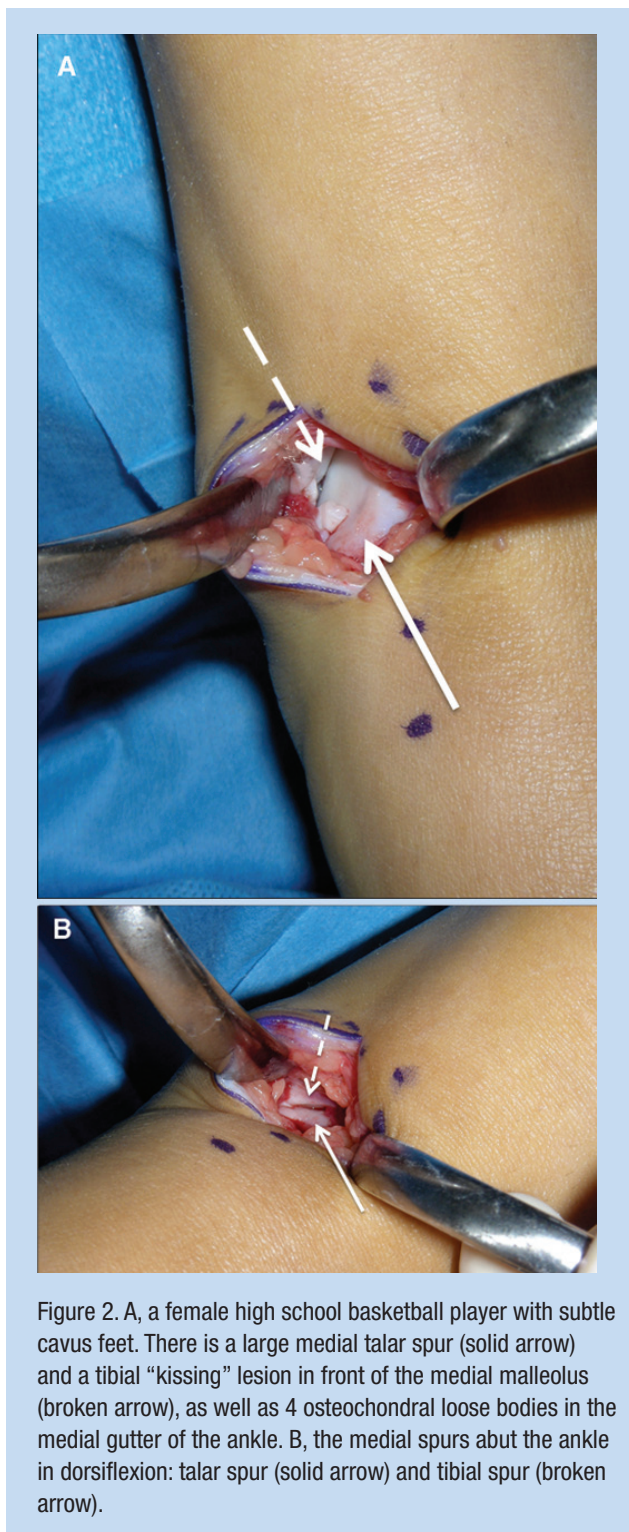
TREATMENT

Nonoperative treatment includes ankle bracing if instability is present. The subtle cavus foot may be treated with a

foot orthotic: plantarflexed first ray recessed below the plane of the lateral rays and the arch kept lower than that of the patient.⁵ Intensive exercise programs may worsen symptoms.

If the medial impingement lesion is sufficiently symptomatic, open or arthroscopic surgery may be indicated.^{7,15,16}

This lesion can be approached through a longitudinal medial incision over the medial gutter of the ankle joint. The talar lesion may present as a marginal osteophyte or a “sharp edge” of the most distal edge of the medial facet, varying in size, from small to very large in chronic phases. A deposition of immature bone may be present (grey to reddish in color), covering the leading edge of the facet (Figures 2 and 4). A pedunculated lesion may also occur at the edge or just distal to the facet (Figure 5).



When the ankle is dorsiflexed, the talar lesion will usually abut against the tibial lesion, which is an accumulation of new bone at the anterior portion of the medial malleolus-tibial

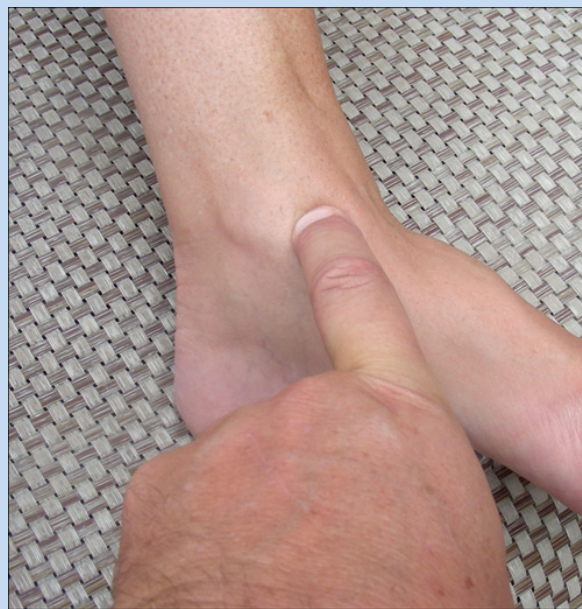

Figure 3. The medial talar spur is palpable on the medial ankle.

plafond junction.^{14-16,18} The osteophyte does not arise from the edge of the mortise corner but lies just anterior to the edge, hanging downward like an awning over the corner of the mortise (Figures 6 and 7). Care must be taken to recognize and remove this lesion.

Both the talar and tibial lesions are generally removed with small osteotomes, rongeurs, and files. When the talar spur is being removed, care should be taken not to notch the neck of the talus, to avoid creating a stress riser and a resultant pathologic fracture. The entire leading edge of the medial facet of the talus should be visualized because the osteophyte may extend inferiorly and cause synovitis between the spur and the deltoid ligament (Figure 7). Frequently, there are loose bodies in the gutter that must be removed^{13,17} (Figure 2A).

A bulky compression dressing is used to minimize swelling and ankle effusion. Motion and weightbearing are gradually begun when the wound is healed. Jumping activities are not advised for 6 to 8 weeks, if there was significant bone removal and exposed cancellous bone.

RESULTS

Results of the surgery are generally good.^{1,19} Very young athletes who continue to participate in jumping sports may require repeat spur removal.

ASSOCIATED LESIONS

Medial spurs may be associated with OCD, especially of the medial talar body. OCD lesions treated with drilling without

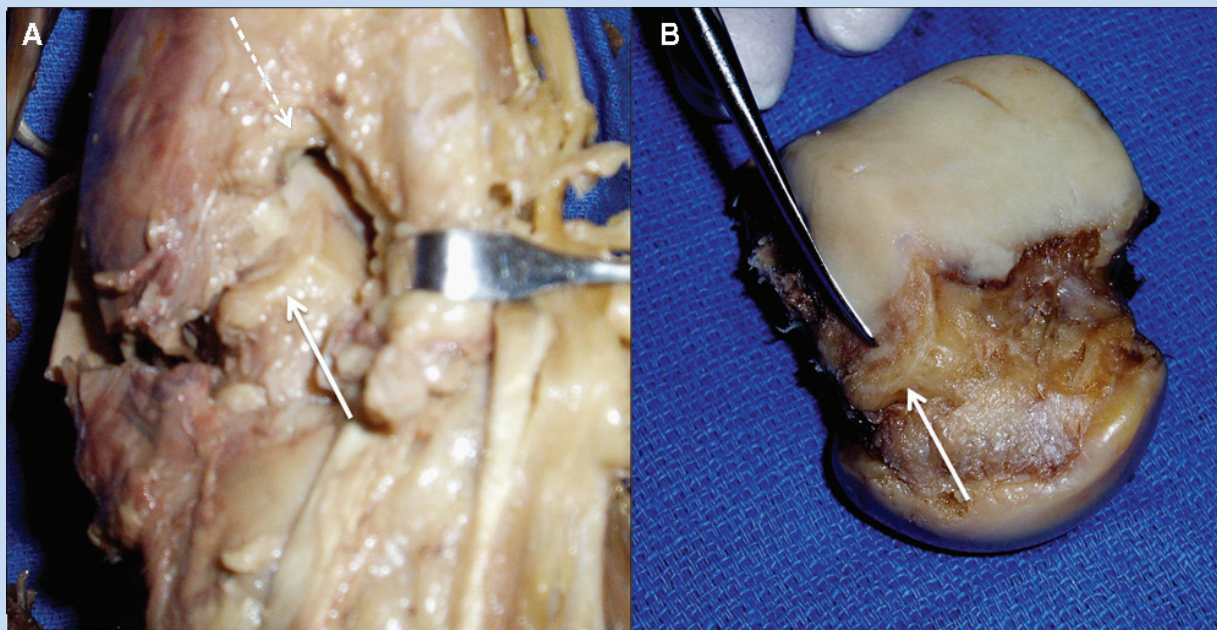


Figure 4. A, medial impingement spurs on the distal tibia and medial facet of the talus—talar spur (solid arrow) and tibial spur (broken arrow); B, a talar spur at the leading edge of the medial facet of the talus (solid arrow).

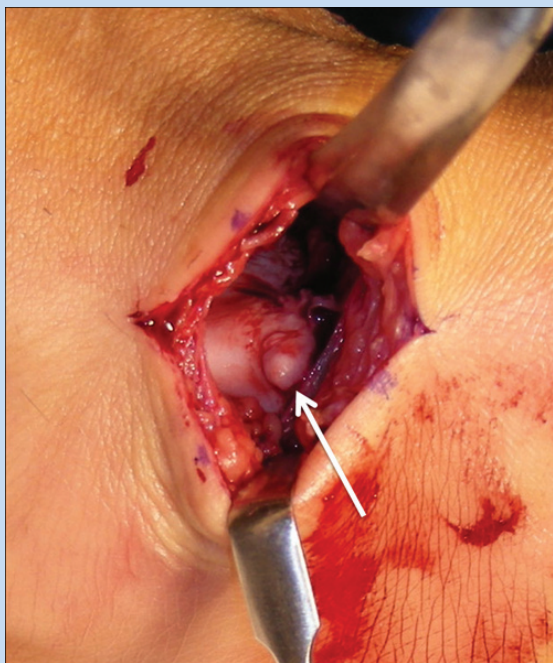


Figure 5. A pedunculated lesion in a teenage female gymnast (solid arrow).

pain relief may be an indicator of this problem. Removal of the impingement spurs may lead to pain relief (M. Ghalambor et al, unpublished data, 2006). A thorough search for medial impingement spurs should be made when treating OCD lesions of the talus; spurs should be removed at the time of the OCD surgery (Figure 8).

Medial impingement syndrome may be associated with or actually caused by a subtle cavus foot and/or lateral ankle instability. Treatment of these abnormalities should be considered at the time of spur removal. Dorsiflexion osteotomies of the first metatarsal, occasionally with a lateralizing calcaneal osteotomy, and a concurrent tightening of the lateral ankle ligaments may be indicated. A female gymnast may require concurrent medial spur removal, tightening of the lateral ankle ligaments, open reduction of a navicular stress fracture, and release of the flexor hallucis longus tendon behind the ankle (Figure 9).

Stress fractures of the foot in athletes tend to occur in patients with subtle cavus.⁵ Fractures of the fifth metatarsal and the tarsal navicular have been associated with medial impingement (Figures 10 and 11). It is possible that the medial impingement may limit ankle dorsiflexion with a resultant increase in bone forces contributing to the fracture.

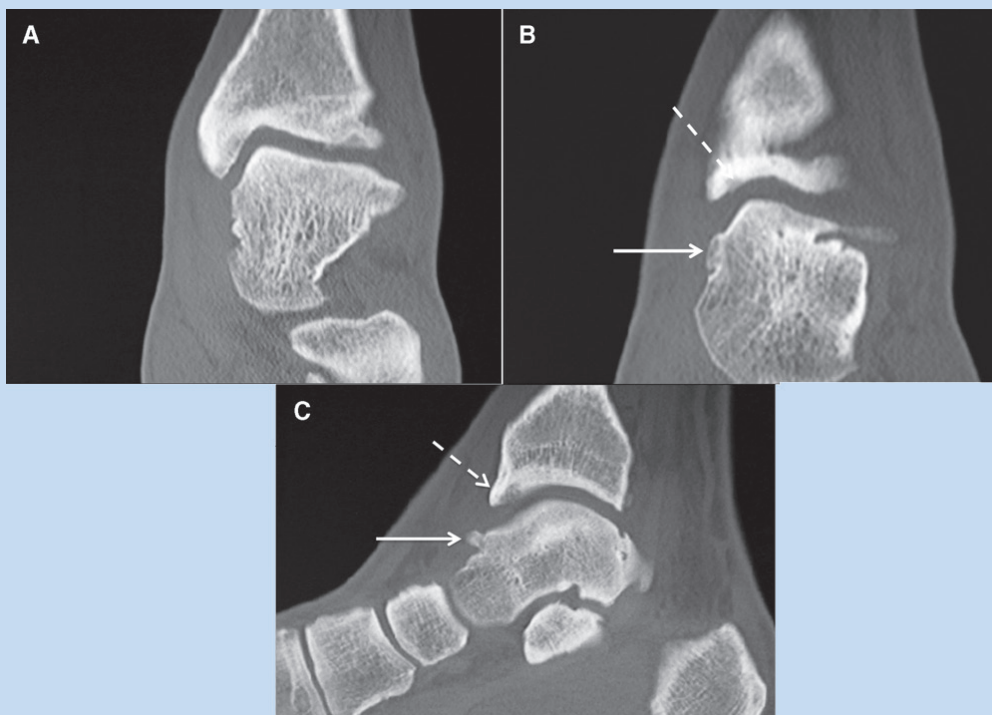


Figure 6. A, semicoronal computed tomography section through the anterior ankle joint in a male basketball player. The medial ankle mortise contour is normal in this section. B, computed tomography section anterior to the section in A, through the tibial impingement spur (broken arrow). The spur changes the apparent contour of the ankle joint medially compared to A. A portion of the talar spur is also seen (solid arrow). C, sagittal computed tomography reconstruction of the patient in A and B. The “kissing” tibial spur (broken arrow) actually extends and hangs downward, like an awning, in front of the normal anterior tibial contour. A talar spur is also seen (solid arrow).

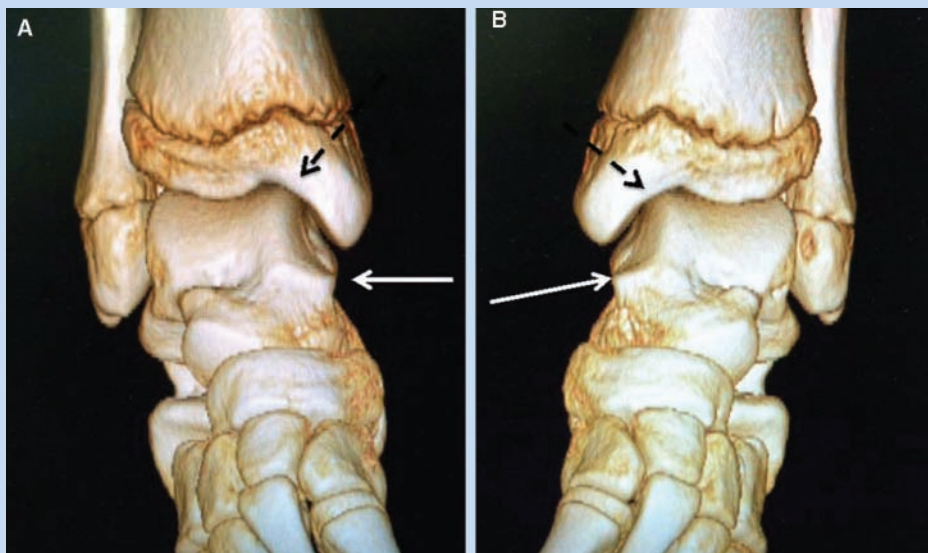


Figure 7. A, 3-dimensional reconstructive CT scan of medial impingement osteophytes in a male teenage soccer player. The prominent spur on the leading edge of the medial talar facet (solid arrow) and the “kissing” lesion spur on the tibial side (broken arrow) covers the corner of the medial ankle joint. B, left ankle computed tomography of the patient in A with similar findings. Inferiorly, the talar spurs extend on both sides. At surgery, they must be removed in their entirety.

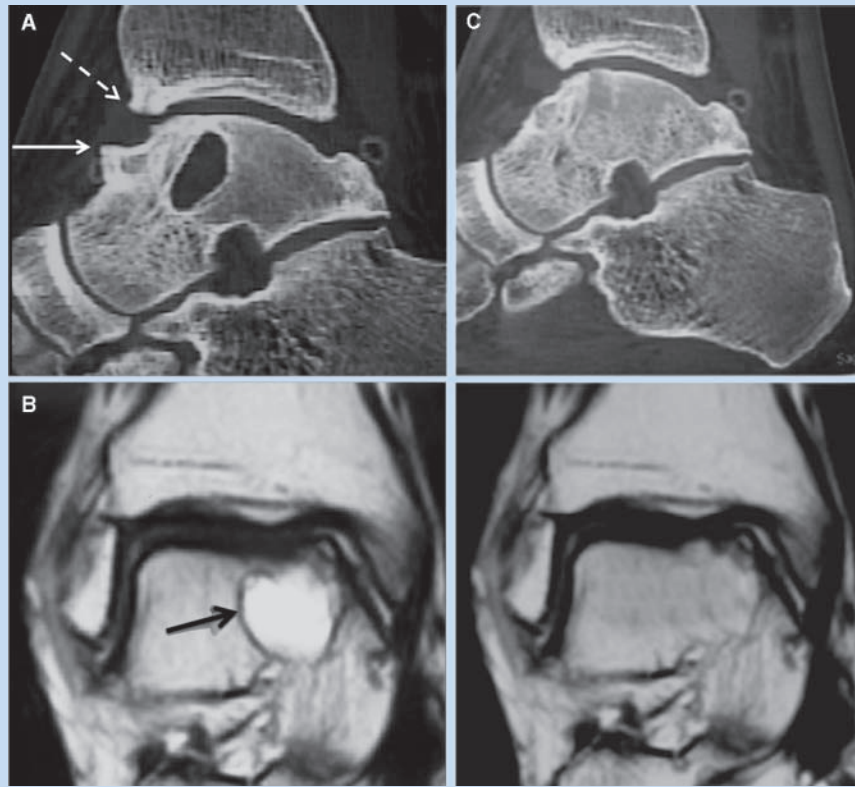


Figure 8. A, sagittal computed tomography image of a young man with a large cystic osteochondritis dissecans of the medial talus and large medial impingement spurs: talar spur (solid arrow) and tibial spur (broken arrow). B, semicoronal computed tomography image of the large medial osteochondritis dissecans lesion (arrow). C, the cyst was bone grafted, and the large impingement spurs were removed with uneventful healing. (Images courtesy of Mark S. Myerson, MD)

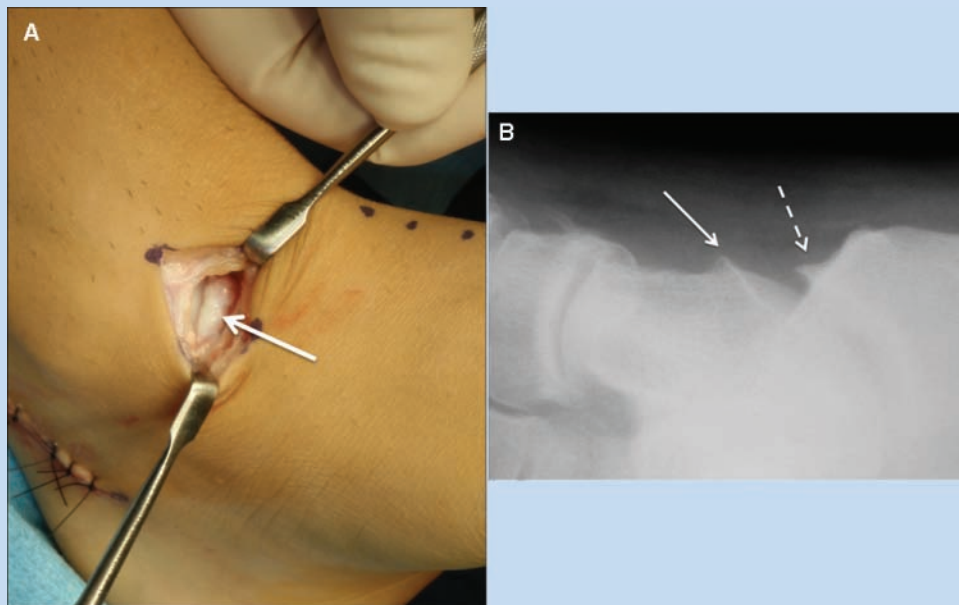


Figure 9. A, large spur along the leading edge of the medial talar facet in a teenage female gymnast (solid arrow). She also had a flexor hallucis longus tendon release and open reduction internal fixation of a navicular stress fracture. B, oblique radiograph of the foot in patient in panel A. Large talar (solid arrow) and tibial (broken arrow) spurs medially.

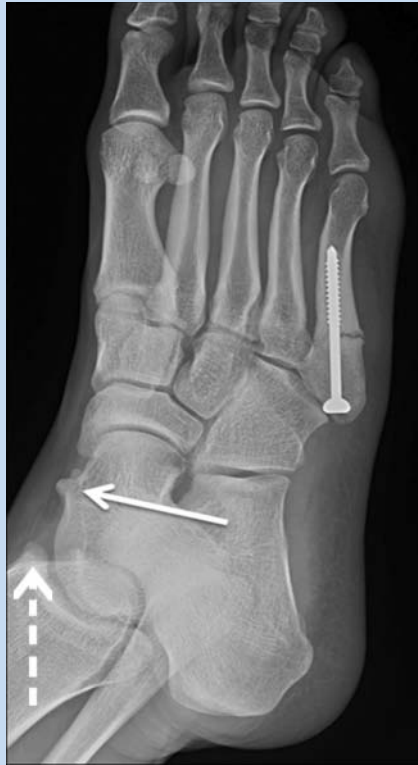

Figure 10. Male basketball player with a stress fracture of the fifth metatarsal and subtle cavus feet. Medial impingement spurs on both the talus (solid arrow) and the tibia (broken arrow).

REFERENCES

1. Chilvers M, Donahue M, Nassar L, Manoli A II. Foot and ankle injuries in elite female gymnasts. *Foot Ankle Int.* 2007;28(2):214-218.
2. Chilvers M, Manoli A II. The subtle cavus foot and association with ankle instability and lateral foot overload. *Foot Ankle Clin.* 2008;13(2):315-324.
3. Fortin PT, Guettler J, Manoli A II. Idiopathic cavovarus and lateral ankle instability: recognition and treatment implications relating to ankle arthritis. *Foot Ankle Int.* 2002;23(11):1031-1037.
4. Hawkins RB. Arthroscopic treatment of sports-related anterior osteophytes in the ankle. *Foot Ankle.* 1988;9(2):87-90.
5. Manoli A II, Graham B. The subtle cavus foot: "the underpronator." *Foot Ankle Int.* 2005;26(3):256-263.
6. McMurray TP. Footballer's ankle. *J Bone Joint Surg Br.* 1950;32(1):68-69.
7. Mosier-La Clair SM, Monroe MT, Manoli A II. Medial impingement syndrome of the anterior tibiotalar fascicle of the deltoid ligament on the talus. *Foot Ankle Int.* 2000;21(5):385-391.
8. Nihal A, Rose DJ, Trepman E. Arthroscopic treatment of anterior ankle impingement syndrome in dancers. *Foot Ankle Int.* 2005;26(11):908-912.
9. O'Donoghue DH. Impingement exostoses of the talus and the tibia. *J Bone Joint Surg Br.* 1957;39A:835-852.
10. Parkes JC, Hamilton WG, Patterson AH, Rawles JG. The anterior impingement syndrome of the ankle. *J Trauma.* 1980;20(10):895-897.
11. Scanton PE Jr, McDermott JE. Anterior tibiotalar spurs: a comparison of open versus arthroscopic debridement. *Foot Ankle.* 1992;13(3):125-129.
12. Scanton PE Jr, McDermott JE, Rogers JV. The relationship between chronic ankle instability and variations in mortise anatomy and impingement spurs. *Foot Ankle Int.* 2000;21(8):657-664.
13. Taga I, Shino K, Inoue M, Nakata K, Maeda A. Articular cartilage lesions in ankles with lateral ligament injury. *Am J Sport Med.* 1993;21(1):120-127.
14. Tol JL, Verhagen RA, Krips R, et al. The anterior ankle impingement syndrome: diagnostic value of oblique radiographs. *Foot Ankle Int.* 2004;25(2):63-68.

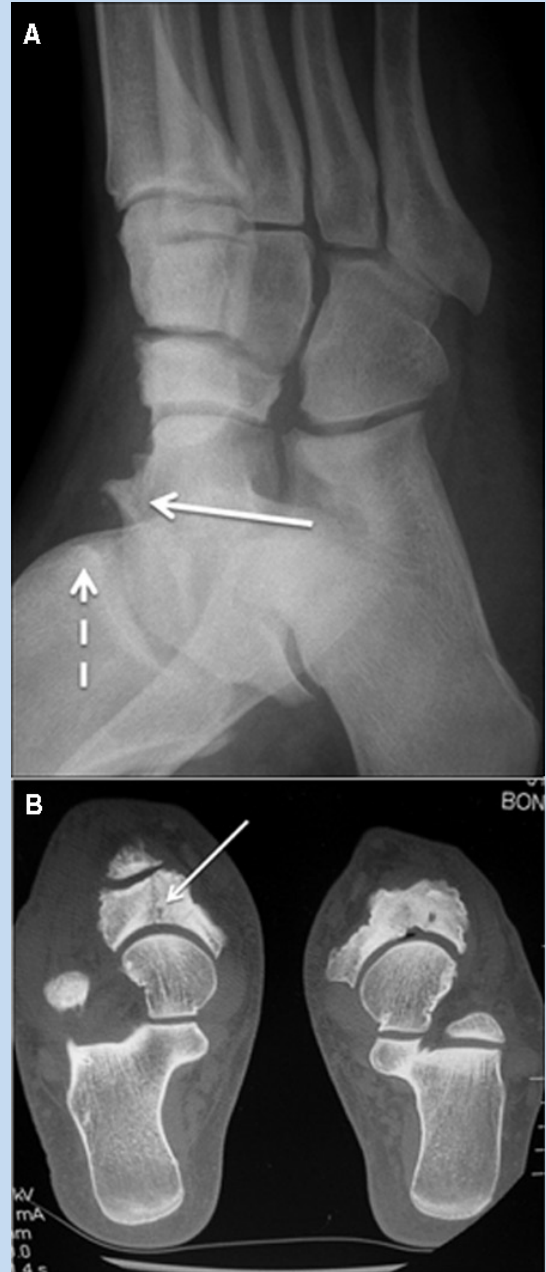


Figure 11. A, a football lineman with a stress fracture of the tarsal navicular and medial impingement symptoms at the ankle—talar spur (solid arrow) and tibial spur (broken arrow); B, axial computed tomography scan of a stress fracture of the right tarsal navicular (solid arrow). The left talonavicular joint has degenerative changes.

15. Tol JL, van Dijk CN. Anterior ankle impingement. *Foot Ankle Clin.* 2006;11(2):297-310.
16. Tol JL, van Dijk CN. Etiology of the anterior ankle impingement syndrome: a descriptive anatomical study. *Foot Ankle Int.* 2004;25(6):382-386.
17. Van Dijk CN, Bossuyt PM, Marti RK. Medial ankle pain after lateral ligament rupture. *J Bone Joint Surg Br.* 1996;78(4):562-567.
18. Van Dijk CN, Wessel RN, Tol JL, Maas M. Oblique radiograph for the detection of bone spurs in anterior ankle impingement. *Skeletal Radiol.* 2002;31(4):214-221.
19. Vann MA 2nd, Manoli A II. Medial ankle impingement in female gymnasts. *Oper Tech Sports Med.* 2010;18(1):50-52.

For reprints and permissions queries, please visit SAGE's Web site at <http://www.sagepub.com/journalsPermissions.nav>.