

Endovascular treatment of thrombosed inferior vena cava filters: Techniques and short-term outcomes

Mohammad Arabi, Venkataramu Krishnamurthy, Wojciech Cwikiel, Ranjith Vellody, Thomas W Wakefield¹, John Rectenwald¹, David Williams

Departments of Radiology, and ¹Vascular Surgery, University of Michigan Health System, Ann Arbor, Michigan, USA

Correspondence: Dr. Mohammad Arabi, Department of Radiology, UH B2-A209, 1500 East Medical Center Drive, Ann Arbor, Michigan - 48109-5030, USA. E-mail: marabi2004@hotmail.com

Abstract

Purpose: To present the techniques for endovascular treatment of thrombosed filter-bearing inferior vena cavae (IVCs), along with short-term clinical and imaging follow-up. **Materials and Methods:** A total of 45 consecutive patients (17 females and 28 males), aged 19-79 years (mean age of 49 years), who had IVC filter placement complicated by symptomatic acute or chronic ilio caval thrombosis and underwent endovascular therapy were studied. All patients presented with lower extremity swelling and/or pain. One patient also had bilateral lower extremity swelling and chronic gastrointestinal (GI) bleeding which was secondary to chronic systemic to portal venous collaterals. Patients underwent one or more of the following endovascular treatments depending on the chronicity and extent of thrombosis: (a) catheter-directed thrombolysis (CDT) ($n = 25$), (b) pharmacomechanical thrombolysis (PMT) ($n = 15$), (c) balloon angioplasty ($n = 45$), and/or (d) stent placement across the filter ($n = 42$). In addition, 16 patients underwent groin arteriovenous fistula (AVF) creation (36%) and 3 (7%) had femoral venous thrombectomy to improve flow in the recanalized iliac veins and IVCs. **Results:** Anatomical success was achieved in all patients. Follow-up was not available in 10 patients (lost to follow-up, $n = 4$; expired due to comorbidities, $n = 2$; lost to follow-up after re-intervention, $n = 4$). At a mean follow-up time of 13.3 months (range 1-48 months), clinical success was achieved in 27 patients (60%), i.e. in 21 patients without re-intervention and in 6 patients with re-intervention. Clinical success was not achieved despite re-intervention in eight patients. Higher clinical success was noted in patients who did not require repeat interventions ($P = 0.03$) and the time to re-intervention was significantly shorter in patients who had clinical failure ($P = 0.01$). AVF creation did not improve the clinical success rate ($P = 1$). There was no significant difference in clinical success between patients who had acute or subacute thrombosis compared to those who had chronically occluded filter-bearing IVCs ($P = 1$). **Conclusion:** This study suggests that endovascular therapy for thrombosed filter-bearing IVCs is safe and technically feasible.

Key words: Inferior vena cavae filter; recanalization; thrombosis

Introduction

The growing number of implanted inferior vena cava (IVC) filters since their introduction in the late 1960s has resulted

in an increasing frequency of long-term filter-related complications such as local thrombosis and increased risk of recurrent lower extremity deep vein thrombosis (DVT).^[1-6] Despite the introduction of retrievable filters to reduce the rate of long-term complications, the number of retrieved filters has not increased in a parallel fashion.^[1,7] The incidence of DVT and IVC thrombosis after filter placement varies widely (6-37%) among various filter types and in different populations of patients.^[8,9] Previous recommendations and guidelines discuss endovascular treatment options in *de novo* DVT in non-filter-bearing IVC and iliofemoral thrombosis. There is a paucity of literature describing the safety and outcome of endovascular treatment for filter-bearing IVC

Access this article online

Quick Response Code:



Website:
www.ijri.org

DOI:
10.4103/0971-3026.161436

thrombosis.^[10-12] The present retrospective study aims to assess our institutional experience with endovascular techniques in this subset of patients.

Materials and Methods

The institutional review board approved this retrospective study, and informed consent was waived. The medical records and imaging data of 45 consecutive patients between 2003 and 2010 were reviewed. This included patients who had IVC filter placement complicated by symptomatic acute or chronic ilio caval thrombosis and underwent endovascular therapy.

Patient population

A total of 45 consecutive patients (17 females and 28 males), with a mean age of 49 years (range 19-79 years) [Table 1], were retrospectively evaluated. All patients presented with lower extremity swelling and/or pain. One patient also had bilateral lower extremity swelling and chronic gastrointestinal (GI) bleeding which was secondary to chronic systemic to portal venous collaterals. Indications for IVC filter placement were either contraindication to or failure of anticoagulation.

Based on the length of the presenting symptoms, the patients were categorized into four groups: Acute ($n = 22$), subacute ($n = 1$), acute-on-chronic ($n = 3$), and chronic ($n = 19$). This categorization was based on the definitions suggested by the quality improvement guidelines for the treatment of lower extremity DVT,^[13] where acute DVT refers to venous thrombosis with symptoms or imaging findings

in ≤ 14 days, subacute DVT in 15-28 days; chronic DVT in more than 28 days, and acute-on-chronic DVT refers to venous thrombosis that has both chronic and acute components.

The group of patients with permanent filters consisted of Greenfield ($n = 3$) (Greenfield; Boston Scientific, Natick, MA, USA), Trapease ($n = 6$) (Trapease; Cordis Corporation, Miami, FL, USA), Simon-Nitinol ($n = 9$) (Simon-Nitinol; Bard Peripheral Vascular, Inc, Arizona, USA), Venatech ($n = 1$) (Venatech; BRAUN, Bethlehem, Pennsylvania, USA), and Mobin-Uddin ($n = 1$) filters. The retrievable group included Celect® ($n = 5$) (Celect; Cook Medical, Bloomington, IN, USA), Gunther-Tulip ($n = 10$) (Cook), OptEase ($n = 6$) (Cordis Corporation), G2 ($n = 3$) (Bard), and G2X ($n = 1$) (Bard) filters. Four of the thrombosed filters were in the suprarenal location, while the remaining filters were in infrarenal position. Only one optional filter was removed. The remaining optional filters were left in place due to the existing extensive thrombosis. The interval between filter placement and presentation varied significantly between patients from 3 days to 3 years.

Treatment methods

The treatment methods are presented in Figures 1-4.

The primary goal of endovascular treatment was to achieve anatomical and clinical success. Anatomical success was defined as either restoration of in-line flow with venous patency or removal of 50% or more of the thrombus burden, while clinical success was defined as the presence of anatomical success and improvement in presenting symptoms.^[13] Patients underwent one or more of the following endovascular treatments depending on the chronicity and extent of thrombosis: (a) Catheter-directed thrombolysis (CDT) ($n = 25$), (b) pharmacomechanical thrombolysis (PMT) ($n = 15$), (c) balloon angioplasty ($n = 45$), and/or (d) stent placement across the filter ($n = 42$). In addition, 16 patients underwent groin arteriovenous fistula (AVF) creation (36%) and 3 (7%) had femoral venous thrombectomy to improve flow in the recanalized iliac veins and IVCs.

CDT, mechanical thrombectomy, PMT

All patients (100%) with acute components of caval and iliofemoral thrombosis were treated with CDT with recombinant-tissue plasmin activator (r-TPA) and Retavase® (EKR therapeutics, NJ, USA) according to the protocols suggested by the quality improvement guidelines.^[13] However, four patients in our series with chronic thrombosis were also initially treated with CDT. The duration of CDT ranged between 24 and 72 h, depending on the extent of thrombosis, chronicity of changes, and response to treatment. PMT techniques were used as an adjunct to accelerate clearance of acute excessive clot burden either before initiation of CDT or if the response to the infused thrombolytic agents was limited. The

Table 1: Patients demographics

Demographics	N=45 (%)
Gender	
Female	17 (38)
Male	28 (62)
Average age (years), mean \pm SD	49 \pm 14
Symptoms duration	
Acute	22 (49)
Subacute	1 (2)
Acute-on-chronic	3 (7)
Chronic	19 (42)
Recanalization method	
Catheter-directed thrombolysis	25 (56)
Pharmacomechanical thrombolysis	15 (33)
Balloon angioplasty	45 (100)
Stent placement across the filter	42 (93)
Clinical success	27 (60)
Re-intervention	17 (38)
Average time to re-intervention (months), mean \pm SD	6.05 \pm 6.4
Average follow-up time with no re-intervention (months), mean \pm SD	13.08 \pm 12.2

SD: Standard deviation

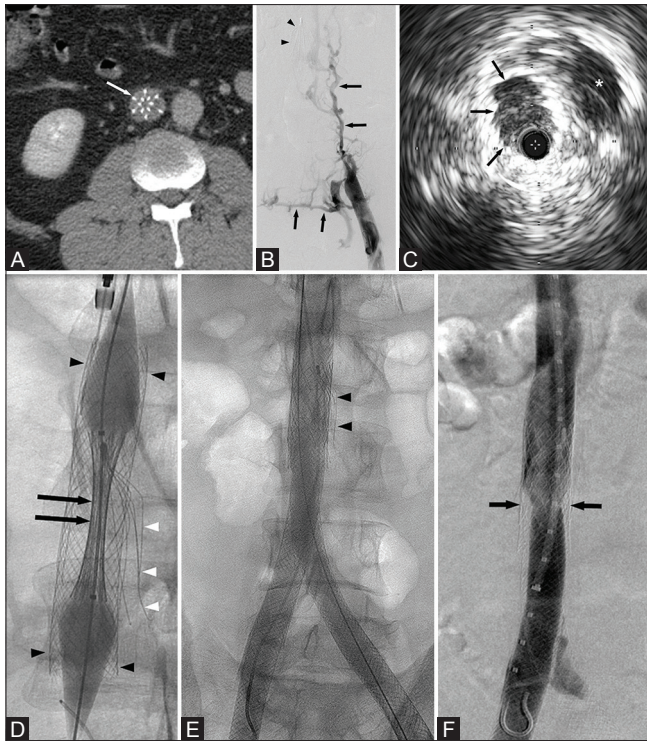


Figure 1 (A-F): (A) Axial contrast-enhanced CT image shows thrombosis of the G2 filter-bearing infrarenal IVC (B) Ascending venogram through left common femoral vein access demonstrates thrombosis of the IVC below the G2 filter (arrowheads) with extensive ascending lumbar and pelvic collaterals (arrows) (C) Intravascular US image reveals narrowing of the IVC with intraluminal thrombosis (arrows) (D) Digital radiograph obtained during deployment of the Palmaz stent (black arrows) at the level of the G2 filter (white arrowheads) to support the previously deployed Wallstents (black arrowheads) (E) Completion venogram shows widely patent IVC and iliac veins. The G2 filter (arrowheads) was displaced laterally. (F) Eighteen month follow-up venogram shows circumferential narrowing of the IVC at the level of the filter (arrows)

devices used included AngioJetPossis (AngioJetPossis; MEDRAD Interventional, Indianola, PA, USA) ($n = 9$), Trellis® system (Trellis; Bacchus Vascular Inc, Santa Clara, CA, USA) ($n = 4$), and EKOS® EndoWave™ (EKOS; EKOS Corporation, Bothell, WA, USA) ($n = 2$).

Patients received standard anticoagulation prior to the procedure according to our institutional practice (heparin normogram) seeking therapeutic levels. During the CDT, anticoagulation was continued with heparin drip at a rate of 250-500 units per hour. Post procedure, patients were bridged to Coumadin using low-molecular-weight heparin.

Balloon angioplasty and balloon clot maceration

High-pressure balloons were used to macerate the clots and displace the existing filters. It was observed that 2 of the 12 Trapease and OptEase filters were broken at the angle between the body of the filter and the upper cone with no secondary complications. The remaining filters remained intact, but were deformed by balloon dilatation. In the special case of the Simon-Nitinol filters, two simultaneously placed balloons (12-16 mm) were inflated across two

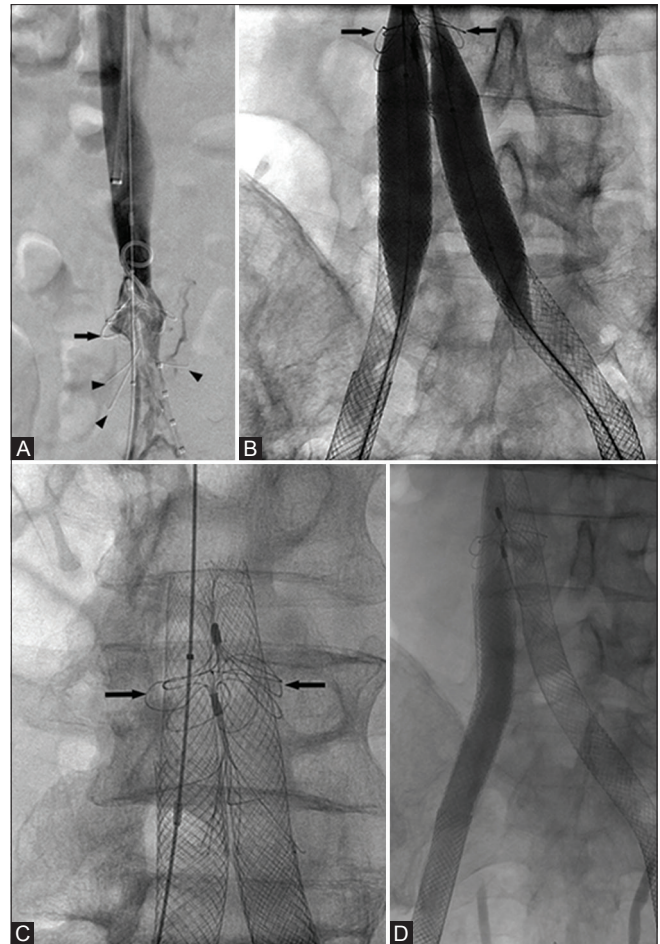


Figure 2 (A-D): (A) Infrarenal cavogram through left femoral access shows the Simon-Nitinol filter (arrow) with extensive caudal thrombosis. Note the penetration of the filter struts through the caval wall (arrowheads) (B) Simultaneous balloon angioplasty of the filter cone (arrows) and the previously deployed bilateral iliac Wallstents (C) Wallstents extended cephalad through the filter rings (arrows) in a double-barrel technique (D) Completion cavogram shows patent stents and resolution of the thrombus

different rings of the filter cone to allow subsequent stent deployment.

Stent placement

Stent placement in the filter-bearing IVC and/or ilio caval segments was performed to exclude the existing filters and residual intraluminal thrombus. In patients who had infrarenal IVC filters, the stents extended caudally from below the level of the renal veins, across the filters, and to the level of the IVC bifurcation. Stents were placed in the ilio caval segments in a kissing fashion, extending to just above the inguinal ligaments. Stents used included Wallstents (Boston Scientific) ranging between 16 and 22 mm. These were supported with Palmaz stents (Cordis Corporation) in four cases where Wallstents alone could not achieve full expansion. In two cases, 14 mm × 60 mm SMART (Cordis Corporation) and Palmaz stents (two; 9 mm in diameter) were used to displace Greenfield and

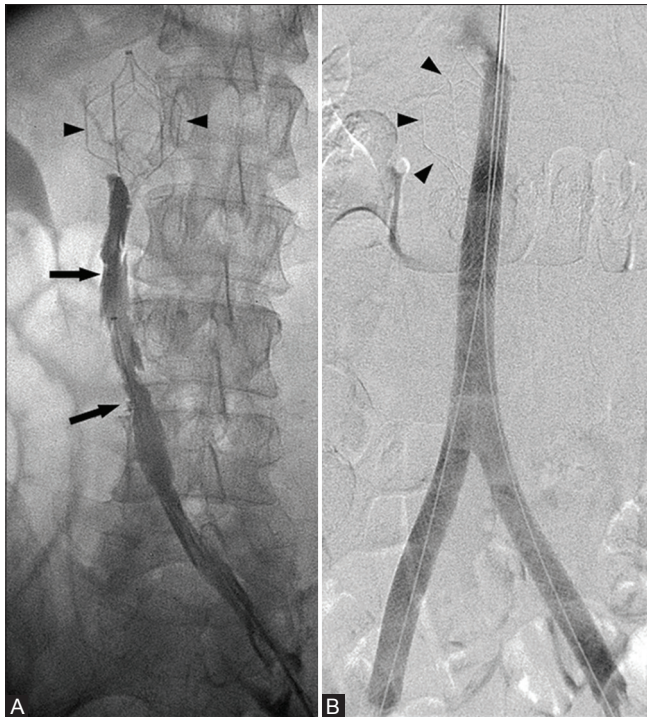


Figure 3 (A and B): (A) Cavogram through a left femoral access demonstrates extensive thrombosis of the cava (arrows) below the preexisting suprarenal Trapease filter (arrowheads) (B) Digital subtraction cavogram shows widely patent Wallstents extending to the level of the filter (arrowheads)

Celect filters, respectively. In the patients with occluded Simon-Nitinol filters, two 16-mm-diameter Wallstents were simultaneously deployed through two different rings of the filter cone and extended caudally into the iliac veins.

Among the four patients who had thrombosed suprarenal IVC filters, two required stenting of the filter-bearing segment extending across the renal veins to the infrarenal cava without interruption of the hepatic veins. The remaining two required only PMT without stent exclusion of the filter; one patient required stenting of the left renal vein, and the filter was successfully retrieved in the other.

Surgical femoral venous thrombectomy and AVF creation

Surgical thrombectomy and/or creation of AVF were performed as a separate surgical procedure in 16 patients (36%) where the venous inflow into the ilio caval segments and IVC was deemed by the operator insufficient to maintain patency of the stents on completion venogram.

The common femoral vein was approached from a vertical incision overlying the vessel. The common femoral vein (CFV) and its branches were isolated and controlled with vessel loops and clamped. In cases where the patient required excision of the chronic thrombus, this was done through a longitudinal venotomy and the thrombus was sharply excised. The vein was then patched with bovine pericardium. An arteriovenous fistula was generally

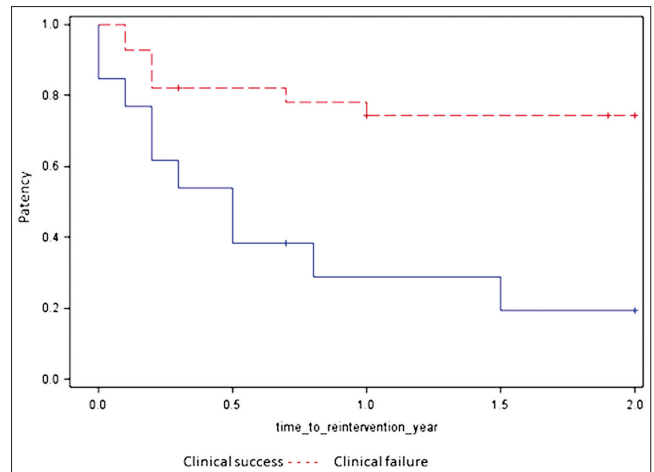


Figure 4: Comparison of time to re-intervention and patency between clinical success and clinical failure groups

constructed between the superficial femoral artery and a proximal branch of the *in situ* saphenous vein. An arteriotomy was created in the superficial femoral artery with a 2.5 mm aortic punch and the branch of the great saphenous vein was anastomosed to the artery with 7-0 polypropylene sutures.

One patient underwent creation of bilateral AVFs 3 months apart due to recurrence of DVT on the contralateral side. Another patient underwent creation of bilateral AVFs at the time of initial therapy. Of the patients who had clinical success without re-intervention, spontaneous occlusion occurred in two cases and following embolization in two other patients. In six patients with seven fistulae who had clinical success with re-intervention, four AVFs had spontaneous occlusion and three underwent percutaneous embolization. The remaining patients lost to follow-up. In one case of clinical failure, the AVF was embolized due to venous hypertension associated with occlusion of the ilio caval outflow.

Periprocedural use of IVC filters

Thirty-four patients (75%) received Gunther-Tulip periprocedural IVC filters for prophylaxis of potential pulmonary emboli. These were placed in a suprarenal location, except three that were placed in an infrarenal position. Four patients who had thrombosed suprarenal filters did not receive additional periprocedural filter placement. Two patients who presented with acute thrombosis also did not receive periprocedural filter. One of the placed filters was removed 6 weeks later and one was repositioned into the infrarenal stents at the end of the procedure.

Statistical analysis

Fisher's exact test was used for all comparisons of dichotomous variables. The Wilcoxon rank sum test was used for comparisons of continuous variables. The

Kaplan-Meier plot was produced to display patency rates in the clinical success and clinical failure groups. A 5% level of significance was used to evaluate statistical significance in all analyses.

Results

Anatomical success was achieved in all patients. Follow-up was not available in 10 patients (lost to follow-up, $n = 4$; expired due to comorbidities, $n = 2$; lost to follow-up after re-intervention, $n = 4$). Clinical evaluation was performed in all patients at the time of follow-up. Earlier patients were evaluated by clinical examination only ($n = 3$) or by Doppler ultrasound (US) of the lower extremities ($n = 17$) and CT scan of the abdomen and pelvis ($n = 4$). Later patients were evaluated by venogram of the ilio caval segments ($n = 11$). At a mean follow-up time of 13.3 months (range 1-48 months), clinical success was achieved in 27 patients (60%), i.e. in 21 patients without re-intervention and in 6 patients with re-intervention. Clinical success was not achieved despite re-intervention in eight patients. Higher clinical success was noted in patients who did not require repeat interventions ($P = 0.03$) and the time to re-intervention was significantly shorter in patients who had clinical failure ($P = 0.01$) [Figure 4]. The mean time to re-intervene (6.05 ± 6.4 months) was significantly shorter than the mean follow-up time in the no-re-intervention cohort (13.08 ± 12.2 months) ($P = 0.04$). AVF creation did not improve the clinical success rate ($P = 1$) [Table 2].

There was no significant difference in clinical success between patients who had acute thrombosis compared to those who had subacute, acute-on-chronic, or chronic occlusion of filter-bearing IVCs ($P = 1$). There was no significant statistical association between the endovascular method and the clinical success.

Complications

Six patients (13%) had complications. Two were related to endovascular treatment. One patient had right renal vein thrombosis 7 days following the initial therapy due to extension of the stents above the renal veins, and was successfully treated with thrombolysis and stenting of the renal vein. The other patient had an acute PE 3 days following CDT and stenting of an acutely thrombosed filter-bearing IVC despite the placement of a suprarenal filter. No IVC tearing or retroperitoneal bleeding was

detected at the completion venograms. The other four complications were related to the creation of the groin AVF or open femoral venous thrombectomy, including groin hematomas ($n = 2$), pseudoaneurysm ($n = 1$), and leg swelling from lymphatic leakage ($n = 1$). IVC rupture was not routinely evaluated for unless there was clinical suspicion, in which case cross-sectional imaging was performed. No clinical PE was observed in patients with acutely thrombosed IVCs who did not receive periprocedural filters.

Discussion

Endovascular treatment of extensive thrombosis of non-filter-bearing IVCs is well studied and is recommended as a first line of therapy in select patients who have a low risk of bleeding (as it may reduce the acute symptoms and post-thrombotic morbidity).^[14-17] However, the usefulness of this technique has not been well validated in thrombosed filter-bearing IVCs. In addition to the potential risk of bleeding related to systemic anticoagulation or CDT in patients who initially required the filter for contraindication to anticoagulation, the presence of filters poses an additional challenging factor in treating IVC thrombosis as it causes mechanical obstruction and flow alterations, especially when the thrombosis extends into the filter itself or cephalad to it. Vedantham *et al.* reported their clinical experience in the endovascular treatment of 10 patients who had thrombosis of filter-bearing IVCs and found that clinical success was achieved in 83% and concluded that endovascular recanalization of the occluded filter-bearing IVC is feasible even in the presence of an IVC filter.^[10] A recent study of 708 patients with chronic non-malignant post-thrombotic ilio caval outflow obstruction, included 53 patients with thrombosed IVC filters.^[11] They found that stenting across the filter may be safely performed with no apparent tear of the IVC, clinically manifesting bleeding or PE.^[11] In the same study, the patency rates with stenting across the filter segment in 25 patients with occluded filters were compared to 28 patients with ilio caval thrombosis not extending into the filter in which the stent did not cross the filter segment. They found that patency is not influenced by the extension of the stents across the filter segment, but is rather related to the severity of post-thrombotic disease.^[11] A comparison was also performed between the limbs stented for recanalized occlusions with and without IVC filters, which showed no significant difference in cumulative primary and secondary patency rates indicating that the presence of filters did not affect the outcome.^[11]

Venous thrombectomy with temporary groin AVFs to augment the inflow into the ilio caval segments has been previously described as an effective treatment for iliofemoral venous thrombosis and it reduces the risk of future venous insufficiency and post-thrombotic syndrome.^[18,19] The data from our study suggest that AVFs did not improve the

Table 2: Comparison of the outcomes between patients with AVF and without AVF

	No re-intervention		Re-intervention	
	Clinical success	Clinical failure	Clinical success	Clinical failure
AVF	4	1	6	2
No AVF	17	1	0	4

AVF: Arteriovenous fistula

likelihood of clinical success. However, it is important to note that the majority of patients who underwent thrombectomy and AVF creation in our cohort initially had more extensive disease and required more aggressive treatment than those who did not require thrombectomy and AVF creation. This fact may have contributed to the worse overall prognosis in this subset of patients.

While there was no documented clinical PE during or following the procedures in patients who had no suprarenal filter, only one clinical PE was observed despite the use of suprarenal filter. It remains difficult to ascertain the role of suprarenal IVC filter in prevention of PE following the thrombolysis procedures and during the follow-up time in these patients. Although suprarenal filter placement is reportedly safe and effective in cases of venous thromboembolism,^[20,21] the use of these filters during thrombolysis procedures needs further evaluation in larger randomized studies.

Our study is inherently limited by its retrospective nature and the small sample size. As a result, the factors leading to clinical failure cannot be identified. Additional limitations include the lack of some of the clinical data pertaining to the anticoagulation regimens prior to the initiation of the endovascular therapy, as well as the short-term follow-up and the lack of follow-up in other patients. In addition, the follow-up methodology was not uniform in all cases. In earlier patients, the clinical success was based on clinical notes, while more rigorous methods (clinical, US, and venographic evaluation) were available in more recent patients. The decision to re-intervention was, however, based on clinical symptomatology with/without imaging documentation. Nevertheless, this study suggests, in concordance with other previous studies, that recanalization of thrombosed filter-bearing IVCs is a safe and feasible technique.

Acknowledgements

Thanks to Kuanwong Watcharotone, Ph.D. and James D Myles, Ph.D, from the Michigan Institute for Clinical Health Research, Ann Arbor, MI, for performing the statistical analysis.

References

1. Hammond CJ, Bakshi DR, Currie RJ, Patel JV, Kinsella D, McWilliams RG, et al. Audit of the use of IVC filters in the UK: Experience from three centres over 12 years. *Clin Radiol* 2009;64:502-10.
2. Decousus H, Leizorovicz A, Parent F, Page Y, Tardy B, Girard P, et al. A clinical trial of vena caval filters in the prevention of pulmonary embolism in patients with proximal deep-vein thrombosis. Prévention du Risque d'Embolie Pulmonaire par Interruption Cave Study Group. *N Engl J Med* 1998;338:409-15.
3. Spencer FA, Bates SM, Goldberg RJ, Lessard D, Emery C, Glushchenko A, et al. A population-based study of inferior vena cava filters in patients with acute venous thromboembolism. *Arch Intern Med* 2010;170:1456-62.

4. Kinney TB. Update on inferior vena cava filters. *J Vasc Interv Radiol* 2003;14:425-40.
5. Nazzal M, Chan E, Nazzal M, Abbas J, Erikson G, Sediqe S, et al. Complications related to inferior vena cava filters: A single-center experience. *Ann Vasc Surg* 2010;24:480-6.
6. Streiff MB. Vena caval filters: A comprehensive review. *Blood* 2000;95:3669-77.
7. Kim HS, Young MJ, Narayan AK, Hong K, Liddell RP, Streiff MB. A comparison of clinical outcomes with retrievable and permanent inferior vena cava filters. *J Vasc Interv Radiol* 2008;19:393-9.
8. Given MF, McDonald BC, Brookfield P, Niggemeyer L, Kossmann T, Varma DK, et al. Retrievable Gunther Tulip inferior vena cava filter: Experience in 317 patients. *J Med Imaging Radiat Oncol* 2008;52:452-7.
9. Kalva SP, Athanasoulis CA, Fan CM, Curvelo M, Geller SC, Greenfield AJ, et al. "Recovery" vena cava filter: Experience in 96 patients. *Cardiovasc Intervent Radiol* 2006;29:559-64.
10. Vedantham S, Vesely TM, Parti N, Darcy MD, Pilgram TK, Sicard GA, et al. Endovascular recanalization of the thrombosed filter-bearing inferior vena cava. *J Vasc Interv Radiol* 2003;14:893-903.
11. Neglen P, Oglesbee M, Olivier J, Raju S. Stenting of chronically obstructed inferior vena cava filters. *J Vasc Surg* 2011;54:153-61.
12. Sildiroglu O, Ozer H, Turba UC. Management of the thrombosed filter-bearing inferior vena cava. *Semin Intervent Radiol* 2012;29:57-63.
13. Vedantham S, Thorpe PE, Cardella JF, Grassi CJ, Patel NH, Ferral H, et al.; CIRSE and SIR Standards of Practice Committees. Quality improvement guidelines for the treatment of lower extremity deep vein thrombosis with use of endovascular thrombus removal. *J Vasc Interv Radiol* 2009;20(Suppl):S227-39.
14. Bjarnason H, Kruse JR, Asinger DA, Nazarian GK, Dietz CA Jr, Caldwell MD, et al. Iliofemoral deep venous thrombosis: Safety and efficacy outcome during 5 years of catheter-directed thrombolytic therapy. *J Vasc Interv Radiol* 1997;8:405-18.
15. Patel NH, Stookey KR, Ketcham DB, Cragg AH. Endovascular management of acute extensive iliofemoral deep venous thrombosis caused by May-Thurner syndrome. *J Vasc Interv Radiol* 2000;11:1297-302.
16. Enden T, Kløw NE, Sandvik L, Slagsvold CE, Ghanima W, Hafsahl G, et al. Catheter-directed thrombolysis vs. anticoagulant therapy alone in deep vein thrombosis: Results of an open randomized, controlled trial reporting on short-term patency. *J Thromb Haemost* 2009;7:1268-75.
17. Kearon C, Kahn SR, Agnelli G, Goldhaber S, Raskob GE, Comerota AJ; American College of Chest Physicians. Antithrombotic therapy for venous thromboembolic disease: American College of Chest Physicians Evidence-Based Clinical Practice Guidelines. (8th Edition). *Chest* 2008;133(Suppl):454S-545S.
18. Fruhwirth J, Gutschi S, Amann W, Luschin-Ebengreuth G, Uggowitz M. Results of surgical treatment of pregnancy-associated pelvic vein thrombosis. *Z Geburtshilfe Neonatol* 1997;201:91-4.
19. Törngren S, Swedenborg J. Thrombectomy and temporary arterio-venous fistula for ilio-femoral venous thrombosis. *Int Angiol* 1988;7:14-8.
20. Matchett WJ, Jones MP, McFarland DR, Ferris EJ. Suprarenal vena caval filter placement: Follow-up of four filter types in 22 patients. *J Vasc Interv Radiol* 1998;9:588-93.
21. Kalva SP, Chlapoutaki C, Wicky S, Greenfield AJ, Waltman AC, Athanasoulis CA. Suprarenal inferior vena cava filters: A 20-year single-center experience. *J Vasc Interv Radiol* 2008;19:1041-7.

Cite this article as: Arabi M, Krishnamurthy V, Cwikiel W, Vellody R, Wakefield TW, Rectenwald J, et al. Endovascular treatment of thrombosed inferior vena cava filters: Techniques and short-term outcomes. *Indian J Radiol Imaging* 2015;25:233-8.

Source of Support: Nil, **Conflict of Interest:** None declared.