


# Acute heart transplantation from mechanical circulatory support in a human immunodeficiency virus-positive patient with fulminant myocarditis

Zsolia Szakal-Toth<sup>1</sup>, Janos Szlavik<sup>2</sup>, Adam Soltesz<sup>3</sup>, Viktor Berzsenyi<sup>3</sup>, Gergely Csikos<sup>3</sup>, Tamas Varga<sup>3</sup>, Kristof Racz<sup>3</sup>, Akos Kiraly<sup>1</sup>, Balazs Sax<sup>1</sup>, Istvan Hartyanyszky<sup>1</sup>, Attila Fintha<sup>4</sup>, Zoltan Prohaszka<sup>5</sup>, Katalin Monostory<sup>6</sup>, Bela Merkely<sup>1</sup> and Endre Nemeth<sup>3\*</sup> 

<sup>1</sup>Heart and Vascular Center, Semmelweis University, Budapest, Hungary; <sup>2</sup>National Institute for Infectology and Haematology, South-Pest Hospital Centre, Budapest, Hungary; <sup>3</sup>Department of Anaesthesiology and Intensive Therapy, Semmelweis University, Budapest, Hungary; <sup>4</sup>1st Department of Pathology and Experimental Cancer Research, Semmelweis University, Budapest, Hungary; <sup>5</sup>Department of Medicine and Haematology, Semmelweis University, Budapest, Hungary; <sup>6</sup>Institute of Enzymology, Research Centre for Natural Sciences, Budapest, Hungary

## Abstract

Since the establishment of highly active antiretroviral therapy, survival rates have improved among patients with human immunodeficiency virus infection giving them the possibility to become transplant candidates. Recent publications revealed that human immunodeficiency virus-positive heart transplant recipients' survival is similar to non-infected patients. We present the case of a 40-year-old human immunodeficiency virus infected patient, who was hospitalized due to severely decreased left ventricular function with a possible aetiology of acute myocarditis, that has later been confirmed by histological investigation of myocardial biopsy. Due to rapid progression to refractory cardiogenic shock, extracorporeal membrane oxygenation implantation had been initiated, which was upgraded to biventricular assist device later. On the 35th day of upgraded support, the patient underwent heart transplantation uneventfully. Our clinical experience confirms that implementation of temporary mechanical circulatory support and subsequent cardiac transplantation might be successful in human immunodeficiency virus-positive patients even in case of new onset, irreversible acute heart failure.

**Keywords** Human immunodeficiency virus; Acute heart failure; Acute myocarditis; Mechanical circulatory support; Heart transplantation; Secondary thrombotic microangiopathy

Received: 6 November 2020; Revised: 21 January 2021; Accepted: 8 February 2021

\*Correspondence to: Endre Nemeth, Department of Anaesthesiology and Intensive Therapy, Semmelweis University, Budapest, Hungary. Tel: +36208259164;

Fax: +36-1-4586842, Email: nemeth.endre@med.semmelweis-univ.hu

The institutions where the work was performed:

1. Heart and Vascular Center, Semmelweis University, Budapest, Hungary.

2. Department of Anaesthesiology and Intensive Therapy, Semmelweis University, Budapest, Hungary.

## Introduction

Since the establishment of highly active antiretroviral therapy (HAART), survival rates have improved among patients with human immunodeficiency virus (HIV) infection with a parallel decrease in the incidence of acquired immunodeficiency syndrome, turning HIV infection into a chronic disease.<sup>1,2</sup> Nowadays, HIV-positive patients' life expectancy mostly depends on chronic organ dysfunctions, including chronic hepatic, renal and pulmonary disorders, or cardiomyopathy.<sup>3</sup> The risk of cardiovascular disease and the prevalence of chronic heart

failure are significantly higher in HIV-positive patients as compared with non-HIV-infected patients.<sup>3–5</sup> HIV infection had been a contraindication for solid organ transplantation until recently, due to concern about the interference of the immunosuppression therapy, viral load, and immune status.<sup>4,6,7</sup> The findings of three recent publications confirmed that HIV-positive heart transplant recipients' survival is comparable with non-HIV-infected patients.<sup>8–10</sup> Furthermore, the occurrences of acute rejection, chronic allograft vasculopathy, infection, and malignancy after heart transplantation (HTx) in HIV-positive patients are also similar to general patient

population.<sup>10</sup> Correspondingly, based on the listing criteria of the updated consensus guidelines generated by the International Society of Heart and Lung Transplantation (ISHLT), HIV infection is not considered an absolute contraindication for HTx anymore.<sup>11</sup> Even though, there are only a few transplant centres performing HTx in HIV-positive patients.<sup>6</sup>

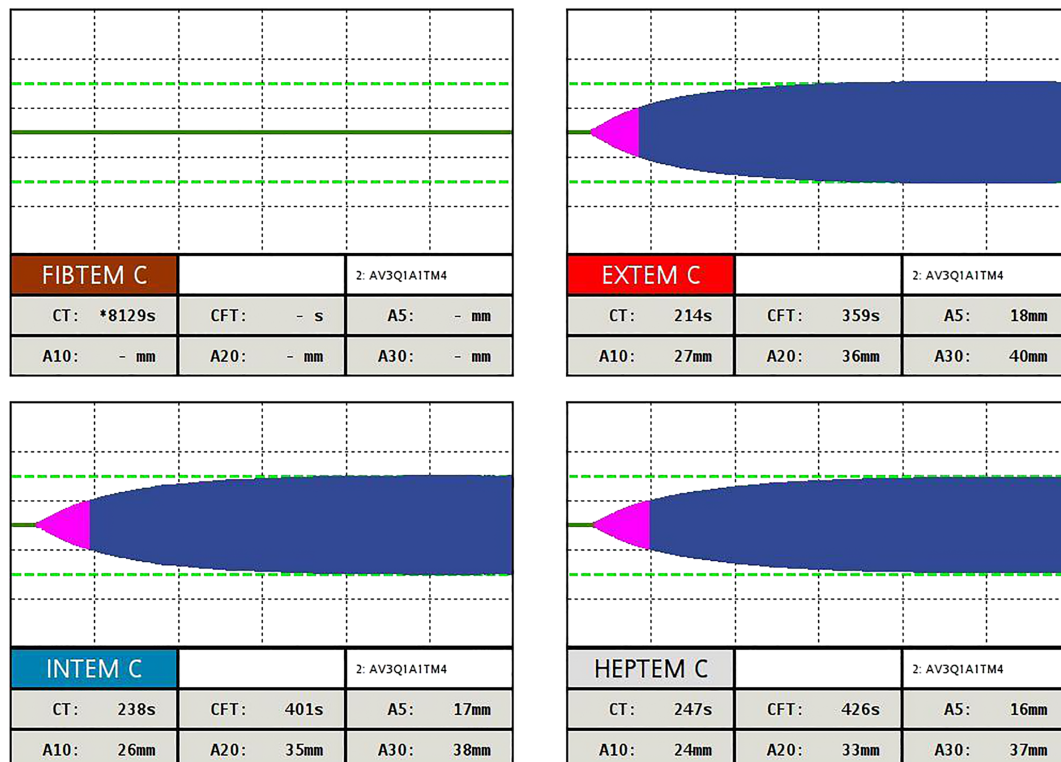
## Case report

We present a case report of a 40-year-old male patient with well-controlled HIV infection in previous medical history. He was diagnosed with HIV infection in 2012, when he had cytomegalovirus infection. In the same year, he underwent opportunistic infections including perianal fistula and pneumonia leading to septic shock. Since then, HAART had been started including darunavir/cobicistat and INN-etravirine. HIV viral load was undetectable, and CD4+ count was greater than 200 cells per microlitre for several years.

At present, the patient was first hospitalized by a district hospital due to new onset, worsening dyspnoea. The clinical examinations confirmed severely decreased left ventricular function [ejection fraction (EF): 20%, cardiac index:

1.37 L/min/m<sup>2</sup>] and a negative coronary angiography with a possible aetiology of acute viral myocarditis. Despite of 5 days of combined inotropic support, patient developed refractory cardiogenic shock; therefore, he was referred for mechanical circulatory support (MCS) implantation and transferred to our tertiary centre. On admission to the intensive care unit, the patient's clinical parameters were as follows: left ventricular EF: 14%, APACHE II score: 9 points, SOFA score: 8 points. The patient went for urgent central venoarterial extracorporeal membrane oxygenation (VA-ECMO) implantation. Intraoperative myocardial biopsy confirmed the diagnosis of subacute active lymphocytic myocarditis, which was considered to be independent of HIV infection, according to the undetectable viral load for many years. Eosinophil granulocytes, giant cells or granulomatous inflammation were excluded. Over the first four postoperative days, the patient stabilized on VA-ECMO support of median of 3.5 (3.4, 3.9) L/min, his vasopressor requirement decreased. On the 2nd postoperative day, the patient has been extubated uneventfully; however, 2 days later, he required an urgent reintubation due to bleeding from the respiratory tract. Laboratory tests showed thrombocytopenia (lowest platelet count: 64 g/L), and the rotational thromboelastometry (ROTEM) revealed pronounced substrate deficiency and prolonged clotting time (*Figure 1*).

**Figure 1** Rotational thromboelastometry test performed at the time of the first respiratory tract bleeding on venoarterial extracorporeal membrane oxygenation support. A5, amplitude 5 min after CT; A10, amplitude 10 min after CT; A20, amplitude 20 min after CT; A30, amplitude 30 min after CT; CFT, clot formation time; CT, clotting time.

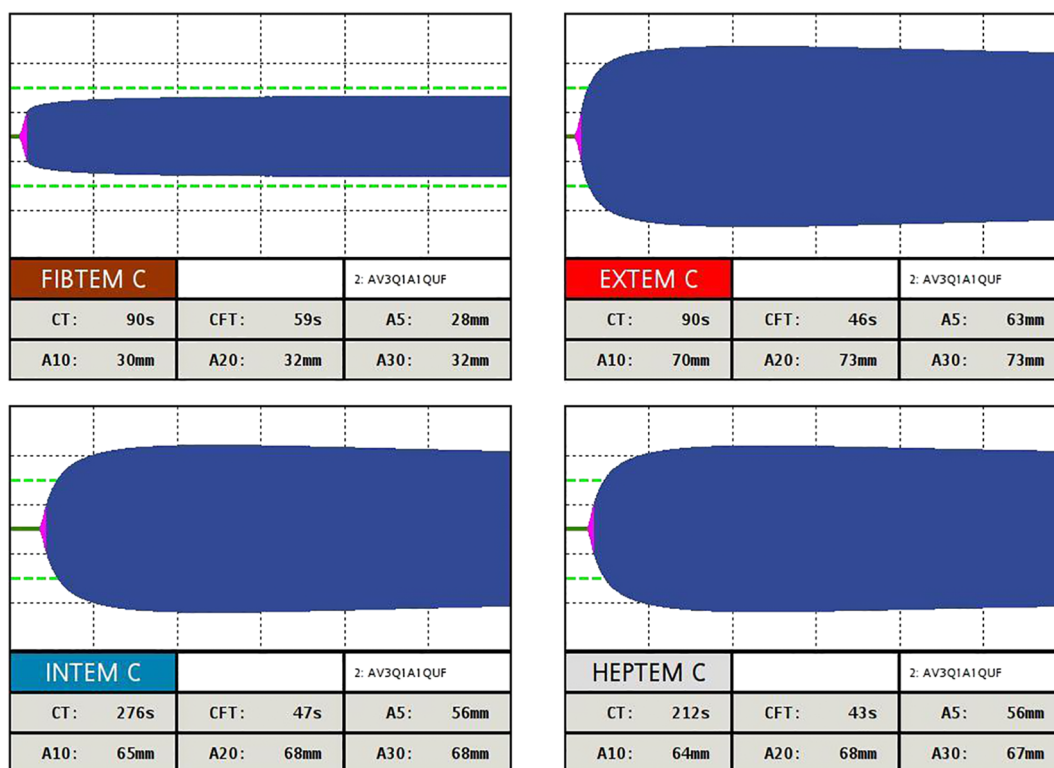

Excluding any improvement or recovery in patient's cardiac function, the multidisciplinary team decided to upgrade VA-ECMO system to paracorporeal biventricular assist device (BiVAD), which was performed 7 days after the VA-ECMO implantation. The patient's general condition showed slow stabilization while being on BiVAD support. Based on echocardiography results, both the left and right ventricular functions remained severely deteriorated. Over the first 2 weeks after BiVAD implantation, several bleeding episodes occurred from the respiratory tract and from the

exit points of the BiVAD cannulas, which were first considered the consequence of the persistent thrombocytopenia. Interestingly, ROTEM follow-up tests showed hypercoagulable state (Figure 2).

To clarify the developed complex coagulopathy, additional haematological examinations have been performed, which confirmed secondary thrombotic microangiopathy (TMA). The ADAMTS13 activity had been severely decreased; the activity of both classical and alternative complement pathways had been markedly reduced (Table 1). According to these

**Figure 2** Rotational thromboelastometry test during bleeding from the respiratory tract and from the exit points of the biventricular assist device cannulas. A5, amplitude 5 min after CT; A10, amplitude 10 min after CT; A20, amplitude 20 min after CT; A30, amplitude 30 min after CT; CFT, clot formation time; CT, clotting time.



**Table 1** Follow-up parameters of secondary thrombotic microangiopathy

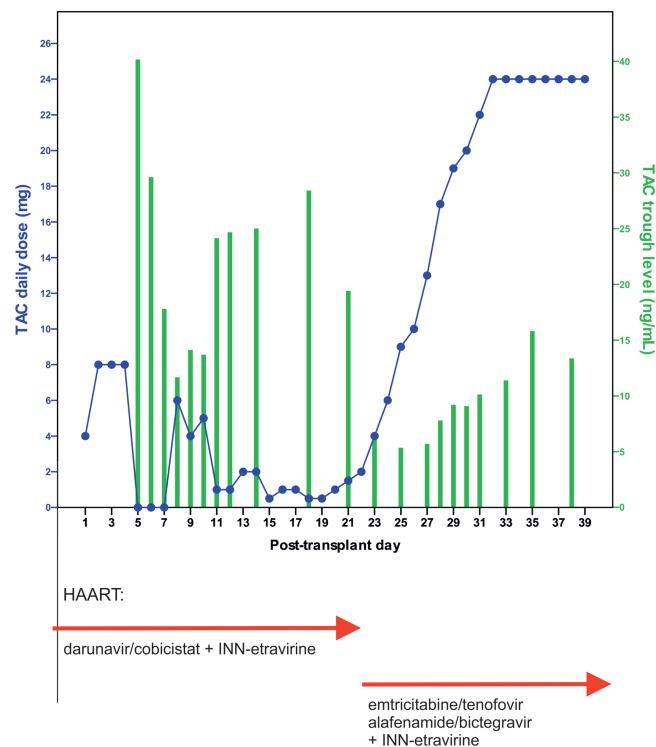
| Parameter (reference range)                               | Postoperative day |      |      |      |
|---|-------------------|------|------|------|
|   | 5                 | 11   | 19   | 32   |
| ADAMTS13 activity (67–137%)                               | 30                | 29   | 61   | 31   |
| Total complement activity (48–103 CH50/mL)                | 93                | 26   | 103  | 129  |
| Alternative pathway activity (70–130%)                    | 64                | 52   | 89   | 107  |
| Complement 3 (0.9–1.8 g/L)                                | 1.29              | 1.22 | 1.66 | 1.78 |
| Complement 4 (0.15–0.55 g/L)                              | 0.20              | 0.19 | 0.26 | 0.36 |
| Terminal pathway activation marker SC5b-9 (110–252 ng/mL) | 335               | 473  | 261  | 225  |
| Haptoglobin (0.3–2.0 g/L)                                 | 0.04              | 2.56 | N/A  | N/A  |
| Platelet (150–400 G/L)                                    | 85                | 147  | 196  | 139  |

results, we supposed that the cause of TMA was an MCS-associated immune modulation combined with a consumptive coagulopathy leading to global over-activation of the complement system. With the aim to control severe TMA, patient received regular fresh frozen plasma transfusions, which resulted in recovery of the TMA after 1 week (Table 1).

On the 21st day of BiVAD support, the patient developed a spontaneous progressive right side haemothorax, which compromised his haemodynamics and led to transient haematological disturbance. Patient was referred for urgent cardiothoracic discussion and went for emergency right-side thoracotomy. The operation revealed an unspecific bleeding source from the pericardial region of the visceral pleura, which was presumed to be associated to BiVAD support. Taking into account the patient's stable general condition (including intact cognitive status, minimal invasive mechanical ventilation support, well-preserved extracardiac organ functions, undetectable HIV viral load with an absolute CD4+ of 244 cells per microlitre), the absence of recovery in cardiac function and the high risk for the recurrence of life-threatening bleeding and/or thromboembolic complications, the multidisciplinary team decided to refer the patient for Eurotransplant high urgent status. On the 33rd day of BiVAD

support, the patient was accepted to Eurotransplant high urgent waiting list. Two days later, he underwent heart transplantation (HTx) uneventfully. The histological investigation of the explanted heart also confirmed the diagnosis of active lymphocytic myocarditis. In places, granulation tissue and replacement fibrosis were identifiable as chronic signs. After the HTx, he tolerated an extended mobilization and a weaning programme on mechanical ventilation, which was completed on the 9th post-transplant day. Two days later, the patient was emitted to the transplant cardiology ward. The maintenance immunosuppressive regimen consisted of tacrolimus, mycophenolate mofetil, and methylprednisolone. Despite applying very low doses of tacrolimus, the trough drug levels were over the therapeutic range in the subsequent series (Figure 3). As tacrolimus is metabolized by the CYP3A enzymes, the patient's CYP3A status was determined, that resulted in intermediate CYP3A4 expression ( $1.48 \times 10^{-6}$ ), which did not explain the extremely high tacrolimus blood concentrations. As cobicistat is a CYP3A enzyme inhibitor, we decided to switch darunavir/cobicistat to emtricitabine/tenofovir alafenamide/bictegravir. This change resulted in significant response in drug metabolism leading to subtherapeutic trough tacrolimus levels within few days (Figure 3). Withdrawal of darunavir/cobicistat induced an

**Figure 3** Tacrolimus trough drug levels and its applied doses during the post-transplant period. The blue spotted line represents the daily applied tacrolimus dose (mg); the green bars represent tacrolimus trough levels (ng/mL). The red arrows display highly active antiretroviral therapy applied in the perioperative period. HAART, highly active antiretroviral therapy; TAC, tacrolimus.



approximately seven-fold increase in CYP3A4 expression ( $9.87 \times 10^{-6}$ ), according to the follow-up CYP3A4 expression measurement.

The third routine endomyocardial biopsy on post-transplant Day 26 revealed moderate acute cellular rejection (ISHLT Grade 2R) that recovered with steroid shot therapy. Echocardiography proved excellent graft function during the follow-up period. The patient was discharged home in medically well condition 6 weeks after HTx. At that time, the patient's HIV infection was well controlled with undetectable viral load and absolute CD4+ of 270 cells per cubic millimetre. Four months after HTx, the patient is stable with outstanding general condition, excellent graft function, and without developing any post-transplant opportunistic infections.

## Discussion

Mechanical circulatory support implantation and performing HTx in HIV-infected patients is exceptionally rare, despite the fact that prevalence of chronic heart failure is significantly higher in this patient group than in non-HIV-infected subjects.<sup>3–5</sup> The main challenges of the post-transplant care are to prevent drug–drug interactions and HIV reactivation by immunosuppressants.<sup>6</sup> Bontempo *et al.* reported the first case of HTx in a HIV-positive patient performed in the USA in 1988.<sup>12</sup> The first European report was published in 2011.<sup>13</sup> Several subsequent studies have highlighted that post-transplant survival rates among patients with well-controlled HIV infection and stable chronic heart failure are the same as compared with general patient population.<sup>8–10</sup> Despite these encouraging data, less than 80 HIV-infected patients went through cardiac transplantation until the end of the year 2019.<sup>14</sup> To the best of our knowledge, there have been only a few case reports regarding VA-ECMO implantation in HIV-infected patients. In one of these cases, ECMO was upgraded to long-term LVAD, and the patient underwent successful HTx later.<sup>15</sup> Another recent publication described heart-lung transplantation bridged

by VA-ECMO in an HIV-positive patient.<sup>16</sup> In comparison, experiences of VV-ECMO implementation among HIV-infected patients with respiratory failure are already more relevant. Favourable outcomes on the widespread use of VV-ECMO were published by Brogan *et al.* and Capatos *et al.* according to the results of their multicentre-based analysis and an observational study, respectively.<sup>17,18</sup> Moreover, the first case of HTx bridged by BiVAD support in an HIV-positive patient suffering from acute heart failure was reported by Peters *et al.* most recently.<sup>19</sup> Our clinical experience demonstrates that bridge-to-transplant implementation of temporary MCS and performing acute HTx could be feasible and successful in HIV-infected patients with convincing outcome, without any major complications even in case of new onset, irreversible acute heart failure.

## Acknowledgements

The authors would like to acknowledge Beata Nagy, MD, for participating in the histopathological investigations and Gyorgy Sinkovits, MD, for assisting in the haematological investigations.

## Conflict of interest

Zsofia Szakál-Tóth, Janos Szlavik, Adam Soltesz, Viktor Berzsenyi, Gergely Csikos, Tamas Varga, Kristof Racz, Akos Kiraly, Balazs Sax, Istvan Hartyanszky, Attila Fintha, Zoltan Prohaszka, Katalin Monostory, Bela Merkely, and Endre Nemeth declare that they have no conflicts of interest to disclose.

## Consent for publication

Written informed consent was obtained from the patient for publication.

## References

1. Palella FJ Jr, Baker RK, Moorman AC, Chmiel JS, Wood KC, Brooks JT, Holmberg SD. Mortality in the highly active antiretroviral therapy era: changing causes of death and disease in the HIV outpatient study. *J Acquir Immune Defic Syndr* 2006; **43**: 27–34.
2. The Joint United Nations Programme on HIV and AIDS (UNAIDS). UNAIDS Data 2017. [http://www.unaids.org/sites/default/files/media\\_asset/201707\\_20\\_Data\\_book\\_2017\\_en.pdf](http://www.unaids.org/sites/default/files/media_asset/201707_20_Data_book_2017_en.pdf). Accessed July 15, 2019.
3. Ingle SM, May MT, Gill MJ, Mugavero MJ, Lewden C, Abgrall S, Fatkenheuer G, Reiss P, Saag MS, Manzardo C, Grabar S, Bruyand M, Moore D, Mocroft A, Sterling TR, Monforte AD, Hernando V, Teira R, Guest J, Cavassini M, Crane HM, Sterne JAC. Impact of risk factors for specific causes of death in the first and subsequent years of antiretroviral therapy among HIV-infected patients. *Clin Infect Dis* 2014; **59**: 287–297.
4. Blumberg EA, Rogers CC. Human immunodeficiency virus in solid organ transplantation. *Am J Transplant* 2013; **13**: 169–178.
5. Remick J, Georgiopolou V, Marti C, Ofotokun I, Kalogeropoulos A, Lewis W, Butler J. Heart failure in patients with human immunodeficiency virus infection: epidemiology, pathophysiology,

- treatment, and future research. *Circulation* 2014; **129**: 1781–1789.
6. Uriel N, Nahumi N, Colombo PC, Yuzefpolskaya M, Restaino SW, Han J, Thomas SS, Garan AR, Takayama H, Mancini DM, Naka Y, Jorde UP. Advanced heart failure in patients infected with human immunodeficiency virus: is there equal access to care? *J Heart Lung Transplant* 2014; **33**: 924–930.
  7. Agüero F, Castel MA, Cocchi S, Moreno A, Mestres CA, Cervera C, Perez-Villa F, Tuset M, Cartana R, Manzardo C, Guaraldi G, Gatell JM, Miro JM. An update on heart transplantation in human immunodeficiency virus-infected patients. *Am J Transplant* 2016; **16**: 21–28.
  8. Madan S, Patel SR, Saeed O, Sims DB, Shin JJ, Goldstein DJ, Jorde UP. Outcomes of heart transplantation in patients with human immunodeficiency virus. *Am J Transplant* 2019; **19**: 1529–1535.
  9. Koval CE, Farr M, Krisl J, Haidar G, Pereira MR, Shrestha N, Malinis MF, Mueller NJ, Hannan MM, Grossi P, Huprikar S. Heart or lung transplant outcomes in HIV-infected recipients. *J Heart Lung Transplant* 2019; **38**: 1296–1305.
  10. Chen C, Wen X, Yadav A, Belviso N, Kogut S, McCauley J. Outcomes in human immunodeficiency virus-infected recipients of heart transplants. *Clin Transplant* 2019; **33**: e13440.
  11. Mehra MR, Canter CA, Hannan MM, Semigran MJ, Uber PA, Baran DA, Danziger-Isakov L, Kirklin JK, Kirk R, Kushwaha SS, Lund LH, Potena L, Ross HJ, Taylor DO, Verschuuren EAM, Zuckermann A. The 2016 International Society for Heart Lung Transplantation listing criteria for heart transplantation: a 10-year update. *J Heart Lung Transplant* 2016; **35**: 1–23.
  12. Bontempo FA, Lewis JH, Spero JA. Heart transplant in a hemophiliac with an acquired factor VIII inhibitor: synthesis of factor VIII:C in pericardial fluid. *Transplant Proc* 1988; **20**: 790–791.
  13. Durante-Mangoni E, Maiello C, Sbreglia C. A European first: successful heart transplant in a human immunodeficiency virus-positive recipient. *J Heart Lung Transplant* 2011; **30**: 845.
  14. Liu GS, Wolfson AM, Genyk PA, Vucicevic D, Pandya K, Fong M, Nattiv J, Li JP, Kingsford PA, Banankhah P, DePasquale E, Vaidya AS. Outcomes of HIV-positive patients post cardiac transplantation. *J Heart Lung Transplant* 2020; **39**: S81.
  15. Mehdiani A, Petrov G, Akhyari P, Saeed D, Kamiya H, Westenfeld R, Lichtenberg A, Boeken U. Heart transplantation bridged by mechanical circulatory support in a HIV-positive patient. *J Card Surg* 2016; **31**: 559–561.
  16. Blackman AL, Heil EL, Devanathan AS, Sheth PN. The effect of veno-arterial extracorporeal oxygenation and nasogastric tube administration on the pharmacokinetic profile of abacavir, lamivudine and dolutegravir: a case report. *Antivir Ther* 2020; **25**: 115–119.
  17. Brogan TV, Thiagarajan RR, Lorusso R, McMullan DM, di Nardo M, Ogino MT, Dalton HJ, Burke CR, Capatos G. The use of extracorporeal membrane oxygenation in human immunodeficiency virus-positive patients: a review of a multicentre database. *Perfusion* 2020; **35**: 772–777.
  18. Capatos G, Burke CR, Ogino MT, Lorusso MR, Brogan TV, McMullan DM, Dalton HJ. Venovenous extracorporeal life support in patients with HIV infection and *Pneumocystis jirovecii* pneumonia. *Perfusion* 2018; **33**: 433–437.
  19. Peters LL, Ambardekar AV. Successful heart transplantation after giant cell myocarditis in a patient with HIV complicated by recurrent giant cell myocarditis and Kaposi sarcoma. *J Heart Lung Transplant* 2020; **39**: 1506–1508.