

IgG4-Related Disease Presenting as Cervical Lymphadenopathy

Po-Hsuan Wu¹, Yu-Chen Chang², Li-Jen Liao^{1,3*}

¹Department of Otolaryngology, Far Eastern Memorial Hospital, Taipei, Taiwan, ²Department of Pathology, Far Eastern Memorial Hospital, Taipei, Taiwan,

³Department of Electrical Engineering, Yuan Ze University, Taoyuan, Taiwan

Abstract

Cervical lymph node enlargement as the first and sole manifestation of IgG4-related disease (IgG4-RD) is rare and is often difficult to distinguish from lymphoma. Here, we report a case of a 63-year-old man initially presenting with bilateral posterior neck masses. Ultrasonography revealed multiple matted, ovoid, homogenous, hypoechoic, and enlarged lymph nodes below the right parotid gland. In addition, there was heterogeneous echotexture with small and indistinct hypoechoic nodules over bilateral parotid and submandibular glands which suggested sclerosing sialadenitis. Pathology of the tissues obtained by core needle biopsy revealed reactive hyperplasia, but a diagnosis of lymphoma could not be excluded. Subsequently, excisional biopsy and serological tests were done. The diagnosis of IgG4-RD was confirmed due to marked elevation of serum IgG4 levels and pathological evidence of IgG+ and IgG4+ plasma cell infiltration in the lymph node specimen. The patient's neck masses subsided gradually after 1 week of oral steroid therapy. The differential diagnosis of IgG4-RD should always be considered when sclerosing sialadenitis is presented with cervical lymphadenopathy.

Keywords: IgG4-related disease, lymph node, ultrasound

INTRODUCTION

IgG4-related disease (IgG4-RD) is an immune-mediated disorder with abundant IgG4-positive plasma cells infiltrated in affected organs. The disease has various clinical features and is easily misdiagnosed as lymphoma when initially presented as cervical lymphadenopathy.^[1] Regional lymph node enlargement is commonly observed adjacent to the affected organs in this disease. However, biopsy of the enlarged lymph nodes is not always diagnostically useful, as they are unlikely to show the histological features observed in the organs affected with IgG4-RD, such as storiform fibrosis and obliterative phlebitis.^[2] Ultrasonography (US) of the head and neck is helpful in evaluating cervical lymphadenopathy. The salivary gland is frequently involved in IgG4-RD and accounts for approximately 25.9% of extrapancreatic lesions.^[3] Regarding the ultrasonographic findings of IgG4-related sclerosing sialadenitis, most of the involved glands showed multiple small hypoechoic nodules within a relatively hyperechoic background.^[4] These findings may help clinicians to raise the suspicion of IgG4-RD and to further arrange appropriate

serological and pathological examinations to confirm the diagnosis.

CASE REPORT

A 63-year-old male came to our clinic due to progressively enlarging masses over the bilateral posterior neck for more than 1 year. There was no fever, body weight loss, nasal obstruction/bleeding, facial numbness/swelling, aural fullness, dry mouth, hemoptysis, short of breath, chest pain, or other discomfort mentioned. Physical examination revealed multiple, nontender, mobile, and solid masses in the posterior triangle region. No thyroid mass was found. No redness or swelling over preauricular, submandibular, or mouth floor region was noted. His bilateral tympanic membrane was intact. Oral cavity examination and nasopharyngoscopic examination revealed no remarkable findings. Review of system also showed negative findings. US was performed using a color Doppler US unit (Toshiba Aplio 500) and a 5–14 MHz broadband linear

Received: 28-06-2018 Accepted: 10-09-2018 Available Online: 30-10-2018

Video Available on: www.jmuonline.org

Access this article online

Quick Response Code:



Website:
www.jmuonline.org

DOI:
10.4103/JMU.JMU_66_18

Address for correspondence: Dr. Li-Jen Liao,

Department of Otolaryngology, Far Eastern Memorial Hospital,
No. 21, Section 2, Nan-Ya South Road Pan Chiao, Taipei 220, Taiwan.
E-mail: liao lj@ntu.edu.tw

This is an open access journal, and articles are distributed under the terms of the Creative Commons Attribution-NonCommercial-ShareAlike 4.0 License, which allows others to remix, tweak, and build upon the work non-commercially, as long as appropriate credit is given and the new creations are licensed under the identical terms.

For reprints contact: reprints@medknow.com

How to cite this article: Wu PH, Chang YC, Liao LJ. IgG4-Related disease presenting as cervical lymphadenopathy. *J Med Ultrasound* 2019;27:43-6.

array transducer [Video]. Multiple matted, ovoid, homogenous, hypoechoic and enlarged lymph nodes [Figure 1] were seen below the right parotid gland. There was also heterogeneous echotextures with small and indistinct hypoechoic nodules over bilateral parotid and submandibular glands [Figure 2]. US-guided core needle biopsy (CNB) of the right neck lymphadenopathies was performed. A 9 cm length modified nonadvancing, disposable, spring-loaded 18 gauge cutting biopsy needle (Temno biopsy system, Allegiance Healthcare corp., McGaw Park, IL, USA) with 15-mm side-notch was used for CNB. Two cores of tissue were sent for the pathological examination. The pathology suggested reactive hyperplasia. However, it was difficult to exclude low-grade lymphoma due to incomplete architectural evaluation of the biopsy specimens; therefore, the patient underwent excisional biopsy of the right neck lymph node. Laboratory examination showed marked elevation of serum IgG4 (4660 mg/dL). The white blood cell count (6.85 k/ μ L), anti-Ro antibody (17 AU/ml), and anti-La antibody (30 AU/ml) were within normal limit. The pathology of excisional biopsy specimens revealed reactive hyperplasia with scattered plasma cells in germinal centers and mildly increased plasma cells in interfollicular areas [Figure 3]. Focal penetration of blood vessels in the germinal center was also noted. Immunostainings for IgG and IgG4 revealed that the ratio of IgG4+/IgG+ plasma cells were >40% [Figure 4]. The final diagnosis was IgG4-RD. The patient received oral steroid therapy, and the lymph nodes completely regressed 1 week later without recurrence after 3 months of follow-up.

DISCUSSION

IgG4-RD is an immune-mediated fibro-inflammatory disease characterized by enlargement of the affected organs, elevation of serum IgG4 levels, and abundant IgG4-positive plasma cell infiltration in the affected organs.^[5] IgG4-RD includes a wide variety of diseases, which may be formerly diagnosed as Mikulicz's disease, autoimmune pancreatitis, Riedel thyroiditis, and retroperitoneal fibrosis.^[5] In the head-and-neck region, salivary glands, orbit, and thyroid are common sites of disease involvement.^[5] Although the pathogenesis of IgG4-RD has not yet been characterized, it is related to an antigen-driven inflammatory process.^[5] Histological examination usually reveals IgG4 plasmacytes infiltration (an elevated IgG4 (+)/IgG (+) cell ratio of >40%), storiform fibrosis, and obliterative phlebitis.^[5] The diagnostic criteria formulated in 2011 included (1) clinical examination showing characteristic diffuse/localized swelling or masses in single or multiple organs; (2) hematological examination showing elevated serum IgG4 concentrations (135 mg/dl); and (3) histopathological examination showing marked lymphocytes and plasmacytes infiltration with fibrosis, and IgG4+ plasma cell infiltration as IgG4+/IgG+ cells >40% in ratio with >10 IgG4+ plasma cells/HPF.^[6] If a case fulfills criteria 1, 2 and 3, the case can be defined as IgG4-RD; the case is probable if 1 and 3 are fulfilled and possible if 1 and 2 are fulfilled.^[6]

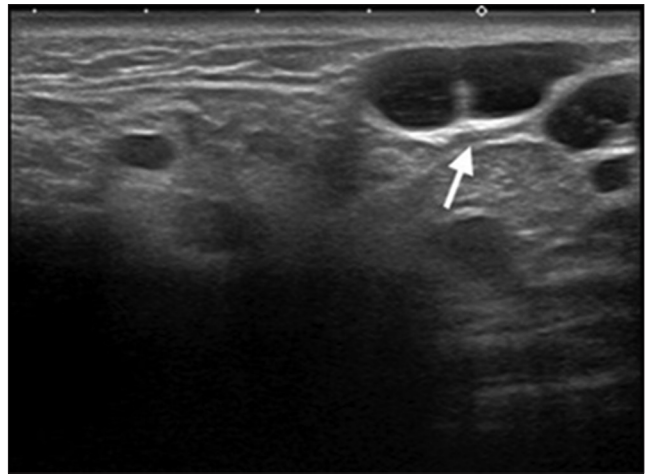


Figure 1: Transverse sonogram of the right upper neck revealed multiple matted, ovoid, hypoechoic, homogenous, and enlarged lymph nodes (arrow) below the right parotid gland

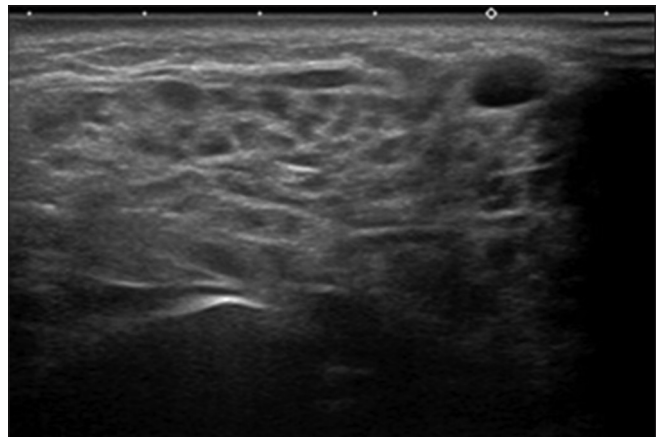


Figure 2: Sonogram of the right parotid gland shows heterogeneous echotexture with small and indistinct hypoechoic nodules. Similar findings are found over the left parotid and bilateral submandibular glands

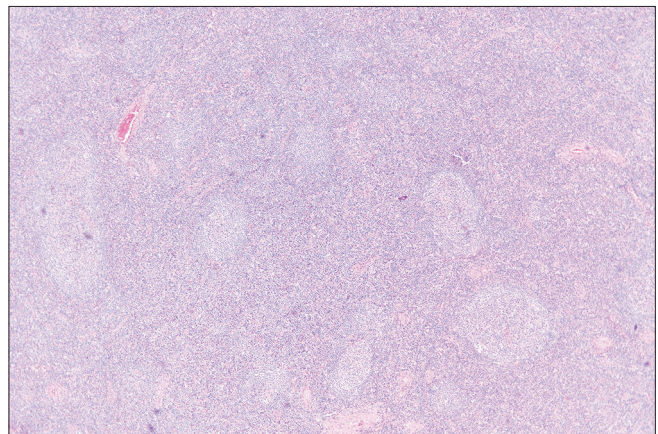


Figure 3: A photograph of histopathology shows retained nodal architecture and lymphoid follicles variable in size, with tangible-body macrophages in germinal centers. There are scattered plasma cells in germinal centers, and mildly increased plasma cells in interfollicular areas. A focal germinal center penetrated by a blood vessel is noted (H and E, $\times 40$)

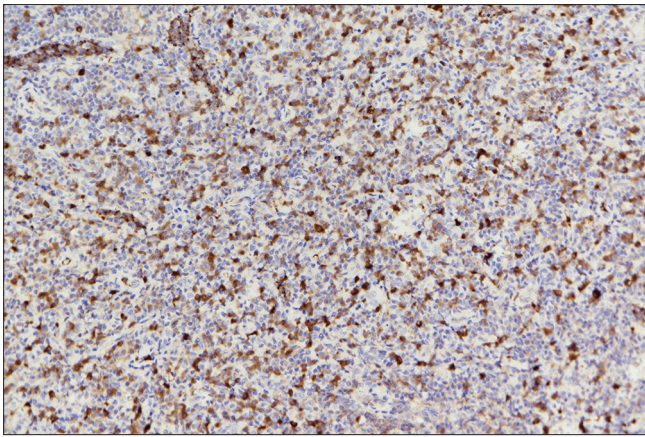


Figure 4: A photograph of immunohistochemistry for IgG and IgG4 reveal that the ratio of IgG4+/IgG+ plasma cell is >40%, which is suggestive of IgG4-related lymphadenopathy ($\times 200$ IgG4 immunostain)

Cervical lymphadenopathy in IgG4-RD generally presents in two forms.^[7] First, generalized lymphadenopathy can be the major or sole component of the clinical presentation. Patients with IgG4-related lymphadenopathy of this nature are often constitutionally well. Second, the involvement of the lymph nodes as a localized disease adjacent to a specific organ affected by IgG4-RD (e.g., the salivary glands) is common. Patients with IgG4-related lymphadenopathy often undergo serial lymph node biopsies to exclude lymphoma as shown in this case. Establishing diagnosis of IgG4-RD purely based on lymph node pathology is difficult because of its remarkable variations.

Clinicians should seek evidence of disease in other organ systems typically involved by IgG4-RD for a confident diagnosis. In this case, the heterogeneous echotexture presented in the bilateral parotid and submandibular glands suggested the possibility of sclerosing sialadenitis.

Increased numbers of IgG4+ plasma cells, of course, are universal; however, the storiform fibrosis commonly seen in other types of IgG4-RD organ involvement is unusual in IgG4-related lymphadenopathy. Lymph node biopsies in most cases are reported as “reactive follicular hyperplasia,” and specific stains for IgG4 are generally not performed because the diagnosis is not considered.

According to the patient’s medical history, there were no systemic features such as fever, body weight loss, night sweat, hepatomegaly or splenomegaly. There were also no constitutional symptoms. Besides, the hemogram showed no leukocytosis (white blood cell: 6.85 k/ μ L). Therefore, it is less likely that the lymphadenopathy resulted from infectious diseases. Among inflammatory cervical lymphadenopathies, several differential diagnoses should be considered including Sjögren syndrome, idiopathic multicentric Castleman’s disease (iMCD) and sarcoidosis. The laboratory study of this patient showed that both anti-Ro antibody (17 AU/ml) and anti-La antibody (30 AU/ml) were

within normal limit. Combined with his clinical manifestations, the diagnosis of Sjögren syndrome is unlikely. Comparison of clinicopathologic features between iMCD and IgG4-RD had been reported. Splenomegaly was observed in only iMCD, while pancreatitis and sialodacryoadenitis were limited to IgG4-RD.^[8] Histologically, sheet-like plasmacytosis was highly characteristic of iMCD, while plasmacytic infiltration in IgG4-RD was always associated with intervening lymphocytes.^[8] Besides, the average age of iMCD was significantly younger (mean: 53 \pm 13 years, compared to 69 \pm 10 years in IgG4-RD). In summary, the diagnosis of iMCD is also unlikely. Considering sarcoidosis, the finding of noncaseating granulomas in the histopathological study would be sufficient to differentiate the disease.

Treatment for IgG4-RD primarily involves systemic corticosteroids.^[5] The suggested dosage for single organ involvement can be initiated with prednisolone at 0.6 mg/kg/day, with a dosage of 1.0 mg/kg/day for multiple organ involvement.^[5] Prednisolone is continued at the initial dosage for 2–4 weeks, followed by a tapering of the dose. A maintenance dose of 5–10 mg/day is recommended due to the high relapse rate.^[5] Rituximab (RTX), an anti-CD20 antibody, has been shown to be effective in inducing remission and achieving steroid-sparing effects and has been frequently used since its first related report in 2010.^[9] Yamamoto *et al.* reported the outcomes of long-term treatment with RTX in IgG4-RD patients and suggested that RTX should be indicated in cases with a definitive diagnosis on histological examination, young age of onset, and wherein increasing the glucocorticoid dose is difficult due to complications.^[10]

Declaration of patient consent

The authors certify that they have obtained all appropriate patient consent forms. In the form the patient(s) has/have given his/her/their consent for his/her/their images and other clinical information to be reported in the journal. The patients understand that their names and initials will not be published and due efforts will be made to conceal their identity, but anonymity cannot be guaranteed.

Financial support and sponsorship

Nil.

Conflicts of interest

There are no conflicts of interest.

REFERENCES

1. Xu L, Li J, Ye Z, Wang X, Wang H, Wang H, *et al.* A case of IgG4-related disease seemingly presenting as a T-cell lymphoma. *Case Rep Clin Pathol* 2016;3:60.
2. Kamisawa T, Zen Y, Pillai S, Stone JH. IgG4-related disease. *Lancet* 2015;385:1460-71.
3. Hamano H, Arakura N, Muraki T, Ozaki Y, Kiyosawa K, Kawa S. Prevalence and distribution of extrapancreatic lesions complicating autoimmune pancreatitis. *J Gastroenterol* 2006;41:1197-205.
4. Hsu YC, Wang CP, Liao WC, Chen TC, Wang HP. Ultrasound examination for immunoglobulin G4-related sclerosing sialadenitis. *Int J Head Neck Sci* 2017;1:114-20.

5. Takano K, Yamamoto M, Takahashi H, Himi T. Recent advances in knowledge regarding the head and neck manifestations of IgG4-related disease. *Auris Nasus Larynx* 2017;44:7-17.
6. Hanaoka M, Kamisawa T, Koizumi S, Kuruma S, Chiba K, Kikuyama M, *et al.* Clinical features of IgG4-related rhinosinusitis. *Adv Med Sci* 2017;62:393-7.
7. Pan Z, Zhou J. IgG4-related lymphadenopathy: a potentially under- and over-diagnosed entity. *Int J Clin Exp Pathol* 2017;10:10153-66.
8. Otani K, Inoue D, Fujikura K, Komori T, Abe-Suzuki S, Tajiri T, *et al.* Idiopathic multicentric Castleman's disease: A clinicopathologic study in comparison with IgG4-related disease. *Oncotarget* 2018;9:6691-706.
9. Khosroshahi A, Bloch DB, Deshpande V, Stone JH. Rituximab therapy leads to rapid decline of serum IgG4 levels and prompt clinical improvement in IgG4-related systemic disease. *Arthritis Rheum* 2010;62:1755-62.
10. Yamamoto M, Awakawa T, Takahashi H. Is rituximab effective for IgG4-related disease in the long term? Experience of cases treated with rituximab for 4 years. *Ann Rheum Dis* 2015;74:e46.