

infectieuses et tropicales, ^bService de néphrologie, ^cService d'anatomie pathologique, hôpital Saint-Louis, and ^dUniversité de Paris Diderot, Sorbonne Paris Cité, Paris, France.

Correspondence to Pauline Penot, MD, service de maladies infectieuses et tropicales, hôpital Saint-Louis, 1 avenue Claude Vellefaux, 75010 Paris, France.

Tel: +33 1 42 49 46 83;

e-mail: pauline.penot@aphp.fr

Received: 25 November 2015; revised: 23 January 2016; accepted: 1 February 2016.

References

1. Turret J, Deray G, Isnard-Bagnis C. **Tenofovir effect on the kidneys of HIV-infected patients: a double-edged sword?** *J Am Soc Nephrol* 2013; **24**:1519–1527.
2. Monteiro N, Branco M, Peres S, Borges F, Mansinho K. **The impact of tenofovir disoproxil fumarate on kidney function: four-year data from the HIV-infected outpatient cohort.** *J Int AIDS Soc* 2014; **17**(4 Suppl 3):19565.
3. Cooper RD, Wiebe N, Smith N, Keiser P, Naicker S, Tonelli M. **Systematic review and meta-analysis: renal safety of tenofovir disoproxil fumarate in HIV-infected patients.** *Clin Infect Dis* 2010; **51**:496–505.
4. Sax PE, Gallant JE, Klotman PE. **Renal safety of tenofovir disoproxil fumarate.** *AIDS Read* 2007; **17**:90–92; 99–104, C3.
5. Hynes P, Urbina A, McMeeking A, Barisoni L, Rabenou R. **Acute renal failure after initiation of tenofovir disoproxil fumarate.** *Ren Fail* 2007; **29**:1063–1066.
6. Karras A, Lafaurie M, Furco A, Bourgarit A, Droz D, Sereni D, et al. **Tenofovir-related nephrotoxicity in human immunodeficiency virus-infected patients: three cases of renal failure, Fanconi syndrome, and nephrogenic diabetes insipidus.** *Clin Infect Dis* 2003; **36**:1070–1073.
7. Malik A, Abraham P, Malik N. **Acute renal failure and Fanconi syndrome in an AIDS patient on tenofovir treatment: case report and review of literature.** *J Infect* 2005; **51**:E61–E65.
8. Quimby D, Brito MO. **Fanconi syndrome associated with use of tenofovir in HIV-infected patients: a case report and review of the literature.** *AIDS Read* 2005; **15**:357–364.
9. Waheed S, Attia D, Estrella MM, Zafar Y, Atta MG, Lucas GM, et al. **Proximal tubular dysfunction and kidney injury associated with tenofovir in HIV patients: a case series.** *Clin Kidney J* 2015; **8**:420–425.
10. Gitman MD, Hirschwerk D, Baskin CH, Singhal PC. **Tenofovir-induced kidney injury.** *Expert Opin Drug Saf* 2007; **6**:155–164.
11. Gracey DM, Snelling P, McKenzie P, Strasser SI. **Tenofovir-associated Fanconi syndrome in patients with chronic hepatitis B mono-infection.** *Antivir Ther* 2013; **18**:945–948.
12. Sultan B, Benn P, Waters L. **Current perspectives in HIV postexposure prophylaxis.** *HIVAIDS (Auckl)* 2014; **6**:147–158.
13. Mayer KH, Mimiaga MJ, Cohen D, Grasso C, Bill R, Van Derwerker R, et al. **Tenofovir DF plus lamivudine or emtricitabine for nonoccupational postexposure prophylaxis (NPEP) in a Boston Community Health Center.** *J Acquir Immune Defic Syndr* 2008; **47**:494–499.
14. Tosini W, Muller P, Prazuck T, Benabdelmoumen G, Peyrouse E, Christian B, et al. **Tolerability of HIV postexposure prophylaxis with tenofovir/emtricitabine and lopinavir/ritonavir tablet formulation.** *AIDS Lond Engl* 2010; **24**:2375–2380.
15. **European AIDS Clinical Society. Guidelines version 7.1** 2014:86.
16. Calcagno A, Gonzalez de Requena D, Simiele M, D'Avolio A, Tettioni MC, Salassa B, et al. **Tenofovir plasma concentrations according to companion drugs: a cross-sectional study of HIV-positive patients with normal renal function.** *Antimicrob Agents Chemother* 2013; **57**:1840–1843.
17. Pavie J, Scemla A, Bouldouyre MA, Pillebout E, Verine J, Molina JM. **Severe acute renal failure in an HIV-infected patient after only 2 weeks of tenofovir-based antiretroviral therapy.** *AIDS Patient Care STDs* 2011; **25**:457–460.
18. Sax PE, Wohl D, Yin MT, Post F, DeJesus E, Saag M, et al. **Tenofovir alafenamide versus tenofovir disoproxil fumarate, coformulated with elvitegravir, cobicistat, and emtricitabine, for initial treatment of HIV-1 infection: two randomised, double-blind, phase 3, noninferiority trials.** *Lancet* 2015; **385**:2606–2615.

DOI:10.1097/QAD.0000000000001054

OPEN

Early experience of dolutegravir pharmacokinetics in pregnancy: high maternal levels and significant foetal exposure with twice-daily dosing

Dolutegravir is licenced for use in both adults and children over 12 years of age, although data are limited on its use in pregnant women. The manufacturer suggests that dolutegravir should be used in pregnancy only if the benefits outweigh the risks [1]. UK and US guidelines state that there are insufficient data to make recommendations on its use in pregnancy [2,3]. Nevertheless there are sporadic case reports of successful use in pregnant women [4,5] with significant placental transfer suggested by ex-vivo models [6] and a case report *in vivo* [5]. However, the effect of pregnancy on dolutegravir pharmacokinetics and optimal dosing during pregnancy is unknown. Here, we present our early experience of dolutegravir pharmacokinetics in two pregnant women, including the first published report of truncated 8-h pharmacokinetic profiles of dolutegravir in the first and third trimesters, in addition to measurement of foetal dolutegravir levels in umbilical cord blood.

Our unit has treated two pregnant women with dolutegravir, in both cases with extensive drug resistance where dolutegravir was justified to prevent onward transmission. The first was a 23-year-old woman who was referred in April 2015 for HIV management when she was 9 weeks pregnant, with a CD4 cell count of 158 cells/ μ l and a HIV viral load of 563 343 copies/ml. She was previously known to our services and had been well controlled on efavirenz and coformulated abacavir/lamivudine until September 2014 when she was lost to follow-up. Genotypic resistance testing showed X4 tropic virus with multiclass resistance to NRTIs and NNRTIs, but no protease or integrase resistance mutations. To aid adherence, she was commenced on a once q.d. regimen of darunavir/ritonavir (800 mg/100 mg) and dolutegravir (50 mg). Her HIV-1 viral load dropped to less than 30 copies/ml after 4 weeks. The drug was well tolerated.

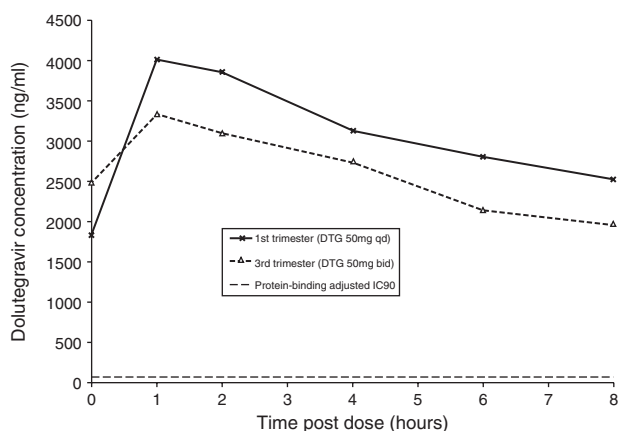


Fig. 1. Serum dolutegravir levels pre and postdose in 1st trimester (13 weeks of gestation) and 3rd trimester (32 weeks of gestation). DTG = dolutegravir, q.d. = once-daily, b.i.d. = twice-daily, IC₉₀ = inhibitory concentration for 90% of viral growth. Dolutegravir concentrations were measured by liquid chromatography with tandem mass spectrometry after resolving the glucuronidated dolutegravir from parent compound.

Eight hour truncated pharmacokinetic profiling of dolutegravir was carried out at week 13 gestation (Fig. 1). This showed a peak dolutegravir concentration (C_{\max}) of 4006 ng/ml, in excess of the mean C_{\max} of 3400 ng/ml in the SPRING-1 study for nonpregnant adults taking 50 mg q.d. of dolutegravir, and well above the protein-binding corrected IC₉₀ of 64 ng/ml for wild-type virus [7]. Area under the curve over 0–8 h (AUC_{0–8}) was 15.9 µg.h/ml.

Despite this, she experienced two rebounds in viral load to 625 and 325 copies/ml, in the context of significant medical problems (a pulmonary embolus and hydronephrosis complicated by bacteraemia). We addressed adherence concerns and her treatment was changed, at 22 weeks of gestation, to b.i.d. darunavir/ritonavir (600/100 mg) and twice daily dolutegravir (50 mg) in the anticipation that exposure to DTG would be reduced in the third trimester. Her viral load resuppressed and repeat pharmacokinetic profiling at 32 weeks of gestation (Fig. 1) showed a C_{\max} of 3334 ng/ml, with AUC_{0–8} 13.5 µg.h/ml, a reduction of 15%.

She delivered a healthy baby by planned caesarean section at 39 weeks of gestation; dolutegravir concentrations at delivery (13 h postdose) were 1730 ng/ml in maternal blood and 2211 ng/ml in cord blood, suggesting significant in-utero exposures. On review at 8 weeks, mother and baby were well; the baby's T and B cell numbers were normal, and are thus far uninfected.

The second woman, aged 27, had poor engagement with services; she was presented in September 2015 at 31 weeks of gestation in her third pregnancy, with a CD4 cell count

of 124 cells/µl and HIV-1 viral load of 235 copies/ml. She was last seen a year previously following delivery of her second child. At that time, she was virologically suppressed on zidovudine, lamivudine, raltegravir, and lopinavir/ritonavir, but had subsequently defaulted from clinic attendance. In view of her late presentation and uncertain resistance profile, she was started on b.i.d. dolutegravir (50 mg) and darunavir/ritonavir (600 mg/100 mg), and once q.d. coformulated tenofovir/emtricitabine (300 mg/200 mg). This was well tolerated and 4 weeks later her HIV-1 viral load was undetectable. She delivered a healthy baby in November 2015 at 38 weeks of gestation by planned caesarean section. Dolutegravir concentration in umbilical cord blood was 1281 ng/ml, again suggesting significant in-utero exposures. On review at 6 weeks, the baby was well, and is thus far uninfected. We have reported both cases to the antiretroviral pregnancy registry (<http://www.apregistry.com/Default.aspx>) and follow-up of both mothers and babies is on-going.

In conclusion, we present the first detailed pharmacokinetic profile of dolutegravir in pregnancy, and confirm significant foetal exposure at a dose of 50 mg b.i.d.. The effects of this level of in-utero exposure are unknown, but we suggest caution with b.i.d. dolutegravir dosing; if this dose is used, we suggest careful follow-up to assess for toxicity in the child. Further studies of dolutegravir in pregnancy are necessary to define the dosing schedule and assess safety.

Acknowledgements

Conflicts of interest

There are no conflicts of interest. This work received no specific funding. J.L. is supported by the Wellcome Trust as a Wellcome Trust clinical PhD fellow (grant number 109105/Z/15/Z).

Joseph M. Lewis^{a,b}, Eimear Railton^a, Andrew Rioridan^c, Saye Khoo^d and Mas Chaponda^a, ^aTropical and Infectious Diseases Unit, Royal Liverpool University Hospital, ^bWellcome Trust Liverpool Glasgow Centre for Global Health Research, ^cDepartment of Paediatric Infectious Diseases, Alder Hey Children's Foundation NHS Trust, and ^dDepartment of Molecular and Clinical Pharmacology, University of Liverpool, United Kingdom.

Correspondence to Joseph M Lewis, Tropical and Infectious Diseases Unit, Royal Liverpool University Hospital, Liverpool, L7 8XP, UK.
Tel: +44 7969 419910;
e-mail: joseph.lewis@liverpool.ac.uk

Received: 14 January 2016; accepted: 1 February 2016.

References

1. Viiv Healthcare Ltd. *Tivicay Summary of Product Characteristics*; 2015.
2. de Ruiter A, Taylor GP, Clayden P, Dhar J, Gandhi K, Gilleece Y, et al. **British HIV Association guidelines for the management of HIV infection in pregnant women 2012 (2014 interim review).** *HIV Med* 2014; **15** (Suppl 4):1–77.
3. US Department of Health and Human Services. Panel on Antiretroviral Guidelines for Adults and Adolescents. Guidelines for the use of antiretroviral agents in HIV-1-infected adults and adolescents. 2014. <http://aidsinfo.nih.gov/contentfiles/lvguidelines/AdultandAdolescentGL.pdf>. [Accessed 10 January 2016]
4. Pinnetti C, Tintoni M, Ammassari A, Tamburrini E, Bernardi S, Liuzzi G, et al. **Successful prevention of HIV mother-to-child transmission with dolutegravir-based combination antiretroviral therapy in a vertically infected pregnant woman with multi-class highly drug-resistant HIV-1.** *AIDS* 2015; **29**:2534–2537.
5. Pain JB, Lè MP, Caseris M, Amiel C, Lassel L, Charpentier C, et al. **Pharmacokinetics of dolutegravir in a premature neonate after HIV treatment intensification during pregnancy.** *Antimicrob Agents Chemother* 2015; **59**:3660–3662.
6. Schalkwijk S, Greupink R, Colbers AP, Wouterse AC, Verweij VG, van Drongelen J, et al. **Placental transfer of the HIV integrase inhibitor dolutegravir in an ex vivo human cotyledon perfusion model.** *J Antimicrob Chemother* 2015; **71**:480–483.
7. van Lunzen J, Maggiolo F, Arribas JR, Rakhmanova A, Yeni P, Young B, et al. **Once daily dolutegravir (S/GSK1349572) in combination therapy in antiretroviral-naïve adults with HIV: planned interim 48 week results from SPRING-1, a dose-ranging, randomised, phase 2b trial.** *Lancet Infect Dis* 2012; **12**:111–118.

DOI:10.1097/QAD.0000000000001055