

Digital cholangioscopy can detect residual biliary stones missed by occlusion cholangiogram in ERCP: a prospective tandem study



Authors

Divyesh V. Sejpal^{1,2}, Arvind J. Trindade^{2,3}, Calvin Lee^{1,2}, Larry S. Miller^{2,3}, Petros C. Benias^{1,2}, Sumant Inamdar^{1,2}, Gurshawn Singh^{1,2}, Molly Stewart^{1,2}, Benley J. George^{1,2}, Anil K. Vegesna^{3,4}

Institutions

- 1 Division of Gastroenterology, North Shore University Hospital, Manhasset, New York, United States
- 2 Zucker School of Medicine at Hofstra/Northwell, Hempstead, New York, United States
- 3 Long Island Jewish Medical Center, New Hyde Park, New York, United States
- 4 The Feinstein Institute for Medical Research

submitted 15.10.2018

accepted after revision 7.1.2019

Bibliography

DOI <https://doi.org/10.1055/a-0842-6450> |
Endoscopy International Open 2019; 07: E608–E614
© Georg Thieme Verlag KG Stuttgart · New York
ISSN 2364-3722

Corresponding author

Divyesh Sejpal, MD, MHCD, FASGE, FACC, AGAF, Professor of Medicine, Chief of Endoscopy, Northwell Health, Zucker School of Medicine at Hofstra/Northwell
Fax: +1-516-562-2683
Dsejpal@northwell.edu

ABSTRACT

Background and study aims After stone removal in endoscopic retrograde cholangiopancreatography (ERCP),

an occlusion cholangiogram (OC) is performed to confirm bile duct clearance. OC can miss residual stones that can lead to recurrent biliary symptoms. The aim of this study was to assess if digital peroral cholangioscopy (POC) increased the diagnostic yield of residual biliary stones that are missed with OC.

Patients and methods Patients having ERCP performed for choledocholithiasis were enrolled into the study only if they had one of the following criteria: dilated bile duct ≥ 12 mm and/or if lithotripsy was being performed. An OC was performed to confirm duct clearance after removal of stones followed by POC, based on inclusion criteria. The incremental yield of biliary stones missed by OC but confirmed by POC was then measured. A total of 96 POC procedures were performed on 93 patients in two tertiary care centers.

Results Residual biliary stones were found in 34% of cases. The average bile duct size in cases with residual stones was $15.1 \text{ mm} \pm 0.7 \text{ mm}$. One- to three-mm stones were found in 41% of cases, 4- to 7-mm stones in 45% of cases, and ≥ 8 -mm stones in 14% of cases. Lithotripsy was performed in 13% of cases and was significantly associated with residual stones (30% vs. 3%, $P < 0.001$).

Conclusions Occlusion cholangiogram can miss residual stones in patients with dilated bile ducts and those receiving lithotripsy. Digital POC can increase the yield of residual stone detection in these patients and should be considered to confirm clearance of stones. (ClinicalTrials.gov: NCT03482375).

Introduction

Gallstone disease affects over 20 million Americans [1]. Among patients with gallbladder disease, prevalence of choledocholithiasis is estimated to be 10% to 20% [2, 3] Endoscopic retrograde cholangiopancreatography (ERCP) is considered the standard of care for removing stones in the bile duct utilizing a variety of conventional methods including biliary sphincterotomy, balloon dilation, extraction balloon, retrieval basket, and lithotripsy. After removal of stones from the bile duct, a balloon

occlusion cholangiogram is usually performed to confirm complete bile duct clearance. However, occlusion cholangiogram (OC) can miss residual stones in 11% to 30% of cases, especially in the setting of a dilated bile duct, severe pneumobilia, and after lithotripsy (mechanical, electrohydraulic, or laser) [4–8]. Missed bile duct stones can lead to recurrent biliary symptoms, pancreatitis, cholangitis, and can have significant cost implication with the need for repeat imaging and/or procedures [4].

Peroral cholangioscopy (POC) enables direct visualization of the bile duct and allows for diagnostic and therapeutic maneu-

vers. Although POC has been available for over 30 years, it did not become a widespread technique due to the fact that traditional cholangioscopes are fragile, cumbersome to use, and require two endoscopists to perform the procedure. Introduction of a single-operator semi-disposable, fiberoptic cholangioscope system (SpyGlass, Boston Scientific, Marlborough, Massachusetts, United States) addressed many of the concerns associated with traditional cholangioscopes and led to more widespread use of cholangioscopy [5, 9, 10]; however, the sub-optimal image quality limited its application. Recent introduction of a completely disposable digital version of the Spyglass system has significantly improved image quality, thus augmenting the diagnostic and therapeutic capabilities of cholangioscopy [11, 12].

Given the substantial miss rate of residual stones on OC, it has been proposed that digital POC may be beneficial for detecting residual stones, especially in the setting of a dilated bile duct or lithotripsy. The goal of this prospective study was to assess whether digital POC would increase the diagnostic yield of residual biliary stones that are missed with OC during conventional ERCP.

Patients and methods

Patients

This was a prospective tandem study conducted at two large academic tertiary care hospitals that are part of Northwell Health System (Long Island, New York, United States). The study was approved by the Northwell Health Institutional Review Board and all patients signed informed consent prior to participating. All patients were scheduled for standard-of-care endoscopy. Inclusion criteria were suspected or documented choledocholithiasis and: 1) dilated bile duct ≥ 12 mm (any portion of duct); and/or 2) the patient underwent mechanical lithotripsy (ML) or electrohydraulic lithotripsy (EHL) for therapy of bile duct stones. Patients younger than age 18 years or who had altered anatomy including Billroth II, Roux-en-Y Gastric bypass, and Whipple procedure were excluded.

Procedure

All ERCPs were performed under general anesthesia per the institutional standard of care. Five therapeutic endoscopists with formal training in advanced endoscopy performed the procedures (DS, AT, CL, LM, and PB). All procedures were performed with a Philips Veradius fluoroscopy C-arm with flat detector. Standard-of-care ERCP was performed with cannulation of the bile duct and cholangiogram to identify any biliary stones. If stones were identified, they were removed with conventional methods such as sphincterotomy, balloon extraction, basket retrieval, and/or lithotripsy. It is our standard practice to sweep the bile duct several times with a balloon prior to OC to remove any residual stones. After the endoscopist thought the bile duct was cleared, an OC was performed with the balloon size being determined by the duct diameter. The concentration of contrast was left to the discretion of the individual endoscopist's standard of care. If the OC was negative, and if patient met enrollment criteria, digital POC (SpyGlass DS, Boston Scientific,

Marlborough, Massachusetts, United States) was performed to assess for residual stones. All operators are experienced in cholangioscopy and have performed at least 30 exams prior to initiation of the study. The single-use disposable cholangioscope was then inserted under endoscopic and fluoroscopic guidance over a wire just proximal to the bile duct hilum. The catheter is 10.5 Fr in diameter, has a four-way tip control, (the catheter handle includes two control knobs for left-right and up-down tip deflection), two channels for water infusion and suction, and a single 1.2-mm working channel. After adequate visualization of the bile duct was achieved, the scope was slowly pulled back carefully examining the entire bile duct. The endoscopists were instructed to examine the right and left hepatic ducts, the hilum, the common hepatic duct, the common bile duct, and the cystic duct/stump takeoff.

Any residual stones that were documented by POC were removed or treated, such as with stone extraction, lithotripsy, or stent placement. All patients that received POC were given one dose of intravenous antibiotic during the procedure because of the associated risk of bacteremia [13].

The primary aim of this study was to determine the incremental yield of digital POC in detection of residual biliary stones that were not detected on an OC. Patients with residual stones detected on POC after OC were defined as the positive POC group. Patients without residual stones on POC after OC were defined as the negative POC group.

Statistical analysis

Based on the literature, it is estimated that between 11% and 30% of these patients will have stones identified on POC that were missed by conventional ECRP. If the percent of patients with missed stones is 30%, then the 95% exact binomial confidence intervals for the proposed sample size of 100 subjects is 21.2% to 40.0%. Due to the expected screen failure rate (eg: - Bile duct size < 12 mm etc.) of approximately 30% to 40%, we planned to enroll a total of 140 subjects.

Continuous variables were expressed as a mean (\pm Standard Error). Statistical comparisons between them were performed using an unpaired Student's *t*-test. Categorical variables were expressed as percentages. Comparisons between nominal variables were performed using the chi-squared test. When two variables were dichotomous, Fisher's exact test was used. When % of expected count less than five, is more than 25%, then Phi and Cramer's V was used. A *P* value < 0.05 was considered statistically significant.

All calculations were made using the SPSS 22 statistical package (SPSS Inc., Chicago, Illinois, United States).

Results

From January 2016 to February 2018, 140 patients with suspected or documented choledocholithiasis were enrolled into the study, of which 93 patients met inclusion criteria of dilated bile duct ≥ 12 and/or lithotripsy being performed. Analysis was performed on a total of 96 procedures from the 93 patients. Patient characteristics are listed in ► **Table 1**. Three patients had repeat procedures because biliary stents were placed after de-

► **Table 1** Demographics and patient characteristics.

		Total qualified procedures	Negative POC	Positive POC	P value	Positive POC with stones ≥ 4 mm	P value
	Count	96 (100%)	63 (66%)	33 (34%)		20 (21%)	
	Age	65.1 ± 1.7	64.2 ± 2.3	66.9 ± 2.6	0.47	66.5 ± 3.6	0.61
Gender	Male	33 (34%)	19 (30%)	14 (42%)	0.23	9 (45%)	0.22
	Female	63 (66%)	44 (70%)	19 (58%)		11 (55%)	
Ethnicity	Hispanic	17 (18%)	14 (23%)	3 (9%)	0.26	0 (0%)	0.07
	Non-Hispanic	67 (71%)	41 (66%)	26 (79%)		17 (85%)	
	Not reported	11 (12%)	7 (11%)	4 (12%)		3 (15%)	
BMI		27.7 ± 0.7	27.6 ± 0.8	27.7 ± 1.1	0.96	29.2 ± 1.4	0.33
Inclusion criteria	Bile duct size ≥ 12 mm only	84 (88%)	61 (97%)	23 (70%)	<0.001 ¹	13 (65%)	0.006 ¹
	Lithotripsy only	2 (2%)	0 (0%)	2 (6%)	0.048 ¹	2 (10%)	0.011 ¹
	Both bile duct size ≥ 12mm and had lithotripsy	10 (10%)	2 (3%)	8 (24%)	0.001 ¹	5 (25%)	0.08
History of cholecystectomy		44 (46%)	28 (44%)	16 (49%)	0.71	11 (55%)	0.41
Past treatment	ERCP	64 (67%)	39 (62%)	25 (76%)	0.17	15 (75%)	0.29
	Balloon extraction	37 (39%)	25 (40%)	12 (36%)	0.75	6 (30%)	0.44
	Lithotripsy	13 (14%)	6 (10%)	7 (21%)	0.11	5 (25%)	0.08
	Sphincterotomy	26 (27%)	17 (27%)	9 (27%)	0.98	4 (20%)	0.53
	Balloon dilation	7 (7%)	4 (6%)	3 (9%)	0.63	1 (5%)	0.83
	Basket retrieval	3 (3%)	3 (5%)	0 (0%)	0.11	0 (0%)	0.32
	Biliary stent	47 (49%)	27 (43%)	20 (61%)	0.09	12 (60%)	0.18
	Other	3 (3%)	1 (2%)	2 (6%)	0.25	1 (5%)	0.39
LABS	Total bilirubin	2.8 ± 0.4	2.4 ± 0.4	3.4 ± 0.9	0.26	3.7 ± 0.7	0.12
	Direct bilirubin	2.1 ± 0.3	2.2 ± 0.5	1.8 ± 0.4	0.53	1.9 ± 0.5	0.70
	Indirect bilirubin	1.2 ± 0.2	1.4 ± 0.3	1.1 ± 0.2	0.75	1.3 ± 0.17	0.97
	Alkaline phosphatase	221.3 ± 17.6	196 ± 20.6	270.3 ± 31.7	0.04 ¹	293 ± 39.8	0.03 ¹
	ALT	187.1 ± 20.5	177.9 ± 21.6	205.3 ± 43.8	0.53	180.7 ± 37.9	0.95
	AST	154.2 ± 20.9	159.2 ± 26.1	144.3 ± 33.5	0.74	118.5 ± 27.1	0.42
Patient location	Inpatient	33 (35%)	23 (37%)	10 (30%)	0.51	7 (35%)	0.87
	Outpatient	62 (65%)	39 (63%)	23 (70%)		13 (65%)	

ALT, alanine aminotransferase; AST, aspartate aminotransferase.

P values are based on comparing to patients with negative POC.

¹ Significant

tection and/or lithotripsy of stones; these patients met inclusion criteria on their subsequent ERCP.

The main indication for performing POC was presence of a dilated bile duct ≥ 12 mm (88%), followed by a combination of dilated bile duct ≥ 12 mm and lithotripsy (10%), and lithotripsy only (2%). Thirty-four percent of the cases had residual stones

seen on POC (► **Table 2**, ► **Fig. 1**, ► **Fig. 2**). In patients with positive POC, the average total number of stones was 1.6 ± 0.1 with most stones seen in the common bile duct (67%), followed by hilum (15%), cystic stump (12%) and common hepatic duct (6%). Average stone size was 4.2 mm ± 0.3 mm, median 4.0, range 1–10 mm. One- to 3-mm stones were found in 41% of

► **Table 2** POC characteristics/findings in patients with residual stones.

		Positive POC N = 33 cases (34%)	Positive POC with stones ≥ 4 mm (N = 20)
Location of stones	Common hepatic duct	2 (6%)	1 (5%)
	Common bile duct	22 (67%)	13 (65%)
	Hilum	5 (15%)	3 (15%)
	Cystic stump	4 (12%)	3 (15%)
Average number of stones per patient		1.6 ± 0.1	1.6 ± 0.2
Average stone size (mm)		4.2 ± 0.3 (Range 1 to 10) (Median 4)	5.6 ± 0.3 (Range 4 to 10) (Median 5)
Grouping based on stone sizes	Stone size 1 to 3 mm	21 (41%)	-----
	Stone size 4 to 7 mm	23 (45%)	23 (77%)
	Stone size ≥ 8 mm	7 (14%)	7 (23%)
Treatment after POC	Balloon extraction	24 (73%)	15 (75%)
	Biliary stent placement	8 (24%)	4 (20%)
	Lithotripsy	6 (18%)	4 (20%)
	▪ Mechanical	0 (0%)	0 (0%)
	▪ EHL	6 (18%)	4 (20%)
	Sphincterotomy	1 (3%)	1 (5%)
	Balloon dilatation	2 (6%)	1 (5%)
	Basket retrieval	0 (0%)	0 (0%)
	Other	1 (3%)	1 (5%)

EHL, electrohydraulic lithotripsy

cases, 4- to 7-mm stones in 45% of cases, and ≥8-mm stones in 14% of cases.

The average bile duct size in the positive and negative POC groups was not statistically different (15.1 ± 0.7, range 11–30 mm and 14.3 ± 0.2, range 12–20 mm; $P=0.2$) (► **Table 3**). When evaluating bile duct sizes (ranging from 11–30 mm), no one size was statistically associated with residual stones. Average stone size initially seen on ERCP prior to POC was significantly larger in the POC-positive group vs. the POC-negative group (9.6 mm ± 0.9 mm vs. 6.7 mm ± 0.4 mm, $P=.001$). When evaluating stone shapes, cuboidal stones were significantly associated with the positive POC group (30% vs. 12%, $P=0.003$). Lithotripsy (both EHL and ML) was performed in 13% of cases and was significantly associated with the positive POC group (30% vs. 3%, $P<0.001$). A subgroup analysis of patients with stones ≥4 mm in the positive POC group was also performed and compared to the negative POC group (► **Table 1**, ► **Table 2**, ► **Table 3**); the findings were similar as all patients with residual stones except that the percentage of cuboidal stones was less.

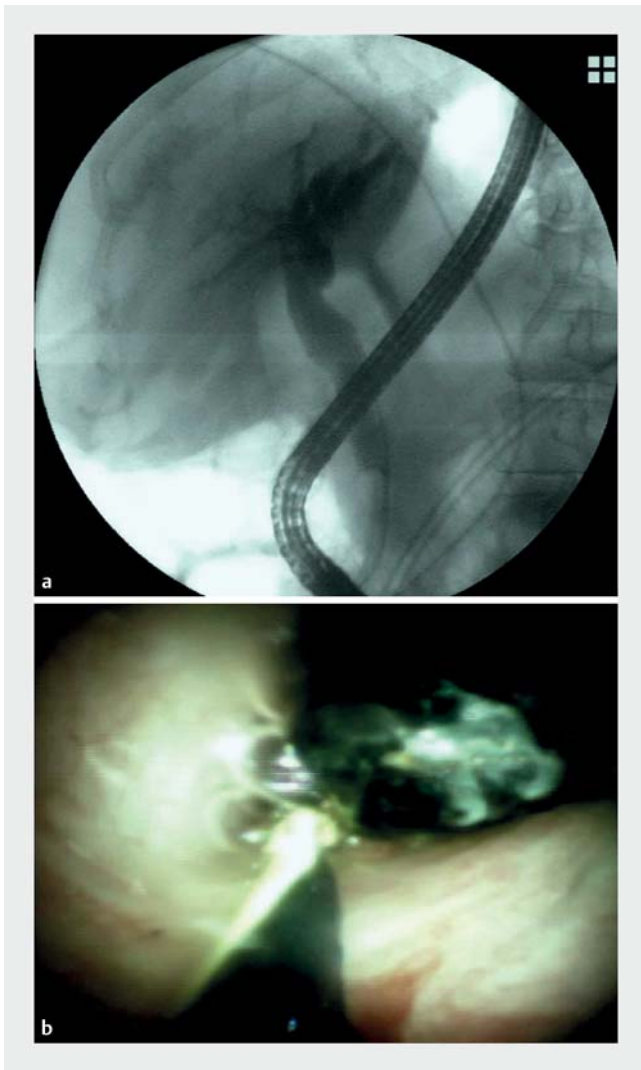
There were a total of three adverse events (AEs) that were related to the procedure. In the positive POC group, one patient had cholangitis which was classified as “mild” based on Ameri-

can Society of Gastrointestinal Endoscopy guidelines on AEs associated with ERCP (the patient was admitted and discharged the next day with PO antibiotics for 7 days). In the negative POC group, two patients had “moderate” pancreatitis, which was classified based on consensus definition and classification proposed by Cotton et al [14, 15].

Discussion

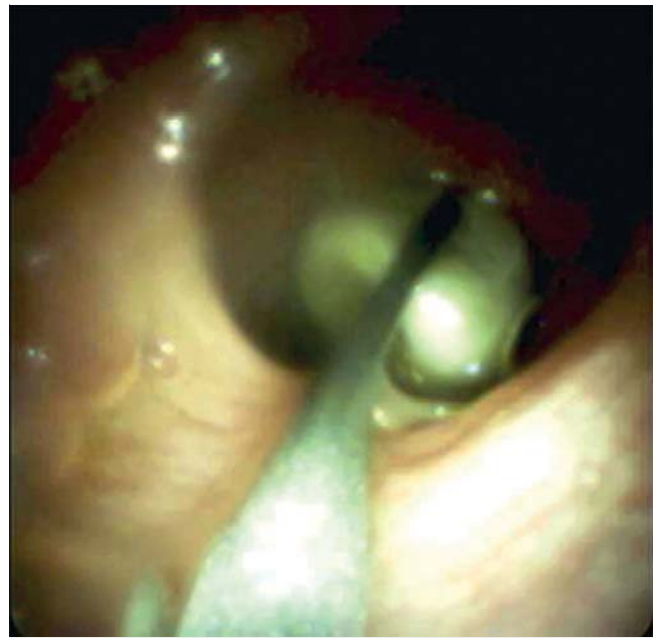
ERCP cholangiogram is considered the reference standard for diagnosis of choledocholithiasis. In fact, most studies evaluating EUS and magnetic resonance cholangiopancreatography for detection of choledocholithiasis use ERCP cholangiogram or intraoperative cholangiography as the “gold standard” for presence or absence of biliary stones [16–23]. However, ERCP cholangiogram and intraoperative cholangiography have been reported to miss stones, especially in the setting of a dilated bile duct or when lithotripsy is performed [6, 24, 25]. Thus, ERCP cholangiogram may not be sensitive enough to confirm clearance of the bile duct in these settings.

Peroral cholangioscopy provides direct visualization of the bile duct during ERCP and its benefits are well documented in numerous published studies. POC is most commonly per-



► **Fig. 1** a Negative occlusion cholangiogram in a dilated bile duct after removal of multiple stones. b Digital cholangioscopy showing a 6-mm residual stone in the common bile duct.

formed for management of difficult biliary stones and for evaluation of biliary strictures [11]. However, POC has also been described in evaluation of residual stones that are missed with cholangiogram. In a multicenter study evaluating POC for a variety of indications, 11% of patients (7/66) had bile duct stones identified only by POC that were missed on ERCP [5]. In a study of patients with primary sclerosing cholangitis, 30% of patients (7/23) were found to have stones with POC that were missed with cholangiography [26]. Lee et al. analyzed a group of 64 patients that had undergone mechanical lithotripsy and found that 28.3% (13/46) had residual stones seen with POC that were missed with an OC [7]. Itoi et al. assessed residual bile duct stones found with POC in comparison to balloon cholangiography in a retrospective study of 108 patients; they found that 24% of patients (26/108) had residual stones seen with POC that were missed with balloon-occluded cholangiography [6]. The residual stones ranged in size from 2 to 8 mm with a mean of 4.8 mm. The authors found that frequency of



► **Fig. 2** Digital cholangioscopy showing a residual stone that was found within the cystic stump.

missed stones was significantly higher with large stone size, presence of juxtapapillary diverticulum, and when ML or EHL was performed. In a small prospective study of 22 patients, Haung et al. showed that 22.7% (5/22) had residual stones detected with POC after a negative balloon-occluded cholangiography [27]. Because of the small sample size, no statistical analysis was performed. However, the residual stones ranged from 2 to 5 mm with a mean bile duct diameter of 19 mm in these patients.

Our study is the largest prospective study to date that evaluated digital POC in detecting residual stones in dilated bile ducts and/or lithotripsy patients that are missed with conventional ERCP. In our study, 34% of cases were found to have residual stones that were seen on POC but missed with an OC. Large stone size (>9 mm), cuboidal stones, and lithotripsy were all significantly associated with residual stones. The average bile duct size in cases with residual stones was 15.1 mm ± 0.7 mm. We attempted to clarify patients by degree of bile duct dilation (e. g. >15 mm), but found no correlation with residual stones. However, our sample size was not powered to find a relationship between specific duct size and residual stones.

In 12% of the positive POC cases, residual stones were found in or at the cystic stump in post-cholecystectomy patients. POC may potentially play an important role in detection of residual stones in the setting of a dilated cystic stump, especially when there is a low take-off from the bile duct. Presumably, these stones can ball-valve in and out of the cystic stump into the main bile duct and cause recurrent symptoms.

The strengths of this study include the prospective tandem design, large sample size for this type of study, and inclusion of multiple endoscopists that increases the generalizability of our study. The main limitation of the study is that we cannot

► **Table 3** ERCP procedure characteristics.

		Total qualified procedures	Negative POC	Positive POC	P value	Positive POC with stones ≥4 mm	P value
Juxtapapillary diverticulum		4 (4%)	3 (5%)	1 (3%)	0.69	1 (3%)	0.97
Biliary stent present at time of index ERCP		48 (50%)	27 (43%)	21 (64%)	0.05 ¹	13 (65%)	0.08
Bile duct size (mm)	Average	14.5 ± 0.3	14.3 ± 0.2	15.1 ± 0.7	0.2	15.5 ± 1.1	0.13
	Median	14	14	15		14	
	Range	11–30	12–20	11–30		11–30	
	≥ 15 mm	44%	40%	52%	0.27	40%	0.98
	≥ 18 mm	9%	10%	9%	0.95	15%	0.49
Stone size (mm)	Average	7.6 ± 0.4	6.7 ± 0.4	9.6 ± 0.9	0.001 ¹	8.9 ± 1.2	0.02 ¹
Stone shapes	Round	70 (40%)	44 (40%)	26 (39%)	0.84	16 (53%)	0.20
	Cuboidal	33 (19%)	13 (12%)	20 (30%)	0.003 ¹	4 (13%)	0.84
	Ovoid	63 (36%)	43 (40%)	20 (30%)	0.12	9 (30%)	0.34
	Other	10 (6%)	9 (8%)	1 (2%)	0.06	1 (3%)	0.36
Treatment during ERCP	Balloon extraction	93 (97%)	63 (100%)	30 (91%)	0.015 ¹	18 (90%)	0.011 ¹
	Biliary stent placement	6 (6%)	2 (3%)	4 (12%)	0.08	3 (15%)	0.07
	Lithotripsy	12 (13%)	2 (3%)	10 (30%)	<0.001 ¹	6 (30%)	<0.001 ¹
	▪ Mechanical	2 (3%) ²	1 (2%)	1 (3%) ²	0.64	1 (5%)	0.39
	▪ EHL	11 (11%)	1 (2%)	10 (30%) ²	<0.001 ¹	6 (30%)	<0.001 ¹
	Sphincterotomy	37 (39%)	28 (44%)	9 (27%)	0.10	5 (25%)	0.12
	Balloon dilatation	16 (17%)	8 (13%)	8 (24%)	0.15	5 (25%)	0.19
	Basket retrieval	2 (2%)	1 (2%)	1 (3%)	0.65	0 (0%)	0.57
	Other	1 (1%)	0 (0%)	1 (3%)	0.17	0 (0%)	_____

P values are based on comparing to patients with negative POC.

EHL, electrohydraulic lithotripsy; ERCP, endoscopic retrograde cholangiopancreatography

¹ Significant

² One patient had both mechanical lithotripsy and EHL

determine the clinical significance of missed residual stones. While there is no definitive way to know if the residual stones would be symptomatic if not detected and removed, we grouped the residual stones into categories based on their size and potential clinical relevance; 1- to 3-mm stones were seen in 41% of cases, 4- to 7-mm stones were seen in 45% of cases, and 8-mm and greater stones were seen in 14% of cases. In general, 59% of stones seen on POC were 4 mm or greater and 23% of these were ≥8 mm. We believe that these larger stones may have more clinical significance. The patients with stones ≥4 mm on POC were subdivided and compared to the negative POC group to identify risk factors for having larger residual stones; however, the findings were similar to all patients with residual stones. Some studies that have analyzed risk factors for recurrent biliary stones suggest that even small residual

stone fragments might act as nidi for future stone formation and lead to recurrent stones [28–31].

Another limitation of the study is that it was not blinded as the same operator performed the OC and the subsequent POC. In addition, no cost analysis was performed; we did not address the direct cost of POC for detection of residual stones nor did we address potential cost savings from avoidance of repeat procedures or hospitalizations from residual stones. Also, the additional potential risk of performing POC on top of standard-of-care ERCP was not addressed in this study.

Conclusion

In conclusion, OC can miss residual stones in patients with dilated bile ducts and those receiving lithotripsy. Digital POC can increase the yield of residual stone detection in these patients and should be considered to confirm clearance of stones.

Competing interests

This study was an investigator-initiated study supported by a research grant from Boston Scientific Corporation. The sponsor was not involved in the clinical trial design, conduct of the trial, analysis of results, or preparation of the manuscript. Dr. Sejpal is a consultant for Boston Scientific and Olympus. Dr. Trindade is a consultant for Pentax Medical. Dr. Benias is a consultant for Apollo and Medtronic.

References

- [1] Everhart JE, Khare M, Hill M et al. Prevalence and ethnic differences in gallbladder disease in the United States. *Gastroenterology* 1999; 117: 632–639
- [2] Lacaine F, Corlette MB, Bismuth H. Preoperative evaluation of the risk of common bile duct stones. *Arch Surg* 1980; 115: 1114–1116
- [3] Neuhaus H, Feussner H, Ungeheuer A et al. Prospective evaluation of the use of endoscopic retrograde cholangiography prior to laparoscopic cholecystectomy. *Endoscopy* 1992; 24: 745–749
- [4] Awadallah NSBS, Chen YKMD, Piraka CMD et al. Is there a role for cholangioscopy in patients with primary sclerosing cholangitis? *Am J Gastroenterol* 2006; 101: 284–291
- [5] Chen YK, Parsi MA, Binmoeller KF et al. Single-operator cholangioscopy in patients requiring evaluation of bile duct disease or therapy of biliary stones (with videos). *Gastrointest Endosc* 2011; 74: 805–814
- [6] Itoi T, Sofuni A, Itokawa F et al. Evaluation of residual bile duct stones by peroral cholangioscopy in comparison with balloon-cholangiography. *Dig Endosc* 2010; 22: (Suppl. 01): S85–s89
- [7] Lee YN, Moon JH, Choi HJ et al. Direct peroral cholangioscopy using an ultraslim upper endoscope for management of residual stones after mechanical lithotripsy for retained common bile duct stones. *Endoscopy* 2012; 44: 819–824
- [8] Maple JT, Ben-Menachem T, Anderson MA et al. The role of endoscopy in the evaluation of suspected choledocholithiasis. *Gastrointest Endosc* 2010; 71: 1–9
- [9] Chen YK. Preclinical characterization of the Spyglass peroral cholangiopancreatography system for direct access, visualization, and biopsy. *Gastrointest Endosc* 2007; 65: 303–311
- [10] Chen YK, Pleskow DK. SpyGlass single-operator peroral cholangiopancreatography system for the diagnosis and therapy of bile-duct disorders: a clinical feasibility study (with video). *Gastrointest Endosc* 2007; 65: 832–841
- [11] Komanduri S, Thosani N, Abu Dayyeh BK et al. Cholangiopancreatography. *Gastrointest Endosc* 2016; 84: 209–221
- [12] Navaneethan U, Hasan MK, Kommaraju K et al. Digital, single-operator cholangiopancreatography in the diagnosis and management of pancreatobiliary disorders: a multicenter clinical experience (with video). *Gastrointest Endosc* 2016; 84: 649–655
- [13] Othman MO, Guerrero R, Elhanafi S et al. A prospective study of the risk of bacteremia in directed cholangioscopic examination of the common bile duct. *Gastrointestinal endoscopy* 2016; 83: 151–157
- [14] Chandrasekhara V, Khashab MA. ASGE Standards of Practice Committee. et al. Adverse events associated with ERCP. *Gastrointest Endosc* 2017; 85: 32–47
- [15] Cotton PB, Lehman G, Vennes J et al. Endoscopic sphincterotomy complications and their management: an attempt at consensus. *Gastrointest Endosc* 1991; 37: 383–393
- [16] Ainsworth AP, Rafaelsen SR, Wamberg PA et al. Is there a difference in diagnostic accuracy and clinical impact between endoscopic ultrasonography and magnetic resonance cholangiopancreatography? *Endoscopy* 2003; 35: 1029–1032
- [17] de Ledinghen V, Lecesne R, Raymond JM et al. Diagnosis of choledocholithiasis: EUS or magnetic resonance cholangiography? A prospective controlled study *Gastrointest Endosc* 1999; 49: 26–31
- [18] Fernandez-Esparrach GMDPD, Gines AMDPD, Sanchez MMD et al. Comparison of Endoscopic Ultrasonography and Magnetic Resonance Cholangiopancreatography in the Diagnosis of Pancreatobiliary Diseases: A Prospective Study. *Am J Gastroenterol* 2007; 102: 1632–1639
- [19] Garrow D, Miller S, Sinha D et al. Endoscopic ultrasound: a meta-analysis of test performance in suspected biliary obstruction. *Clin Gastroenterol Hepatol* 2007; 5: 616–623
- [20] Kondo S, Isayama H, Akahane M et al. Detection of common bile duct stones: comparison between endoscopic ultrasonography, magnetic resonance cholangiography, and helical-computed-tomographic cholangiography. *Euro J Radiol* 2005; 54: 271–275
- [21] Materne R, Van Beers BE, Gigot JF et al. Extrahepatic biliary obstruction: magnetic resonance imaging compared with endoscopic ultrasonography. *Endoscopy* 2000; 32: 3–9
- [22] Scheiman JM, Carlos RC, Barnett JL et al. Can endoscopic ultrasound or magnetic resonance cholangiopancreatography replace ERCP in patients with suspected biliary disease? A prospective trial and cost analysis *Am J Gastroenterol* 2001; 96: 2900–2904
- [23] Tse F, Liu L, Barkun AN et al. EUS: a meta-analysis of test performance in suspected choledocholithiasis. *Gastrointest Endosc* 2008; 67: 235–244
- [24] Liu CL, Lo CM, Chan JK et al. EUS for detection of occult cholelithiasis in patients with idiopathic pancreatitis. *Gastrointest Endosc* 2000; 51: 28–32
- [25] Shimizu S, Tada M, Kawai K. Diagnostic ERCP. *Endoscopy* 1994; 26: 88–92
- [26] Awadallah NS, Chen YK, Piraka C et al. Is there a role for cholangioscopy in patients with primary sclerosing cholangitis? *Am J Gastroenterol* 2006; 101: 284–291
- [27] Huang SW, Lin CH, Lee MS et al. Residual common bile duct stones on direct peroral cholangioscopy using ultraslim endoscope. *World J Gastroenterol* 2013; 19: 4966–4972
- [28] Ando T, Tsuyuguchi T, Okugawa T et al. Risk factors for recurrent bile duct stones after endoscopic papillotomy. *Gut* 2003; 52: 116–121
- [29] Cheon YK, Lehman GA. Identification of risk factors for stone recurrence after endoscopic treatment of bile duct stones. *Eur J Gastroenterol Hepatol* 2006; 18: 461–464
- [30] Saito M, Tsuyuguchi T, Yamaguchi T et al. Long-term outcome of endoscopic papillotomy for choledocholithiasis with cholecystolithiasis. *Gastrointest Endosc* 2000; 51: 540–545
- [31] Tsuchiya S, Tsuyuguchi T, Sakai Y et al. Clinical utility of intraductal US to decrease early recurrence rate of common bile duct stones after endoscopic papillotomy. *J Gastroenterol Hepatol* 2008; 23: 1590–1595