

## CLINICAL REPORT

# Cohen syndrome in two patients from China

Jiaoe Gong<sup>1</sup> | Lily Zhang<sup>2</sup> | Yanwei Long<sup>2</sup> | Bo Xiao<sup>2</sup> | Hongyu Long<sup>2</sup> <sup>1</sup>Neurology Department, Hunan Children's Hospital, Changsha, China<sup>2</sup>Neurology Department, Xiangya Hospital, Central South University, Changsha, China**Correspondence**

Hongyu Long, Neurology Department, Xiangya Hospital, Central South University, Changsha, Hunan 410008, China.

Email: [longhongyu@csu.edu.cn](mailto:longhongyu@csu.edu.cn)**Funding information**

Hunan Provincial Science and Technology Department, Grant/Award Number: 2019SK1010; National Natural Science Foundation of China, Grant/Award Number: 81974206; Natural Science Foundation of Hunan province, Grant/Award Number: 2021JJ30389 and 2022JJ30945; the Scientific Research project of Hunan Provincial Commission of Health, Grant/Award Number: C20200475; the National Key R&amp;D Program of China, Grant/Award Number: 2021YFC1005305

**Abstract****Background:** Cohen syndrome (CS; OMIM 216550) is a rare syndrome with evident clinical heterogeneity. The diverse phenotype comprises early-onset hypotonia and developmental delays, intellectual disabilities, microcephaly, hypermobile joints, neutropenia, myopia, and characteristic facial features. The disease is rarely reported. Vacuolar Protein Sorting 13 Homolog B (*VPS13B*; OMIM 607817) is the only causative gene of CS.**Methods:** Blood samples sourced from both siblings and parents were sent to identify mutations by trio-WES, and changes in the patient's condition were understood through consultation data and follow-up.**Results:** We reported two siblings affected by developmental delay, microcephaly, intellectual disability, and facial features. The siblings' WES detected compound heterozygous variants in the exon region of *VPS13B* (NM\_017890): c.9337A>T and c.8551A>C.**Conclusion:** Two individuals were diagnosed with CS by genetic testing and clinical features. In addition, we conduct a brief review of the reports on the Chinese population with CS and reinforce the understanding of the correlation between genotype–phenotype.**KEYWORDS**Chinese, Cohen syndrome, compound heterozygous mutation, *VPS13B* gene

## 1 | INTRODUCTION

Cohen syndrome (CS), first reported in 1973 by Cohen et al., is a rare autosomal recessive developmental disorder that is characterized by global developmental delay, intellectual disability, myopia, and neutropenia (1973). Additional, nonobligatory features include microcephaly, hypotonia, joint hypermobility, spindly fingers, and facial features consisting of heavy eyebrows, thick hair, canthus

drooping, short philtrum, and protruding upper incisors. *VPS13B* gene (OMIM 607817) is the sole gene responsible for Cohen Syndrome, located on 8q22.2, encodes a 4022-aminoacid transmembrane protein of the Golgi apparatus which plays a role in intracellular protein transport and vesicle-mediated sorting. Missense or nonsense mutations of the *VPS13B* gene are the cause of CS with more than 150 described mutations in The Human Gene Mutation Database (Kolehmainen et al., 2003, 2004; Momtazmanesh

Jiaoe Gong and Lily Zhang contributed equally to this work.

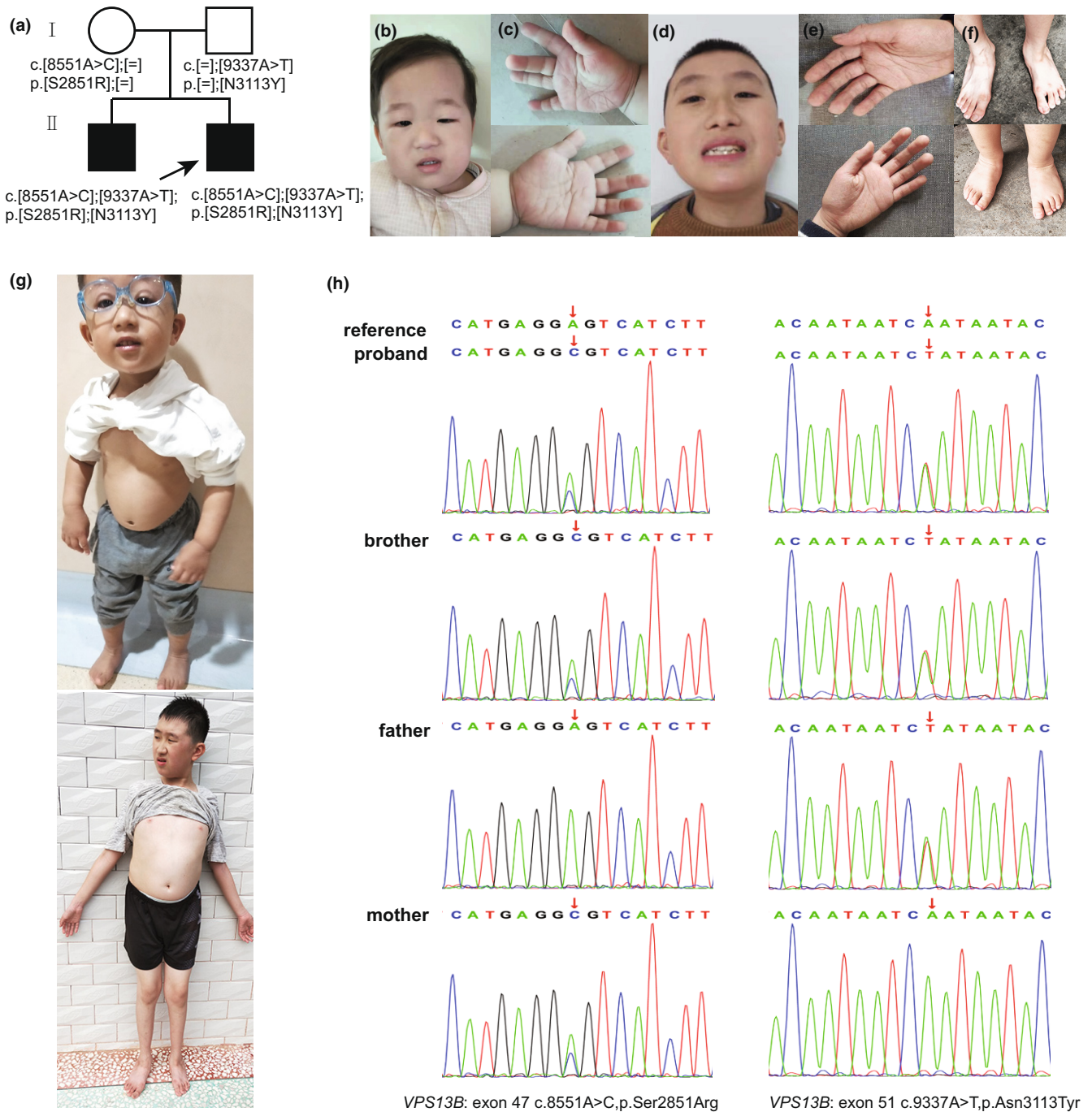
This is an open access article under the terms of the [Creative Commons Attribution-NonCommercial-NoDerivs](https://creativecommons.org/licenses/by-nc-nd/4.0/) License, which permits use and distribution in any medium, provided the original work is properly cited, the use is non-commercial and no modifications or adaptations are made.

© 2022 The Authors. *Molecular Genetics & Genomic Medicine* published by Wiley Periodicals LLC.

et al., 2020; Zhao et al., 2019), while only a few cases associated with CS have been reported in a Chinese family.

Here we performed trio-whole-exome sequencing (trio-WES) in a Chinese family with two siblings affected and identified two compound heterozygous

*VPS13B* mutations (c.9337A>T, p.Asn3113Tyr and c.8551A>C, p.Ser2851Arg). In addition, we summarized *VPS13B* variants and reviewed the clinical features reported among the Chinese population with Cohen syndrome.



**FIGURE 1** (a) Family pedigree. (b) A picture of the proband. Facial features including sparse eyebrows, left ptosis, epicanthus, and mild oblique palpebral fissure. (c) the hyperlinear palms of the proband's hands. (d) A photograph of the older brother. Facial features including bilateral epicanthus, prominent upper middle incisors, and strabismus. (e) slender fingers and hyperlinear palms of the older brother. (f) Flat feet of the two siblings. (g) Slender extremities with truncal obesity of the two siblings. (h) Sanger sequencing electropherograms showing compound heterozygous variants in *VPS13B* (c.8551A>C and c.9337A>T).

## 2 | CASE REPORT

The proband was the second child born to healthy non-consanguineous parents (Figure 1a). He was born of a full-term normal vaginal delivery with normal Apgar scores. The length was 49 cm, birth weight was 3000 g, and occipitofrontal circumference (OFC) was 32 cm. He was admitted into our hospital at 16 months because of a global development delay. Developmental milestones were grossly delayed. He wasn't capable to sit independently till 15 months. The limbs had muscle weakness and hypotonia. He wasn't capable to speak at the age of 16 months. He had overly sociable behavior, like clapping and shaking hands with strangers, and pacing back and forth excitedly. In addition, he had special features including microcephaly (OFC 43 cm), thin eyebrows, left ptosis, mild canthus drooping, epicanthus, amblyopia, and hyperlinear palms (Figure 1b,c). He was found to have intermittent neutropenia (neutrophils count  $0.99 \times 10^9/L$ ), which may explain his frequent colds and pneumonia.

Through ultrasonic cardiogram examination, we found that the boy had a patent foramen ovale. Brain MRI at 3 months showed no abnormality and the eye examination was normal. Hip ultrasound at 3 months showed developmental dysplasia of the hip, classified as Graf type 2a. Amino acid and organic acids in the blood and urinary genetic metabolic screening were all in the normal range. An ophthalmic examination revealed that he had amblyopia at the age of 16 months.

The propositus' older brother was evaluated when he was 12 years old. he exhibits severe mental retardation, microcephaly, hypotonia, truncal obesity with slim limbs, pes planus, strephenopodia, slender fingers, and hyperlinear palms. He had a severe speech delay and had just started to speak a single word like "ba" at the age of 12 years old. He liked to shake hands and hug strangers. In addition, he underwent the WISC-IV scale and was categorized as moderate delay according to the ICD-10 classification for ID. His special facial features include prominent upper central incisors, bilateral epicanthus, strabismus, and

myopia (Figure 1d-f). Both the two siblings had flat feet and truncal obesity with slim limbs relative to the trunk (Figure 1g), although the proband did not show truncal obesity at the age of 16 months.

## 3 | GENETIC ANALYSIS

Blood samples sourced from both siblings and parents were sent to Chigene (Beijing) Translational Medical Research Center for trio-WES (<https://www.chigene.cn/>). The proband's WES detected compound heterozygous variants in the exon region of *VPS13B* (NM\_017890): c.9337A>T and c.8551A>C. The two variations in the *VPS13B* gene were also presented in the brother. The heterozygous missense variant c.9337A>T (p.Asn3113Tyr) was inherited from the father. The other heterozygous missense variant c.8551A>C (p.Ser2851Arg) was inherited from the mother. Sanger sequencing showed that the two *VPS13B* variants present in both siblings were of biparental origin (Figure 1h). Additional CNVseq analysis approach on the proband indicated no microdeletion/duplications that were highly associated with his symptoms. These two variants are classified as variants of uncertain significance according to ACMG guidelines. In addition, the two missense variants were predicted to be deleterious in Provean, Polyphen2, and SIFT. According to the clinical manifestations of the siblings and the principle of familial co-segregation, other variants of the propositus detected by WES were considered non-pathogenic.

## 4 | DISCUSSION

*VPS13B* is a Golgi-associated peripheral membrane protein, which is colocalized with the cis-Golgi matrix protein GM130 and plays an important role in protein sorting and transport mediated by vesicles within the cell. CS is a rare autosomal recessive disease associated with *VPS13B* mutations. CS has a variety of clinical

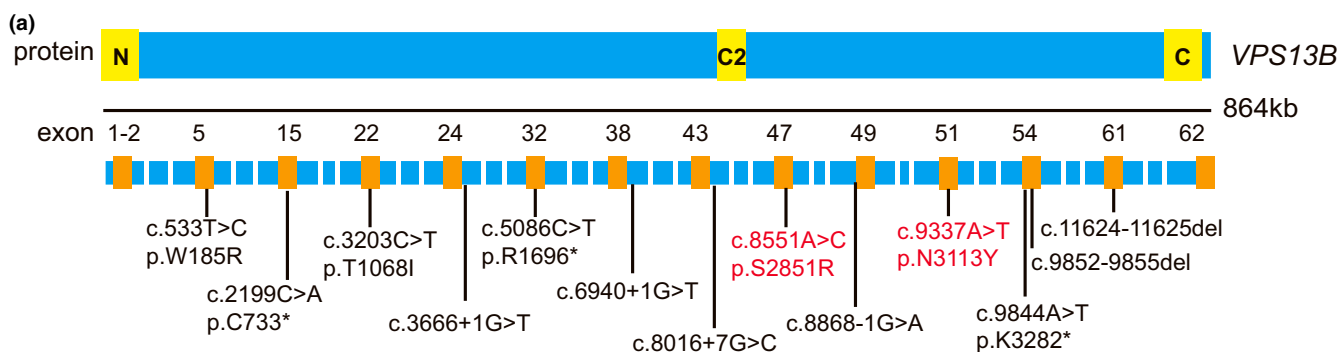


FIGURE 2 (a) A schematic of the transcript and protein indicating the *VPS13B* variants among Chinese families to date.

TABLE 1 Summary of clinical features of patients with VPS13B mutations among Chinese families

Patients	Present case		Zhao et al. (2019)		Yang et al. (2018)		Zhang et al. (2018)		Yin et al. (2016)	
	Het	Het	Het	Het	Het	Het	Het	Het	Het	Het
<b>Types of variants</b>										
<b>VPS13B variants</b>	c.8551A>C	c.8551A>C	c.3666+1G>T	c.3666+1G>T	c.5086 C>T	c.3203C>T	c.2199C>A	c.6940+1 G>T	c.8868-1G>A	c.5086C>T
	c.9337A>T	c.9337A>T	c.9844A>T	c.9844A>T	c.6940+1 G>T	c.8016+7 G>C	c.553 T>C	c.9852-9855del	c.11624_11625del	c.6940+1 G>T
<b>Amino acid change</b>	p.S2851R	p.S2851R	-	-	p.R1696*	p.T1068I	p.C733*	-	-	p.R1696*
	p.N3113Y	p.N3113Y	p.K3282*	p.K3282*	-	-	p.W185R	p.E3287Afs*28	p.V3875Afs*10	-
<b>Sex</b>	M	M	M	F	M	M	M	M	M	M
<b>Microcephaly</b>	(+)	(+)	(+)	(+)	(+)	(-)	(+)	(+)	(+)	(+)
<b>Hypotonia</b>	(+)	(+)	(+)	(+)	(+)	(-)	(-)	(+)	(+)	(+)
<b>Language</b>	(+)	(+)	(+)	(+)	(+)	(+)	(+)	(+)	(+)	(+)
<b>Developmental delay</b>	(+)	(+)	(+)	(+)	(+)	(+)	(+)	(+)	(+)	(+)
<b>Intellectual disability</b>	(+)	(+)	(+)	(+)	(+)	(+)	(+)	(+)	(+)	(+)
<b>Seizure</b>	(-)	(-)	(-)	(-)	(-)	(+)	(-)	(-)	(-)	(-)
<b>Joint hypermobility</b>	(+)	(-)	(+)	(+)	NA	NA	NA	NA	(+)	(+)
<b>Slender fingers</b>	(+)	(+)	(+)	(+)	NA	NA	NA	NA	NA	(+)
<b>Neutropenia</b>	(+)	(-)	(+)	(-)	(+)	(-)	(-)	(-)	(+)	(+)
<b>Ophthalmic test</b>	(-)	(+)	(+)	(-)	(-)	(-)	(-)	(-)	(-)	(-)
<b>Facial features</b>	(+)	(+)	(+)	(+)	(+)	(-)	(+)	(+)	(+)	(+)
<b>Brain MRI</b>	(-)	(-)	(-)	(-)	(+)	(-)	(-)	(+)	(-)	(+)

Note: (+), features present; (-), features absent; Het, heterozygous variants; NA, not applicable or not determined.



manifestations, including mild to severe psychomotor development delay, microcephaly, hypotonia and joint laxity, truncal obesity, a cheerful personality, intermittent neutropenia, and characteristic facial features (Cohen et al., 1973). Approximately, more than 200 cases of CS have been identified to date. Only a few *VPS13B* variants have been reported in Chinese patients diagnosed with CS (Zhao et al., 2019). We review the variants among the Chinese population diagnosed with CS (Figure 2a) and the clinical features reported among the Chinese population with CS. Hyperlinear palms were also found in the two siblings, which supports the hypothesis that the hyperlinear palms maybe a novel phenotype of CS and offer new clues for the diagnosis of CS. Because the clinical heterogeneity and multiple phenotypes of CS are difficult to observe before 10 years old, the diagnosis of CS is not easy until middle and late childhood. Kolehmainen et al. (2004) It has been reported that at least six out of the following eight manifestations presented can confirm the diagnosis of CS, including: (1) myopia and retinal dystrophy; (2) developmental retardation; (3) primary microcephaly; (4) joint hypermobility; (5) special facial features; (6) slender extremities; (7) overly sociable behavior; (8) neutropenia. The proband has 7 features suggestive of CS, microcephaly, developmental delay, joint hypermobility, myopia and retinal dystrophy, overly sociable behavior, neutropenia, and facial features. Truncal obesity with slim limbs of the proband is not evident at present and needs further follow-up. The older brother has 6 CS presentations, microcephaly, developmental delay, facial features, truncal obesity with slim limbs, overly sociable behavior, strabismus, and myopia. Cohen syndrome is a rare autosomal recessive disorder. The phenotypic traits could be lacking till middle or late childhood. In most cases, mutations are stop codon mutations that result in a functionally null protein. Compared to clinical features of patients with predicted loss-of-function variants, the compound heterozygous variants presented in these two siblings are associated with milder symptoms. Brain MRI showed no abnormality, and pigmentary retinopathy wasn't observed by fundus examination. Besides these clinical diagnostic standards, in view of the heterogeneous manifestations, WES is strongly recommended whenever the clinical diagnosis is not evident. WES is a useful diagnostic option in consanguineous families.

In conclusion, here we describe two Chinese siblings with CS carrying compound heterozygous variants in the *VPS13B* gene, and review the variants and clinical features of the Chinese population diagnosed with CS (Table 1). The information presented will increase the *VPS13B* mutational landscape and is useful for genetic counseling to the family.

## AUTHOR CONTRIBUTIONS

JG and LZ performed the research, HL extracted genomic DNA for exome sequencing, YL and BX contributed in study design. LZ analysed the exome sequencing data and wrote the manuscript. All authors read and approved the final manuscript.

## ACKNOWLEDGMENTS

This study was supported by the National Key R&D Program of China (2021YFC1005305), the National Natural Science Foundation of China (81974206), the Natural Science Foundation of Hunan Province (2022JJ30945, 2021JJ30389), the Scientific Research project of Hunan Provincial Commission of Health (C20200475), and the Project of Hunan Provincial Science and Technology Department (2019SK1010). Gratitude is extended to the subject family for their cooperation and participation.

## CONFLICT OF INTEREST

The authors declare that they have no competing interests.

## DATA AVAILABILITY STATEMENT

No data are available.

## ETHICS STATEMENT

The study protocol was approved by the Academic Committee of Hunan Children's Hospital. The Ethics committee approval number is HCHLL-2021-02 for the research project number KS2021-01. Written informed consent was obtained from the patient's father.

## ORCID

Hongyu Long  <https://orcid.org/0000-0001-5641-8850>

## REFERENCES

- Cohen, M. M., Jr., Hall, B. D., Smith, D. W., Graham, C. B., & Lampert, K. J. (1973). A new syndrome with hypotonia, obesity, mental deficiency, and facial, oral, ocular, and limb anomalies. *Journal of Pediatrics*, 83(2), 280–284. [https://doi.org/10.1016/s0022-3476\(73\)80493-7](https://doi.org/10.1016/s0022-3476(73)80493-7)
- Kolehmainen, J., Black, G. C., Saarinen, A., Chandler, K., Clayton-Smith, J., Träskelin, A. L., Perveen, R., Kivitie-Kallio, S., Norio, R., Warburg, M., Fryns, J. P., de la Chapelle, A., & Lehesjoki, A. E. (2003). Cohen syndrome is caused by mutations in a novel gene, *COH1*, encoding a transmembrane protein with a presumed role in vesicle-mediated sorting and intracellular protein transport. *American Journal of Human Genetics*, 72(6), 1359–1369. <https://doi.org/10.1086/375454>
- Kolehmainen, J., Wilkinson, R., Lehesjoki, A. E., Chandler, K., Kivitie-Kallio, S., Clayton-Smith, J., Träskelin, A. L., Waris, L., Saarinen, A., Khan, J., Gross-Tsur, V., Traboulsi, E. I., Warburg, M., Fryns, J. P., Norio, R., Black, G. C., & Manson, F. D. (2004). Delineation of Cohen syndrome following a large-scale genotype-phenotype screen. *American Journal of Human Genetics*, 75(1), 122–127. <https://doi.org/10.1086/422197>

- Momtazmanesh, S., Rayzan, E., Shahkarami, S., Rohlf, M., Klein, C., & Rezaei, N. (2020). A novel VPS13B mutation in Cohen syndrome: A case report and review of literature. *BMC Medical Genetics*, 21(1), 140. <https://doi.org/10.1186/s12881-020-01075-1>
- Zhao, S., Luo, Z., Xiao, Z., Li, L., Zhao, R., Yang, Y., & Zhong, Y. (2019). Case report: Two novel VPS13B mutations in a Chinese family with Cohen syndrome and hyperlinear palms. *BMC Medical Genetics*, 20(1), 187. <https://doi.org/10.1186/s12881-019-0920-x>

**How to cite this article:** Gong, J., Zhang, L., Long, Y., Xiao, B., & Long, H. (2022). Cohen syndrome in two patients from China. *Molecular Genetics & Genomic Medicine*, 10, e2053. <https://doi.org/10.1002/mgg3.2053>