

# Intravitreal Dexamethasone Implant in the Treatment of Non-Infectious Uveitic Macular Edema

Omer Karti <sup>1</sup>, Ali Osman Saatci <sup>2\*</sup>

<sup>1</sup> Department of Ophthalmology, Bozyaka Training and Research Hospital, İzmir, Turkey

<sup>2</sup> Department of Ophthalmology, Dokuz Eylul University, İzmir, Turkey

## ABSTRACT

Macular Edema (ME) is a common complication, leading to severe vision loss in patients with Non-Infectious Uveitis (NIU). The treatment of uveitic ME is still very challenging for many ophthalmologists. Various agents, such as corticosteroids, anti-vascular endothelial growth factors, and immune-modulators, have been used for combatting uveitic ME. However, there is not enough evidence to support the efficacy of any of these agents. Intravitreal Dexamethasone Implant (IDI) (Ozurdex; Allergan Inc, Irvine, CA) is a widely administered corticosteroid for the long-term management of uveitic ME in certain cases. Ophthalmic implant is made up of a biodegradable copolymer that contains glycolic acid and lactic acid. Recent studies have demonstrated that dexamethasone implant effectively improves uveitis-related ME. The authors suggest that this effect could be sustained for at least six months with close monitoring and re-treatment, as needed. The current study reviewed major clinical studies about IDI in eyes with NIU and briefly overviewed their results.

## KEYWORDS

Intravitreal Injection; Dexamethasone Implant; Non-Infectious Uveitis; Macular Edema

©2018, Med Hypothesis Discov Innov Ophthalmol.

This is an open-access article distributed under the terms of the Creative Commons Attribution Non-Commercial 3.0 License (CC BY-NC 3.0), which allows users to read, copy, distribute and make derivative works for non-commercial purposes from the material, as long as the author of the original work is cited properly.

---

## Correspondence to:

Professor Ali Osman Saatci MD, Department of Ophthalmology, Dokuz Eylul University, İzmir, Turkey. E-mail: [osman.saatci@yahoo.com](mailto:osman.saatci@yahoo.com)

**How to cite this article:** Karti O, Saatci AO. Intravitreal Dexamethasone Implant in the Treatment of Non-Infectious Uveitic Macular Edema. Med Hypothesis Discov Innov Ophthalmol. 2018 Winter; 7(4): 169-175.

---

## INTRODUCTION

The term uveitis describes a wide range of inflammatory conditions, affecting uveal tissue. It is responsible for 5% to 20% of blindness in developed countries and 2.8% to 10% of blindness in the working-age population [1-5]. Epidemiological studies have shown that the estimated annual incidence and prevalence of uveitis are nearly 17 to 52/100.000 and 38 to 714/100.000, respectively [6]. Macular Edema (ME) and its sequelae may lead to persistent visual impairment in patients with intermediate or posterior Non-Infectious Uveitis (NIU). Its prevalence varies between 20% and 30%, occurring in

up to 50% of uveitis cases in some clinical trials [7, 8]. The pathophysiological mechanism of ME has not been fully elucidated in uveitis. The breakdown of inner and/or outer blood-retina barrier and/or disturbance in the pumping function of the retinal pigment epithelium is considered as the main mechanism. Constant release of numerous chemical mediators, such as various cytokines (interleukins, tumor necrosis factor  $\alpha$ , etc.), leukotrienes, prostaglandins, nitric oxide, vascular endothelial growth factor, and protein kinase C causes increased retinal vascular permeability that leads to extravasations of the



fluid, proteins, and other macromolecules to the retinal interstitium, which is particularly pronounced at the macula and it may accumulate in cystoid spaces by expanding the extracellular compartments [6, 9-15]. The cystoid spaces were mainly located in the outer retinal layer, and more precisely in the Henle layer [15]. Optical Coherence Tomography (OCT) has provided new insights in the morphological changes occurring in patients with uveitic ME and is widely used in the diagnosis and follow-up of these patients. It is also useful for detecting early ME and the evaluation of response to treatment, even in the presence of severe vitreous haze. Diffuse Macular Edema (DME), Cystoid Macular Edema (CME), and Serous Retinal Detachment (SRD) have been reported as three different OCT patterns of fluid accumulation in uveitic patients [16]. In a study conducted by Lanetti et al. [17], the percentages of CME, DME, and SRD were reported as 58%, 42%, and 28%, respectively.

Treatment of NIU is still very challenging. Steroids have long been used effectively in the control of uveitic inflammation together with other immunosuppressants and/or biological agents. The main immunosuppressive effect of steroids occurs by reducing neutrophil transmigration, cytokine production, and vascular endothelial growth factor production, induced by pro-inflammatory cytokines [18]. It can be administered systemically, topically, and locally [intravitreal and periocular (subconjunctival, orbital floor, and sub-Tenon)] [19]. However, the most effective route of steroid administration is still a matter of debate. Topical steroids cannot control inflammation in intermediate and posterior uveitis, since effective vitreous concentrations cannot be achieved [20]. Although systemic steroids are effective in controlling intraocular inflammation and its complications, prolonged usage may result in undesirable systemic (Cushingoid habitus, weight gain, systemic hypertension, steroid-induced diabetes, osteoporosis, necrosis of the hip, gastrointestinal disturbance, electrolyte imbalance, psychosis, and insomnia) and/or ocular [cataract formation and Increased Intraocular Pressure (IOP)] side effects [20-23]. Local routes have been used to avoid the systemic side effects of steroids and to achieve effective local tissue concentrations. In periocular steroid injections, short-term and uncertain therapeutic drug concentrations are obtained in the vitreous cavity. It may also cause serious ocular complications, such as optic nerve injury, extraocular muscle injury, globe rupture, retinal and/or choroidal vascular occlusion, ptosis, subdermal fat atrophy, and hypopigmentation of periocular skin [24, 25]. Therefore, intravitreal injections have become an accepted

approach to transfer therapeutic agents directly to the choroid and retina. Intravitreal triamcinolone acetonide is still used as an off-label treatment modality in NIU. However, short intraocular half-life, local side effects, such as increase in IOP and development of cataract, usually restricts its use. In the recent years, sustained corticosteroid-release implants have been developed and legally approved for injection in the vitreous cavity. Intravitreal Dexamethasone Implant (IDI) (Ozurdex; Allergan Inc, Irvine, CA) is one of the sustained-release implants approved by the US Food and Drug Administration for treating posterior NIU [21, 24]. It consists of a biodegradable copolymer of glycolic acid and lactic acid that erodes to carbon dioxide and water, while 700 micrograms ( $\mu\text{g}$ ) of dexamethasone is gradually released in the eye [26-29]. The pharmacokinetic features of the implant are responsible for the response pattern. The drug release peaks at two months and then a steady decline occurs that prolongs its effect up to six months [29]. The action mechanism of the dexamethasone is the same as other steroids. It acts by binding to the steroid receptors in the cytoplasm, and then modifying the DNA expression in the cell nucleus.

#### **Clinical Trials of Dexamethasone Implant for Non-Infectious Uveitic Macular Edema**

The major clinical studies examining the effect of IDI on ME in patients with NIU are summarized in Table 1 [21, 24, 30, 31].

HURON (dexamethasone intravitreal implant for non-infectious intermediate or posterior uveitis) was the first prospective randomized sham-controlled trial investigating the efficacy of IDI in patients with intermediate or posterior NIU [24]. In this 26-week study, a significant reduction in Central Macular Thickness (CMT) was detected at week eight and 26 after the first IDI injection. The mean decrease in CMT from baseline was  $-99 \mu\text{m}$  at week eight and  $-50 \mu\text{m}$  at week 26. The authors suggested that the significant improvement in CMT was maintained for six months [24].

Cardoso et al. (30) reported the outcomes of 41 eyes of 31 patients with posterior NIU, treated with IDI. They classified the ME as CME (26 eyes), CME with Sub-Retinal Fluid (SRF) (nine eyes), DME (four eyes), and isolated SRF (two eyes). In this study, one month after the IDI, significant reduction in CMT was observed in most patients. However, CMT showed a deterioration in up to 70% of patients six months after the injection, and 13 eyes required repeat injections. The average time to relapse was 6.7 months (Range, 2 to 15) and overall relapse rate was 83% at 12 months.



Table 1: The Summary of Studies on Non-infectious Uveitic Macular Edema Treatment with Intravitreal Dexamethasone Implant

Study design, sample size and mean or median follow-up after the first injection	Type of uveitis	Number of implant	Changes in central macular thickness during the follow-up period
<b>Pohlmann et al. [32], (2018)</b>			
*Prospective study - *0.70 mg IDI (n:109 eyes) - *22 months (6-44 months)	Intermediate (50%, n:54), posterior (42%, n:46) and panuveitis (8%, n:9)	*Single implant n:31 eyes (28%) - *Multiple implantations n:78 eyes (72%). 2 implants (78 eyes) 3 implants (48 eyes) 4 implants (31 eyes) 5 implants (17 eyes) 6 implants (12 eyes) 7 implants (3 eyes)	*Significant decrease in CMT at 1, 3 and 6 months after first injection - 465 ± 142 μm (at baseline) - 318 ± 80 μm (at 1 month) - 342 ± 92 μm (at 3 months) - 388 ± 106 μm (at 6 months)
<b>Yalcınbayır et al. [33], (2018)</b>			
*Retrospective study - *0.70 mg IDI (n:27 eyes) - *24 months	Posterior uveitis (Behçet disease)	*Single implant n:22 eyes (81%) - *Multiple implantations n:5 eyes (19%). 2 implants (5 eyes)	*Significant decrease in CMT at 1,3,and 6 months - 406 ± 190 μm (at baseline) - 243 ± 101 μm (at 6 months)
<b>Lowder et al. [24], (HURON Study Group) (2011)</b>			
*Prospective study - *0.70 mg IDI (n:77 eyes) - *26 weeks	Intermediate (82%, n:63) and posterior uveitis (18%, n:14)	*Single implant	*Significant reduce in CMT at weeks 8 and 26.
<b>Cardoso et al. [30], (2017)</b>			
*Retrospective study - *0.70 mg IDI (n:41 eyes) - *13.4 months (2-23 months)	Anterior, intermediate and posterior uveitis	*Single implant n:28 eyes (68.3%) - *Multiple implantations n:13 eyes (31.7%). 2 implants (10 eyes) 3 implants (2 eyes) 4 implants (1 eye)	*Significant reduce in CMT at 1 and 3 months - 461 ± 158 μm (at baseline) - 308 ± 93 μm (at 1 month) - 340 ± 110 μm (at 3 months) - 442 ± 172 μm (at 6 months) - 361 ± 108 μm (at 12 months)
<b>Tsang et al. [34], (2017)</b>			
*Retrospective study - *0.70 mg IDI (n:25 eyes) - *270 days (101-582 days)	Anterior, intermediate and posterior uveitis	*Single implant n:18 eyes (72%) - *Multiple implantations n:7 eyes (28%). 2 implants (4 eyes) 3 implants (3 eyes)	*Significant reduction in CMT in 91% of eyes at 3 months. - 590 ± 28 μm at baseline - 380 ± 28 μm at 1 month - 370 ± 31 μm at 3 months - *The median time to recurrence after injection → 6 months.
<b>Khurana et al. [35], (2015)</b>			
*Retrospective Study - *0.70 mg IDI (n:18 eyes) - *12 months	Intermediate uveitis (39%, n:7) Birdshot chorioretinitis (22%, n:4) Sarcoidosis (22%, n:4) Other (17%, n:3)	*Single implant n:8 eyes (44%) - *Multiple implantations (range from 1 to 4) n:10 eyes (56%)	*Complete resolution of CME → 89% of eyes at 1 month. → 72% of eyes at 3 months. * The rate of eyes with no recurrence of CME → 35% at 6 months. → 30% at 12 months. - *The median time to recurrence of CME → 201 days. - *Reccurence time of CME was shorter in eyes with epiretinal membrane present at baseline (110 days).
<b>Sella et al. [21], (2015)</b>			
*Retrospective Study - 0.70 mg IDI (n:14 eyes) - *12 months	Intermediate and posterior uveitis	*Single implant n:9 eyes (64.3%) - *Multiple implantations n:5 eyes (35.7%) 3 implants (5 eyes)	*Significant reduction in CMT at 1 month and 3 months, then increased at 3-6 months.
<b>Bansal et al. [36], (2015)</b>			



Study design, sample size and mean or median follow-up after the first injection	Type of uveitis	Number of implant	Changes in central macular thickness during the follow-up period
*Prospective study - *0.70 mg IDI (n:30 eyes) - *6 months	Anterior, intermediate and posterior uveitis	*Single implant n:27 eyes (90%) - *Multiple implantations n: 3 eyes (10%) 2 implants (3 eyes)	Significant reduction in CMT at week 4, maintained during the follow-up visits up to week 24. - 524 ± 88 µm (at baseline). - 269 ± 41 µm (at 4 weeks) - 274 ± 83 µm (at 12 weeks) - 289 ± 73 µm (at 24 weeks)
<b>Pleyer et al. [37], (2014)</b>			
*Prospective study - *0.70 mg IDI (n:84 eyes) - *6 months	Intermediate (51%, n:43) and posterior uveitis (49%, n:41).	*Single implant	*Significant decrease in CMT at week 4. The effect sustained till at week 24. - 463 ± 164 µm (at baseline) - 299 ± 109 µm (at week 4)
<b>Cao et al. [38], (2014)</b>			
*Retrospective study - *0.70 mg IDI (n:27 eyes) - *14 months (8-27 months)	Anterior, intermediate and posterior uveitis	*Single implant n:4 eyes (15%) - *Multiple implantations n: 23 eyes (85%) 2 implants (7 eyes) ≥3 implants (16 eyes)	*Significant decrease in CMT at week 4, maintained at 3 months. - 478 ± 330 µm (at baseline) - 278 ± 206 µm (at week 4)
<b>Ventura et al. [39], (2014)</b>			
*Retrospective study - *0.70 mg IDI (n:82 eyes) - *12 months	Intermediate uveitis (37.8%, n:31), posterior uveitis (23.1%, n:19), and panuveitis (21.9%, n:18)	*Single implant n:43 eyes (52.4%) - *Multiple implantations n:39 eyes (47.6%). 2 implants (24 eyes) ≥3 implants (15 eyes)	*Reduced in CMT peaked at week 4, but slightly deteriorated till 12 months. - 469 ± 193 µm (at baseline) - 267 ± 74 µm (at 1 month) - 366 ± 140 µm (at 6 months) - 355 ± 160 µm (at 12 months)
<b>Adán et al. [31], (2013)</b>			
*Retrospective study - *0.70 mg IDI (n:17 eyes) - *9.6 months (6-17 months)	Anterior, intermediate, posterior uveitis and panuveitis.	*Single implant - n:9 eyes (53%) - *Multiple implantations n:8 eyes (47%) 2 implants (8 eyes)	Significant reduction in CMT at week 4. The effect maintained at 3 months, but slightly deteriorated till 6 months. - 461 ± 121 µm (at baseline) - 277 ± 66 µm (at week 4) - 349 ± 143 µm (at 3 months) - 394 ± 138 µm (at 6 months)

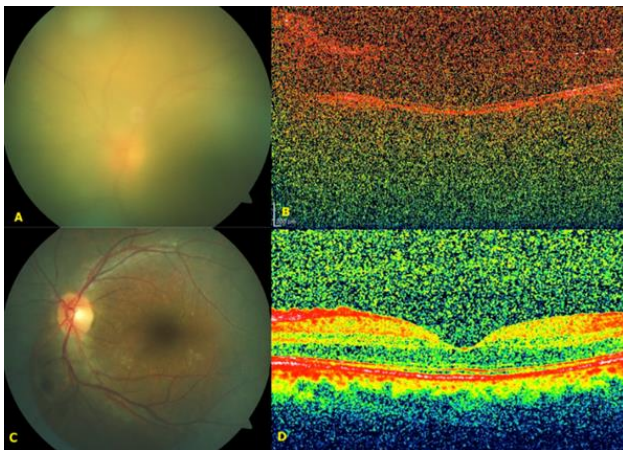
Abbreviations: IDI: Intravitreal Dexamethasone Implant; CMT: Central Macular Thickness; mg: Milligram; µm: Micrometer; n: Number.

In a very recent study conducted by Pohlmann et al. [32], the outcome of 109 eyes of 76 patients with NIU, who underwent IDI (a total of 298 implants) was analyzed, prospectively. More than three dexamethasone implants were injected in 44% of eyes. The CMT decreased significantly from 465 µm at baseline to 318, 342, and 388 µm after one, three, and six months, respectively. Similar trends were seen in eyes receiving a second, third, and fourth dexamethasone implant. The mean time of injection between the first to second, second to third, and third to fourth IDI was reported as 10.3, 8.6, and 9.2 months, respectively. This research reported that CMT decreased markedly at one, three, and six months after the first three IDI. The authors concluded that reduction in CMT, obtained with the first injection, could also be achieved in repeated injections. In this study, the authors noted that the greatest overall benefit was

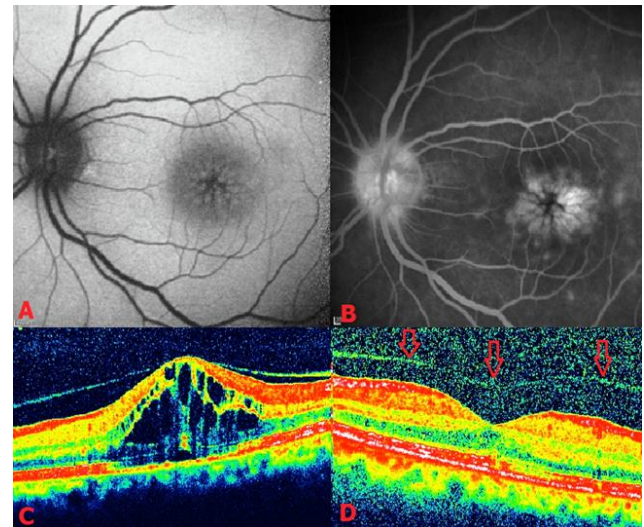
achieved in patients with no systemic treatment and patients receiving antimetabolites and cyclosporine A. In a recent study, Yalcinbayir et al. [33] reported on the results of IDI in uveitic ME, secondary to Behçet's Disease (BD). The authors examined 27 eyes of 20 patients with BD, who received IDI for CME. They reported that CMT was markedly reduced from baseline values at one, three, and six months after the injection. The authors stated that a second implant was required in five eyes within an average of 16 months. The overall number of injections per eye was 1.18. As a consequence of the current study, the authors suggested that IDI was efficacious in reducing ME in Behçet uveitis. Although NIU less commonly occurs in children, it is an important cause of severe visual loss. Periocular corticosteroids, systemic corticosteroids, other systemic antimetabolites and/or biologic agents are often used for



controlling intraocular inflammation. Long-term steroid usage in the pediatric cases causes significant side effects, such as growth retardation, osteoporosis, and other physiological disorders. Therefore, IDI has been used for controlling longer duration of local inflammation in these patients [21]. The use of IDI in the pediatric age group has been limited and a few studies have been conducted on the efficacy of the implant. Sella et al. [21] investigated 14 eyes of 10 patients aged 6.5 to 15 years old with intermediate and posterior NIU, who were poor responders to standard uveitis treatment. They reported that CME was present in ten eyes. The authors demonstrated a decrease in CMT (10 eyes; 100%) between one week and three months after the first injection, followed by a fading treatment effect within three to six months. In this study, five eyes needed repeated injections due to recurrence in ME. The average interval time between two injections was found to be 4.8 months (range, four to six). The authors emphasized that the response pattern after the repeated injections was similar to that of the first injection. Some authors performed pars plana vitrectomy in eyes with resistant uveitic ME [40-42]. Intravitreal drugs in vitrectomized eyes may have a short half-life due to increased drug clearance [41]. In a study comparing the efficacy of IDI on uveitic ME between vitrectomized and non-vitrectomized eyes, the authors showed similar efficacy in terms of reduction in CMT in both groups.



**Figure 1:** Color Fundus and Optical Coherence Tomographic (OCT) Images of the Left Eye of a Patient with Behçet's Disease under Systemic Azathioprine and Cyclosporin Treatment yet still Experiencing a Severe Unilateral Uveitis Attack. Fundus Image of the Left Eye prior to Dexamethasone Implant Administration showing Severe Vitreous Haze (A). OCT could not be Obtained Sufficiently due to Severe Vitritis at the Time (B). Six Weeks after Receiving Intravitreal Dexamethasone Implant, Vitreous Haze was Resolved, Dramatically (C), and Left Macula was Normal, Tomographically (D).



**Figure 2:** Fundus Auto-fluorescence Image obtained from the Left Eye of a Patient with Unilateral Intermediate Uveitis, who did not Receive any Local or Systemic Medical Treatment Depicting Hyperautofluorescence Petaloid Pattern at the Fovea (A). Late Venous Phase of Fluorescein Angiographic Image showing a Typical Petaloid Pattern of Macular Leakage together with Perifoveal Retinal Leakage and late Staining of the Optic Disc (B). Baseline Optical Coherence Tomography (OCT) showed Cystoid Macular Edema and a Serous Macular Detachment (C). Six Weeks after receiving the Intravitreal Dexamethasone Implant, OCT Image delineated an almost Total Improvement in Macular Edema and Separation of the Posterior Hyaloid Membrane following the Injection (Red Arrows) (D).

They stated that this reduction was maintained during the entire follow-up period. The authors emphasized that there was no significant difference between the two groups in terms of the number of injections and the time interval among the injections. They suggested that the median interval between the two injections in both groups was five months [42]. Likewise, in a study conducted by Adán et al. [31], the efficacy of IDI on uveitic ME in vitrectomized eyes was similar to that of non-vitrectomized eyes. Two of the clinical cases treated with IDI are displayed in Figure 1 and 2.

## CONCLUSIONS

Intravitreal Dexamethasone Implant has already found a niche in the treatment armamentarium of uveitic ME, as several papers have demonstrated its undeniable positive effect on uveitic ME. Dexamethasone implant can either be used as a single therapeutic agent in some selected cases or as an adjunct agent to an already ongoing systemic therapy or as a bridging treatment option while changing the systemic agents.

## DISCLOSURE

Ethical issues have been completely observed by the authors. All named authors meet the International



Committee of Medical Journal Editors (ICMJE) criteria for authorship in this manuscript, take responsibility for the integrity of the work as a whole, and have given final approval for the version to be published. No conflict of interest has been presented.

## REFERENCES

1. de Smet MD, Taylor SR, Bodaghi B, Miserocchi E, Murray PI, Pleyer U, et al. Understanding uveitis: the impact of research on visual outcomes. *Prog Retin Eye Res.* 2011;30(6):452-70. doi: [10.1016/j.preteyeres.2011.06.005](https://doi.org/10.1016/j.preteyeres.2011.06.005) pmid: [21807112](https://pubmed.ncbi.nlm.nih.gov/21807112/)
2. Bodaghi B, Cassoux N, Wechsler B, Hannouche D, Fardeau C, Papo T, et al. Chronic severe uveitis: etiology and visual outcome in 927 patients from a single center. *Medicine (Baltimore).* 2001;80(4):263-70. pmid: [11470987](https://pubmed.ncbi.nlm.nih.gov/11470987/)
3. Rothova A, Suttorp-van Schulten MS, Frits Treffers W, Kijlstra A. Causes and frequency of blindness in patients with intraocular inflammatory disease. *Br J Ophthalmol.* 1996;80(4):332-6. pmid: [8703885](https://pubmed.ncbi.nlm.nih.gov/8703885/)
4. Darrell RW, Wagener HP, Kurland LT. Epidemiology of uveitis. Incidence and prevalence in a small urban community. *Arch Ophthalmol.* 1962;68:502-14. pmid: [13883604](https://pubmed.ncbi.nlm.nih.gov/13883604/)
5. Suttorp-Schulten MS, Rothova A. The possible impact of uveitis in blindness: a literature survey. *Br J Ophthalmol.* 1996;80(9):844-8. pmid: [8962842](https://pubmed.ncbi.nlm.nih.gov/8962842/)
6. Goldhardt R, Rosen BS. Uveitic Macular Edema: Treatment Update. *Curr Ophthalmol Rep.* 2016;4(1):30-7. doi: [10.1007/s40135-016-0090-3](https://doi.org/10.1007/s40135-016-0090-3) pmid: [27347446](https://pubmed.ncbi.nlm.nih.gov/27347446/)
7. de Smet MD, Julian K. The role of steroids in the management of uveitic macular edema. *Eur J Ophthalmol.* 2011;21 Suppl 6:S51-5. doi: [10.5301/EJO.2010.6056](https://doi.org/10.5301/EJO.2010.6056) pmid: [23264329](https://pubmed.ncbi.nlm.nih.gov/23264329/)
8. Freeman G, Matos K, Pavesio CE. Cystoid macular oedema in uveitis: an unsolved problem. *Eye (Lond).* 2001;15(Pt 1):12-7. doi: [10.1038/eye.2001.5](https://doi.org/10.1038/eye.2001.5) pmid: [11318279](https://pubmed.ncbi.nlm.nih.gov/11318279/)
9. Durrani OM, Meads CA, Murray PI. Uveitis: a potentially blinding disease. *Ophthalmologica.* 2004;218(4):223-36. doi: [10.1159/000078612](https://doi.org/10.1159/000078612) pmid: [15258410](https://pubmed.ncbi.nlm.nih.gov/15258410/)
10. Forrester JV. Uveitis: pathogenesis. *Lancet.* 1991;338(8781):1498-501. pmid: [1683927](https://pubmed.ncbi.nlm.nih.gov/1683927/)
11. Dick AD. Immune mechanisms of uveitis: insights into disease pathogenesis and treatment. *Int Ophthalmol Clin.* 2000;40(2):1-18. pmid: [10791254](https://pubmed.ncbi.nlm.nih.gov/10791254/)
12. Cordero Coma M, Sobrin L, Onal S, Christen W, Foster CS. Intravitreal bevacizumab for treatment of uveitic macular edema. *Ophthalmology.* 2007;114(8):1574-9 e1. doi: [10.1016/j.ophtha.2006.11.028](https://doi.org/10.1016/j.ophtha.2006.11.028) pmid: [17363060](https://pubmed.ncbi.nlm.nih.gov/17363060/)
13. de Smet MD, Okada AA. Cystoid macular edema in uveitis. *Dev Ophthalmol.* 2010;47:136-47. doi: [10.1159/000320077](https://doi.org/10.1159/000320077) pmid: [20703047](https://pubmed.ncbi.nlm.nih.gov/20703047/)
14. Ossewaarde-van Norel A, Rothova A. Clinical review: Update on treatment of inflammatory macular edema. *Ocul Immunol Inflamm.* 2011;19(1):75-83. doi: [10.3109/09273948.2010.509530](https://doi.org/10.3109/09273948.2010.509530) pmid: [21034302](https://pubmed.ncbi.nlm.nih.gov/21034302/)
15. Catier A, Tadayoni R, Paques M, Erginay A, Haouchine B, Gaudric A, et al. Characterization of macular edema from various etiologies by optical coherence tomography. *Am J Ophthalmol.* 2005;140(2):200-6. doi: [10.1016/j.ajo.2005.02.053](https://doi.org/10.1016/j.ajo.2005.02.053) pmid: [15992752](https://pubmed.ncbi.nlm.nih.gov/15992752/)
16. Markomichelakis NN, Halkiadakis I, Pantelia E, Peponis V, Patelis A, Theodossiadis P, et al. Patterns of macular edema in patients with uveitis: qualitative and quantitative assessment using optical coherence tomography. *Ophthalmology.* 2004;111(5):946-53. doi: [10.1016/j.ophtha.2003.08.037](https://doi.org/10.1016/j.ophtha.2003.08.037) pmid: [15121373](https://pubmed.ncbi.nlm.nih.gov/15121373/)
17. Iannetti L, Accorinti M, Liverani M, Caggiano C, Abdulaziz R, Pivetti-Pezzi P. Optical coherence tomography for classification and clinical evaluation of macular edema in patients with uveitis. *Ocul Immunol Inflamm.* 2008;16(4):155-60. doi: [10.1080/09273940802187466](https://doi.org/10.1080/09273940802187466) pmid: [18716950](https://pubmed.ncbi.nlm.nih.gov/18716950/)
18. Karim R, Sykakis E, Lightman S, Fraser-Bell S. Interventions for the treatment of uveitic macular edema: a systematic review and meta-analysis. *Clin Ophthalmol.* 2013;7:1109-44. doi: [10.2147/OPHTH.S40268](https://doi.org/10.2147/OPHTH.S40268) pmid: [23807831](https://pubmed.ncbi.nlm.nih.gov/23807831/)
19. Venkatesh P, Kumar CS, Abbas Z, Garg S. Comparison of the efficacy and safety of different methods of posterior subtenon injection. *Ocul Immunol Inflamm.* 2008;16(5):217-23. doi: [10.1080/09273940802209153](https://doi.org/10.1080/09273940802209153) pmid: [19065416](https://pubmed.ncbi.nlm.nih.gov/19065416/)
20. Winterhalter S, Behrens UD, Salchow D, Jousen AM, Pleyer U. Dexamethasone implants in paediatric patients with noninfectious intermediate or posterior uveitis: first prospective exploratory case series. *BMC Ophthalmol.* 2017;17(1):252. doi: [10.1186/s12886-017-0648-3](https://doi.org/10.1186/s12886-017-0648-3) pmid: [29246154](https://pubmed.ncbi.nlm.nih.gov/29246154/)
21. Sella R, Oray M, Friling R, Umar L, Tugal-Tutkun I, Kramer M. Dexamethasone intravitreal implant (Ozurdex(R)) for pediatric uveitis. *Graefes Arch Clin Exp Ophthalmol.* 2015;253(10):1777-82. doi: [10.1007/s00417-015-3124-x](https://doi.org/10.1007/s00417-015-3124-x) pmid: [26228441](https://pubmed.ncbi.nlm.nih.gov/26228441/)
22. Sampat KM, Garg SJ. Complications of intravitreal injections. *Curr Opin Ophthalmol.* 2010;21(3):178-83. doi: [10.1097/ICU.0b013e328338679a](https://doi.org/10.1097/ICU.0b013e328338679a) pmid: [20375895](https://pubmed.ncbi.nlm.nih.gov/20375895/)
23. Fassbender Adeniran JM, Jusufbegovic D, Schaal S. Common and Rare Ocular Side-effects of the Dexamethasone Implant. *Ocul Immunol Inflamm.* 2017;25(6):834-40. doi: [10.1080/09273948.2016.1184284](https://doi.org/10.1080/09273948.2016.1184284) pmid: [27379861](https://pubmed.ncbi.nlm.nih.gov/27379861/)
24. Lowder C, Belfort R, Jr., Lightman S, Foster CS, Robinson MR, Schiffman RM, et al. Dexamethasone intravitreal implant for noninfectious intermediate or posterior uveitis. *Arch Ophthalmol.* 2011;129(5):545-53. doi: [10.1001/archophthalmol.2010.339](https://doi.org/10.1001/archophthalmol.2010.339) pmid: [21220619](https://pubmed.ncbi.nlm.nih.gov/21220619/)
25. Ratra D, Barh A, Banerjee M, Ratra V, Biswas J. Safety and Efficacy of Intravitreal Dexamethasone Implant for Refractory Uveitic Macular Edema in Adults and Children. *Ocul Immunol Inflamm.* 2018;1-7. doi: [10.1080/09273948.2018.1424342](https://doi.org/10.1080/09273948.2018.1424342) pmid: [29394119](https://pubmed.ncbi.nlm.nih.gov/29394119/)
26. Haller JA, Dugel P, Weinberg DV, Chou C, Whitcup SM. Evaluation of the safety and performance of an applicator for a novel intravitreal dexamethasone drug delivery system for the treatment of macular edema. *Retina.*



- 2009;29(1):46-51. doi: [10.1097/IAE.0b013e318188c814](https://doi.org/10.1097/IAE.0b013e318188c814) pmid: [18827732](https://pubmed.ncbi.nlm.nih.gov/18827732/)
27. Chang-Lin JE, Attar M, Acheampong AA, Robinson MR, Whitcup SM, Kuppermann BD, et al. Pharmacokinetics and pharmacodynamics of a sustained-release dexamethasone intravitreal implant. *Invest Ophthalmol Vis Sci*. 2011;52(1):80-6. doi: [10.1167/iops.10-5285](https://doi.org/10.1167/iops.10-5285) pmid: [20702826](https://pubmed.ncbi.nlm.nih.gov/20702826/)
28. Kuppermann BD, Blumenkranz MS, Haller JA, Williams GA, Weinberg DV, Chou C, et al. Randomized controlled study of an intravitreal dexamethasone drug delivery system in patients with persistent macular edema. *Arch Ophthalmol*. 2007;125(3):309-17. doi: [10.1001/archophth.125.3.309](https://doi.org/10.1001/archophth.125.3.309) pmid: [17353400](https://pubmed.ncbi.nlm.nih.gov/17353400/)
29. London NJ, Chiang A, Haller JA. The dexamethasone drug delivery system: indications and evidence. *Adv Ther*. 2011;28(5):351-66. doi: [10.1007/s12325-011-0019-z](https://doi.org/10.1007/s12325-011-0019-z) pmid: [21494891](https://pubmed.ncbi.nlm.nih.gov/21494891/)
30. Nobre-Cardoso J, Champion E, Darugar A, Fel A, Lehoang P, Bodaghi B. Treatment of Non-infectious Uveitic Macular Edema with the Intravitreal Dexamethasone Implant. *Ocul Immunol Inflamm*. 2017;25(4):447-54. doi: [10.3109/09273948.2015.1132738](https://doi.org/10.3109/09273948.2015.1132738) pmid: [27003221](https://pubmed.ncbi.nlm.nih.gov/27003221/)
31. Adan A, Pelegrin L, Rey A, Llorens V, Mesquida M, Molins B, et al. Dexamethasone intravitreal implant for treatment of uveitic persistent cystoid macular edema in vitrectomized patients. *Retina*. 2013;33(7):1435-40. doi: [10.1097/IAE.0b013e31827e247b](https://doi.org/10.1097/IAE.0b013e31827e247b) pmid: [23514796](https://pubmed.ncbi.nlm.nih.gov/23514796/)
32. Pohlmann D, Vom Brocke GA, Winterhalter S, Steurer T, Thees S, Pleyer U. Dexamethasone Inserts in Noninfectious Uveitis: A Single-Center Experience. *Ophthalmology*. 2018;125(7):1088-99. doi: [10.1016/j.ophtha.2017.12.038](https://doi.org/10.1016/j.ophtha.2017.12.038) pmid: [29459041](https://pubmed.ncbi.nlm.nih.gov/29459041/)
33. Yalcinbayir O, Caliskan E, Ucan Gunduz G, Gelisken O, Kaderli B, Yucel AA. Efficacy of Dexamethasone Implants in Uveitic Macular Edema in Cases with Behcet Disease. *Ophthalmologica*. 2018;1-5. doi: [10.1159/000490674](https://doi.org/10.1159/000490674) pmid: [30244248](https://pubmed.ncbi.nlm.nih.gov/30244248/)
34. Tsang AC, Virgili G, Abtahi M, Gottlieb CC. Intravitreal Dexamethasone Implant for the Treatment of Macular Edema in Chronic Non-infectious Uveitis. *Ocul Immunol Inflamm*. 2017;25(5):685-92. doi: [10.3109/09273948.2016.1160130](https://doi.org/10.3109/09273948.2016.1160130) pmid: [27191685](https://pubmed.ncbi.nlm.nih.gov/27191685/)
35. Khurana RN, Porco TC. Efficacy and Safety of Dexamethasone Intravitreal Implant for Persistent Uveitic Cystoid Macular Edema. *Retina*. 2015;35(8):1640-6. doi: [10.1097/IAE.0000000000000515](https://doi.org/10.1097/IAE.0000000000000515) pmid: [25741813](https://pubmed.ncbi.nlm.nih.gov/25741813/)
36. Bansal P, Agarwal A, Gupta V, Singh R, Gupta A. Spectral domain optical coherence tomography changes following intravitreal dexamethasone implant, Ozurdex(R) in patients with uveitic cystoid macular edema. *Indian J Ophthalmol*. 2015;63(5):416-22. doi: [10.4103/0301-4738.159870](https://doi.org/10.4103/0301-4738.159870) pmid: [26139803](https://pubmed.ncbi.nlm.nih.gov/26139803/)
37. Pleyer U, Klamann M, Laurent TJ, Manz M, Hazirolan D, Winterhalter S, et al. Fast and Successful Management of Intraocular Inflammation with a Single Intravitreal Dexamethasone Implant. *Ophthalmologica*. 2014. doi: [10.1159/000368987](https://doi.org/10.1159/000368987) pmid: [25428335](https://pubmed.ncbi.nlm.nih.gov/25428335/)
38. Cao JH, Mulvahill M, Zhang L, Joondeph BC, Dacey MS. Dexamethasone intravitreal implant in the treatment of persistent uveitic macular edema in the absence of active inflammation. *Ophthalmology*. 2014;121(10):1871-6. doi: [10.1016/j.ophtha.2014.04.012](https://doi.org/10.1016/j.ophtha.2014.04.012) pmid: [24907061](https://pubmed.ncbi.nlm.nih.gov/24907061/)
39. Zarranz-Ventura J, Carreno E, Johnston RL, Mohammed Q, Ross AH, Barker C, et al. Multicenter study of intravitreal dexamethasone implant in noninfectious uveitis: indications, outcomes, and reinjection frequency. *Am J Ophthalmol*. 2014;158(6):1136-45 e5. doi: [10.1016/j.ajo.2014.09.003](https://doi.org/10.1016/j.ajo.2014.09.003) pmid: [25217856](https://pubmed.ncbi.nlm.nih.gov/25217856/)
40. Wiechens B, Nolle B, Reichelt JA. Pars-plana vitrectomy in cystoid macular edema associated with intermediate uveitis. *Graefes Arch Clin Exp Ophthalmol*. 2001;239(7):474-81. pmid: [11521690](https://pubmed.ncbi.nlm.nih.gov/11521690/)
41. Heiligenhaus A, Bornfeld N, Wessing A. Long-term results of pars plana vitrectomy in the management of intermediate uveitis. *Curr Opin Ophthalmol*. 1996;7(3):77-9. pmid: [10163465](https://pubmed.ncbi.nlm.nih.gov/10163465/)
42. Pelegrin L, de la Maza MS, Molins B, Rios J, Adan A. Long-term evaluation of dexamethasone intravitreal implant in vitrectomized and non-vitrectomized eyes with macular edema secondary to non-infectious uveitis. *Eye (Lond)*. 2015;29(7):943-50. doi: [10.1038/eye.2015.73](https://doi.org/10.1038/eye.2015.73) pmid: [25998942](https://pubmed.ncbi.nlm.nih.gov/25998942/)