

Prevalence of Premolars with Dens Evaginatus in a Taiwanese and Spanish Population and Related Complications of the Fracture of its Tubercle

 Chia-Shiuan LIN,
  Maria LLACER-MARTINEZ,
  Chirag C SHETH,
  Mar JOVANI-SANCHO,
  Benjamín MARTÍN BIEDMA

ABSTRACT

Objective: Dens evaginatus (DE) is an odontogenic developmental anomaly that can be defined as a supernumerary tubercle structure that extends from the occlusal surface of the affected tooth. Tubercular fracture or attrition of the tubercle, invaded by pulp tissue, may cause various pulpal diseases, such as pulpitis, pulp necrosis, and periapical periodontitis. This study aimed to determine the prevalence of premolars with DE in Taiwanese and Spanish study populations and to report associated dental complications.

Methods: This study was based on the clinical examination of volunteers of Spanish and Taiwanese origin, recruited among the undergraduate dentistry students at CEU-Cardenal Herrera University, Valencia, Spain. Informed consents were obtained from students identified with DE. Additional examinations were performed, including vitality test, percussion, palpation, and radiographs, to diagnosis the status of the pulp and periapical tissue.

Results: The prevalence of DE among Taiwanese students was 4.08%, compared to 0% in the Spanish Caucasian group. In the Taiwanese group, the occurrence of DE in premolars was more common in the mandibular (78.9%) compared to the maxillary region (21.1%). In 84% of the cases, DE-affected teeth were found bilaterally. The mandibular second premolar was the most commonly involved tooth (57.8%). When investigating the complications related to DE among six affected Taiwanese students, it was found that two teeth (10.5%) had received pulp treatment, one of them prior to complete root formation.

Conclusion: DE appears to be more prevalent in people of Mongoloid origin and rare in those of Caucasian origin. The wear or fracture of DE may affect pulpal tissue, leading to incomplete root growth.

Keywords: Complication, dens evaginatus, premolar, prevalence, tubercle fracture

Please cite this article as: Lin CS, Llacer-Martinez M, Sheth CC, Jovani-Sancho M, Martín Biedma B. Prevalence of Premolars with Dens Evaginatus in a Taiwanese and Spanish Population and Related Complications of the Fracture of its Tubercle. *Eur Endod J* 2018; 2: 118-22

From the Department of Dentistry (M.J.S. ✉ marjovani@uchceu.es, C.S.L., M.L.M.) Facultad de Ciencias de la Salud, Universidad Cardenal Herrera-CEU, CEU Universities, Valencia, Spain; Department of Biomedical Sciences, (C.C.S.), Facultad de Ciencias de la Salud, Universidad Cardenal Herrera-CEU, CEU Universities, Valencia, Spain; Department of Surgery, (B.M.B.), School of Medicine and Dentistry, University of Santiago de Compostela, Spain

Received 09 June 2018, last revision received 13 June 2018, accepted 13 June 2018

Published online: 19 July 2018
DOI 10.14744/eej.2018.08208

HIGHLIGHTS

- Dens evaginatus (DE) is an odontogenic developmental anomaly defined as a supernumerary tubercular structure or supplemental solid elevation on the crown surface, extending away from the occlusal surface of the affected tooth. It consists of an outer layer of enamel and a core of dentin, sometimes containing a slender extension of pulp tissue. The presence of pulp within the cusp-like tubercle is of great clinical importance.
- The prevalence of DE varies between 0.1% to 15% depending on race and differences in diagnostic criteria. In the present study, DE-affected premolars were detected in 6 out of 147 Taiwanese students with a prevalence of 4.1%, and 0% in Spanish students. These patterns support a strong genetic etiological component for DE, supporting previous observations suggesting that DE anomalies are highly heritable processes.
- Approximately 1.1% of DE-affected teeth eventually develop dental complications. The wear of this tubercle can result in pulpal affectation with incomplete root formation.

INTRODUCTION

The tooth, an essential part of the oral cavity, is susceptible to morphological anomalies during its development, which may eventually lead to pathological processes. Developmental dental anomalies are highly heritable, arising from genetic and environmental factors, leading to marked deviations from the standard morphology (1-3).

Dens evaginatus (DE) is an odontogenic developmental anomaly defined as a supernumerary tubercular structure or supplemental solid elevation on the crown surface, extending away from the occlusal surface of the affected tooth (Fig. 1) (4-8). It comprises an outer layer of enamel and a core of dentine, sometimes containing a slender extension of pulp tissue (Fig. 2a). The most common form of DE is characterized as an extra cusp (9, 10). The

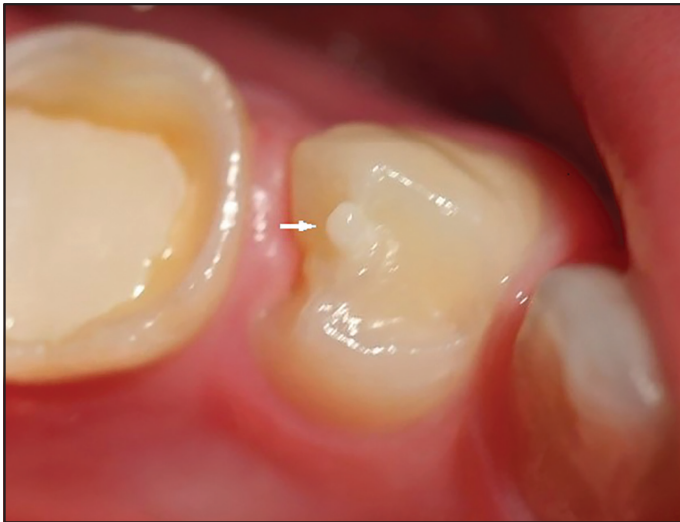

Figure 1. Clinical photograph showing a first lower premolar with dens evaginatus (tooth 34), partially erupted. Its intact tubercle can be observed on the occlusal surface

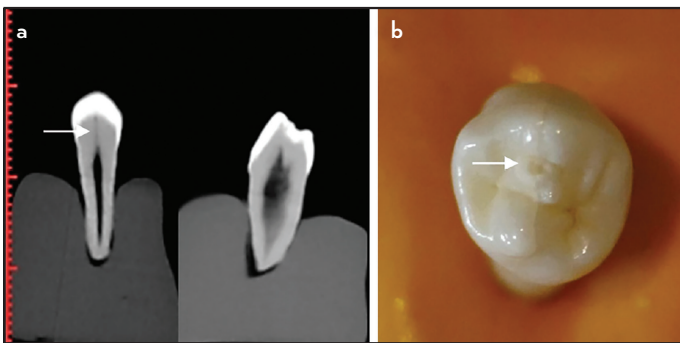


Figure 2. (a) CBCT images of an extracted first lower premolar with dens evaginatus where a thin coronal extension of pulp tissue can be noted (arrow). Coronal and sagittal views are presented. (b) Photograph of its occlusal surface where a fractured or worn down tubercle can be observed

presence of pulp tissue within the cusplike tubercle may have a clinical significance (11).

This condition is clinically important since DE may lead to several problems, such as tongue movement irritation and occlusal interferences, which may cause accidental cusp fracture (Fig. 2b), temporomandibular joint pain, and periodontium damage as a result of excessive occlusal force (11-13). Moreover, severe attrition or fracture of the protuberance frequently leads to pulp necrosis and apical periodontitis, often prior to complete root formation. Such patients usually require corrective endodontic procedures, such as apexification and subsequent obturation in teeth with immature apices, or tooth removal (14).

DE occurs most frequently in premolars, particularly in the mandibular second premolar (15). It occurs in both primary and permanent dentition and is more common in mandibular premolars than maxillary premolars. Bilateral involvement of collateral teeth has been observed in approximately 50% of cases (16).

DE occurs in a broad range of different ethnic groups (3, 9, 13-14), with an elevated prevalence in people of Mongoloid origin (Chinese, Japanese, Malays, Filipinos, specific Eskimos, American Indians, and Aleuts), with a prevalence of up to 4.3% (8), being higher in Nigerian and Turkish people (approximately 6%) (12, 17). A prevalence of 2.4% has been reported in a study of an Indian population (18); however, Yip did not find any cases within a cohort of 225 Indo-Europeans (4). In Caucasians, DE is considered a rare anomaly, although some individual cases have been observed (4, 13).

The distribution of prevalence may provide important information for genetic studies and assist in the understanding of racial differences in populations (14). The causes of DE are multifactorial, with some studies suggesting an autosomal dominant, X-linked inheritance pattern (3, 6, 8), whereas others have described the impact of environmental factors on the formation of DE (8, 19). However, the exact aetiology for the formation of this anomaly is still undetermined (13).

Globalization and increased migratory movements have resulted in regional and local communities experiencing a greater mixing of people of different races and backgrounds (11). Therefore, it is in the interest of community dentists to increase their awareness of this clinical condition to provide information to the patient regarding preventive, hygienic, and therapeutic measures for the management of DE (14).

The main purpose of this study was to determine the prevalence and pattern of distribution of premolars exhibiting DE in a Taiwanese and Spanish study population and to report associated dental complications.

MATERIALS AND METHODS

This research has been conducted in full accordance with the World Medical Association Declaration of Helsinki and has been independently reviewed and approved by the Universidad CEU-Cardenal Herrera Ethics Committee (Ref: 16/014).

The present study was based on the clinical examination of the oral cavity of undergraduate dentistry student volunteers from CEU-Cardenal Herrera University, Valencia, Spain. Students enrolled between 2010 and 2017 were included in the study. Written consents were obtained prior to participation in the study.

The inclusion criteria were restricted participation to Asian (Taiwanese) and Caucasian (Spanish) students. Participants with dental anomalies secondary to oral structure were excluded.

Demographic data of the study volunteers were recorded as well as the number and distribution of premolars with DE. In the absence of a defined tubercle, a positive identification of DE was also applied to teeth exhibiting a circular area of exposed dentine on the occlusal surface, denoting the presence of a previous tubercle, currently fractured or worn down (9). The dental history of students was reviewed, and after obtaining the written consents, students with teeth having DE were examined further for vitality tests, palpation, percussion, and periodontal exploration. Periapical radiographic views of DEaffected teeth were examined.

Patient demographic data were analyzed using descriptive statistics. The mean age and prevalence of students with DE were calculated. The percentage distribution of DE in maxillary and mandibular arches was calculated, and chi-squared analysis was performed.

RESULTS

Two identically sized groups of age- and sex-matched Taiwanese and Caucasian students were compared in this study. A total of 147 Taiwanese and 147 Spanish students were successfully recruited. The age of the students ranged between 18 and 39 years with a mean age of 23.3 years (SD=3.9). Most of the students were 21–25 years old at the time of dental examination (Table 1).

A total of 2058 premolars were examined during this study: 1004 teeth in Taiwanese students and 1054 teeth in Spanish students. 19 premolars in the Taiwanese group were found to be DE-affected, whereas the anomaly was not identified in the Caucasian group. One or more premolars with DE were detected in 6 of the 147 Taiwanese students, with an overall prevalence of 4.1% [sex-specific prevalence; five females (6.2%) and one male (1.5%)]. The overall male-to-female ratio was 1:5; however, there was no statistically significant difference ($P>0.05$) in the gender distribution (Table 1). The prevalence of DE-affected teeth and the relationship between DE and gender were analyzed using a chi-squared test. Detailed notes were taken of dental arch location, pulp status, periodontal status, periapical status, presence of syndromes, and previous treatment.

The analysis of the distribution of DE-affected teeth to different dental arches revealed that the left-to-right ratio was 1:1 and that the occurrence of DE was significantly ($P<0.05$) higher in the mandible (78.8%) compared to the maxilla (21.2%). The mandibular second premolar (57.8%) was the most commonly affected tooth (Table 2).

The six DE-affected students were further evaluated by the diagnosis of complications related to DE. In these students, percussion test revealed no pain, and palpation showed an absence of pain or swelling. No widening of the periodontal ligament or periapical lesions was found, with the exception

of one student who had been previously diagnosed with an inflammatory cyst. With the exception of two, all teeth responded normally to cold in the vitality test. The two non-responsive teeth had received previous pulpal treatments. One tooth received partial pulpotomy when the patient was 14 years old due to a complaint of severe pain related to her non-carious left mandibular second premolar. (Fig. 3). The second non-responsive tooth (also left a mandibular second premolar) received revascularization treatment due to the presence of a fistula 1 year prior to this study, as a result of pulp necrosis arising from the fracture of the tubercle. Three months later,

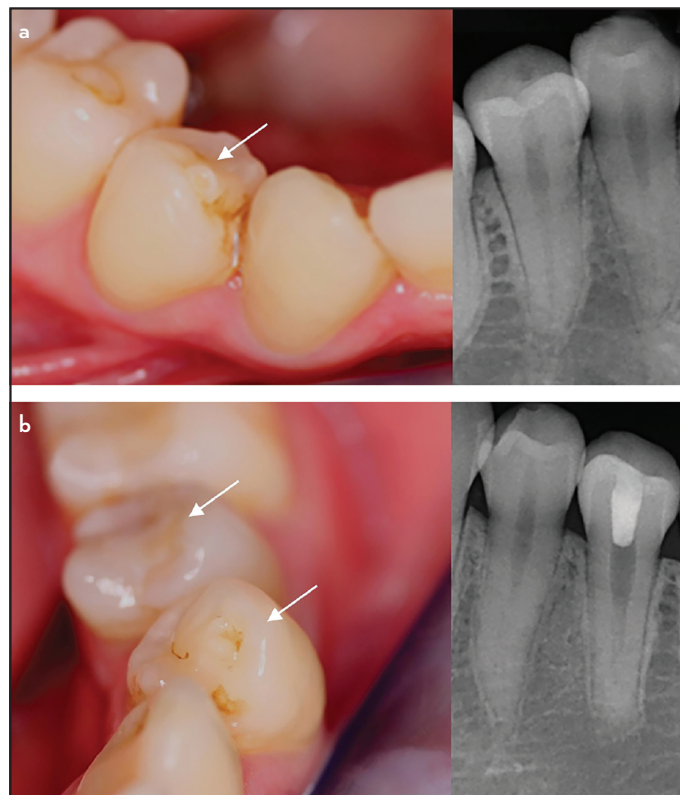


Figure 3. (a) Occlusal view of wearing down in the buccal cusp of 4.4 and periapical radiograph. (b) Occlusal view of the wearing down in the buccal cusp of 3.4 and 3.5, and periapical radiograph of tooth 3.4 and 3.5 showing the presence of a pulpotomy treatment on 3.5. Arrow indicates DE tubercle

TABLE 1. Socio-demographic data of study volunteers

Students	Number	Gender	Average age	Present DE	Prevalence
Taiwanese	147	66 male, 81 female	23.3	6 (1 male, 5 female)	4.1%
Spanish	147	69 male, 78 female	24.2	0	0%

TABLE 2. DE-affected premolar distribution in maxillary and mandibular arches

Tooth affected	No.(right)	%	No. (left)	%	Subtotal	%
Maxillary first premolars	1	5.3%	1	5.3%	2	10.6%
Maxillary second premolars	1	5.3%	1	5.3%	2	10.6%
Mandibular first premolars	2	10.5%	2	10.5%	4	21.0%
Mandibular second premolars	5	26.3%	6	31.5%	11	57.8%
Total	9	47.4%	10	52.6%	19	100%

P value=0.012

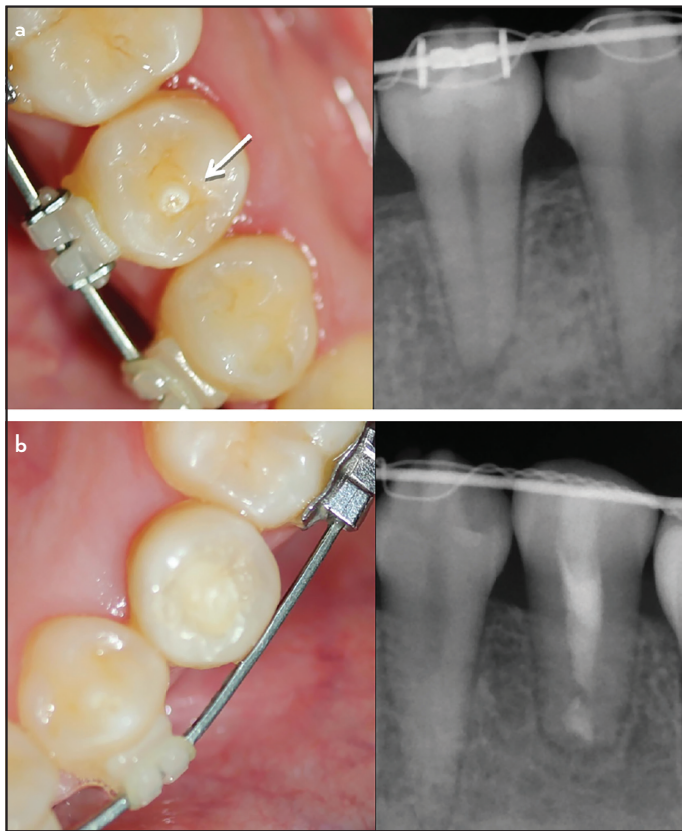


Figure 4. (a) Clinical photograph showing an occlusal tubercle consistent with dens evaginatus in 4.5 and periapical radiograph. (b) Occlusal view of the occlusal filling in 3.5, and periapical radiograph 1 year after having received apical surgery. Arrow indicates DE tubercle

apical surgery was performed due to the recurrence of the fistula. Up to date of check-up examination, both teeth was in function and free of symptoms (Fig. 4).

DISCUSSION

Although there have been several studies reporting the prevalence of DE in people of Mongoloid and Caucasian origin (5, 7, 13, 14), to the best of our knowledge, no study has been conducted on the prevalence of DE in Taiwanese and Spanish populations.

The prevalence of DE ranges from 0.1% to 15% depending on race and differences in diagnostic criteria (3-7, 12-14). In the present study, DE-affected premolars were detected in 6 of 147 Taiwanese students, with a prevalence of 4.1%, and the prevalence in Spanish students was 0%. These patterns support a strong genetic etiological component for DE, supporting previous observations suggesting that DE is a hereditary developmental anomaly (13).

This study showed that the occurrence of DE was significantly ($P < 0.05$) more common in the mandible (78.8%) compared to the maxilla (21.2%). This is in agreement with results of previous studies (1, 2, 4, 6-9, 16, 19, 20). Moreover, several authors have reported a higher frequency of DE in mandibular second premolars (22-25), which support results of the present study. Furthermore, one study (2) showed that DE anomaly is bilateral, which agrees with our observations. Because of the

frequent bilateral occurrence of these anomalies, the symmetrical teeth must also be included in the clinical examination.

A recent study by Shanthy et al. (23) described the bilateral involvement of collateral teeth in approximately 50% of cases, with a slight bias toward females. Our study results coincide strongly with these data, in which female students demonstrated a higher prevalence of DE-affected teeth than males, although these differences were not statistically significant ($P = 0.155$).

Reports (2, 4-9, 16-20, 22, 27) showed that DE-affected teeth are more prone to pulpal diseases, such as pulpitis, pulp necrosis, and periapical periodontitis, as a result of tubercular fracture or the attrition of pulp-containing tubercles. Current practice recommends timely prophylactic interventions (2, 22, 27) to avoid pulp necrosis, particularly in those with incomplete root development (8).

Recommended prophylactic treatments include selective grinding of the tubercles to allow the formation of reparative dentine avoiding pulp exposure; the application of resin to reinforce the tubercles; if the tubercle was accidentally fractured and dentine is exposed, the placement of cavity liners prior to resin composite, or cavity preparations followed by partial pulpotomy procedures are considered as possible treatment options (2, 27-30). The latter treatment option had been applied to one student in the present study in response to a complaint of severe pain.

When a pulp exposure exists in a tooth with complete root formation, root canal treatment is indicated, but if the apex is immature, techniques to promote apexification are recommended (30). Nowadays, revascularization technique would be another viable option.

DE is a developmental anomaly having clinical implications. Dental practitioners should be able to diagnose it as early as possible and treat the affected teeth effectively. Early treatment provides the greatest opportunity for complete root development, avoiding pathological conditions. Regular examinations of individuals with DE-affected teeth may assist dentists in optimizing complete root formation and maintaining pulp vitality (24).

Therefore, it is important for clinicians to familiarize themselves with this clinical condition to improve diagnosis and provide the correct information to the patient. Approximately 1.1% of DE-affected teeth eventually develop dental complications. The wear of this tubercle can result in pulpal affectation with incomplete root formation; a fact that can severely influence the survival of teeth. An increased awareness of this anomaly will allow dentists to make the correct decision regarding preventive and therapeutic strategies.

Disclosures

Conflict of interest: No conflict of interest was declared by the authors.

Ethics Committee Approval: This research has been conducted in full accordance with the World Medical Association Declaration of Helsinki and has been independently reviewed and approved by the Universidad CEU-Cardenal Herrera Ethics Committee (Ref: 16/014).

Peer-review: Externally peer-reviewed.

Financial Disclosure: The authors declared that this study has received no financial support.

Authorship contributions: Concept – C.S.L., M.J.S.; Design – C.S.L., M.L.M., C.C.S., M.J.S., B.M.B.; Supervision – M.J.S., B.M.B.; Resources – C.S.L., M.L.M.; Materials – C.S.L., M.L.M.; Data collection &/or processing – C.S.L., M.L.M., C.C.S.; Analysis and/or interpretation – C.S.L., M.L.M., C.C.S.; Literature search – C.S.L., M.L.M., M.J.S.; Writing – C.S.L., M.L.M., C.C.S., M.J.S., B.M.B.; Critical Review – C.S.L., M.L.M., C.C.S., M.J.S., B.M.B.

REFERENCES

- Priya M, Muthu MS, Jeevarathan J, Rathnaprabhu V. Unusual dens evaginatus on maxillary premolars: a case report. *J Dent Child (Chic)* 2011; 78(1):71–5.
- Koh ET, Ford TR, Kariyawasam SP, Chen NN, Torabinejad M. Prophylactic treatment of dens evaginatus using mineral trioxide aggregate. *J Endod* 2001; 27(8):540–2.
- Curzon ME, Curzon JA, Poyton HG. Evaginated odontomes in the Keewatin Eskimo. *Br Dent J* 1970; 129(7):324–8.
- Yip WK. The prevalence of dens evaginatus. *Oral Surg Oral Med Oral Pathol* 1974; 38(1):80–7.
- Bedi R, Pitts NB. Dens evaginatus in the Hong Kong Chinese population. *Endod Dent Traumatol* 1988; 4(3):104–7.
- Tsai SJ, King NM. A catalogue of anomalies and traits of the permanent dentition of southern Chinese. *J Clin Pediatr Dent* 1998; 22(3):185–94.
- Stewart RE, Dixon GH, Graber RB. Dens evaginatus (tuberculated cusps): genetic and treatment considerations. *Oral Surg Oral Med Oral Pathol* 1978; 46(6):831–6.
- Levitan ME, Himel VT. Dens evaginatus: literature review, pathophysiology, and comprehensive treatment regimen. *J Endod* 2006; 32(1):1–9.
- Yong SL. Prophylactic treatment of dens evaginatus. *ASDC J Dent Child* 1974; 41(4):289–92.
- Lim ST, Yong SL, Chen ML. A review of the prophylactic treatment of dens evaginatus. *J Int Assoc Dent Child* 1982; 13(1):21–5.
- Archana JP, Prabhakaran AC. Nonsteroidal anti-inflammatory drugs misleading the diagnosis of periapical abscess. *J Nat Sci Biol Med* 2012; 3(1):84–6.
- Temilola DO, Folayan MO, Fatusi O, Chukwumah NM, Onyejaka N, Oziegbe E, et al. The prevalence, pattern and clinical presentation of developmental dental hard-tissue anomalies in children with primary and mix dentition from Ile-Ife, Nigeria. *BMC Oral Health* 2014; 14:125.
- Palmer ME. Case reports of evaginated odontomes in Caucasians. *Oral Surg Oral Med Oral Pathol* 1973; 35(6):772–9.
- Merrill RG. Occlusal anomalous tubercles on premolars of alaskan eskimos and indians. *Oral Surg Oral Med Oral Pathol* 1964; 17:484–96.
- Reynolds K, Johnson JD, Cohenca N. Pulp revascularization of necrotic bilateral bicuspidids using a modified novel technique to eliminate potential coronal discoloration: a case report. *Int Endod J* 2009; 42(1):84–92.
- Cho SY. Supernumerary premolars associated with dens evaginatus: report of 2 cases. *J Can Dent Assoc* 2005; 71(6):390–3.
- Uslu O, Akcam MO, Evirgen S, Cebeci I. Prevalence of dental anomalies in various malocclusions. *Am J Orthod Dentofacial Orthop* 2009; 135(3):328–35.
- Gupta SK, Saxena P, Jain S, Jain D. Prevalence and distribution of selected developmental dental anomalies in an Indian population. *J Oral Sci* 2011; 53(2):231–8.
- Senia ES, Regezi JA. Dens evaginatus in the etiology of bilateral periapical pathologic involvement in caries-free premolars. Abbreviated case report. *Oral Surg Oral Med Oral Pathol* 1974; 38(3):465–8.
- Geist JR. Dens evaginatus. Case report and review of the literature. *Oral Surg Oral Med Oral Pathol* 1989; 67(5):628–31.
- Davis PJ, Brook AH. The presentation of talon cusp: diagnosis, clinical features, associations and possible aetiology. *Br Dent J* 1986; 160(3):84–8.
- Morinaga K, Aida N, Asai T, Tezen C, Ide Y, Nakagawa K. Dens evaginatus on occlusal surface of maxillary second molar: a case report. *Bull Tokyo Dent Coll* 2010; 51(3):165–8.
- Viswanathan S, Nagaraj V, Adimoulame S, Kumar S, Khemaria G. Dens evaginatus in proximal surface of mandibular premolar: a rare presentation. *Case Rep Dent* 2012; 2012:603583.
- Augsburger RA, Wong MT. Pulp management in dens evaginatus. *J Endod* 1996; 22(6):323–6.
- Ohno K, Nomura T, Sato A, Ohmori I. Dens evaginatus in the permanent dentition and the clinical management. *Jpn J Ped Dent* 1996; 34:842–8.
- Lau TC. Odontomes of the axial core type. *Br Dent J* 1955; 99:219–25.
- Oehlers FA, Lee KW, Lee EC. Dens evaginatus (evaginated odontome). Its structure and responses to external stimuli. *Dent Pract Dent Rec* 1967; 17(7):239–44.
- Cervino G, Fiorillo L, Spagnuolo G, Bramanti E, Laino L, Lauritano F, et al. Interface Between MTA and Dental Bonding Agents: Scanning Electron Microscope Evaluation. *J Int Soc Prev Community Dent* 2017; 7(1):64–8.
- Segura-Egea JJ, Jiménez-Rubio A, Velasco-Ortega E, Ríos-Santos JV. Talon cusp causing occlusal trauma and acute apical periodontitis: report of a case. *Dent Traumatol* 2003; 19(1):55–9.
- Chu FC, Sham AS, Yip KH. Fractured dens evaginatus and unusual periapical radiolucency. *Dent Traumatol* 2002; 18(6):339–41.