

Contents lists available at [ScienceDirect](#)

International Journal of Surgery Case Reports

journal homepage: www.casereports.com

A case of intra-abdominal hemorrhage secondary to peliosis hepatis

Ross O. Downes^{a,*}, Craig L. Cambridge^b, Charles Diggiss^c, James Iferenta^d, Muneesh Sharma^e^a General Surgery, Laparoscopy Bsc MB BS DM Doctors Hospital, Nassau, Bahamas^b Medical Student/Research Assistant Doctors Hospital, Nassau, Bahamas^c General Surgery, Bariatrics FRCS CMO Doctors Hospital, Nassau, Bahamas^d Emergency Services, FRCS F IAS Doctors Hospital, Nassau, Bahamas^e Radiology Doctors Hospital, Nassau, Bahamas

ARTICLE INFO

Article history:

Received 17 June 2014

Received in revised form

19 December 2014

Accepted 20 December 2014

Available online 30 December 2014

Keywords:

Intra-abdominal hemorrhage

Peliosis hepatis

Acute abdomen

Hepatic disease

ABSTRACT

INTRODUCTION: peliosis hepatis (PH) is a rare vascular condition of the liver characterized by the presence of cystic blood filled cavities distributed randomly throughout the liver parenchyma Tsokos and co-workers [1–6]. Peliosis is most commonly found in the liver but can also involve the spleen, bone marrow, lungs, and abdominal lymph nodes Tsokos and Erbersdobler [1].

PRESENTATION OF CASE: We report a case of peliosis hepatis diagnosed post laparotomy. She required a re-look laparotomy with removal of packs peritoneal lavage, placement of intraseed and subhepatic drain. The patient was discharged after an 11-day recovery period.

CONCLUSION: We examine the literature and subsequently discuss the etiology and management of peliosis. Peliosis is a rare vascular condition of the liver characterized by the presence of cystic blood filled cavities. Causes are associated with a number of conditions, however, etiology is largely unknown. Management is overwhelmingly conservative except in a handful of cases.

© 2014 The Authors. Published by Elsevier Ltd. on behalf of Surgical Associates Ltd. This is an open access article under the CC BY-NC-SA license (<http://creativecommons.org/licenses/by-nc-sa/4.0/>).

1. Introduction

Peliosis hepatis (PH) is a rare vascular condition of the liver characterized by the presence of cystic blood filled cavities distributed randomly throughout the liver parenchyma [1]. Peliosis is most commonly found in the liver but can also involve the spleen, bone marrow, lungs, and abdominal lymph nodes [1–6]. We report a case of Peliosis Hepatitis diagnosed post laparotomy.

2. Case report

A 58-year-old woman was transferred to Doctor's Hospital of Nassau, Bahamas. The Patient presented in the Turks and Caicos and stated that two days prior she began having sharp, aching abdominal pain, non radiating, aggravated by palpation and sitting up; alleviated when walking/standing and associated with vomiting, diarrhea, abdominal distention and weakness. She is noted to have a long history of heavy alcohol consumption and oral contraceptive use. She sought medical attention and was admitted to hospital

where she was found to have an acute abdomen. Her pregnancy test at this time was negative. After a brief period of resuscitation she subsequently had a laparotomy. A large hepatic lesion was seen and approximately 2 l of dark blood was removed from the abdominal cavity. Peri-hepatic packing was performed and the abdomen closed. She was later airlifted to our institution. When she presented to Doctor's Hospital, she was noted to be tachycardic and in hypovolemic shock. A diagnosis of intra-abdominal hemorrhage secondary to a hemorrhagic hepatic lesion post laparotomy and abdominal packing was made. We optimized the patient and performed a re-look laparotomy, removal of packs, peritoneal lavage, placement of intraseed and sub-hepatic drain. We found a large right subscapular hematoma, six abdominal packs in situ, 400 cc blood but no palpable or visible lesion in the left lobe of the liver.

Her post operative period was uneventful until day 3 when her course was complicated by a right pleural effusion which required tube thoracostomy and hypokalemia which was corrected. During that time she had a CT scan, which confirmed the diagnosis peliosis hepatis. She also received psychiatric consultation to aid in cessation of alcohol consumption. The rest of her course was uneventful. The patient was discharged on day 11 postoperative.

3. Examination technique

High-resolution axial MDCT images are obtained from the level of the domes of diaphragm to the level of symphysis pubis after IV

* Corresponding author.

E-mail addresses: rossdownes@yahoo.com (R.O. Downes), craig@ufm.com (C.L. Cambridge), cdig@themednetgroup.com (C. Diggiss), jiferenta@doctorshosp.com (J. Iferenta), Muneeshsharma99@gmail.com (M. Sharma).

non ionic contrast (Ultravist 370) injection; in a 64 slice CT scanner (Philips Brilliance).

Plain (non contrast) and arterial phase (30 s) scans for the liver; a portal venous phase (70 s) of the whole abdomen and a delayed scan (300 s, hepatic equilibrium phase) for the liver are performed.

4. Findings

There is evidence of a massive non enhancing hyperdense sub-capsular hematoma measuring about 21 × 16 × 6 cm s in relation to the entire right hepatic lobe (Figs. 1 and 2-marked with an asterisk on all images).

It is further capped by numerous complex densities with mottled air foci and hyperdense curvilinear bands, suggesting surgical packing (Fig. 2-marked with an up arrowhead).

There is an irregular (non mass like) abnormal parenchymal enhancement in the left hepatic lobar segment 4a (Fig. 1-white arrows on images), measuring approx 8 × 6 × 4 cm s in size, this region is not encapsulated, shows no calcification or air foci. On the plain scan it is hypodense to the remainder of the liver with progressive contrast pooling and poor wash out leading to hyperdense appearance in the portal venous and delayed phase scans. It has several sinuous irregular branching hypodensities within it in the arterial and portal venous phases. The distinct lack of mass effect on the adjacent portal and hepatic venous radicles is also noted (Figs. 1 and 2).

Above features suggest peliosis hepatis (possibly related to use of OCs) in the left lobar segment 4a, and its rupture leading to a large right subcapsular hematoma. Moderate abdominal ascites and hemoperitoneum with frank pneumoperitoneum are noted, post laprotomy status. Bilateral small pleural effusions are identified. Liver shows no suggestion of cirrhosis. Biliary radicals are not dilated. Porta hepatis is normal. Gall bladder is well distended. Kidneys, spleen, pancreas, and both adrenal glands are normal. Gastrointestinal tract is grossly unremarkable, though the right half of the colon is displaced by the large hepatic pathology.

5. Discussion

Peliosis is a pathological condition of the mononuclear phagocytic system (reticuloendothelial system) [1,6]. The term peliosis originates from the Greek “pelios”, which means blue/black or discolored extravasated blood [2,12]. It is characterized by cystic blood filled cavities of the parenchymatous organs from the mononuclear phagocytic system [3,4]. Microscopically, there are two morphologic patterns of peliosis, as originally described by Yanoff and Rawson: the phlebectatic pattern, which is characterized by regular centrilobular blood-filled spaces that communicate with the sinusoids and are lined with the endothelium and/or fibrosis [5]. Secondly, the parenchymal pattern, characterized by irregular blood-filled spaces that are not by endothelium [5].

Although an exact etiology and pathophysiology of peliosis hepatis has yet to be discovered, there are many conditions associated with PH. It has been associated with certain drugs [5,13,14] (2-chloro-3'-deoxyadenosine, 6-mercaptopurine, 6-thioguanine, androgenic-anabolic steroids, arsenic, azathioprine, cadmium, contraceptive steroids, danazol, glucocorticoids, tamoxifen, thorium dioxide, urethane, vinyl chloride, vitamin A toxicity); infections [16–19,21] (Bacterial endocarditis *Bartonella*, HIV, leprosy, Pyelonephritis, Syphilis, Tuberculosis); hematologic conditions [16–19,21] (Agnogenic myeloid metaplasia, Anaplastic anemia, Castleman's disease, Fanconi disease, Hodgkin disease, Lymphoma, Malignant histiocytosis, Multiple myeloma, Waldenstrom macroglobulemia); malignancies [7,16–19,21] (Colorectal adenocarcinoma, gastric adenocarcinoma, hepatocellular carcinoma, pancreatic cancer, prostate cancer, renal cell carcinoma, seminoma); Others (Cardiac transplantation, Chronic hemodialysis, Chron's disease, Diabetes mellitus, Idiopathic restrictive cardiomyopathy, Liver transplant, Marasmus, Pregnancy, Renal transplantation, Rheumatoid arthritis, Systemic lupus erythematosus, Alcoholism) [7,16–21].

It has been hypothesized that peliosis hepatis is the result of loss of the integrity of the microvasculature of the liver either to congenital malformation of vessels or microcirculatory disturbances manifesting under alerted local intravascular pressure conditions

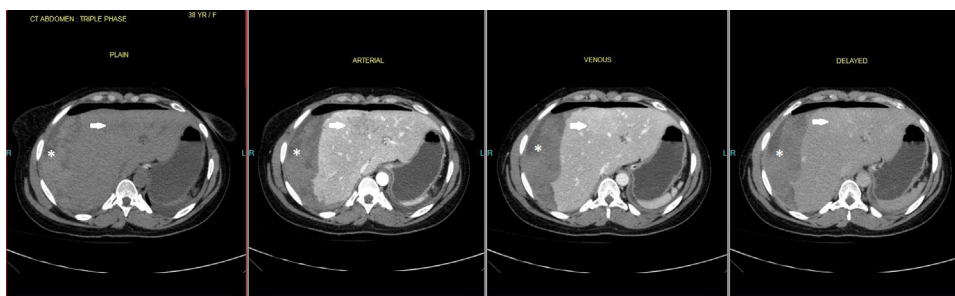


Fig. 1. CT scan abdomen post laparotomy.

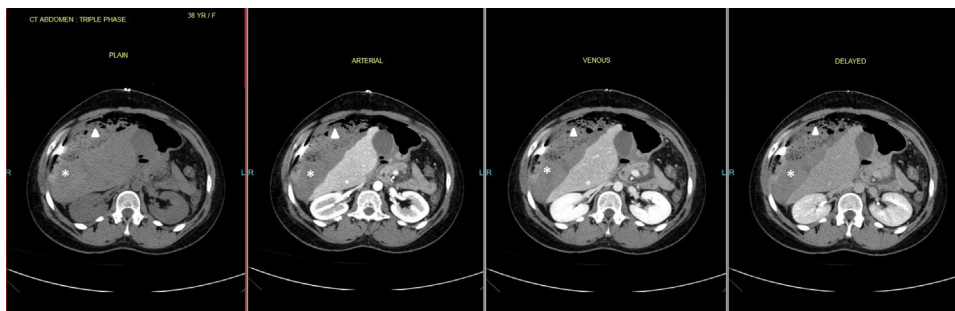


Fig. 2. CT scan abdomen showing large sub-capsular hematoma.

or even direct damage to the sinusoidal lining cells [7–11]. Nevertheless, none of the conditions associated with PH described in the previous paragraph explain its pathogenesis. Therefore, we believe that a loss of integrity of vasculature along with other unknown exacerbating factors is responsible for the development of peliosis hepatis. It has also been hypothesized that PH is the result of a neoplastic process which represents the final stage of vascular tumors in the liver [7,23,24].

Peliosis hepatis is typically asymptomatic and historically was a diagnosis of unclear significance made during autopsy [12]. Nowadays, it is discovered following the evaluation of abnormal liver function tests [12]. However, when severe it can manifest as abdominal pain, jaundice, hepatomegaly, liver failure, and haemoperitoneum [12,25–28]. The size of the peliotic cavity and extent of liver involvement appear to be predictive of the clinical manifestations. Patients with minor microscopic forms of PH usually remain asymptomatic, while patients with major macroscopic forms of PH display more recognizable symptoms [7,12,17].

Liver biopsy is the most reliable tool in diagnosing peliosis hepatis [13–15]. However, various imaging techniques (Ultrasound, CT, MRI, hepatic scintigraphy, hepatic angiography) may suggest a diagnosis of PH in an appropriate clinical setting [29–37].

The differential diagnosis on microscopic examination of liver specimens includes sinusoidal obstruction syndrome, heart failure, and Budd–Chiari syndrome. On imaging studies, the differential diagnosis includes other focal liver lesions including adenoma, hemangioma, focal nodular hyperplasia, abscess, hypervascular metastatic lesions, and hepatocellular carcinoma [22,29–37].

There is no specific treatment of peliosis hepatis (PH) except for the bacillary form. The natural course of peliosis hepatis is regression after drug withdrawal, cessation of steroid therapy, or resolution of an associated infectious disease [20,38]. Patients presenting with intrahepatic or peritoneal hemorrhage may require angiographic intervention or surgery [31].

6. Conclusion

Peliosis hepatis (PH) is a rare vascular condition of the liver characterized by the presence of cystic blood filled cavities distributed randomly throughout the liver parenchyma. There are many conditions associated with PH but none of them can satisfactorily explain its pathological findings. Therefore, we believe that a loss of integrity of vasculature along with other unknown exacerbating factors is responsible for the development of peliosis hepatis. PH is typically asymptomatic and usually an incidental finding on autopsy. Liver biopsy is the most reliable tool in diagnosing peliosis hepatis. Treatment is supportive and involves removal of the suspected causal agent.

Conflict of interest

None.

Funding

None.

Consent

Written informed consent was obtained from the patient for publication of this case report and accompanying images. A copy of the written consent is available for review by the Editor-in-Chief of this journal on request.

Author contribution

Ross Downes – Primary Physician, Author, Study Design, Analysis, Writing.

Muneesha Sharma – Radiologist.

Craig Cambridge – Student Aid, Data Collection, Writing.

James Iferenta – Er Physician, Data Analysis.

Charles Diggiss – Study Design.

References

- [1] M. Tsokos, A. Erbersdobler, Pathology of peliosis, *Forensic Sci. Int.* 149 (2005) 25–33.
- [2] E. Wagner, A case of blood cysts in the liver, *Arch. Med.* 2 (1861) 369–370.
- [3] M. Guggler, J.O. Gebbers, Peliosis of the spleen: an immune-complex disease? *Histopathology* 33 (1998) 387–389.
- [4] M. Tsokos, K. Püschel, Isolated peliosis of the spleen: report of two autopsy cases, *Am. J. Forensic Med. Pathol.* 25 (2004) 251–254.
- [5] M. Yanoff, A.J. Rawson, Peliosis hepatis an anatomic study with demonstration of two varieties, *Arch. Pathol.* 77 (1964) 159–165.
- [6] G. Kent, J.R. Thompson, Peliosis hepatis: involvement of reticuloendothelial system, *Arch. Pathol.* 72 (1961) 658–6664.
- [7] R. Cavalcanti, S. Pol, F. Carnot, et al., Impact and evolution of peliosis hepatis in renal transplant recipients, *Transplantation* 58 (1994) 315.
- [8] J. Nadell, J. Kosek, Peliosis hepatis: twelve cases associated with oral androgen therapy, *Arch. Pathol. Lab. Med.* 101 (1977) 405–410.
- [9] C.A. Zapar, C.M. Weldon-Linne, et al., Peliosis hepatis in the acquired immunodeficiency syndrome, *Arch. Pathol. Lab. Med.* 110 (1986) 611–613.
- [10] B.S. Gordon, J. Wolf, T. Krause, et al., Peliosis hepatis and cholestasis following administration of norethandrolone, *Am. J. Clin. Pathol.* 33 (1960) 156–165.
- [11] F. Naeim, P.H. Copper, et al., Peliosis hepatis: possible etiologic role of anabolic steroids, *Arch. Pathol.* 95 (1973) 284–285.
- [12] C. Degott, B. Rueff, H. Kreis, et al., Peliosis hepatis in recipients of renal transplants, *Gut* 19 (1978) 748.
- [13] F.G. Zak, Peliosis hepatis, *Am. J. Pathol.* 26 (1950) 1.
- [14] E.S. Zafarani, Y. von Pinaudeau, D. Dhumeaux, Drug-induced vascular lesions of the liver, *Arch. Intern. Med.* 143 (1983) 495.
- [15] M. Iwai, A. Muramatsu, S. Tanaka, et al., Macroscopic and microscopic findings of livers in malignant hematologic disorders, biopsied under peritoneoscopy, *J. Clin. Gastroenterol.* 35 (2002) 262.
- [16] T. Wakabayashi, H. Onda, T. Tada, et al., High incidence of peliosis hepatis in autopsy cases of aplastic anemia with special reference to anabolic steroid therapy, *Acta Pathol. Jpn.* 34 (1984) 1079.
- [17] F. Degos, C. Degott, J. Bedrossian, et al., Is renal transplantation involved in post-transplantation liver disease? A prospective study, *Transplantation* 29 (1980) 100.
- [18] D.R. Radin, G.C. Kanel, Peliosis hepatis in a patient with human immunodeficiency virus infection, *Am. J. Roentgenol.* 156 (1991) 91.
- [19] S. Chopra, A. Edelstein, R.S. Koff, et al., Peliosis hepatis in hematologic disease, *Rep. Two Cases. JAMA* 240 (1978) 1153.
- [20] K. Atila, A. Coker, D. Uçar, et al., A rare clinical entity misdiagnosed as a tumor: peliosis hepatis, *Ulus. Travma. Acil. Cerrahi. Derg.* 13 (2007) 149.
- [21] J.Y. Scoazec, C. Marche, P.M. Girard, et al., Peliosis hepatis and sinusoidal dilation during infection by the human immunodeficiency virus (HIV). An ultrastructural study, *Am. J. Pathol.* 131 (1988) 38.
- [22] S.S. Leong, R.A. Cazen, G.S. Yu, et al., Abdominal visceral peliosis associated with bacillary angiomatosis. Ultrastructural evidence of endothelial destruction by bacilli, *Arch. Pathol. Lab. Med.* 116 (1992) 866.
- [23] L.D. DeLeve, Hepatic microvasculature in liver injury, *Semin Liver Dis.* 27 (2007) 390.
- [24] K.N. Tzirogiannis, G.K. Papadimas, V.G. Kondyli, et al., Peliosis hepatis: microscopic and macroscopic type, time pattern, and correlation with liver cell apoptosis in a model of toxic liver injury, *Dig. Dis. Sci.* 51 (2006) 1998.
- [25] N.R. Hung, L. Chantraine, S. Dechambre, Peliosis hepatis revealed by biliary colic in a patient with oral contraceptive use, *Acta. Chir. Belg.* 104 (2004) 727.
- [26] D.M. Simon, R. Krause, J.T. Galambos, Peliosis hepatis in a patient with marasmus, *Gastroenterology* 95 (1988) 805.
- [27] A. Berzigotti, D. Magalotti, P. Zappoli, et al., Peliosis hepatis as an early histological finding in idiopathic portal hypertension: a case report, *World J. Gastroenterol.* 12 (2006) 3612.
- [28] S.K. Chawla, H.D. Patel, S.D. Mahadevia, P.A. LoPresti, Portal hypertension in peliosis hepatis. Report of the first case, *Am. J. Proctol. Gastroenterol. Colon Rectal Surg.* 31 (1980) 11.
- [29] R. Iannaccone, M.P. Federle, G. Brancatelli, et al., Peliosis hepatis: spectrum of imaging findings, *Am. J. Roentgenol.* 187 (2006) W43.
- [30] S.H. Kim, J.M. Lee, W.H. Kim, et al., Focal peliosis hepatis as a mimicker of hepatic tumors: radiological-pathological correlation, *J. Comput. Assist. Tomogr.* 31 (2007) 79.
- [31] K. Ofiordan, A. Blei, R. Vogelzang, et al., Peliosis hepatis with intrahepatic hemorrhage: successful embolization of the hepatic artery, *HPB Surg.* 11 (2000) 353.

- [32] L. Wannesson, E. Chigrinova, M. Raditchkova, et al., Peliosis hepatis in cancer patients mimicking infection and metastases, *Onkologie* 32 (2009) 54.
- [33] E. Yekeler, M. Dursun, A. Tunaci, et al., Diagnosing of peliosis hepatis by magnetic resonance imaging, *J. Hepatol.* 41 (2004) 351.
- [34] R.L. Smathers, J.P. Heiken, J.K. Lee, et al., Computed tomography of fatal hepatic rupture due to peliosis hepatis, *J. Comput. Assist. Tomogr.* 8 (1984) 768.
- [35] J. Lyon, J.J. Bookstein, C.A. Cartwright, et al., Peliosis hepatis: diagnosis by magnification wedged hepatic venography, *Radiology* 150 (1984) 647.
- [36] D.A. Jamadar, S.P. D'Souza, E.A. Thomas, T.E. Giles, Case report: radiological appearances in peliosis hepatis, *Br. J. Radiol.* 67 (1994) 102.
- [37] I. Saatci, M. Coskun, F. Boyvat, et al. MR findings in peliosis hepatis *Pediatric Radiology* 25 1995; 31. K. Sandrasegaran, D.R. Hawes, G. Matthew, Hepatic peliosis (bacillary angiomatosis) in AIDS: CT findings *Abdominal Imaging* 30 2005; 738.
- [38] M. Hyodo, A.M. Mogensen, P.N. Larsen, et al., Idiopathic extensive peliosis hepatis treated with liver transplantation, *J. Hepatobiliary Pancreat Surg.* 11 (2004) 371.

Open Access

This article is published Open Access at scimedirect.com. It is distributed under the [IJSCR Supplemental terms and conditions](#), which permits unrestricted non commercial use, distribution, and reproduction in any medium, provided the original authors and source are credited.