

OPEN

Paradoxical Autoinflammatory Skin Reaction to Tumor Necrosis Factor Alpha Blockers Manifesting as Amicrobial Pustulosis of the Folds in Patients With Inflammatory Bowel Diseases

Angelo V. Marzano, MD, Simona Tavecchio, MD, Emilio Berti, MD, Carlo Gelmetti, MD, and Massimo Cugno, MD

Abstract: The therapy of inflammatory bowel disease, particularly with tumor necrosis factor (TNF) blockers, may be associated with a number of cutaneous adverse effects, including psoriasis-like, eczema-like, and lichenoid eruptions. Other rare skin complications are neutrophilic dermatoses such as amicrobial pustulosis of the folds (APF), which is a chronic relapsing pustular disorder classified in this spectrum.

The authors analyzed clinical, histopathologic, and cytokine expression profiles of 3 inflammatory bowel disease patients with APF triggered by adalimumab (patient 1) and infliximab (patients 2 and 3).

All 3 patients presented with sterile pustules involving the cutaneous folds, genital regions, and scalp 6 months after starting adalimumab (patient 1) and 9 months after starting infliximab (patients 2 and 3). Histology was characterized by epidermal spongiform pustules with a dermal neutrophilic and lymphocytic infiltrate. Tumor necrosis factor blocker withdrawal associated with topical and systemic corticosteroids induced complete remission of APF in all 3 patients. The expressions of interleukin (IL)-1 beta and its receptors as well as TNF alpha and its receptors were significantly higher in APF than in controls. Also IL-17, leukocyte selectin, and chemokines, such as IL-8, [C-X-C motif] chemokine ligand 1/2/3 (C = cysteine, X = any amino acid), [C-X-C motif] chemokine ligand 16 (C = cysteine, X = any amino acid), and RANTES (regulated on activation, normal T cell expressed and secreted) were significantly overexpressed. Finally, the authors found significant overexpression of both metalloproteinases 2/9 and their inhibitors 1/2.

The observation of 3 patients with APF following anti-TNF therapy expands not only the clinical context of APF but also the spectrum of anti-TNF side effects. Overexpression of cytokines/chemokines and molecules amplifying the inflammatory network supports the view that APF is autoinflammatory in origin.

Editor: Xiwen Cheng.

Received: July 28, 2015; revised: September 9, 2015; accepted: September 22, 2015.

From the Dermatology Unit, Department of Pathophysiology and Transplantation, University of Milan, IRCCS Cà Granda Foundation, Milan, Italy (AVM, ST, EB, CG) and Internal Medicine Unit, Department of Pathophysiology and Transplantation, University of Milan, IRCCS Cà Granda Foundation, Milan, Italy (MC).

Correspondence: Angelo V. Marzano, MD, Dermatology Unit, Department of Pathophysiology and Transplantation, University of Milan, IRCCS Cà Granda Foundation, Via Pace 9, 20122 Milan, Italy (e-mail: angelovalerio.marzano@policlinico.mi.it).

This work was supported by "Ricerca corrente," Fondazione IRCCS Cà Granda, Ospedale Maggiore Policlinico, Milano, Italy.

The authors have no conflicts of interest to disclose.

Copyright © 2015 Wolters Kluwer Health, Inc. All rights reserved.

This is an open access article distributed under the Creative Commons Attribution-NonCommercial License, where it is permissible to download, share and reproduce the work in any medium, provided it is properly cited.

The work cannot be used commercially.

ISSN: 0025-7974

DOI: 10.1097/MD.0000000000001818

(*Medicine* 94(45):e1818)

Abbreviations: APF = amicrobial pustulosis of the folds, BCA = bichinchoninic acid, CD = Crohn disease, CXCL = [C-X-C motif] chemokine ligand [C = cysteine, X = any amino acid], E-selectin = endothelial selectin, IBD = inflammatory bowel disease, IFN = interferon, IL = interleukin, IL-1R = interleukin-1 receptor, ITP = idiopathic thrombocytopenic purpura, L-selectin = leukocyte selectin, MMP = matrix metalloproteinase, PG = pyoderma gangrenosum, RANTES = regulated on activation, normal T cell expressed and secreted, RIPA = radioimmunoprecipitation assay, SS = Sweet syndrome, TIMP = tissue inhibitor of metalloproteinase, TNF = tumor necrosis factor, TNFR = tumor necrosis factor receptor, UC = ulcerative colitis.

INTRODUCTION

Inflammatory bowel disease (IBD), including Crohn disease (CD) and ulcerative colitis (UC), may present extraintestinal manifestations in up to 40% of cases.¹ Among the extraintestinal organs, the skin is one of the most commonly affected. Mucocutaneous findings are frequent and may occur in 22% to 75% of patients with CD^{2,3} and in 5% to 11% of patients with UC.⁴ Skin manifestations associated with IBD are polymorphic and can be classified into 4 categories according to their pathophysiology: specific, reactive, associated, and induced by IBD treatment.⁵ Cutaneous manifestations are regarded as specific if they share with IBD the same granulomatous histopathologic pattern: perianal or metastatic CD, commonly presenting with abscesses or fistulas. Reactive cutaneous manifestations are different from IBD in the histopathology but have close physiopathologic links: autoinflammatory skin diseases such as neutrophilic dermatoses are the paradigm of this group. Among the cutaneous diseases associated with IBD, the most commonly seen are erythema nodosum and psoriasis. There are a number of cutaneous manifestations because of adverse effects of IBD therapy, in particular biologics, including psoriasis-like, eczema-like, and lichenoid eruptions as well as cutaneous lupus erythematosus. These immune-mediated inflammatory skin reactions represent a paradoxical event considering that biologic agents, most notably anti-tumor necrosis factor (TNF), are commonly used in the management of severe psoriasis. Autoinflammatory neutrophilic dermatoses have been very rarely reported in IBD patients under TNF blocker therapy,⁶ in particular, to the best of our knowledge, only 1 case of amicrobial pustulosis-like rash in a patient with CD under anti-TNF alpha has been described.⁷ Here, we studied 3 IBD patients who developed a paradoxical skin reaction

manifesting as amicrobial pustulosis of the folds (APF) after treatment with anti-TNF alpha agents [2 patients were treated with infliximab (a chimeric mouse–human monoclonal anti-TNF alpha antibody) and 1 with adalimumab (a fully human monoclonal anti-TNF alpha antibody)]. Amicrobial pustulosis of the folds is a chronic relapsing neutrophilic dermatosis that presents with sterile pustular lesions involving the main cutaneous folds, genital regions and scalp.^{8,9} Clinical, histopathologic, and cytokine expression profiles of the 3 patients have been analyzed. Notably, we have evaluated the main proinflammatory cytokines and chemokines commonly involved in autoinflammatory diseases with the aim of supporting the autoinflammatory nature of anti-TNF-induced APF in IBD patients.

PATIENTS AND METHODS

Patients

Three patients attended our University Department from 2012 to 2015 for having developed a skin reaction to anti-TNF agents manifesting as APF were studied clinicopathologically and immunologically. The patients were followed-up for a period ranging from 3 to 36 months. The diagnosis of APF was established on the basis of criteria previously suggested by Marzano et al⁹ and modified as reported in Table 1. To conduct the immunologic study, lesional skin biopsies taken from the 3 patients were evaluated by means of a cytokine array method. The controls were normal skin tissue specimens taken from 6 patients (4 women and 2 men; age range: 27–37 years) who underwent excision of benign skin tumors (melanocytic nevi). All the controls were not overweight nor had any cutaneous or systemic immune-mediated disorder. Blood and tissue samples were collected during routine diagnostic procedures and all patients gave oral informed consent that remaining samples

could be used for research purposes. The protocol was approved by the Institutional Review Board of IRCCS Fondazione Ca' Granda, Ospedale Maggiore Policlinico, Milano, Italy.

Methods

Cytokine Array

Each tissue sample was weighed and diced into very small pieces using a clean razor blade. Frozen tissues were sliced very thinly and thawed in radioimmunoprecipitation assay buffer (sc-24948) containing protease and phosphatase inhibitors by using 3 mL of ice-cold radioimmunoprecipitation assay buffer per gram of tissue.

Samples were incubated on ice for 30 minutes, transferred to microcentrifuge tubes and centrifuged at $10,000 \times g$ for 10 minutes at 4°C. The supernatant was collected and the sample was centrifuged again. The new supernatant fluid was added to the previous one, this mixture representing the total cell lysate. To standardize the cell lysate of each tissue sample, we measured the total proteins in each sample by a micro bicinchoninic acid kit (Thermo Scientific, Waltham, MA). For each sample, we loaded a volume containing 100 µg of proteins in a glass slide format of cytokine antibody array (RayBio®, Norcross, GA). The volume to be loaded was calculated by the following formula: volume (expressed in µL) = 100 µg/protein concentration (expressed in µg/µL). Each glass slide array contained 14 subarrays and was suitable for 14 samples. Each subarray was allowed to evaluate cytokine expression levels in a sample. Normalization of data at the end of the experiment provided semiquantitative results. The subarray was composed by specific antibodies against target molecules coated on the glass slide. After the hybridization of tissue lysate, each antibody bound its target molecule and unbound proteins were washed out. The slide was then incubated with biotin-conjugated antibodies against the same target cytokines, washed and then incubated with Cy3-conjugated streptavidin, creating a biotin–streptavidin–Cy3 complex detectable using a microarray laser scanner. By using data extraction software, we could convert fluorescent signals into numerical data and, after normalization, we obtained an expression value of signal intensity for each molecule in each sample. The molecules tested were the following: interleukin-1 beta (IL-1 beta), interleukin 1 receptor I (IL-1RI), IL-1RII, TNF alpha, tumor necrosis factor receptor I (TNFRI), TNFRII, IL-17, IL-17R, leukocyte selectin (L-selectin), endothelial selectin, IL-8, regulated on activation, normal T cell expressed and secreted (RANTES), [C-X-C motif] chemokine ligand 1,2,3 (C = cysteine, X = any amino acid) (CXCL 1,2,3), CXCL 16, matrix metalloproteinase (MMP)-2, MMP-9, tissue inhibitor of metalloproteinase (TIMP)-1, and TIMP-2.

Statistics

Because the signal intensity data were positively skewed, they were log transformed before analysis. The results are reported as antilog values of means with standard deviation. Student *t* test for unpaired values was used to assess statistical significance of differences. The significance level was set at $P < 0.05$.

RESULTS

Clinical Features

Clinical features are reported in Table 2. A 35-year-old woman (patient 1) was referred for evaluation of a recurrent

TABLE 1. Diagnostic Criteria for Amicrobial Pustulosis of the Folds

Major Criteria	Minor Criteria
Pustulosis involving 1 or more major folds, 1 or more minor folds, and the anogenital area	Association with 1 or more autoimmune or autoinflammatory disorders
Histologic pattern consisting of intraepidermal spongiform pustules and a mainly neutrophilic dermal infiltrate	Positive ANA at a titer of 1/160 or higher
Negative culture from unopened pustule	One or more serum autoantibodies (anti-ENA, anti-dsDNA, antiphospholipid, antihistone, antismooth muscle, antimitochondrial, antigastric parietal cell, and antiendomysial)

The diagnosis of amicrobial pustulosis of the folds can be ascertained if major criteria and at least 1 minor criterion are fulfilled.

ANA = antinuclear antibodies; dsDNA = double-stranded DNA; ENA = extractable nuclear antigens.

TABLE 2. Clinical Features, Laboratory Findings, Treatment and Course in the 3 Inflammatory Bowel Disease Patients With Skin Reaction to Antitumor Necrosis Alpha Agents Manifesting as Microbial Pustulosis of the Folds

Patient	Sex/Age at Diagnosis, Years	Triggering Drug	Associated Disorders	Laboratory Findings	Treatment	Course
1	Female/35	Adalimumab	Crohn disease	ESR 60 mm/first hour; CRP 1.25 mg/dL; hemoglobin 11.4 g/dL; ANA 1/320	Clobetasol dipropionate and intravenous methylprednisolone 1 mg/kg/d; switch from adalimumab to ustekinumab	Complete remission
2	Male/38	Infliximab	Ulcerative colitis	ESR 100 mm/first hour; CRP 6.2 mg/dL	Intravenous methylprednisolone 250 mg/d for 3 days (then oral prednisone); switch from infliximab to sulfasalazine	Complete remission
3	Female/26	Infliximab	Crohn disease	ESR 70 mm/first hour; CRP 4.1 mg/dL	Clobetasol dipropionate and intravenous methylprednisolone 1 mg/kg/d; switch from infliximab to sulfasalazine	Complete remission

ANA = antinuclear antibodies; CRP = C-reactive protein; ESR = erythrocyte sedimentation rate.

pustular and erosive eruption of 6 month duration involving mainly the inguinal folds and anogenital region. She had a 5-year history of undifferentiated connective tissue disease and a 2-year history of Crohn disease (CD). For treating CD, she had been receiving adalimumab subcutaneously for 1 year (induction dose of 160 mg at week 0 and 80 mg at week 2, followed by a maintenance dose of 40 mg every other week). She was initially treated by the gastroenterologists with several courses of systemic (amoxicillin + clavulanic acid) and topical (mupirocin) antibiotics without any improvement.

A 38-year-old man (patient 2) and a 26-year-old woman (patient 3) were referred to our department for cutaneous manifestations closely similar to those seen in patient 1, present since 3 months. Both had a 6-year history of IBD, namely UC in patient 2 and CD in patient 3. Both had been receiving infusions of infliximab (5 mg/kg) for 1 year every other month, following an attack schedule of 1 infusion at time 0 and after 2 and 6 weeks. Also in these patients, previous antibiotic regimen had failed to obtain any clinical response.

On examination, in all 3 patients, there were multiple erythematous pustules (Fig. 1A) coalescing in macerated erosive areas (Fig. 1B), symmetrically involving the major skin folds, such as axillae and groins (Fig. 1C), and the anogenital region (Fig. 1D) as well as minor folds, such as the external auditory canals, retroauricular flexures (Fig. 2A-B), and the area around the nostrils; the cutaneous lesions were associated with intense oozing and accompanied by burning. In patient 1, a large eroded plaque was also present in the intergluteal fold (Fig. 2C). None of the patients was overweight.

Laboratory Findings

Results from laboratory examinations are shown in Table 2. On admission to our department, the erythrocyte sedimentation rate was elevated in all 3 patients (60, 100, and 70 mm/first hour, respectively); C-reactive protein was also increased in all 3 patients (1.25, 6.2, and 4.1 mg/dL, respectively; normal values <0.5 mg/dL). Patient 1 showed also mild anemia (hemoglobin: 11.4 g/dL). Antinuclear antibodies, at a titer of 1/320 with homogeneous pattern, were present in patient 1. In all 3 patients, serum zinc levels were within the normal limits. Repeated bacteriological cultures from closed pustules were negative, while cultures from erosive areas demonstrated the presence of *Staphylococcus aureus* in all 3 patients. Fungal cultures were negative in all 3 patients.

Histopathologic Aspects and Direct/Indirect Immunofluorescence Findings

In all 3 patients, light microscopy studies of skin biopsy specimens obtained from an affected area revealed a very similar pattern characterized by spongiform pustules in the epidermis with slight acanthosis and dermal edema with a mixed neutrophilic and lymphocytic inflammatory infiltrate (Fig. 3).

Direct immunofluorescence, performed on peripustular normal skin, was negative and indirect immunofluorescence failed to detect circulating antibodies in any of the 3 cases (except for antinuclear antibodies in patient 1).

Treatment and Course

Patient 1 was treated with both topical and systemic corticosteroids (clobetasol dipropionate and intravenous methylprednisolone 1 mg/kg/d, respectively), achieving rapid improvement of the clinical picture. Considering the tendency of APF lesions to relapse upon tapering the doses of

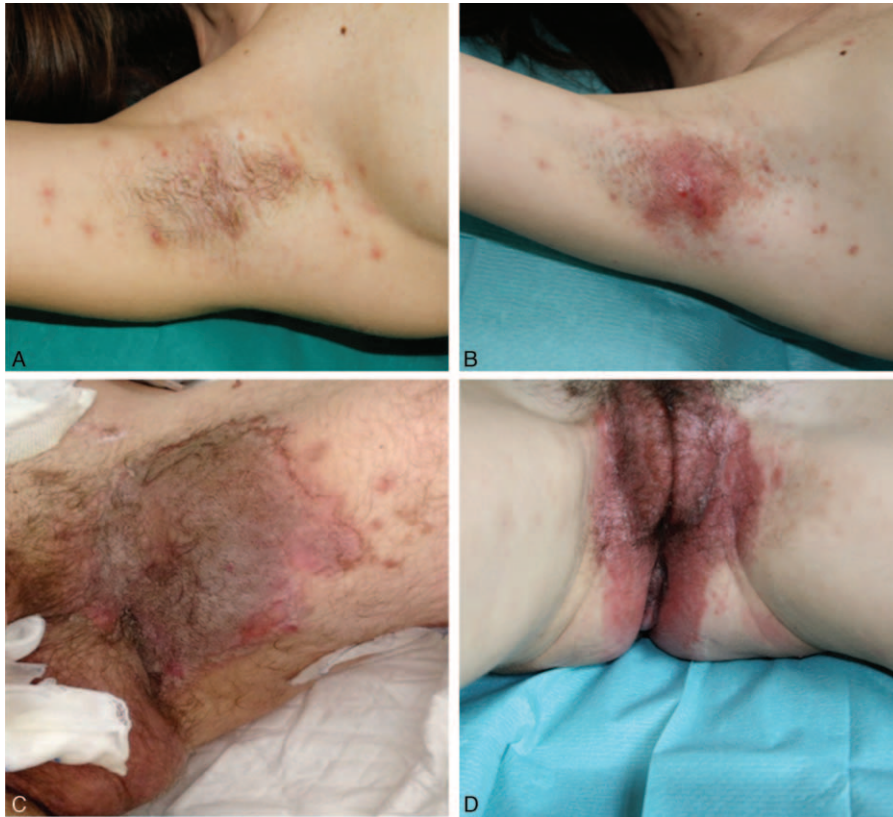

FIGURE 1. Clinical features of amicrobial pustulosis of the folds triggered by tumor necrosis factor alpha blockers. A, Erythematous pustules involving the axilla in patient 3. B, Erosive area because of coalescence of pustules on the axilla in patient 3. C, Erosions with vegetating aspects on the inguinal fold in patient 2. D, Erythematous erosive lesions on the anogenital region in patient 1.

methylprednisolone and based on the potential triggering role of adalimumab, the patient, however, was switched to ustekinumab for her CD. At the time of writing, after a follow-up period of 3 months, there was complete resolution of the pustules and marked improvement of the intergluteal plaque, which was clinically diagnosed as metastatic CD (the patient refused a skin biopsy on the latter site).

In patient 2, a pulsed therapy with intravenous methylprednisolone 250 mg/d for 3 days (followed by oral prednisone at progressively tapering doses), in combination with switching over to sulfasalazine for UC, induced complete healing of cutaneous manifestations, lasting at the time of writing after a follow-up of 18 months.

In patient 3, clearing of APF lesions was obtained using the same treatment schedule as in patient 1, associated with switching over to sulfasalazine as in patient 2. At the time of writing, on a 36-month follow-up, there was still complete remission of APF.

In all 3 patients, systemic antibiotic therapy (amoxicillin + clavulanic acid) in combination with antiseptic baths was given to treat the *S. aureus* superinfection.

Expression Analysis of Cytokines, Chemokines, and Effector Molecules in Skin Specimens

Cytokine Expression

Interleukin-1 beta and its receptors (IL-1RI and II) were significantly more expressed in lesional skin of the 3 patients with APF (20.75 ± 48.96 , 4.33 ± 2.79 , and 13.63 ± 13.74 , respectively)

than in normal skin (3.42 ± 1.87 , 2.00 ± 0.82 , and 4.49 ± 1.73 ; $P = 0.023$, $P = 0.013$, and $P = 0.027$, respectively; Figure 4). The proinflammatory cytokine TNF alpha was also overexpressed (3.85 ± 0.74 versus 2.60 ± 0.19 ; $P = 0.003$) as well as its receptors TNFRI (14.74 ± 2.74 versus 5.87 ± 3.43 ; $P = 0.005$) and TNFRII (15.89 ± 4.09 versus 6.25 ± 3.31 ; $P = 0.017$; Figure 5). Finally, we observed an overproduction of IL-17 (6.09 ± 4.70 versus 2.17 ± 0.44 ; $P = 0.014$) and its receptor IL-17R (6.68 ± 0.55 versus 3.98 ± 1.33 ; $P = 0.026$, Figure 6).

Leukocyte Selectin Expression

The expression of L-selectin was significantly higher in lesional skin of the 3 patients with APF (10.32 ± 6.76) than in normal skin (2.14 ± 1.21 ; $P = 0.005$; Figure 6).

Chemokine Expression

As compared with controls, lesional skin of APF patients showed overexpression of chemokines promoting neutrophil transendothelial migration into inflamed tissues, such as IL-8 (12.53 ± 8.65 versus 2.73 ± 1.05 ; $P = 0.003$), CXCL 1/2/3 (109.70 ± 108.58 versus 7.61 ± 7.75 ; $P = 0.001$), CXCL 16 (4.40 ± 0.54 versus 2.50 ± 0.74 ; $P = 0.007$), and RANTES (19.74 ± 19.65 versus 3.41 ± 1.57 ; $P = 0.004$; Figure 7).

Matrix Metalloproteinase and Tissue Inhibitor of Metalloproteinase Expression

In lesional skin of APF patients, we observed a significant overexpression of molecules involved in tissue damage, such

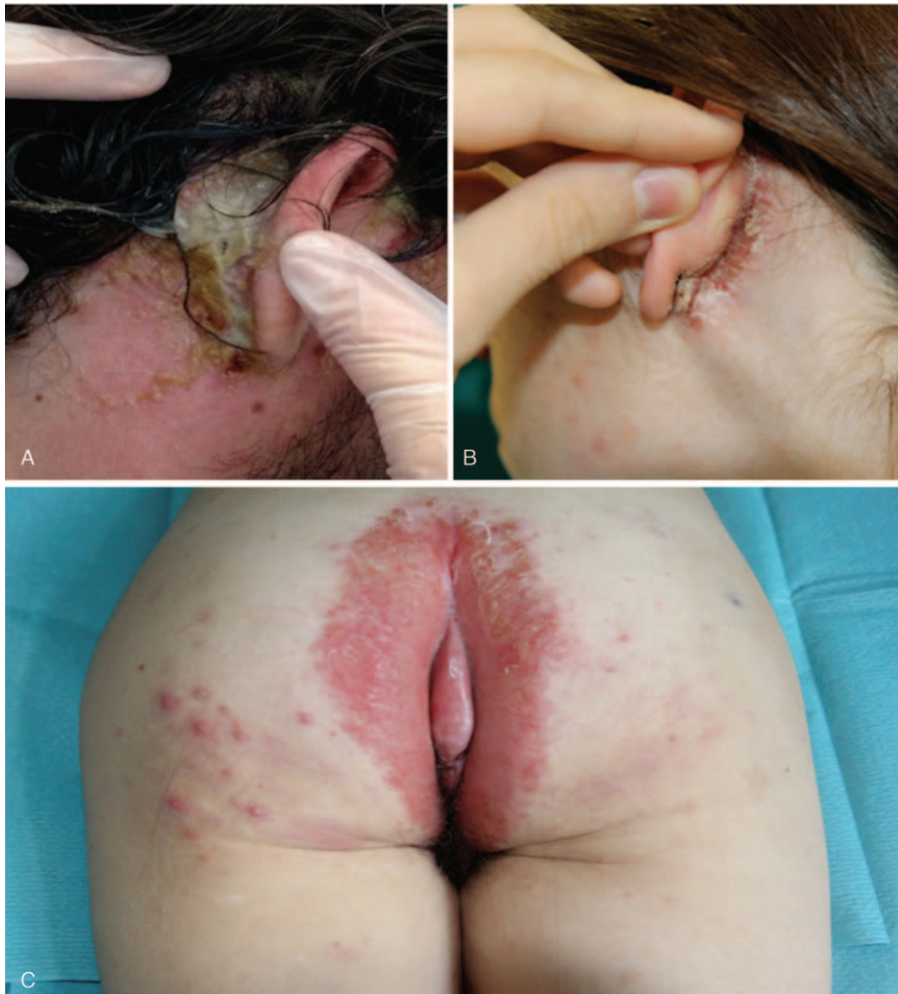

FIGURE 2. Clinical features of amicrobial pustulosis of the folds triggered by tumor necrosis factor alpha blockers. Macerated erosive lesions with crusts on the retroauricular region in patient 2 (A) and in patient 3 (B). C, Erythematous plaque surrounded by an exudating erosive area on the intergluteal region in patient 1.

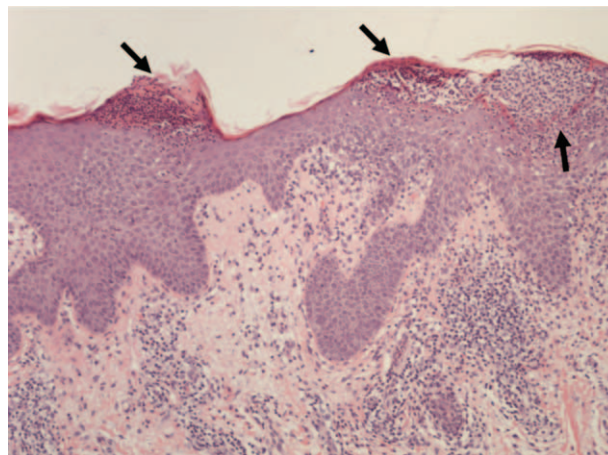


FIGURE 3. Histopathologic features of amicrobial pustulosis of the folds triggered by tumor necrosis factor alpha blockers. The histology shows pustules (highlighted with arrows) and a mainly neutrophilic infiltrate in the epidermis as well as a predominantly lymphocytic infiltrate in the upper dermis (hematoxylin and eosin stain; original magnification, $\times 200$).

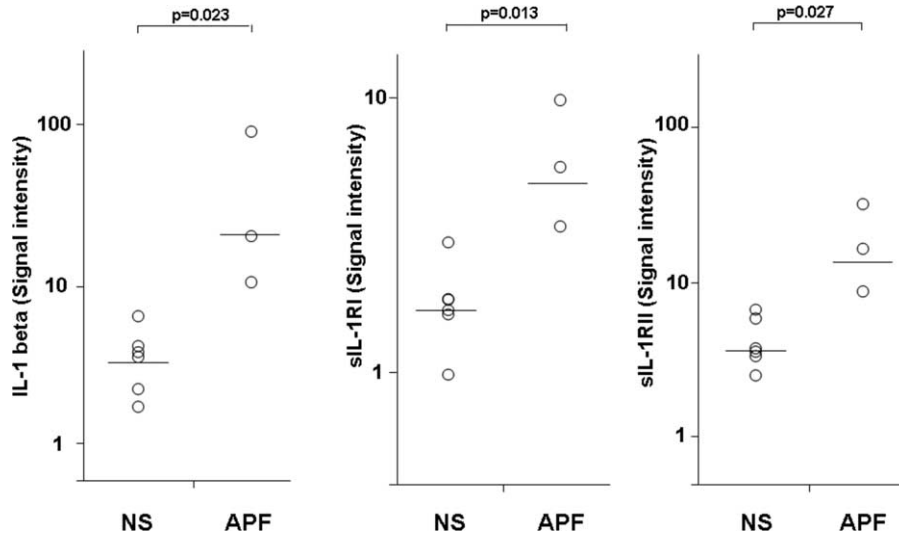


FIGURE 4. Expression of IL-1 beta and its soluble receptors I and II in homogenate samples of lesional skin from 3 patients with amicrobial pustulosis of the folds triggered by tumor necrosis factor alpha blockers. Six normal subjects served as controls. Numerical values represent signal intensity in a cytokine array assay.

as MMP-2 (6.96 ± 3.24 versus 2.49 ± 0.90 ; $P = 0.008$) and MMP-9 (388.69 ± 54.56 versus 24.71 ± 68.33 ; $P = 0.0001$; Figure 8). Overproduction of molecules responsible for inhibitory signals aimed at attenuating MMP-mediated inflammation was also demonstrated: TIMP-1 (47.02 ± 83.04 versus 4.45 ± 1.63 ; $P = 0.004$) and TIMP-2 (107.45 ± 111.29 versus 48.69 ± 24.40), the latter, however, did not reach statistical significance (Figure 8).

DISCUSSION

Amicrobial pustulosis of the folds is a rare chronic relapsing dermatosis that affects almost exclusively young women with sudden onset of follicular and nonfollicular sterile pustular lesions involving the main cutaneous folds, anogenital area and

scalp as well as minor skin folds, particularly the area around the nostrils, retroauricular regions, and external auditory canals. The clinical picture of APF is similar to that of the inverse type of psoriasis pustulosa, which, however, usually spares the minor folds and often presents with psoriasis lesions in other sites of the body. Its histologic picture is characterized by subcorneal pustules associated with a mainly neutrophilic infiltrate in the dermis, which led to include APF in the spectrum of neutrophilic dermatoses.⁹ Neutrophilic dermatoses represent a clinically heterogeneous group of disorders hallmarked by an accumulation of neutrophils in the skin and rarely internal organs.¹⁰ Amicrobial pustulosis of the folds has been reported to be associated with a number of autoimmune diseases, including lupus erythematosus,^{9,11} mixed connective tissue disease,^{12,13} myasthenia gravis,¹¹ Sjögren syndrome,¹⁴ celiac

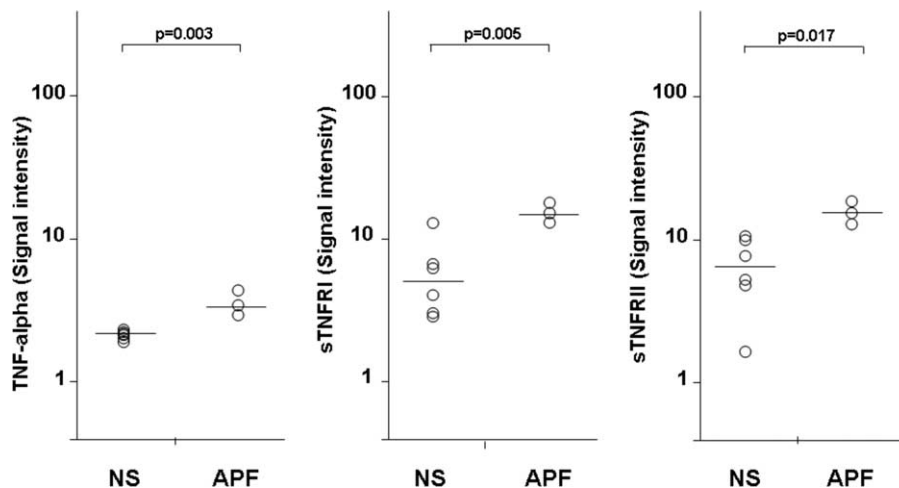


FIGURE 5. Expression of tumor necrosis factor alpha and its soluble receptors I and II in homogenate samples of lesional skin from 3 patients with amicrobial pustulosis of the folds triggered by tumor necrosis factor alpha blockers. Six normal subjects served as controls. Numerical values represent signal intensity in a cytokine array assay.

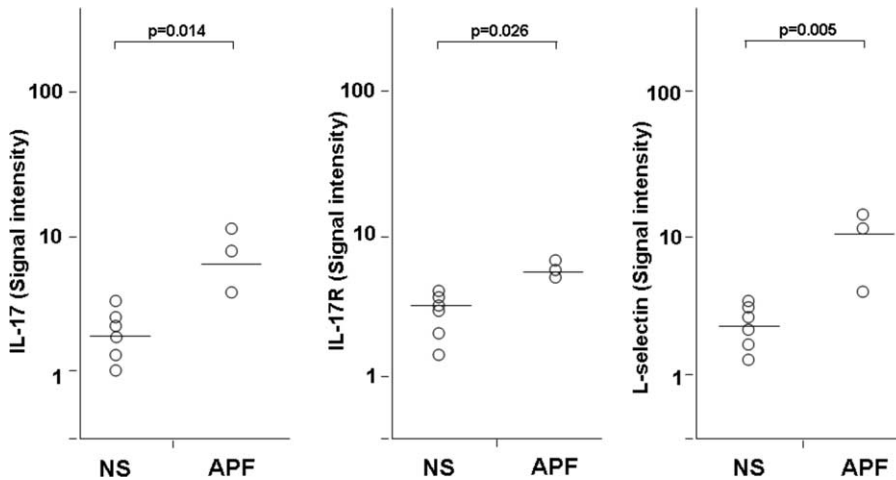


FIGURE 6. Expression of interleukin-17, its soluble receptor, and leukocyte selectin in homogenate samples of lesional skin from 3 patients with amicrobial pustulosis of the folds triggered by tumor necrosis factor alpha blockers. Six normal subjects served as controls. Numerical values represent signal intensity in a cytokine array assay.

disease,⁸ rheumatoid arthritis,¹⁵ idiopathic thrombocytopenic purpura,¹¹ and immunoglobulin A nephropathy.¹⁶ It is well known that neutrophilic dermatoses, particularly pyoderma gangrenosum (PG) and Sweet syndrome (SS), are among the better recognized extraintestinal manifestations of IBD¹⁷ and in 2011, Lee et al⁷ described the first case of APF associated with

IBD. Here, we report 3 additional cases of APF in patients with IBD treated with anti-TNF alpha agents. Although APF may complicate IBD and other immune-mediated disorders at any time during the disease course, in our patients, the strict association of APF with TNF blocker therapy and its prompt resolution upon drug withdrawal support the triggering role of

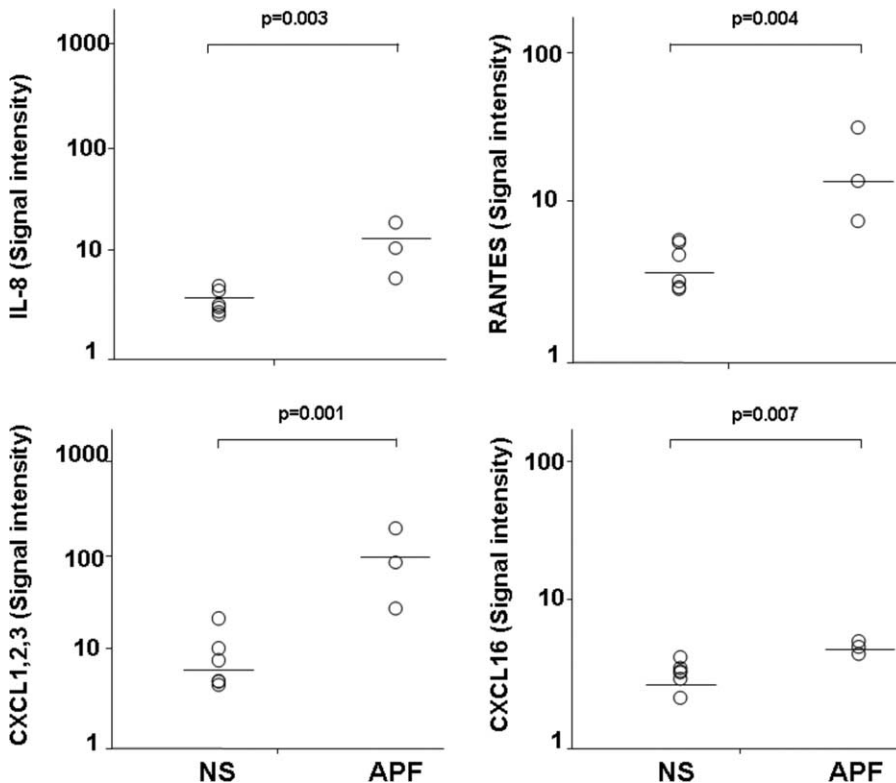


FIGURE 7. Expression of interleukin-8, regulated on activation, normal T cell expressed and secreted, [C-X-C motif] chemokine ligand 1,2,3 (C = cysteine, X = any amino acid), and [C-X-C motif] chemokine ligand 16 (C = cysteine, X = any amino acid) in homogenate samples of lesional skin from 3 patients with amicrobial pustulosis of the folds triggered by tumor necrosis factor alpha blockers. Six normal subjects served as controls. Numerical values represent signal intensity in a cytokine array assay.

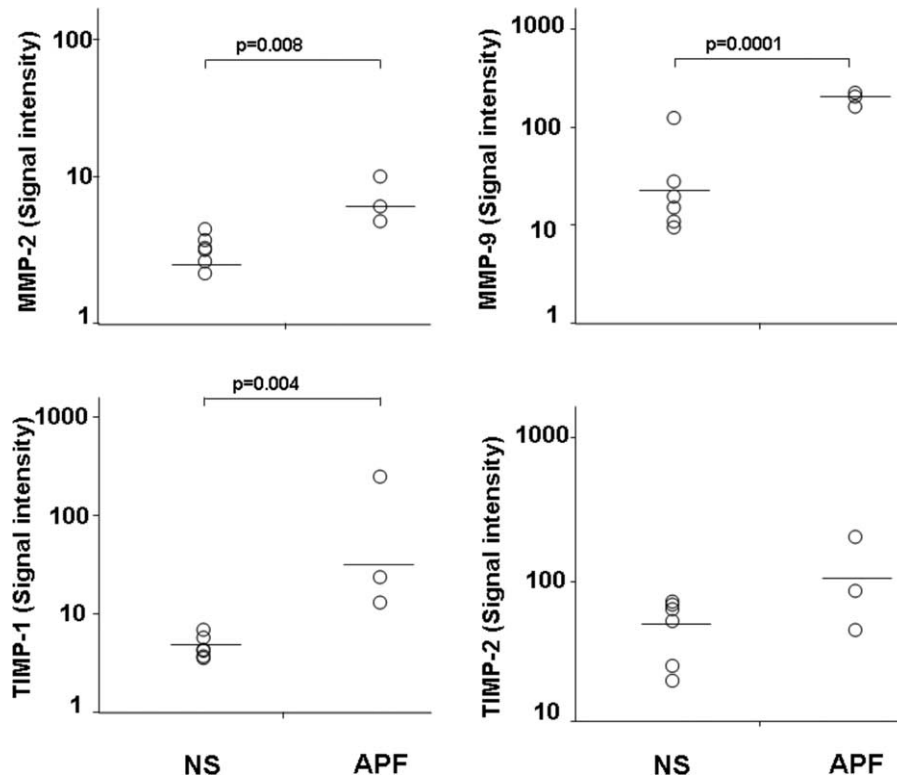


FIGURE 8. Expression of matrix metalloproteinase-2, matrix metalloproteinase-9, tissue inhibitor of metalloproteinase 1, and tissue inhibitor of metalloproteinase 2 in homogenate samples of lesional skin from 3 patients with amicrobial pustulosis of the folds triggered by tumor necrosis factor alpha blockers. Six normal subjects served as controls. Numerical values represent signal intensity in a cytokine array assay.

anti-TNF treatment. Tumor necrosis factor blockers are responsible for a number of cutaneous adverse reactions, the most frequent of which are pustular eruptions.⁶ Pustular reactions represent a paradoxical event because TNF antagonists are commonly used in the treatment of psoriasis, including its pustular variant. Pustular psoriasis and other neutrophilic dermatoses, such as PG and SS are nowadays considered autoinflammatory conditions, which are characterized by recurrent episodes of sterile inflammation, without circulating autoantibodies and autoreactive T cells.¹⁷ Increasing evidence, however, supports clinical and immunologic similarities between autoimmune and autoinflammatory diseases, giving rise to consider them as a single group of diseases with a large spectrum of immunologic and clinical abnormalities, which include at 1 end pure autoinflammatory diseases and at the other end pure autoimmune diseases.¹⁸ In PG and SS, we recently demonstrated an overexpression of cytokines/chemokines and molecules amplifying the inflammatory network, supporting the view that these disorders are autoinflammatory in origin.¹⁹

In our study, we found an overexpression of IL-1 beta and its receptors in all 3 patients. This could be linked to dysregulation of the function of inflammasome, which is a molecular platform responsible for the activation of caspase 1, an enzyme inducing the proteolytic cleavage of the inactive pro-IL-1 beta to its functionally active form, IL-1 beta. Interleukin-1 promotes the production and release of both classic proinflammatory cytokines, such as TNF alpha and interferon gamma, and a number of chemokines, notably IL-8 and RANTES.²⁰ Tumor necrosis factor alpha, which also acts as a key regulator of other

proinflammatory cytokines and chemokines, including the same IL-1 beta and IL-8,²¹ was overexpressed in all the 3 APF patients. Also chemokines, such as IL-8, CXCL 1/2/3, CXCL 16, and RANTES, were overexpressed, promoting neutrophil transendothelial migration into the site of inflammatory process that was also favored by the upregulation of L-selectin. In our study, we found an overexpression of IL-17 and its receptor in all 3 patients, confirming the previously hypothesized role for this T-helper 17-related cytokine in the pathophysiology of the whole spectrum of neutrophilic dermatoses, similarly to psoriasis and other autoimmune diseases.^{22–24} Interleukin-17 amplifies the recruitment of neutrophils and monocytes by increasing the local production of chemokines, most notably IL-8²⁵ and synergizing with various other cytokines, in particular with TNF alpha.²⁶ Moreover, IL-17, such as IL-1 and TNF alpha, induces the production of MMPs,²⁷ a family of endopeptidases that include the so-called gelatinases MMP-2 and MMP-9. An improper activity of MMPs synthesized by inflammatory cells, particularly neutrophils, is known to cause tissue damage via degradation of components of the extracellular matrix and to influence the production of chemokines, promoting neutrophil transendothelial migration.²⁸

Here, we found an overexpression of MMP-9 in the skin inflammatory infiltrate, suggesting that this proteinase and to a lesser degree MMP-2 may be involved in inducing tissue damage. Interestingly, we detected also an overproduction of TIMP-1 and TIMP-2, which likely represent an inhibitory pathway aimed at attenuating the MMP-mediated inflammation.

The main limitation of our study is the small number of patients, because of the rarity of drug-induced APF, which may be, however, counterbalanced by the wide panel of molecules investigated and by the clear-cut differences observed. One could argue that the ideal controls to evaluate the role of proinflammatory cytokines in the pathogenesis of anti-TNF-induced APF would be samples taken from normal skin of IBD patients and/or nonlesional skin of patients with anti-TNF-induced APF. We, however, have decided to choose normal skin of patients without any immune-mediated disorder as control to avoid the possible finding of an initial low overexpression of inflammatory effector molecules preceding the development of cutaneous lesions; on the contrary, a strong expression of proinflammatory cytokines is unlikely in the absence of cutaneous lesions, as previously found in other neutrophilic dermatoses, such as PG and SS.¹⁹ Another source of bias could be the location of the biopsy because the skin of areas different from major and minor folds is not involved in APF. Testing the normal skin of major and minor folds in IBD patients before and after treatment with TNF-blockers could be matter for future studies aimed at identifying early molecular markers predicting the onset of skin–drug reactions.

Overall, our data show high values of proinflammatory cytokines, chemokines, and tissue damage effector molecules, supporting the autoinflammatory origin of APF as paradoxical skin reaction to TNF blockers. Concerning a possible explanation of this paradoxical side effect, it is possible to hypothesize pathomechanisms similar to those of the psoriatic skin lesions occurring in the setting of anti-TNF therapy, which are mainly related to uncontrolled increase of IFN alpha as a result of TNF pathway blockade.^{29,30} The activation of autoreactive T cells,^{31,32} certain infectious agents,^{31,33} and a genetic susceptibility^{31,33,34} could be possible further mechanisms.

REFERENCES

- Huang BL, Chandra S, Shih DQ. Skin manifestations of inflammatory bowel disease. *Front Physiol.* 2012;3:13.
- Burgdorf W. Cutaneous manifestations of Crohn's disease. *J Am Acad Dermatol.* 1981;5:689–695.
- Palamaras I, El-Jabbour J, Pietropaolo N, et al. Metastatic Crohn's disease: a review. *J Eur Acad Dermatol Venereol.* 2008;22:1033–1043.
- Timani S, Mutasim DF. Skin manifestations of inflammatory bowel disease. *Clin Dermatol.* 2008;26:265–273.
- Marzano AV, Borghi A, Stadnicki A, et al. Cutaneous manifestations in patients with inflammatory bowel diseases: pathophysiology, clinical features, and therapy. *Inflamm Bowel Dis.* 2014;20:213–227.
- Marzano AV, Borghi A, Meroni PL, et al. Immune-mediated inflammatory reactions and tumors as skin side effects of inflammatory bowel disease therapy. *Autoimmunity.* 2014;47:146–153.
- Lee HY, Pelivani N, Beltraminelli H, et al. Amicrobial pustulosis-like rash in a patient with Crohn's disease under anti-TNF-alpha blocker. *Dermatology.* 2011;222:304–310.
- Marzano AV, Capsoni F, Berti E, et al. Amicrobial pustular dermatosis of cutaneous folds associated with autoimmune disorders: a new entity? *Dermatology.* 1996;193:88–93.
- Marzano AV, Ramoni S, Caputo R. Amicrobial pustulosis of the folds. *Dermatology.* 2008;216:305–311.
- Wallach D, Vignon-Pennamen M-D. From acute febrile neutrophilic dermatosis to neutrophilic disease: forty years of clinical research. *J Am Acad Dermatol.* 2006;55:1066–1071.
- Lagrange S, Chosidow O, Piette JC, et al. A peculiar form of amicrobial pustulosis of the folds associated with systemic lupus erythematosus and other auto-immune diseases. *Lupus.* 1997;6:514–520.
- Vignon-Pennamen MD, Wallach D. Cutaneous manifestations of neutrophilic disease. *Dermatologica.* 1991;183:255–264.
- Bénéton N, Wolkenstein P, Bagot M, et al. Amicrobial pustulosis associated with autoimmune diseases: healing with zinc supplementation. *Br J Dermatol.* 2000;143:1306–1310.
- Kuyama M, Fujimoto W, Kambara H, et al. Amicrobial pustular dermatosis in two patients with immunological abnormalities. *Clin Exp Dermatol.* 2002;27:286–289.
- Hoch O, Herbst RA, Gutzmer R, et al. Amicrobial intertriginous pustulosis in autoimmune disease: a new entity? *Hautarzt.* 1998;49:634–640.
- Natsuga K, Sawamura D, Homma E, et al. Amicrobial pustulosis associated with IgA nephropathy and Sjögren's syndrome. *J Am Acad Dermatol.* 2007;57:523–526.
- Marzano AV, Ishak RS, Saibeni S, et al. Autoinflammatory skin disorders in inflammatory bowel diseases, pyoderma gangrenosum and Sweet's syndrome: a comprehensive review and disease classification criteria. *Clin Rev Allergy Immunol.* 2013;45:202–210.
- Doria A, Zen M, Bettio S, et al. Autoinflammation and autoimmunity: bridging the divide. *Autoimmun Rev.* 2012;12:22–30.
- Marzano AV, Fanoni D, Antiga E, et al. Expression of cytokines, chemokines and other effector molecules in two prototypic autoinflammatory skin diseases, pyoderma gangrenosum and Sweet's syndrome. *Clin Exp Immunol.* 2014;178:48–56.
- Dinarello CA. A clinical perspective of IL-1β as the gatekeeper of inflammation. *Eur J Immunol.* 2011;41:1203–1217.
- Oppenheim JJ, Zachariae CO, Mukaida N, et al. Properties of the novel proinflammatory supergene 'intercrine' cytokine family. *Ann Rev Immunol.* 1991;9:617–648.
- Marzano AV, Cugno M, Trevisan V, et al. Role of inflammatory cells, cytokines and matrix metalloproteinases in neutrophil-mediated skin diseases. *Clin Exp Immunol.* 2010;162:100–107.
- Pene J, Chevalier S, Preisser L, et al. Chronically inflamed human tissues are infiltrated by highly differentiated Th17 lymphocytes. *J Immunol.* 2008;180:7423–7430.
- Dardalhon V, Korn T, Kuchroo VK, et al. Role of Th1 and Th17 cells in organ-specific autoimmunity. *J Autoimmun.* 2008;31:252–256.
- Nalbandian A, Crispin JC, Tsokos GC. Interleukin-17 and systemic lupus erythematosus: current concepts. *Clin Exp Immunol.* 2009;157:209–215.
- Ruddy MJ, Wong GC, Liu XK, et al. Functional cooperation between interleukin-17 and tumor necrosis factor-alpha is mediated by CCAAT/enhancer-binding protein family members. *J Biol Chem.* 2004;279:2559–2567.
- Agarwal S, Misra R, Aggarwal A. Interleukin 17 levels are increased in juvenile idiopathic arthritis synovial fluid and induce synovial fibroblasts to produce proinflammatory cytokines and matrix metalloproteinases. *J Rheumatol.* 2008;35:515–519.
- Delclaux C, Delacourt C, D'Ortho MP, et al. Role of gelatinase B and elastase in human polymorphonuclear neutrophil migration across basement membrane. *Am J Respir Cell Mol Biol.* 1996;14:288–295.
- Pathirana D, Ormerod AD, Saiag P, et al. European S3-guidelines on the systemic treatment of psoriasis vulgaris. *J Eur Acad Dermatol Venereol.* 2009;23:1–70.
- Nestle FO, Conrad C, Tun-Kyi A, et al. Plasmacytoid dendritic cells initiate psoriasis through interferon-alpha production. *J Exp Med.* 2005;202:135–143.

31. Guerra I, Algaba A, Perez-Calle JL, et al. Induction of psoriasis with anti-TNF agents in patients with inflammatory bowel disease: a report of 21 cases. *J Crohns Colitis*. 2012;6:518–523.
32. Denadai R, Teixeira VF, Saad-Hossne R. Letter: pathogenesis of tumor necrosis factor alpha antagonists-induced psoriasiform lesions. *Aliment Pharmacol Ther*. 2012;36:77–78.
33. Iborra M, Beltran B, Bastida G, et al. Infliximab and adalimumab-induced psoriasis in Crohn's disease: a paradoxical side effect. *J Crohns Colitis*. 2011;5:157–161.
34. Rahier JF, Buche S, Peyrin-Biroulet L. Severe skin lesions cause patients with inflammatory bowel disease to discontinue anti-tumor necrosis factor therapy. *Clin Gastroenterol Hepatol*. 2010;8:1048–1055.