

Neural processing of traumatic events in subjects suffering PTSD: a case study of two surgical patients with severe accident trauma

Neuronale Aktivierungsprozesse bei akuter PTSD: eine fMRI-Fallstudie bei zwei Patienten nach schwerer Unfalltraumatisierung

Abstract

Neuroimaging research on the neurobiology of chronic PTSD (post-traumatic stress disorder) has revealed structural and functional alterations primarily affecting areas of the medial temporal lobe (hippocampus, amygdala, and parahippocampal gyrus) and the frontal cortex known to be associated with the disorder. Using functional magnetic resonance imaging (fMRI), the present study studied the functional neuroanatomy of traumatic and non-traumatic emotional memory in two surgical patients who had sustained severe accident trauma. While patient 1 had developed acute PTSD following the traumatic event, patient 2 (control) did not. When confronted with traumatic (relative to negatively valenced non-traumatic) memory, the PTSD patient exhibited evidence for increased neural activity in the right and the left superior temporal lobe, the amygdala, the left angular gyrus, and the medial frontal gyrus, while the non-PTSD patient exposed to identical conditions showed increased activations in frontal and parietal regions. Both patients exhibited identical activation patterns when recalling non-traumatic memories relative to neutral memories. It is concluded that the pronounced activation patterns in the PTSD patient may be considered specific for acute PTSD, involved with the emotional arousal and the vivid visual recollections typical for the acute phase of the disorder.

Zusammenfassung

Neuere bildgebende Studien zur Neurobiologie der chronifizierten PTSD lassen vermuten, dass das Störungsbild sowohl mit funktionellen als auch strukturellen Veränderungen in umschriebenen Hirnregionen des medialen Temporallappens (Hippokampus, Amygdala, Parahippokampaler Gyrus) und des frontalen Cortex einhergeht. Die vorliegende fMRT(funktionelle Magnetresonanztomografie)-Studie untersuchte die funktionelle Neuroanatomie traumatischer und nicht-traumatischer Erinnerungen bei zwei chirurgischen Patienten nach schwerer Unfalltraumatisierung. Nur Patient 1 entwickelte eine akute PTSD, während Patient 2 ohne klinisch relevante PTSD-Symptomatik blieb. Konfrontiert mit der Unfall Erinnerung (im Vergleich zu negativen, aber nicht traumatischen Erinnerungen) zeigte der PTSD-Patient vermehrte neuronale Aktivitäten im Bereich des rechten und linken superioren Temporallappens, im Bereich der Amygdalae, des linken Gyrus angularis, und des Gyrus frontalis medialis. Der Patient ohne PTSD-Symptome zeigte bei gleichen Untersuchungsbedingungen vermehrte neuronale Aktivitäten in frontalen und parietalen Regionen. Beide Patienten zeigten identische Aktivierungsmuster für den Vergleich negativer, nicht-traumatischer zu neutralen Erinnerungen. Die Untersuchungsergebnisse lassen vermuten, dass die besonderen Aktivierungsmuster bei dem Patienten mit akuter PTSD spezifisch für das Stadium einer akuten PTSD sind, die typischer-

Guido Flatten¹
Volker Perlitz¹
Martina Pestinger¹
Tuncay Arin¹
Barbara Kohl²
Frank Kastrau³
Ralph Schnitker³
René Vohn³
Jochen Weber³
Michael Ohnhaus²
Ernst R. Petzold¹
Hans J. Erli²

1 Department of Psychosomatics and Psychotherapeutic Medicine, RWTH Aachen, Germany

2 Department of Trauma Surgery, RWTH Aachen, Germany

3 Interdisciplinary Centre for Clinical Research (ICCR), Functional Neuroimaging Unit, RWTH Aachen, Germany

weise durch sehr lebendige und emotional belastende Wiedererinnerungen der traumatischen Situation charakterisiert ist.

Introduction

Posttraumatic Stress Disorder (PTSD) is characterized by intrusive memories which expose patients to repetitive and vivid recollections of trauma-related cognitive, emotive and sensory input. These memories frequently provoke a state of hypervigilance and hyperarousal which is typically accompanied by various vegetative symptoms. Neurobiological research has provided sound evidence in support of the hypothesis of neurotoxicity of stress-related increases in steroid hormones which enhance the vulnerability of central nervous structures causing memory dysfunctions. Due to the extended time courses frequently observed in PTSD, this disorder has been suggested to induce a variety of chronic alterations in neural plasticity which affect both brain functions and behaviour [8].

Functional neuroimaging SPECT (single photon emission computed tomography) [27], PET (positron emission tomography) [31], [37], [4], [6], [18] and fMRI (functional magnetic resonance imaging) studies [32], [39], [22], [23], [24], [25] supplied understanding of the neural activation patterns associated with the disorder using script-driven imagery as a reliable method for symptom provocation in PTSD patients during trauma-related memory retrieval. It was suggested that in chronic PTSD patients processing of emotional and stress related memories results in dysfunctions of PTSD specific brain areas and neural networks [6]. These PTSD-related neural networks include various subcortical limbic brain regions: the amygdaloid complex, the hippocampal formation, and structures of the limbic cortex, such as orbitofrontal and anterior cingulate areas [27]. In the PET study by Rauch et al. [31], exposure to traumatic scripts was shown to increase limbic regional blood flow in the right amygdala, insula, orbitofrontal cortex, and the anterior cingulate while blood flow in the left middle temporal gyrus and inferior frontal cortex decreased. Vietnam veterans with combat-related PTSD, however, did not exhibit clear orbitofrontal cortex activation in response to combat-related acoustic and visual contents when compared to Vietnam veterans without combat-related PTSD [3]. Another PET study on PTSD patients by Shin et al. [37] revealed a relative failure of orbitofrontal cortex activation, an increase in blood flow in the right amygdala and anterior cingulate, and a decrease in blood flow in the left middle temporal and inferior frontal cortices induced by combat trauma-related (versus neutral) mental imagery (relative to healthy controls). Using functional MRI and script-driven imagery, Lanius et al. [24] more recently compared nine patients who had developed PTSD subsequent to sexual abuse or motor vehicle accidents to controls who merely met DSM-IV A criteria for PTSD (relevant traumatic experience according to the Diagnostic and Statistical Manual of Mental Disorders, APA [1]). In the control group, bilateral activations of the thalamus, anterior cingulate, medial frontal gyrus, as well as right occipital cortex ex-

ceeded that observed in patients with full-blown PTSD. These findings strongly suggest PTSD-related alterations of brain activation affecting those regions of the brain engaged in memory processing. Owing to Brewin's dual representation model, processing of traumatic memories possibly uses specific pathways referred to as the 'situational accessible memories system' (SAM) [7]. It remains a key question for the understanding of PTSD whether there are different pathways engaged in the encoding and retrieval of traumatic and non-traumatic memories. Recent findings suggest traumatic stress to frequently induce a functional block and/or inhibition of fronto-temporal pathways which can then lead to the formation of rather isolated neural networks which are responsible for the processing of trauma dominated information [25]. Regarding memory consolidation as a time dependent process, re-confrontation with traumatic memories is likely to result different activation patterns, depending on the temporal stage of traumatic information processing.

The DSM-IV defines acute PTSD as a transient disorder with symptoms prevailing less than three months in contrast to the chronic form of PTSD which is diagnosed in the case of symptoms prevailing longer than 3 month. Most neuroimaging studies conducted on PTSD focused exclusively on the chronic stage of the disorder. Only recently, Lanius et al. [22] published a first fMRI case study on acute PTSD in a couple surviving a severe motor vehicle accident. Hence, little is known about traumatic information processing in the acute stage. Our present fMRI study aimed at expanding the current understanding of acute trauma-related information processing by assessing the functional neuroanatomy of traumatic and non-traumatic emotional memory in two patients with acute PTSD following accident trauma.

Materials and methods

Subjects

2 right-handed, male subjects were enrolled in the study who had recently experienced an accident trauma. Patient 1 (aged 21) developed acute PTSD according to DSM IV criteria [45] following a motor vehicle accident. Patient 2 (aged 40) suffered a severe accident on a construction site sustaining a T7/8 paraplegia without developing a PTSD. None of the patients reported any previous or current psychiatric or neurological diagnoses. Psychometric testing yielded diverging results for both patients: patient 1 (PTSD) scored on the IES (Impact of Event Scale, German Version) 21, patient 2 scored 11 (cut-off 19). For diagnosis of acute PTSD, the Structured Clinical Interview for DSM IV (SCID I) was also applied [45]. Patient 1 met all DSM-IV criteria for acute PTSD, while patient 2 did not. The HADS (Hospital Anxiety and Depression Scale) was

also employed, but did not exhibit any relevant differences between both patients [19].

Both patients were tested within identical time frames after suffering their accidents: patient 1 (PTSD) was tested on day 21, patient 2 (no PTSD) on day 24 following the accident. Written informed consent was obtained from each patient prior to participation, and the study was approved by the local ethics committee.

Stimuli

Three individualized stimuli were obtained for each patient by means of a semi-structured interview (duration = 60 min; time-interval between interview and scanning session 1 week): one of their traumatic accident event, a second of a negative, but non-incriminating life event, and a third of a neutral episode. Patients were asked to provide as many details and contextual information for each of the remembered episodes as possible to allow for the preparation of scripts describing specific situations of the respective episodes. Scripts were presented during scanning to trigger the subjects' memories of each episode. The total number of words included in each script was 160 ± 5 . Scripts were read by a sex-matched person not involved in the study and recorded in a professional media center.

Tasks and experimental design

The experimental paradigm used in the present study is commonly termed script driven imagery. In previous functional neuroimaging studies on traumatic memory [e.g. [23], [38]], this paradigm was shown to reliably trigger highly emotional memories and symptoms typically associated with trauma-related memory retrieval in PTSD (flashbacks, intrusions, dissociation, depersonalisation, derealisation). It has thus been effectively used for the provocation of symptoms in patients with PTSD and other psychiatric diseases frequently associated with traumatic experience. For auditory presentation of the scripts during the fMRI experiment, MR (magnetic resonance) compatible headphones and Cool Edit Pro 2.0 Software (Syntrillium Software Corporation, Phoenix, USA) were used. Lying in the MR scanner, patients listened to their scripts describing the traumatic accident episode, a negative non-traumatic or neutral autobiographical episode, respectively. An fMRI blocked design was applied to evoke the neural responses associated with the retrieval of emotionally arousing traumatic, negatively valenced but non-traumatic, and neutral memories. The neutral memory condition was used as the baseline condition.

A total of three experimental runs were completed, maintaining the same sequence of scripts used throughout. During each experimental run, each script was played once for 90 s, starting with the negative non-traumatic episode, followed by the accident trauma script, to be finished by presentation of the neutral event. Participants were instructed to remember the events and situations triggered by the scripts as vividly as possible

trying to re-experience events imagined. Order of conditions was not counterbalanced across runs and individuals since it was assumed disadvantageous to start with the traumatic episode as patients might have been unable to mentally distance the trauma event and adjust to the negative non-traumatic episode. Switching from the traumatic to the neutral episode, however, is known to reduce the level of emotional arousal inducing relaxation. For each condition, forty complete brain volumes (TR (repetition time) = 3 s) were acquired during each run. A total of three experimental runs each consisting of 3 memory blocks were performed, leading to the acquisition of 360 volumes per subject (120 volume images per run). Prior to scanning, subjects were familiarized with the experimental set-up and the tasks.

MR hardware and technical parameters

Scanning was performed using the equipment as detailed earlier [30]. In short, we employed a 1.5 T whole-body scanner (Philips Gyroscan NT, Hamburg, Germany) with echo-planar imaging (EPI) capability. For transmitting and receiving, a standard radiofrequency head coil was used. The fMRI paradigm consisted of 3 time-series, as described above.

Post-scanning debriefing

To assess successful recollection of the episodes triggered by the scripts, each subject was asked immediately after scanning to (1) indicate the scripts' quality of sound and (2) separately rate specific dimensions of the memories retrieved during scanning for each experimental condition on a visual analogue scale (VAS) ranging from 0 (not at all) to 10 (highly intense). The following items were used to identify typical features of emotional autobiographical memory retrieval: imagery, emotions associated with the memory, psychophysiological responses, picture-like memory, acoustical perceptions, haptic perceptions, olfactory perceptions, gustatory perceptions, and subjective discomfort.

Image processing

Image processing and all statistical calculations were performed on Ultra 20 workstations (SUN Microsystems Computers) using MATLAB 6 (The Mathworks Inc., Natick, MA, USA) and SPM2 (Statistical Parametric Mapping software, SPM; Wellcome Department of Cognitive Neurology, London, UK; <http://www.fil.ion.ucl.ac.uk>). SPM2 was employed for image preprocessing (image realignment, normalization, and smoothing) and to create statistical maps of changes in relative regional BOLD (blood oxygenation level dependent) responses corresponding to the two emotional memory conditions and the baseline [14], [15].

The first 2 images of each time-series were discarded to allow the MR signal to reach steady state. To correct for head movement between scans, the remaining 120

volume images of each time-series were realigned to the first image. Thereafter, images were transformed into standard stereotactic space as defined by Talairach and Tournoux [42] using linear proportions and a non-linear sampling algorithm. The intercommissural AC (anterior commissure)-PC (posterior commissure) line was used as the reference plane [14]. For this normalization procedure, a representative brain from the Montreal Neurological Institute (MNI) series provided by SPM2 was employed as the reference template [11]. Subsequently, all data were expressed in terms of standard stereotactic x-, y-, and z-coordinates using the Talairach and Tournoux stereotactic space convention. The resulting pixel size was 2 x 2 mm with an interplane distance of 2 mm. Following normalization procedures, transformed data were smoothed with a Gaussian kernel of 8 mm (full width half maximum) to compensate for normal variation in individual brain size and shape, as well as gyral and sulcal anatomy across subjects, and to meet the statistical requirements of the theory of Gaussian random fields presupposed by the General Linear Model employed in SPM2.

Statistical analyses

Following image pre-processing, statistical analyses of functional MR data were performed. Subject-specific low frequency drifts in signal were modeled and removed using low frequency cosine waves, and proportional scaling normalized the global means. Data analysis was performed by modeling the experimental memory conditions (traumatic and negative non-traumatic memories) and the baseline (neutral memories) by means of reference waveforms which correspond to boxcar functions convolved with a haemodynamic response function [14]. Accordingly, a design matrix which comprised contrasts modeling alternating intervals of "activation" (referring to the two different experimental memory conditions) and "baseline" (referring to the neutral memory condition) was defined. Specific effects were assessed by applying appropriate linear contrasts to the parameter estimates of the two experimental conditions and the baseline resulting in t-statistics for each voxel. These constituted Statistical Parametric Maps (SPM_T) of differences between both the memory conditions and between the memory conditions and the baseline. SPM_T -statistics were interpreted in light of the theory of probabilistic behavior of Gaussian random fields. Voxels had to pass a height threshold of $T = 4.61$ ($p < 0.05$, corrected for multiple comparisons) in order to be identified as reflecting statistically significant activation. However, for medial temporal areas, specifically, the amygdala and the hippocampus, and for several cortical areas of interest, statistical threshold was set to $T = 3.09$ ($p < 0.001$, uncorrected) since the Bonferroni correction was supposed to be too stringent for the use in the analysis of functional neuroimaging data. It has been shown evidence that this classic method of statistical correction frequently wipes out areas of significant activations and thus yields a reduced view of the activation patterns associated with a specific cognitive

and/or emotional task demand [13]. Small volume corrections for predefined regions of interest (ROI) were not applied since the definition of commonly used ROIs is based on neuroimaging research on patients with chronic PTSD. Rather, the present study explicitly aimed at assessing putative differences in neural activations associated with traumatic memory retrieval in patients with acute compared to those with chronic PTSD. An extent threshold of 10 voxels was applied.

Masking of the relevant contrasts was performed to assess whether or not relative increases in neural activity between conditions reflected activations in the condition of interest or rather deactivations in the other (relative to baseline).

Data were analyzed for the overall effect of negatively valenced emotional autobiographical memory retrieval contrasting the joint traumatic and negative non-traumatic experimental conditions with the baseline, for the simple effects of the two emotional memory conditions contrasting each experimental condition separately with the baseline, and for the main effect of trauma contrasting the traumatic with the negative non-traumatic condition, and vice versa.

Localization of activations

Standard stereotactic coordinates of pixels showing local maximum activation were determined within areas of significant relative changes in neural activity associated with the demands of the different memory conditions. These local maxima were anatomically localized by reference to a standard stereotactic atlas [42]. For validation of this method of localization, SPM_T -statistics were superimposed on the T_1 -weighted individual 3D high resolution anatomical MR acquired for each patient prior to functional neuroimaging.

Results

Brain activity associated with the effect of traumatic memory versus negative non-traumatic memory

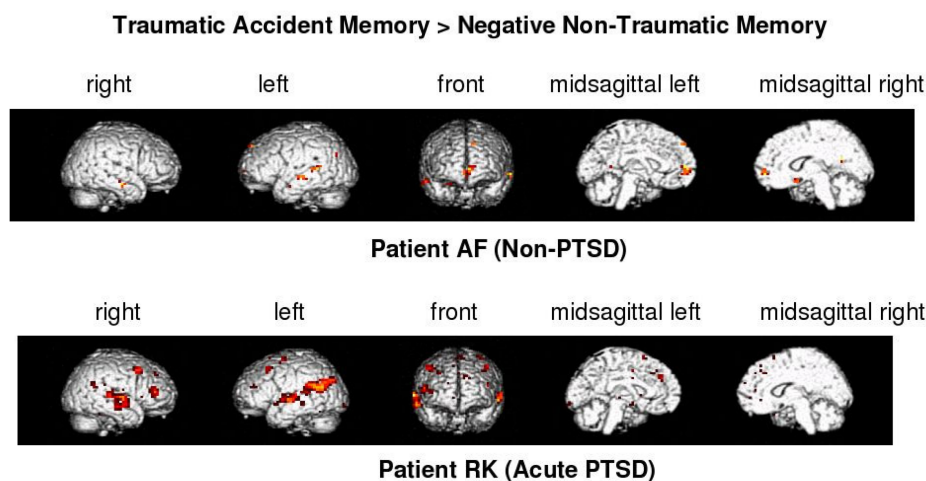
When contrasting traumatic negative non-traumatic memory, the non-PTSD patient showed statistically significant activation of the right inferior frontal gyrus ($p < 0.05$, corrected for multiple comparisons). At a lower statistical threshold ($p < 0.001$, uncorrected) increased neural activity was also observed in left medial frontal gyrus and precuneus (see Table 1a). By contrast, the PTSD patient significantly activated the left angular gyrus and the right superior temporal gyrus ($p < 0.05$, corrected for multiple comparisons) during the retrieval of the traumatic accident episode. When a lower statistical threshold was applied ($p < 0.001$, uncorrected), there were also activations in the left superior temporal and medial frontal gyri, the

Table 1: Brain areas activated during the retrieval of traumatic and negative non-traumatic memories in patient RK (with acute PTSD) and patient AF (without PTSD)

Brain regions showing relative significant BOLD signal increases associated with (a) traumatic relative to negative non-traumatic memory and (b) vice versa, as well as (c) negative non-traumatic memory versus baseline in patient AF (non-PTSD) and patient RK (PTSD). For each region of activation, the coordinates in standard stereotactic space are given referring to the maximally activated focus within an area of activation as indicated by the highest T-value. x, distance (mm) to right (+) or left (-) of the midsagittal plane; y, distance anterior (+) or posterior (-) to vertical plane through the anterior commissure; z, distance above (+) or below (-) the inter-commissural (AC-PC) plane. L = left, R = right, M = medial.

Region	Side	X	Y	Z	p value	z-Score (T value)
(a) Traumatic > Negative Non-Traumatic Memory						
AF (without PTSD)						
Gyrus frontalis inferior (BA 13)	R	32	7	-10	0.017	4.84 (4.93)*
Gyrus frontalis medialis (BA 10)	L	-8	55	5	0.660	4.05 (4.10)
Parietal cortex: Precuneus (BA 19)	L	-32	-68	33	0.814	3.92 (3.97)
RK (PTSD)						
Gyrus angularis (BA39)	L	-44	-76	33	0.000	6.45 (6.66)*
Gyrus temporalis superior (BA 21)	R	67	-8	4	0.016	4.85 (4.93)*
Gyrus temporalis superior (BA 22)	L	-63	-16	1	0.063	4.64 (4.57)
Motorischer Cortex (BA 6)	R	40	14	44	0.075	4.53 (4.60)
Gyrus frontalis medius (BA 9)	L	-12	44	27	0.084	4.51 (4.58)
Amygdala	L	-24	-1	-10	0.977	3.69 (3.73)
(b) Negative Non-Traumatic > Neutral Memory						
AF (without PTSD)						
Gyrus temporalis medius (BA 21)	R	63	-12	-13	0.000	6.13 (6.31)*
Gyrus temporalis superior (BA 22)	L	-55	-11	4	0.000	5.71 (5.85)*
Gyrus temporalis superior (BA 22)	L	-63	-39	6	0.001	5.38 (5.51)*
RK (PTSD)						
Gyrus temporalis superior (BA 22)	R	63	-11	4	0.000	5.53 (5.66)*
Gyrus temporalis superior (BA 22)	L	-59	-8	0	0.004	5.14 (5.25)*
Gyrus temporalis superior (BA 41)	L	-53	-23	9	0.032	4.71 (4.79)*
(c) Negative Non-Traumatic > Traumatic Memory						
AF (without PTSD)						
Gyrus temporalis superior (BA 22)	R	55	12	-1	0.041	4.66 (4.74)*
Parietaler Cortex: postzentr. gyrus (BA 7)	R	12	-47	72	0.620	4.07 (4.12)
Gyrus frontalis medius (BA 9)	R	40	33	32	0.848	3.89 (3.93)
RK (PTSD)						
No statistically significant activations						

* = significant at $p < 0.05$, corrected for multiple comparisons



Flatten et al. Fig. 1

Figure 1: Relative increases in neural activity associated with traumatic accident memories compared to negative non-traumatic autobiographical memories in patient AF non-PTSD and patient RK (acute PTSD). The local maxima of areas of statistically significant relative increases in neural activity are superimposed on sections of the T_1 -weighted high resolution MR template provided by SPM2 to depict the functional anatomy of the activations and their relationship to the underlying structural anatomy. Standard stereotactic coordinates of the pixels with the local maximum of activation were determined within areas of significant relative changes in neural activity associated with the two different memory conditions. These local maxima were anatomically localized by reference to a standard stereotactic atlas [42]. The figure focuses on medial temporal lobe activations associated with traumatic memory. The exact coordinates of the local maxima within the areas of activation and their t-statistics are shown in Table 1a.

left amygdala, and the right motor cortex (see Table 1a and Figure 1).

Brain activity associated with the simple effect of negative non-traumatic memories versus baseline (neutral memories)

Comparing negative non-traumatic memories with the neutral memory baseline condition, identical activation patterns were observed in both patients: local maxima in the right middle temporal gyrus and the left superior temporal gyrus in the non-PTSD patient, and bilateral activation of the superior temporal gyrus in the PTSD patient, meaning that the right hemisphere activation peak was located slightly above the right temporal activation observed in the non-PTSD patient (see Table 1b and Figure 2).

Brain activity associated with the effect of non-traumatic versus traumatic memory

In the non-PTSD patient, negative non-traumatic memories (relative to traumatic accident memories) significantly increased neural activity ($p < 0.05$, corrected for multiple comparisons) in the right superior temporal gyrus. Application of a lower statistical threshold revealed additional activations of the right postcentral gyrus and the medial frontal gyrus (see Table 1b). In the PTSD patient, there were no significant activations associated

with the contrast between negative non-traumatic and traumatic memories, even at the lower statistical threshold of $p < 0.001$ (uncorrected, see Table 1c and Figure 3).

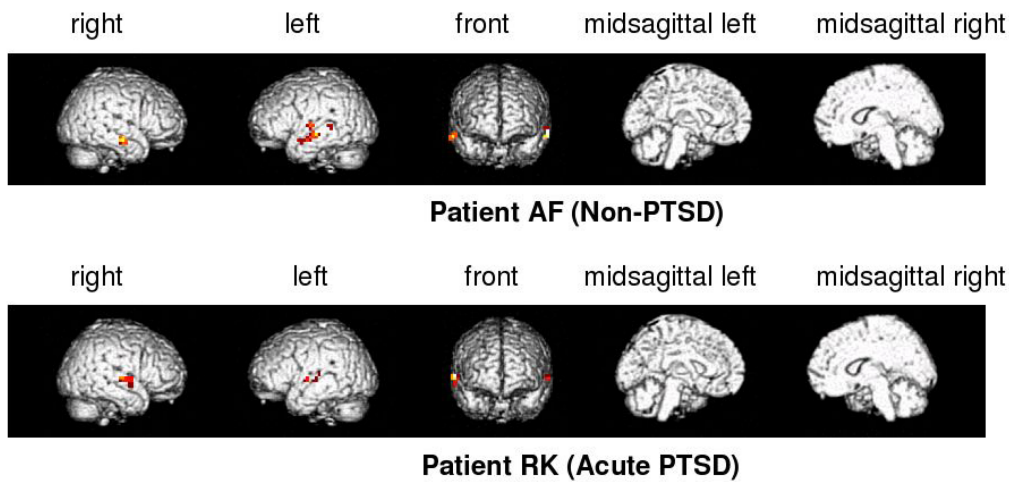
Post-scanning debriefing procedures

Post-scanning assessment of the memories retrieved during the fMRI measurement revealed that the PTSD patient rated memories triggered by the trauma script higher for all items of our questionnaire than did the non-PTSD patient. This difference was most evident for the item 'subjective discomfort induced by the trauma script' (PTSD patient rated 10 while non-PTSD patient rated 5).

Discussion

We present neuroimaging data of two patients who sustained severe accident related trauma. While one patient developed acute PTSD, the other did not. We observed marked differences in neural correlates of traumatic and non-traumatic memory between both patients. Confronted with the traumatic episode relative to a negative non-traumatic memory, the patient with acute PTSD showed increased activations predominantly in the angular gyrus and the amygdala. Since PTSD is typically associated with vivid visual recollections of traumatic experiences, activation of visual areas such as the angular gyrus can be interpreted to represent intrusive recollection. Activation of the amygdala appears to be also responsible for the high degree of emotional disturbance known to coincide with the subjective recollection of the traumatic situation

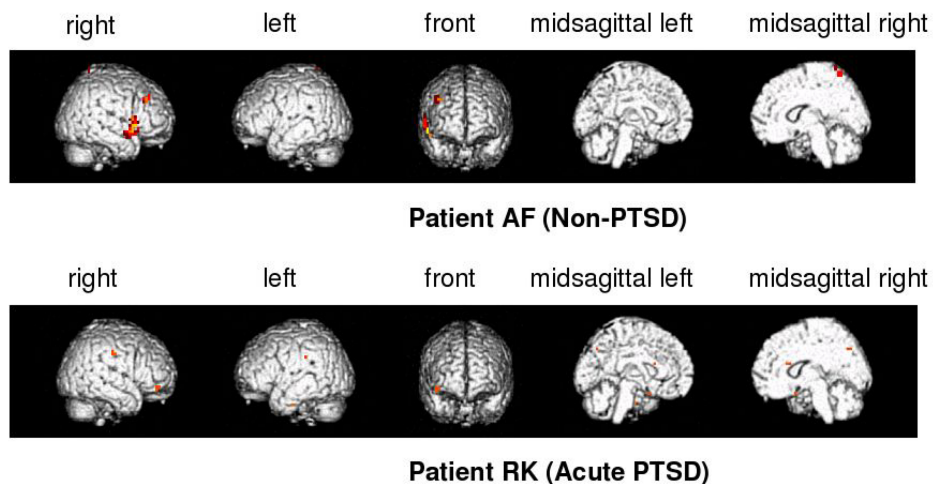
Negative Non-Traumatic Memory > Neutral Memory (Baseline)



Flatten et al. Fig 2

Figure 2: Relative increases in neural activity associated with negative non-traumatic autobiographical memories compared to neutral memories in patient AF (non-PTSD) and patient RK (acute PTSD). The local maxima of areas of statistically significant relative increases in neural activity are superimposed on sections of the T_1 -weighted high resolution MR template provided by SPM2 to depict the functional anatomy of the activations and their relationship to the underlying structural anatomy. Standard stereotactic coordinates of the pixels with the local maximum of activation were determined within areas of significant relative changes in neural activity associated with the two different memory conditions. These local maxima were anatomically localized by reference to a standard stereotactic atlas [42]. The exact coordinates of the local maxima within the areas of activation and their t-statistics are shown in Table 1b.

Negative Non-Traumatic Memory > Traumatic Accident Memory



Flatten et al. Fig 3

Figure 3: Relative increases in neural activity associated with negative non-traumatic autobiographical memories compared to traumatic accident memories in patient AF (non-PTSD) and patient RK (acute PTSD). The local maxima of areas of statistically significant relative increases in neural activity are superimposed on sections of the T_1 -weighted high resolution MR template provided by SPM2 to depict the functional anatomy of the activations and their relationship to the underlying structural anatomy. Standard stereotactic coordinates of the pixels with the local maximum of activation were determined within areas of significant relative changes in neural activity associated with the two different memory conditions. These local maxima were anatomically localized by reference to a standard stereotactic atlas [42]. The exact coordinates of the local maxima within the areas of activation and their t-statistics are shown in Table 1c.

[44]. Analysis of the reverse contrast (non-traumatic versus traumatic memory) confirmed that there were no dominant activations for the contrast of negative non-traumatic to traumatic memories. Hence, our findings apparently support the notion that during the acute stage of traumatic memory processing, traumatic stimuli (relative to non-traumatic ones) lead to a differential activation of brain regions in that the same, and also additional brain regions were activated, however to a higher degree. Clinical symptoms of PTSD, defined as a complex of sensory and emotive responses can be readily attributed to the neural activation pattern observed in our PTSD patient. This notion is corroborated by a review on neuroimaging findings in PTSD [35], [21]. In the studies reviewed, the most frequently observed circumscribed functional changes included increases in the activation of the amygdala following symptom provocation (which is likely to reflect its role in emotional memory) on the one hand, and simultaneous decreases in the activation of Broca's area at the same time (which may explain the problem of patients to describe their experiences) on the other hand. In the patient who did not develop PTSD, we observed clear differences in brain activation following confrontation with trauma-related memories, relative to negative non-traumatic memories specifically within frontal and parietal regions well known to be engaged in the processing of non-traumatic memories [36]. This suggests activation of these regions to be possibly characteristic of processes for the successful cognitive restructuring when coping with overwhelming emotions. Moreover, the reverse contrast (negative non-traumatic relative to traumatic memory) was associated with right hemisphere activations in the superior temporal gyrus, the medial frontal gyrus, and the postcentral gyrus. Most of these regions were described earlier to play a crucial role in the processing and retrieval of autobiographical memories [12], [28].

In our study, the contrast of negative non-traumatic to neutral memories served as a control condition to investigate the specificity of neural responses to the three stimuli used in our present study. Analyses of this contrast showed highly similar bilateral activation of the superior temporal gyrus in both patients. We consider this finding important proof of the reliability of stimulus presentation used since it apparently successfully activated identical patterns in brain regions known to be part of the autobiographical memory system. Activations found in response to this contrast condition confirm the hypothesis that patients do not differ with regard to the processing of negative non-traumatic and neutral memories, but exclusively with respect to traumatic memory processing. Thus, it is reasonable to assume that in acute PTSD, patients do not suffer episodic memory disturbances in a more general sense. It may corroborate the hypothesis of Sierra and Berrios [40] who suggested dysfunctional trauma related activations in the corticolimbic system as a cause for clinical symptoms such as dissociation and depersonalization. Based on her findings in a fMRI study, Lanius [25] recently concluded that prefrontal and limbic struc-

tures underlie dissociative responses in PTSD patients. This conclusion also supports the hypothesis of neural specificity of information processing in PTSD-related states leading to distinct activations associated with traumatic and non-traumatic memory recollection. Hence, brain regions exhibiting altered neural activity associated with trauma-related memory retrieval relative to non-traumatic memory in our PTSD patient are widely similar to those reported in previous studies on functional brain alterations in chronic PTSD patients [4], [5], [6], [23], [24]. This finding is of importance with regard to the question whether different neural structures are engaged in the acute and chronic stage of PTSD. If there were merely different activation patterns in otherwise identical neural structures, intervention strategies were to be designed to prevent chronification of traumatic information processing. Owing to Lanius et al. [24], traumatic recollection in chronic PTSD patients significantly increased bilateral activation of the thalamus, medial frontal gyri, anterior cingulate gyri, as well as the right occipital lobe. In contrast, the retrieval of traumatic (relative to negatively valenced non-traumatic) memories in our study in two acutely traumatized patients was associated with significant medial and lateral temporal activations. Although the lateral temporal activations are likely to result at least partially from auditory presentation of the scripts, the modality of stimulus presentation cannot account solely for the differences observed. It is thus reasonable to assume medial and lateral temporal areas to play a key role specifically during the acute stage of the PTSD. This notion is supported by a wealth of studies on hippocampal and amygdala functions in memory consolidation, including animal research [41], [43], neuropsychological assessment of patients with hippocampal damage [2], [33], and functional neuroimaging studies on human episodic memory [17], [30]. The clear lateral temporal activations allow to hypothesize lateral temporal areas transiently acting as sites of memory storage. In conclusion, our findings are well in agreement with current models of emotional processing in adaptation to stressful events.

The emotionally overwhelming and stressful (i.e. not adaptive) recollection of traumatic experiences, one of the key symptoms of PTSD, causes persisting states of hyperarousal due to the tight intertwinement between the emotional limbic system, the autonomic nervous system, and the Hypothalamic-Pituitary-Adrenal (HPA) axis. The frontal pole and adjacent medial frontal activations observed in the present study are thus in keeping with current knowledge on functions of the medial prefrontal cortex. Since these brain areas are known to mediate interactions between various neural circuits engaged in the cognitive control of memory and emotion processing, as well as working memory and attention, activation of these regions may be indicative of a successful cognitive and emotional adaptation to the patients' negative non-traumatic memories.

In summary, the findings presented in our present study supply evidence for differential activation patterns in two

acutely traumatized patients related to the PTSD and non-PTSD state. In the case of the PTSD patient, we observed dominating activations in regions representing the visual (gyrus angularis) and emotional (amygdala) aspect of traumatic recollection, while in the non-PTSD patient, we observed activation in the frontal and temporal areas which have been repeatedly found to be involved in the retrieval of non-traumatic autobiographical memories [12], [30]. Still, at a lower statistical threshold, the PTSD patient also exhibited frontal and temporal activations. We therefore hypothesize that this finding may in part be due to the acute phase of the posttraumatic process which corroborates the notion of an incomplete fronto-temporal dissociation contrasting the complete corticolimbic disconnection associated with the chronic PTSD state. We have to concede, though, that the findings of this study are limited to the two cases presented. There is need for extending our data employing a controlled group design. Yet, our findings match clinical observations of posttraumatic adaptation processes in acute PTSD patients which can be described as a time-dependent integration of information mediated by prefrontal areas. In this light, incomplete processing of trauma experiences appears to be reflected by neural activation patterns at a lower frontal involvement and enhanced neural activity in limbic areas of the medial temporal lobe. The neural networks activated during the retrieval of traumatic memories in patients with acute PTSD resemble those reported from neuroimaging studies on chronic PTSD patients, although we were able to observe activations in brain areas unknown to be affected by chronic PTSD. It is reasonable to assume that alterations in traumatic memory-related activation patterns during the course of PTSD are based on mechanisms of neural plasticity which have yet not been identified. The role of neuroplasticity in the progress of PTSD will thus also require further investigation. Although the results of this case study are preliminary, our data underscore the importance of acute PTSD as a topic for future research which may also contribute to the discussion on the question whether secondary preventive interventions of trauma therapy can effect the neural mechanisms underlying the chronification of PTSD symptoms.

Acknowledgements

We wish to thank the Department of Neuroradiology and the fMRI staff of the Interdisciplinary Centre for Clinical Research (ICCR) for their expert technical assistance. F.K., R.S., R.V., and J.W. are supported by the ICCR.

References

1. American Psychiatric Association. Diagnostic and Statistical Manual of Mental Disorders. 4th ed. Washington DC: American Psychiatric Press; 1994.
2. Bak H, Antoun N, Balan KK, Hodges JR. Memory lost, memory regained: neuropsychological findings and neuroimaging in two cases of paraneoplastic limbic encephalitis with radically different outcomes. *J Neurol Neurosurg Psychiatry*. 2001;71: 40-7.
3. Bremner JD, Innis RB, Ng CK, Staib LH, Salomon RM, Bronen RA et al. Positron emission tomography measurement of cerebral metabolic correlates of yohimbine administration in combat-related posttraumatic stress disorder. *Arch Gen Psychiatry*. 1997; 54:246-54.
4. Bremner JD, Narayan M, Staib LH, Southwick SM, McGlashan TH, Charney DS. Neural correlates of memories of childhood sexual abuse in women with and without posttraumatic stress disorder. *Am J Psychiatry*. 1999;156:787-95.
5. Bremner JD, Southwick SM, Darnell A, Charney DS. Chronic PTSD in Vietnam combat veterans: course of illness and substance abuse. *Am J Psychiatry*. 1996;153:369-75.
6. Bremner JD, Vythilingam M, Vermetten E, Southwick SM, McGlashan TH, Staib LH et al. Neural correlates of declarative memory for emotionally valenced words in women with posttraumatic stress disorder related to early childhood sexual abuse. *Biol Psychiatry*. 2003;53:879-89.
7. Brewin C; Holmes EA. Psychological theories of posttraumatic stress disorder. *Clin Psychology Rev*. 2003;23:339-76.
8. Chambers R, Bremner JD, Moghaddam B, Southwick SM, Charney DS, Krystal JH. Glutamate and post-traumatic stress disorder: toward a psychobiology of dissociation. *Semin Clin Neuropsychiatry*. 1999;4:274-84.
9. Damasio AR. Descartes' error and the future of human life. *Sci Am*. 1994;27:144.
10. Drevets WC, Price JL, Simpson JR, Todd RD, Reich T, Vannier M et al. Subgenual prefrontal cortex abnormalities in mood disorders. *Nature*. 1997;386:824-7.
11. Evans AC, Kamber M, Collins DL, MacDonald D. An MRI-based probabilistic atlas of neuroanatomy. In: Shorvon S, Fish D, Andermann F, Bydder GM, Stefan H, editors. *Magnetic Resonance Scanning and Epilepsy*. New York: Plenum Press; 1994. p. 263-74.
12. Fink GR, Markowitsch HJ, Reinkemeier M, Bruckbauer T, Kessler J, Heiss WD. Cerebral representation of one's own past: Neural networks involved in autobiographical memory. *J Neurosci*. 1996;16:4275-82.
13. Friston KJ. Testing for anatomically specified regional effects. *Hum Brain Mapp*. 1997;5:133-166.
14. Friston KJ, Ashburner J, Frith CD, Poline J-B, Heather JD, Frackowiak RSJ. Spatial registration and normalization of images. *Hum Brain Mapp*. 1995;3:165-89.
15. Friston KJ, Holmes A, Worsley KJ, Poline J-B, Frith CD, Frackowiak RSJ. Statistical parametric maps in functional imaging: a general linear approach. *Hum Brain Mapp*. 1995;2:189-210.
16. George MS, Ketter TA, Parekh PI, Horwitz B, Herscovitch P, Post RM. Brain activity during transient sadness and happiness in healthy women. *Am J Psychiatry*. 1995;152:341-51.
17. Haist F, Bowden GJ, Mao H. Consolidation of human memory over decades revealed by functional magnetic resonance imaging. *Nat Neurosci*. 2001;4:1139-45.
18. Hamann S. Cognitive and neural mechanisms of emotional memory. *Trends Cogn Sci*. 2001;1:394-400.
19. Hermann C, Buss U, Snaith RP. HADS-D Hospital Anxiety and Depression Scale - Deutsche Version. Ein Fragebogen zur Erfassung von Angst und Depressivität in der somatischen Medizin. Textdokumentation und Handanweisung. Bern, Göttingen, Toronto: Verlag Hans Huber; 1995.

20. Hopper JW, van der Kolk BA. Retrieving, Assessing, and Classifying Traumatic Memories: a preliminary report on three case studies of a new standardized method. *J Aggress Maltreat Trauma*. 2001;4:33-71.
21. Hull AM. Neuroimaging findings in post-traumatic stress disorder: systematic review. *Br Psychiatry*. 2002;181:102-10.
22. Lanius RA, Hopper JW, Menon RS. Individual differences in a husband and wife who developed PTSD after a motor vehicle accident: a functional MRI case study. *Am J Psychiatry*. 2003;160:667-9.
23. Lanius RA, Williamson PC, Boksman K, Densmore M, Gupta M, Neufeld RW et al. Brain activation during script-driven imagery induced dissociative responses in PTSD: a functional magnetic resonance imaging investigation. *Biol Psychiatry*. 2002;52:305-11.
24. Lanius RA, Williamson PC, Densmore M, Boksman K, Gupta MA, Neufeld RW et al. Neural correlates of traumatic memories in posttraumatic stress disorder: a functional MRI investigation. *Am J Psychiatry*. 2001;158:1920-2.
25. Lanius RA, Williamson PC, Hopper JW, Densmore M, Boksman K, Gupta MA et al. Recall of emotional states in posttraumatic stress disorder: an fMRI investigation. *Biol Psychiatry*. 2003;53:204-10.
26. LeDoux, Joseph E. Setting "stress" into motion: brain mechanisms of stimulus evaluation. In: Friedman, Matthew J; Charney, Dennis S; Deutch, Ariel Y, editors. *Neurobiological and clinical consequences of stress: from normal adaptation to post-traumatic stress disorder*. Philadelphia: Lippincott-Raven; 1995. p. 125-34.
27. Liberzon I, Taylor SF, Amador R, Jung TD, Chamberlain KR, Minoshima S et al. Brain activation in PTSD in response to trauma-related stimuli. *Biol Psychiatry*. 1999;45:817-26.
28. Markowitsch HJ. Which brain regions are critically involved in the retrieval of old episodic memory? *Brain Res Rev*. 1995;21:117-27.
29. Nadel L, Moscovitch M. Memory consolidation, retrograde amnesia and the hippocampal complex. *Curr Opin Neurobiol*. 1997;7:217-27.
30. Piefke M, Weiss PH, Zilles K, Markowitsch HM, Fink GR. Differential remoteness and emotional tone modulate the neural correlates of autobiographical memory. *Brain*. 2003;126:650-68.
31. Rauch SL, Van der Kolk BA, Fisler RE, Alpert NM, Orr SP, Savage CR et al. A symptom provocation study of posttraumatic stress disorder using positron emission tomography and script-driven imagery. *Arch Gen Psychiatry*. 1996;53:380-7.
32. Rauch SL, Whalen PJ, Shin LM, McInerney SC, Macklin ML, Lasko NB et al. Exaggerated amygdala response to masked facial stimuli in posttraumatic stress disorder: a functional MRI study. *Biol Psychiatry*. 2000;47:769-76.
33. Rempel-Clover NL, Zola SM, Squire LR, Amaral DG. Three cases of enduring memory impairment after bilateral damage limited to the hippocampal formation. *J Neurosci*. 1996;16: 5233-55.
34. Ryan L, Nadel L, Keil K, Putnam K, Schnyder D, Trouard T et al. Hippocampal complex and retrieval of recent and very remote autobiographical memories: evidence from functional magnetic resonance imaging in neurologically intact people. *Hippocampus*. 2001;11:707-14.
35. Schmahl CG, Vermetten E, Elzinga BM, Bremner JD. Magnetic resonance imaging of hippocampal and amygdala volume in women with childhood abuse and borderline personality disorder. *Psychiatry Res Neuroimaging*. 2003;122: 193-8.
36. Shaw ME, Strother SC, McFarlane A, Morris PL, Anderson J, Clark CR, Egan GF. Abnormal functional connectivity in posttraumatic stress disorder. *Neuroimage*. 2002;15:661-74.
37. Shin LM, McNally RJ, Kosslyn SM, Thompson WL, Rauch SL, Alpert NM et al. A positron emission tomographic study of symptom provocation in PTSD. *Ann N Y Acad Sci*. 1997;821:521-3.
38. Shin LM, McNally RJ, Kosslyn SM, Thompson WL, Rauch SL, Alpert NM, et al. Regional cerebral blood flow during script-driven imagery in childhood sexual abuse-related PTSD: a PET investigation. *Am J Psychiatry*. 1999;156:575-84.
39. Shin LM, Whalen PJ, Pitman RK, Bush G, Macklin ML, Lasko NB et al. An fMRI study of anterior cingulate function in posttraumatic stress disorder. *Biol Psychiatry*. 2001;50:932-42.
40. Sierra M, Berrios GE. Depersonalization: Neurobiological perspectives. *Biol Psychiatry*. 1998;44:898-908.
41. Squire LR. Memory and the hippocampus: a synthesis from findings with rats, monkeys, and humans. *Psychol Rev*. 1992; 99:195-231.
42. Talairach J, Tournoux P. *Co-planar Stereotactic Atlas of the Human Brain*. Stuttgart: Thieme; 1988.
43. Teng E, Squire LR. Memory for places learned long ago is intact after hippocampal damage. *Nature*. 1999;400:675-7.
44. Vermetten E, Bremner JD. Olfaction as a traumatic reminder in posttraumatic stress disorder: case reports and review. *J Clin Psychiatry*. 2003;64:202-7.
45. Wittchen H, Wunderlich V, Gruschwitz S, Zaudig M. *Strukturiertes Klinisches Interview für DSM IV, Achse I: Psychische Störungen*. Göttingen: Hogrefe; 1997.

Corresponding author:

Dr. med. Guido Flatten

Department of Psychosomatics and Psychotherapeutic Medicine, University Hospital of the RWTH Aachen, Pauwelsstr. 30, 52074 Aachen, Tel.: ++49-241-40029044, Fax : ++49-241-40996873
gflatten@euripp.org

Please cite as

Flatten G, Perlitz V, Pestinger M, Arin T, Kohl B, Kastrau F, Schnitker R, Vohn R, Weber J, Ohnhaus M, Petzold ER, Erli HJ. *Neural processing of traumatic events in subjects suffering PTSD: a case study of two surgical patients with severe accident trauma*. *Psychosoc Med*. 2004;1:Doc06.

This article is freely available from

<http://www.egms.de/en/psm/2004-1/psm000006.shtml>

Copyright

©2004 Flatten et al. This is an Open Access article distributed under the terms of the Creative Commons Attribution License (<http://creativecommons.org/licenses/by-nc-nd/3.0/deed.en>). You are free: to Share – to copy, distribute and transmit the work, provided the original author and source are credited.