

Available online at [www.sciencedirect.com](http://www.sciencedirect.com)

ScienceDirect

journal homepage: [www.elsevier.com/locate/radcr](http://www.elsevier.com/locate/radcr)

## Case Report

# Pineal cyst apoplexy and memory loss: a novel complication <sup>☆</sup>

Arez Shafqat, MBBS medical student<sup>a,\*</sup>, Hanin Jaber AlGethami, MD<sup>b</sup>, Shameel Shafqat, MBBS medical student<sup>c</sup>, Syed Shafqat Ul Islam, MBBS, FCPS, FRCR<sup>d</sup>

<sup>a</sup> College of Medicine, Alfaisal University, Riyadh, Kingdom of Saudi Arabia

<sup>b</sup> Division of Neurology, Department of Pediatrics, King Salman Hospital, Riyadh, Kingdom of Saudi Arabia

<sup>c</sup> Medical College, Aga Khan University, Karachi, Pakistan

<sup>d</sup> Department of Radiology, King Salman Hospital, Riyadh, Kingdom of Saudi Arabia

## ARTICLE INFO

## Article history:

Received 26 June 2022

Revised 8 July 2022

Accepted 13 July 2022

Available online 5 August 2022

## Keywords:

Pineal gland

Cyst

Apoplexy

Trauma

Memory loss

## ABSTRACT

An 8-year-old boy presented to our hospital complaining of a bilateral headache associated with episodes of anterograde amnesia. He had a road traffic accident 3 years ago when a computed tomography (CT) scan revealed traumatic brain injury. In addition, a small pineal cyst (PC) was noted with minor intramural calcifications. A follow-up CT a day later demonstrated increased density in the pineal gland of 60 Hounsfield Units, suggestive of apoplectic changes in the PC. However, the patient was lost to follow-up and presented with memory loss a year and a half later, upon which CT and magnetic resonance imaging revealed enlargement of the PC. PC apoplexy is a very rare occurrence usually affecting young adult women; cases in children are rarely reported. Furthermore, PC apoplexy secondary to severe craniofacial trauma manifesting as memory loss has not yet been reported in the literature to the best of our knowledge.

© 2022 The Authors. Published by Elsevier Inc. on behalf of University of Washington.

This is an open access article under the CC BY-NC-ND license

(<http://creativecommons.org/licenses/by-nc-nd/4.0/>)

## Introduction

The advent of the magnetic resonance imaging (MRI) has increased the detection of pineal cysts (PCs). PCs affect all age groups but are especially prevalent in women between 20 and 30 years of age; a study evaluating PCs in 48,417 patients by

MRI found PCs in 478 patients (1%), of which 316 were female [1]. Most PCs are clinically benign, but larger cysts may cause symptoms related to mass effect, necessitating neurosurgical consultation. In terms of their course, most PCs remain stable over time, whereas others enlarge or become complicated to cause symptoms.

Pineal apoplexy is the most severe complication of PCs, featuring hemorrhagic necrosis of the pineal gland, and is by

Abbreviations: MRI, Magnetic resonance imaging; CT, Computed tomography; PC, Pineal cyst; HU, Hounsfield units; AD, Alzheimer's disease; A $\beta$ , Amyloid  $\beta$ .

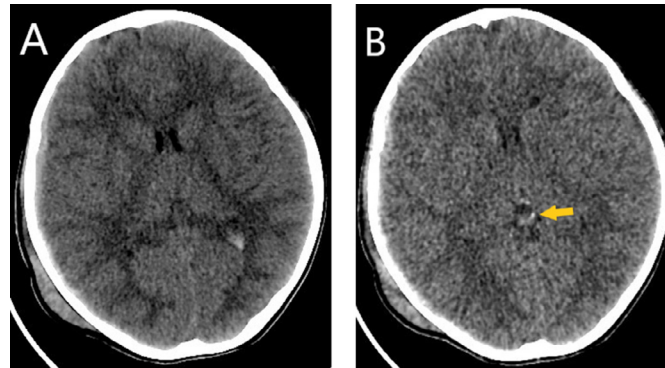
<sup>☆</sup> Competing Interests: The authors declare no conflicts of interest.

\* Corresponding author.

E-mail addresses: [ashafqat@alfaisal.edu](mailto:ashafqat@alfaisal.edu) (A. Shafqat), [hanin\\_88\\_jg@hotmail.com](mailto:hanin_88_jg@hotmail.com) (H.J. AlGethami), [shameel.shafqat@scholar.aku.edu](mailto:shameel.shafqat@scholar.aku.edu) (S. Shafqat), [drssislam@hotmail.com](mailto:drssislam@hotmail.com) (S.S.U. Islam).

<https://doi.org/10.1016/j.radcr.2022.07.055>

1930-0433/© 2022 The Authors. Published by Elsevier Inc. on behalf of University of Washington. This is an open access article under the CC BY-NC-ND license (<http://creativecommons.org/licenses/by-nc-nd/4.0/>)



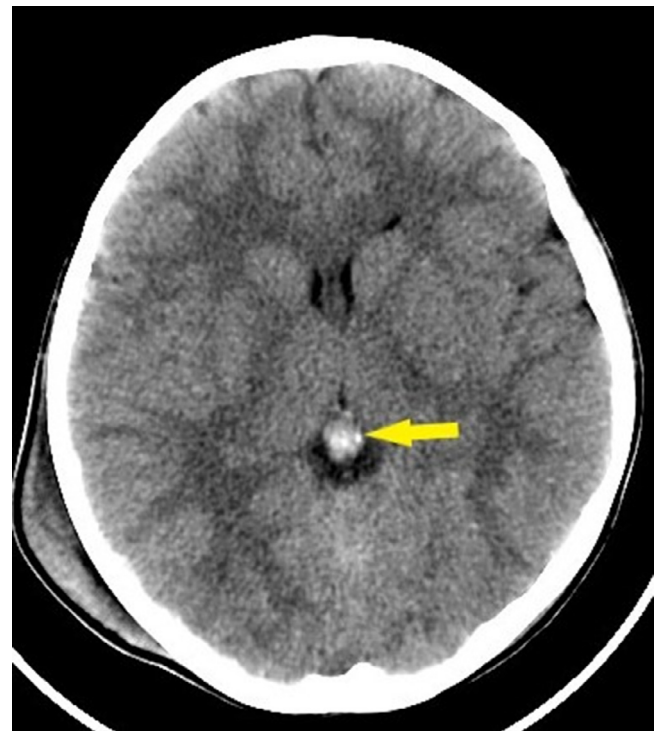
**Fig. 1 – (A) Axial CT reconstruction demonstrating right parietal subdural hematoma, intraventricular hemorrhage, right subgaleal hematoma. (B) A small Pineal cyst with small mural calcification noted (arrow).**

definition symptomatic with neurologic deterioration, potentially a medical emergency. Fortunately, PC apoplexies are exceedingly rare, and most occur in young adult women, but seldom in children. However, their rarity has limited our understanding of the etiopathogenesis, clinical manifestations, and conservative management of PC apoplexies. The present case reports a novel etiology and complication of PC apoplexies, trauma, and memory loss, respectively, occurring in an 8-year-old boy.

### Case presentation

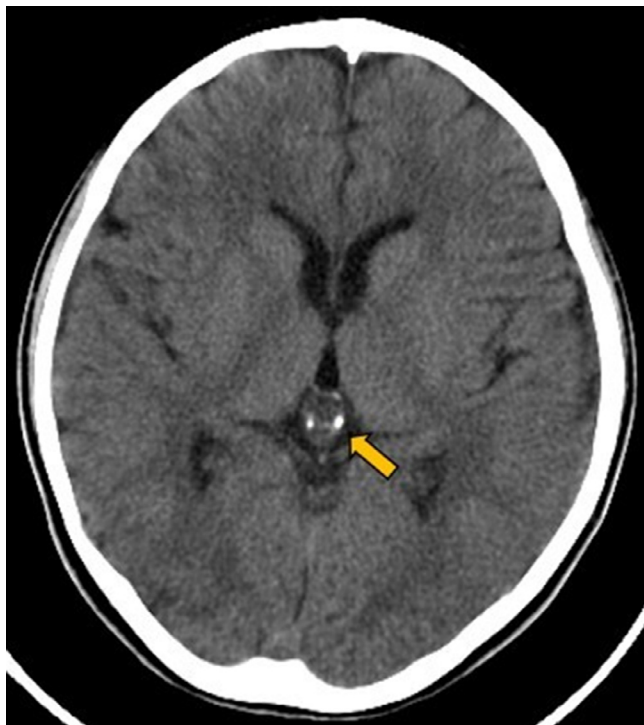A 9-year-old boy presented to the neurology clinic in November 2021 complaining of a bilateral headache – mild to moderate in severity – which lasted between minutes up to an hour and responded to analgesia. This was associated with episodes of anterograde amnesia, which significantly affected school performance, as described by the mother.

Our patient's past medical history revealed a prior admission to the PICU in September 2018 after he suffered a road traffic accident. CT brain without contrast performed at the time of presentation to evaluate for potential traumatic brain injury revealed mild brain edema, a small right-sided frontoparietal and temporal subdural hematoma with a maximum width of 3 mm, and intraventricular hemorrhage. No mass effect and midline shift was noted. Additionally, a focal left parietal lobe cortical contusion, right subgaleal hematoma, non-depressed linear right parietal bone fracture, small pneumocephalus, and mild neck surgical emphysema were seen. The pineal gland showed a small cyst with fluid density and a minor peripheral mural interrupted calcification on the left side (Fig. 1). Follow-up CT brain after 24 hours demonstrated mildly reduced width of the subdural hematoma and more conspicuous hemorrhagic contusional changes in frontal lobes. The pineal gland size was relatively increased, measuring 9 × 9 mm, and showed increased density (60 HU), suggestive of Pineal cyst apoplexy (Fig. 2). Our patient stayed in the hospital for three months. He was discharged with 6 months of extensive rehabilitation therapy.



**Fig. 2 – Follow-up CT 24 hours after admission revealing hyperdense signals in the region of the pineal gland, indicating apoplexy (arrow).**

However, after 2 months posthospitalization the patient developed episodes of a mild headache, later developing anterograde amnesia, which disturbed his educational memory. He was then lost to follow-up and contacted the primary physician after almost 2 years of the initial episode. After clinical evaluation, the patient was advised to undergo a repeat CT scan of the Brain, which noted the persistence of the pineal cyst with bilateral mural calcifications (Fig. 3). MRI Brain without contrast was performed in which the only positive finding was a cyst in the pineal gland (Fig. 4). After reviewing all the previous imaging and clinically correlating it with the his-



**Fig. 3 – Follow-up CT after 3 years showing enlargement of the pineal cyst with bilateral mural calcifications (arrow).**

tory of anterograde amnesia, we concluded the case as post-traumatic pineal cyst apoplexy complicated by memory loss. The patient was advised to have periodical Neurology outpatient clinic visits for further monitoring and progression of symptoms.

## Discussion

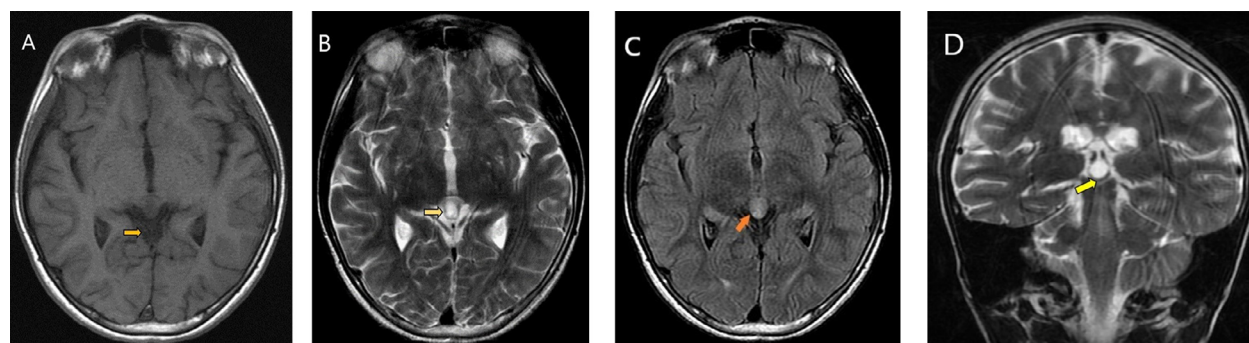
PCs are common findings seen by MRI in the general population and autopsy studies. Although this has not been proven,

they most commonly occur in young females, suggesting a potential hormonal role in developing these lesions [2]. Nevertheless, the origin of PCs is still not clear.

PCs are typically asymptomatic, but, when symptoms do occur they are nonspecific and difficult to attribute clinically to a PC. To explain this variable presentation, PCs usually remain stable and do not enlarge over time, but some may grow and cause symptoms: symptomatic cysts vary from 7 to 45 mm, whereas asymptomatic cysts are typical 10 mm [3]. Larger PCs come to clinical attention by compressing adjacent structures, such as the cerebral aqueduct and tectal midbrain. To correlate these neuroanatomical relationships clinically, Wisoff and Epstein [4] categorized the presentation of pineal cysts into (1) paroxysmal headache with gaze paresis; (2) chronic headache, gaze paresis, papilledema, and hydrocephalus; and (3) PC apoplexy with acute hydrocephalus.

Of these presentations, the most common symptom is headache, whereas PC apoplexy is the rarest and most severe [5]. In the pediatric age group, pineal apoplexy is exceedingly rare, and the youngest case described in the literature is that of an 8-year-old female [6], followed by a 10-year-old girl [7]. There have been reported 34 cases of pineal gland apoplexy worldwide, and 10 of them were less than 18 years of age. Our case is the youngest case of PC apoplexy in a male, the first pediatric case of pineal apoplexy in Saudi Arabia, the first one secondary to severe cranial trauma, and the first to present with persistent anterograde amnesia or memory loss, to the best of our knowledge.

The etiology of PC apoplexy is still unclear, and many potential precipitating factors have been implicated in other case reports: therapeutic anticoagulation [8,9], vascular malformation [10], hypertension [11], and degenerative changes in the PC [12,13]. In our case, the pineal apoplexy was likely secondary to trauma, but this was missed initially on imaging. Hence, we propose that pineal apoplexy is an important finding to assess in the setting of severe head trauma. Furthermore, after 2 months, our patient started suffering from memory loss, after which a CT scan and MRI were performed to reveal a PC. Therefore, we initially believed that apoplexy was likely the cause of PC in our case, consistent with McNeely et al., who reported cystic changes in the pineal gland 7



**Fig. 4 – (A). Axial T1 image showing low intensity cyst in the pineal region (arrow). (B) Axial T2-weighted image showing a pineal cyst with hyperintense signal intensity (arrow). (C) Axial FLAIR sequence indicating a slightly hyperintense cyst in the pineal gland (arrow). (D) Coronal T2-weighted image revealing a signal cyst in the pineal gland (arrow).**

weeks after the initial presentation of apoplexy [14]. However, the possibility that apoplexy caused a small pre-existing PC to become detectable and symptomatic cannot be excluded. On later evaluation of our patient's initial CT scan, a small fluid-filled density was noted in the pineal gland with mural calcifications, suggesting that the apoplectic event enlarged a small, pre-existing PC in the present case.

Pineal apoplexy can present with many abnormalities, including sudden onset of severe headaches or acute exacerbation of a persistent headache, gaze paresis and visual disturbances, cognitive impairment, ataxia, hearing loss, hemiparesis, sexual dysfunction, insomnia, seizures, syncope, and neurologic deterioration [15]. These symptoms may develop suddenly, necessitating hospital admission, but may also extend months to years before presentation. In addition, Richardson and Hirsch reported sudden death in a patient, with pineal apoplexy being confirmed as the cause at autopsy [10]. Therefore, pineal apoplexy is an essential condition that warrants prompt recognition and management to prevent potentially severe complications.

To our knowledge, persistent memory loss for two months as a presentation of PC apoplexy is a first in the literature. To explain this presentation, we looked into the role of the pineal gland in the pathophysiology of Alzheimer's disease (AD), of which memory loss is a well-established consequence [16]. In animal models, the pineal gland secretes melatonin, which has been shown to prevent amyloid  $\beta$  ( $A\beta$ )-induced neurotoxicity, including memory loss [17]. In agreement with this, melatonin levels are decreased in AD, which has been implicated in memory loss. Lastly, exogenous melatonin is potentially a crucial pharmacologic intervention to mitigate the pathology of AD, particularly in its early stage [18]. Therefore, the loss of melatonin secretion secondary to pineal apoplexy may explain the memory loss in our patient. Contrarily, however, memory loss is not a commonly reported presentation in PCs. This can be explained by a recent study demonstrating preserved melatonin secretion in a cohort of 4 patients with PC [19]; however, given the small sample size of this study, these results should be validated by larger independent cohort studies. Another observation contrary to our hypothesis is the lack of other melatonin deficiency-related symptoms such as insomnia, which has been reported in another case and postulated to be secondary to melatonin deficiency, although in both instances melatonin levels could not be measured [20]. This is a significant limitation to our hypothesis.

Imaging evaluation is essential in PCs and apoplexy due to the nonspecific clinical presentation. MRI is the imaging modality of choice in confirming the cystic nature of PCs and differentiating them from cystic neoplasms in the pineal gland region. Uncomplicated PCs exhibit iso- to hypointense signals on T1 and hyperintense signals relative to brain parenchyma on T2-weighted images depending on the proteinaceous content of the cyst [21]. On postcontrast MRI, PCs display even enhancement of the cyst wall. The imaging hallmark of apoplectic PCs is a cystic lesion with hemorrhage products without an associated soft-tissue mass [22]. Notably, radiologists must differentiate apoplectic PCs from cystic pineal tumors. The imaging features of PCs are typically enough to set them apart from pineal neoplasms. In contrast, postcontrast MR imaging helps distinguish PCs from other le-

sions causing pineal hemorrhage, including tumors. A smooth cyst wall  $<2$  mm indicates PCs, whereas an irregular contour of the cyst wall with nodular enhancement suggests other lesions, of which there is a broad differential [23,24].

The definitive diagnosis of PCs requires histopathological evaluation. PCs histologically comprise an inner glial layer, which may be favorable for GFAP and S100 and form Rosenthal fibers, a middle layer of pineal parenchyma with or without calcification, and an outer fibrous capsule. When apoplectic, evidence of bleeding is present histologically in the form of hemosiderin deposition in the inner glial layer [15]. Significantly, PCs can be mistaken for pineocytomas if the surrounding pancreatic parenchyma is also sampled. Therefore, this may lead to unnecessary exposure to chemoradiation and is an essential point for practitioners to be aware of. Thus, because pineal neoplasms are included in the differential of apoplectic PCs, a laboratory workup of blood and CSF tumor markers can help supplement neuroimaging and histopathological findings to narrow down the differential diagnosis of apoplectic pineal pathologies.

Patients with symptomatic PCs, especially those suffering symptoms from obstructive hydrocephalus or brainstem compression, or apoplectic PCs, require surgical intervention. Stereotactic or endoscopic aspiration, ventriculoperitoneal shunting, or cyst resection have been utilized to relieve symptoms in patients [15]. Shunting can relieve obstructive hydrocephalus but carries inherent risks of infection or persistence of symptoms; instances have been reported of PC apoplexy that was initially treated via shunting but later required resection or aspiration [25,26]. Stereotactic aspiration has shown to be a successful approach for PC apoplexy with no symptom recurrence for up to 40 months of follow-up [27]; however, it is risky or even contraindicated in patients with bleeding disorders and does not usually allow for a biopsy specimen, hindering the confirmatory diagnosis of PCs [28]. One case used third ventriculostomy to relieve the hydrocephalus, but symptoms recur due to cyst enlargement, necessitating surgical resection [14]. On the other hand, cystectomy eliminates the risk of recurrence associated with shunting and is free of the inherent risks of aspiration and shunting [6,15]. However, the best approach for symptomatic or hemorrhagic PCs remains undetermined. The follow-up time in published data is relatively short; studies usually repeat neurologic exams and imaging within the first year after treatment. Future comparative analyses would further our understanding in this regard.

While symptomatic or apoplectic PCs typically require intervention, neurologically intact and symptom-free patients can be managed conservatively. Asymptomatic PCs are managed conservatively with repeat follow-up and neuroimaging, but a recent study demonstrated no advantage to follow-up imaging [29]. In contrast, conservatively managing PC apoplexies lacks sufficient evidence because the rarity of PC apoplexies has limited opportunities to develop a robust management guideline. To some success, only five case reports have managed pineal apoplexy conservatively [6,20,22,30,31]. One case even reported apoplexy resolved spontaneously, supporting the conservative management of PC apoplexies [20]. However, notably, the 2 youngest PC apoplexy patients treated expectantly later required surgical resection due to a

symptom recurrence from a second hemorrhagic event [6,7]. A recent study also demonstrated that patients with enlarging PCs were significantly younger than patients whose PC shrunk over time [32]. The clinician should remain aware of this fact during follow-up.

## Conclusion

Pineal apoplexy is a rare, but severe complication of a PC and requires prompt recognition and intervention. The present case had three unique features: it is likely the youngest case reported of a pineal apoplexy in males, it was secondary to severe craniofacial trauma, and it resulted in memory loss, which has rarely been reported. On this basis, we propose that pineal apoplexy be evaluated during neuroimaging studies in the setting of severe craniofacial trauma. Furthermore, future studies should further elucidate the management protocol for PC apoplexy that yields the best patient outcome; in very young patients, surgical intervention may be indicated as the minimal literature shows that these patients are likely to suffer a symptom recurrence due to a second hemorrhagic event or an enlarging cyst.

## Patient consent

Patient anonymity is maintained throughout the manuscript. Informed Consent was obtained from the patient and his parents for use of data.

## REFERENCES

- [1] Al-Holou WN, Terman SW, Kilburg C, Garton HJ, Muraszko KM, Chandler WF, et al. Prevalence and natural history of pineal cysts in adults. *J Neurosurg* 2011;115(6):1106–14.
- [2] Sawamura Y, Ikeda J, Ozawa M, Minoshima Y, Saito H, Abe H. Magnetic resonance images reveal a high incidence of asymptomatic pineal cysts in young women. *Neurosurgery* 1995;37(1):11–15 discussion 5–6.
- [3] Bosnjak J, Budisić M, Azman D, Strineka M, Crnjaković M, Demarin V. Pineal gland cysts—an overview. *Acta Clin Croat* 2009;48(3):355–8.
- [4] Wisoff JH, Epstein F. Surgical management of symptomatic pineal cysts. *J Neurosurg* 1992;77(6):896–900.
- [5] Kim E, SM Kwon. Pineal cyst apoplexy: a rare complication of common entity. *Brain Tumor Res Treat* 2020;8(1):66–70.
- [6] Goehner D, Soyland D, Vuong S, Trumble E. Pineal cyst apoplexy in an 8-year-old girl: case report and literature review. *World Neurosurg* 2020;142:159–66.
- [7] Majeed K, SA Enam. Recurrent pineal apoplexy in a child. *Neurology* 2007;69(1):112–14.
- [8] Apuzzo ML, Davey LM, Manuelidis EE. Pineal apoplexy associated with anticoagulant therapy. Case report. *J Neurosurg* 1976;45(2):223–6.
- [9] Avery GJ, Lind CR, AP Bok. Successful conservative operative management of pineal apoplexy. *J Clin Neurosci* 2004;11(6):667–9.
- [10] Richardson JK, Hirsch CS. Sudden, unexpected death due to "pineal apoplexy". *Am J Forensic Med Pathol* 1986;7(1):64–8.
- [11] Werder GM, Razdan RS, Gagliardi JA, Chaddha SKB. Conservatively managed pineal apoplexy in an anticoagulated patient. *Radiography* 2008;14(1):69–72.
- [12] Taraszewska A, Matyja E, Koszewski W, Zaczyński A, Bardadin K, Czernicki Z. Asymptomatic and symptomatic glial cysts of the pineal gland. *Folia Neuropathol* 2008;46(3):186–95.
- [13] Mena H, Armonda RA, Ribas JL, Ondra SL, Rushing EJ. Nonneoplastic pineal cysts: a clinicopathologic study of twenty-one cases. *Ann Diagn Pathol* 1997;1(1):11–18.
- [14] McNeely PD, Howes WJ, Mehta V. Pineal apoplexy: is it a facilitator for the development of pineal cysts? *Can J Neurol Sci* 2003;30(1):67–71.
- [15] Patel AJ, Fuller GN, Wildrick DM, Sawaya R. Pineal cyst apoplexy: case report and review of the literature. *Neurosurgery* 2005;57(5):E1066 discussion E.
- [16] Srinivasan V, Kaur C, Pandi-Perumal S, Brown GM, Cardinali DP. Melatonin and its agonist ramelteon in Alzheimer's disease: possible therapeutic value. *Int J Alzheimers Dis* 2010;2011:741974.
- [17] Rudnitskaya EA, Muraleva NA, Maksimova KY, Kiseleva E, Kolosova NG, Stefanova NA. Melatonin attenuates memory impairment, amyloid- $\beta$  accumulation, and neurodegeneration in a rat model of sporadic Alzheimer's disease. *J Alzheimers Dis* 2015;47(1):103–16.
- [18] Rudnitskaya EA, Maksimova KY, Muraleva NA, Logvinov SV, Yanshole LV, Kolosova NG, et al. Beneficial effects of melatonin in a rat model of sporadic Alzheimer's disease. *Biogerontology* 2015;16(3):303–16.
- [19] Májovský M, Řezáčová L, Sumová A, Pospíšilová L, Netuka D, Bradáč O, et al. Melatonin and cortisol secretion profile in patients with pineal cyst before and after pineal cyst resection. *J Clin Neurosci* 2017;39:155–63.
- [20] Ayhan S, Bal E, Palaoglu S, Cila A. Pineal cyst apoplexy: report of an unusual case managed conservatively. *Neurol Neurochir Polska* 2011;45(6):604–7.
- [21] Lee DH, Norman D, Newton TH. MR imaging of pineal cysts. *J Comput Assist Tomogr* 1987;11(4):586–90.
- [22] Koenigsberg RA, Faro S, Marino R, Turz A, Goldman W. Imaging of pineal apoplexy. *Clin Imaging* 1996;20(2):91–4.
- [23] Fakhra S, Escott EJ. Pineocytoma mimicking a pineal cyst on imaging: true diagnostic dilemma or a case of incomplete imaging? *AJNR Am J Neuroradiol* 2008;29(1):159–63.
- [24] Osborn AG, Preece MT. Intracranial cysts: radiologic-pathologic correlation and imaging approach. *Radiology* 2006;239(3):650–64.
- [25] Mukherjee KK, Banerji D, Sharma R. Pineal cyst presenting with intracystic and subarachnoid haemorrhage: report of a case and review of the literature. *Br J Neurosurg* 1999;13(2):189–92.
- [26] Osborn RE, Deen HG, Kerber CW, Glass RF. A case of hemorrhagic pineal cyst: MR/CT correlation. *Neuroradiology* 1989;31(2):187–9.
- [27] Musolino A, Cambria S, Rizzo G, Cambria M. Symptomatic cysts of the pineal gland: stereotactic diagnosis and treatment of two cases and review of the literature. *Neurosurgery* 1993;32(2):315–20 discussion 20–1.
- [28] Steven DA, McGinn GJ, McClarty BM. A choroid plexus papilloma arising from an incidental pineal cyst. *AJNR Am J Neuroradiol* 1996;17(5):939–42.

- [29] Tanaka T, Arnold L, Gabriela Mazuru D, Golzy M, Carr SB, Litofsky NS. Pineal cysts: does anyone need long-term follow up? *J Clin Neurosci* 2021;83:146–51.
- [30] Yamamoto K, Omodaka T, Watanabe R, Kodaira M. A hemorrhagic pineal cyst with a bacterial meningitis-like manifestation and benign outcome. *Intern Med* 2013;52(24):2817–20.
- [31] Michielsen G, Benoit Y, Baert E, Meire F, Caemaert J. Symptomatic pineal cysts: clinical manifestations and management. *Acta Neurochir (Wien)* 2002;144(3):233–42 discussion 42.
- [32] Majovsky M, Benes V. Natural course of pineal cysts—a radiographic study. *Chin Neurosurg J* 2018;4(1):33.