

Case report

Multimodal imaging of membranoproliferative glomerulonephritis type II



Zafer Cebeci*; Serife Bayraktar; Merih Oray; Nur Kir

Abstract

To report the fundus findings on multimodal imaging of a membranoproliferative glomerulonephritis type II (MPGNII) patient. A 41-year-old woman had a medical history of renal transplantation for MPGNII 5 years prior to presentation to our clinic for ophthalmic examination. Fundus examination showed macular retinal pigment epithelial changes and large peripapillary atrophy in the right eye, and yellowish bilateral drusen-like deposits peripherally. Fundus fluorescein angiography and indocyanine green angiography revealed multifocal hyperfluorescence in the peripheral retina with accompanying deposits. A hyperautofluorescence pattern was seen in the fundus autofluorescence (FAF) images of the deposits. Spectral domain optical coherence tomography (SD-OCT) scans of the drusen-like material showed retinal pigment epithelium (RPE) elevations with moderate hyperreflectivity underneath. Multiple imaging modalities of the posterior segment can provide detailed information about the ocular involvement of MPGNII and help us to confirm the diagnosis and to follow the lesions.

Keywords: Membranoproliferative glomerulonephritis type II, Autofluorescence, Optical coherence tomography

© 2016 The Authors. Production and hosting by Elsevier B.V. on behalf of Saudi Ophthalmological Society, King Saud University. This is an open access article under the CC BY-NC-ND license (<http://creativecommons.org/licenses/by-nc-nd/4.0/>). <http://dx.doi.org/10.1016/j.sjopt.2016.11.005>

Introduction

Membranoproliferative glomerulonephritis type II (MPGNII), also known as dense deposit disease, is an inflammation of the glomerulus and one of the major causes of nephrotic syndrome. The main mechanism of the disease is regulation failure of the complement cascade alternative pathway.¹ Electron-dense transformation of the glomerular basement membrane (GBM) is the characteristic histopathological feature of MPGNII.² Constitution of dense deposits seen in the renal capillary tuft/GBM/glomerular epithelial interface is analogous to deposits detected in the choroid/Bruch's membrane/retinal pigment epithelium (RPE) interface.³

Visual prognosis usually depends on complications secondary to deposit formation. Visual impairment may result

from the choroidal neovascular membrane, central serous chorioretinopathy, or macular detachment.^{4,5}

Herein, we present the findings of multimodal imaging of the fundus in a patient with MPGNII who had undergone renal transplantation.

Case report

A 41-year-old female patient was admitted to our clinic for routine ophthalmological examination. She had a complaint of vision decrease in her right eye since 10 years. She never had any treatment for her ocular complaints. Past medical history included diagnosis of MPGNII at the age of 15 years. Based on her past medical records, she had undergone renal transplantation for end-stage renal disease 5 years ago and had no evidence of MPGNII recurrence on the transplant

Received 3 April 2015; received in revised form 20 February 2016; accepted 2 November 2016; available online 10 November 2016.

Istanbul University, Istanbul Faculty of Medicine, Department of Ophthalmology, Capa 34390, Istanbul, Turkey

* Corresponding author. Fax: +90 212 414 20 26.
e-mail address: zafceb@gmail.com (Z. Cebeci).



Peer review under responsibility of Saudi Ophthalmological Society, King Saud University



Production and hosting by Elsevier

Access this article online:
www.saudiophthaljournal.com
www.sciencedirect.com

tissue, according to the nephrology consultation. On ophthalmic examination, her visual acuity was 20/200 in the right eye and 20/20 in the left eye. Anterior segments were normal bilaterally. Fundus examination showed retinal pigment epithelial changes on the macula, peripapillary atrophic areas

extending superiorly and inferiorly in the right eye, and yellow-white, elevated, basal laminar drusen-like lesions peripherally in both eyes (Fig. 1a and b). Fundus fluorescein angiography (FFA) showed hyperfluorescence in the macula and peripapillary region in the right eye, superotemporally

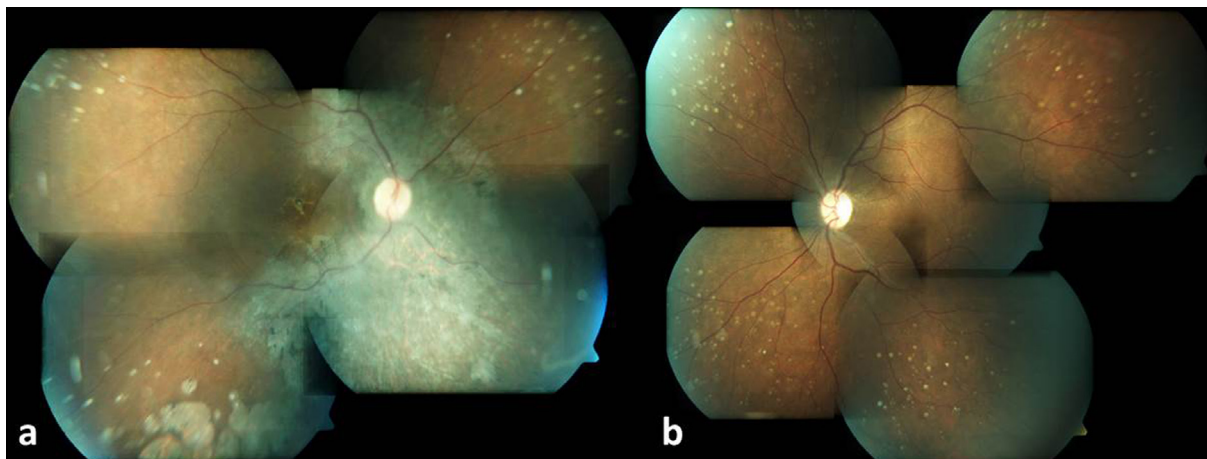


Figure 1. Fundus photograph of the right eye shows retinal pigment epithelial changes on macula and drusen like deposits in the peripheral retina (a). Fundus photograph of the left eye demonstrates drusen like deposits in the periphery (b).

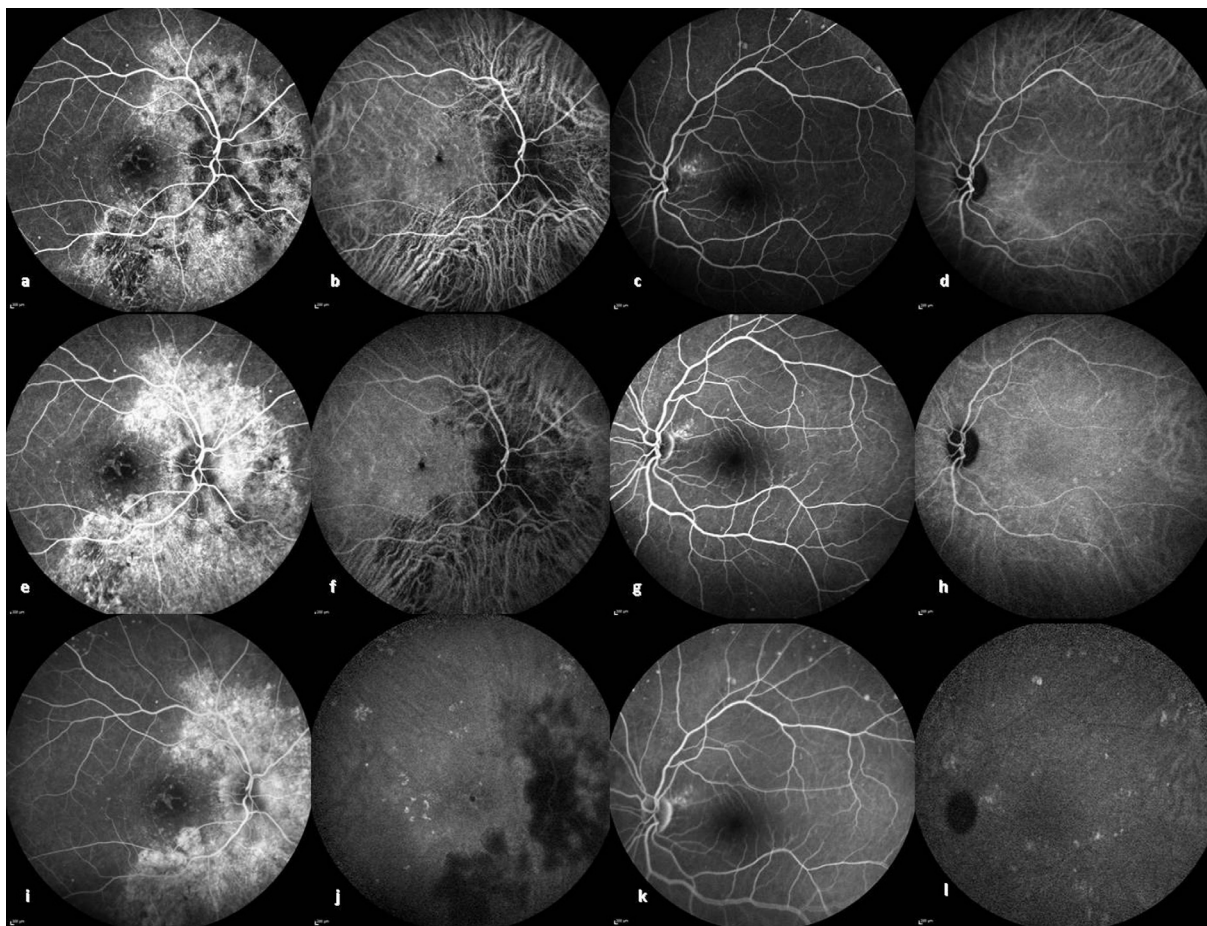


Figure 2. Fluorescein angiography (FA) of the right eye illustrates large peripapillary hyperfluorescence due to window defect in early (a), mid (e), and late (i) phases. FA of the left eye shows window defect superotemporally to the optic disc and hyperfluorescence spots in the periphery in early (c), mid (g), and late (k) phases. Indocyanine green angiography (ICG-A) demonstrates marked peripapillary hypofluorescence and scattered hyperfluorescent spots from early to late phases in the right eye (b, f, j) and hyperfluorescent spots becoming more marked in the late phases of ICG-A in the left eye (d, h, l).

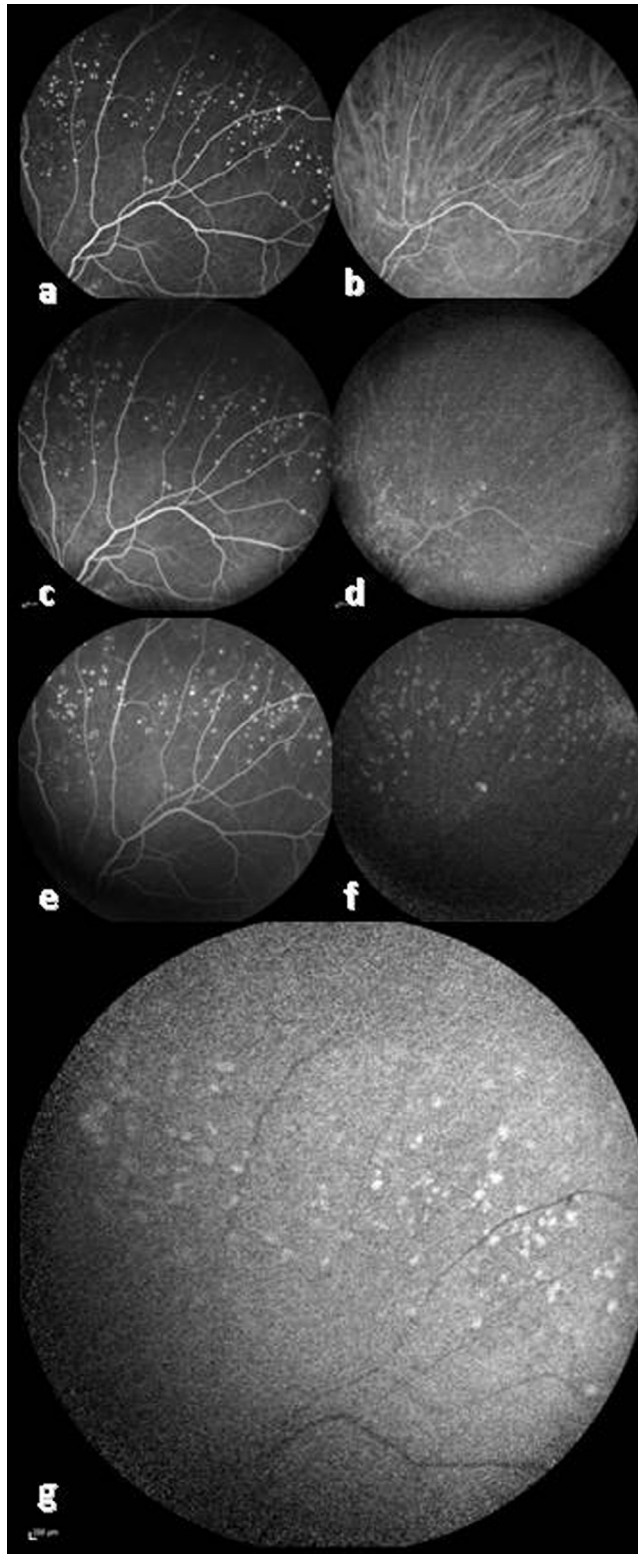


Figure 3. Hyperfluorescence spots due to drusen like deposits in the superior periphery in early to late phases of FA in the left eye (a, c, e). ICG-A demonstrates prominent hyperfluorescent spots in late phases, consistent with the deposits in the same area (b, d, f). Fundus autofluorescence shows hyperautofluorescence in the deposit areas (g).

of the optic disc in the left eye due to a window defect and multiple small, round, well-defined hyperfluorescent spots throughout the peripheral fundus due to staining of drusen-

like lesions in both eyes and indocyanine green angiography (ICG-A) revealed small hyperfluorescent areas corresponding to the drusen-like lesions bilaterally (Figs. 2a–l, 3a–f). Fundus autofluorescence (FAF) showed multiple hyperautofluorescent spots in the areas of peripheral deposit lesions in both eyes (Fig. 3g). Spectral-domain optical coherence tomography (SD-OCT) images of the macula revealed loss of the inner segment/outer segment (IS/OS) of photoreceptors in the right eye (Fig. 4a), and were normal in the left eye. OCT scans from the deposits showed focal RPE elevations and bumps, with moderate reflectivity below these elevations (Fig. 4b). Based on clinical examination and imaging, fundus lesions were diagnosed as retinal findings of MPGNII and the patient will continue to follow up in our retina department.

Discussion

Membranoproliferative glomerulonephritis type II is a rare and progressive renal disease that can cause end-stage renal disease. The disease usually presents in the early adulthood and patients often develop drusen-like deposits in the second decade of life, but also visual loss can occur at older ages.⁶ Histopathologically, abnormal dense deposits in the Bruch's membrane and choriocapillaris in an MPGNII patient were first reported by Duvall-Young et al. in 1989.⁷ D'Souza et al. showed that drusen-like deposits in MPGNII share common compositions with the drusen in age-related macular degeneration (AMD) and suggested that deposits are the end result of both diseases.³ The alternative complement pathway system components play a critical role in the pathogenesis of MPGNII, and the same factors take part in drusen formation in AMD.⁸

Fundus fluorescein angiography and ICG-A have been shown to demonstrate abnormal hyperfluorescent dots, which are possible links to the vascular pathology in the choriocapillaris.⁹

Optical coherence tomography scans of the deposits show similar structural features with soft drusen detected in AMD.^{10,11} Scans of the drusen-like lesions show alterations in RPE with elevations accompanying moderate-to-highly reflective material beneath the elevations. In some cases, a hyporeflective image can be seen under the RPE elevations.¹¹

Drusen, especially soft types, shows increased signals on FAF images because of excessive lipofuscin accumulation. Einbock et al. stated that focal or plaque-like FAF changes in the macula carry a high risk for the progression of geographic atrophy.¹² Our case had large peripapillary atrophic areas extending to the superior and inferior fundus. The possible mechanism may be intense drusen-like deposits around the optic disc causing atrophic changes over time, as seen in AMD.

Visual loss develops due to secondary changes in patients with prolonged fundus findings. Choroidal neovascularization (CNV), central serous chorioretinopathy, and atrophic macula are the main complications that can occur in the course of the disease.^{4,5}

Lesions in the fundus can be seen long after renal transplantation with stable renal status.¹³ Also, it has been shown that renal transplantation did not affect the development of CNV in 4 patients with long-term follow-up.¹³ However, Abazi et al. reported that renal transplantation can provoke the development of retinopathy, including hemorrhages

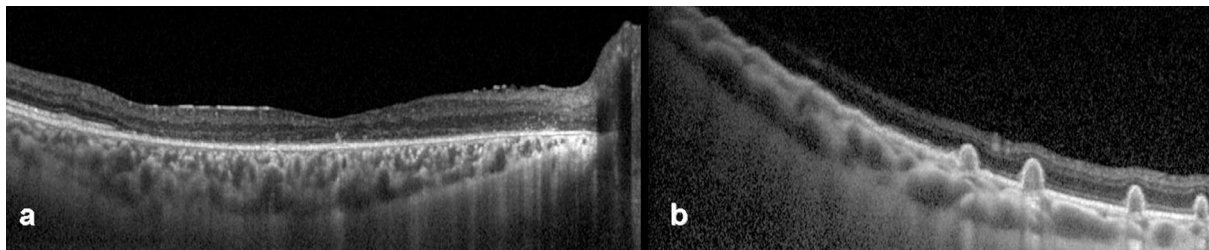


Figure 4. OCT of the right macula demonstrates loss of IS/OS line (a). Scans from the deposits show pigment epithelial irregularity and elevations with underlying moderate hyperreflective material (b).

and serous retinal detachment.¹⁴ We did not detect subretinal fluid or choroidal neovascularization in our patient with any of the imaging modalities. In our case, macular and large peripapillary RPE changes and atrophic areas in the right eye might be sequelae of presumed previous serous retinal detachment. However, our patient experienced visual loss in her right eye for 5 years prior to the transplantation and reported no worsening or new complaints after the transplantation.

Histopathological and imaging studies have shown that lesions in AMD and MPGNII share many features in common. However, further investigations with larger groups of patients must be done to differentiate the characteristics between the drusen in AMD and the deposits in MPGNII.

In conclusion, fundus findings may persist for a long time period following renal transplantation. Multimodal imaging may be helpful for the clinicians to diagnose and also to follow the posterior segment changes in patients with MPGNII. In addition, clinicians must be aware of the development of complications secondary to lesions, and periodic ophthalmic examinations must be performed in MPGNII patients.

Conflict of interest

The authors declared that there is no conflict of interest.

References

1. Appel GB, Cook HT, Hageman G, et al. Membranoproliferative glomerulonephritis type II (dense deposit disease): an update. *J Am Soc Nephrol* 2005;**16**:1392–403.
2. Walker PD, Ferrario F, Joh K, Bonsib SM. Dense deposit disease is not a membranoproliferative glomerulonephritis. *Mod Pathol* 2007;**20**:605–15.
3. D'souza YB, Jones CJ, Short CD, Roberts IS, Bonshek RE. Oligosaccharide composition is similar in drusen and dense deposits in membranoproliferative glomerulonephritis type II. *Kidney Int* 2009;**75**:824–7.
4. McAvoy CE, Silvestri G. Retinal changes associated with type 2 glomerulonephritis. *Eye* 2005;**19**:985–9.
5. Ulbig MR, Riordan-Eva P, Holz FG, Rees HC, Hamilton HA. Membranoproliferative glomerulonephritis type II associated with central serous retinopathy. *Am J Ophthalmol* 1993;**116**:410–3.
6. Colville D, Guymer R, Sinclair RA, Savage J. Visual impairment caused by retinal abnormalities in mesangiocapillary (membranoproliferative) glomerulonephritis type II ("dense deposit disease"). *Am J Kidney Dis* 2003;**42**:E2–5.
7. Duvall-Young J, MacDonald MK, McKechnie NM. Fundus changes in (type II) mesangiocapillary glomerulonephritis simulating drusen: a histopathological report. *Br J Ophthalmol* 1989;**73**:297–302.
8. Mullins RF, Aptsiauri N, Hageman GS. Structure and composition of drusen associated with glomerulonephritis: implications for the role of complement activation in drusen biogenesis. *Eye* 2001;**15**:390–5.
9. Parrat A, Arndt CF, Labalette P, et al. Retinochoroidal involvement of type II membranoproliferative glomerulonephritis. An angiographic study with indocyanine green. *J Fr Ophthalmol* 1997;**20**:430–8.
10. Batioglu F, Müftüoğlu O, Atmaca L. Optical coherence tomography of fundus abnormalities associated with type II membranoproliferative glomerulonephritis. *Retina* 2003;**23**:261–2.
11. Ritter M, Bolz M, Haidinger M, et al. Functional and morphological macular abnormalities in membranoproliferative glomerulonephritis type II. *Br J Ophthalmol* 2010;**94**:1112–4.
12. Einbock W, Moessner A, Schnurrbusch UE, Holz FG, Wolf S. FAM Study Group. Changes in fundus autofluorescence in patients with age-related maculopathy. Correlation to visual function: a prospective study. *Graefes Arch Clin Exp Ophthalmol* 2005;**243**:300–5.
13. D'souza Y, Short CD, McLeod D, Bonshek RE. Long-term follow-up of drusen-like lesions in patients with type II mesangiocapillary glomerulonephritis. *Br J Ophthalmol* 2008;**92**:950–3.
14. Abazi Z, Magarasevic L, Sukalo S, Kosanovic-Jakovic N, Risovic D. Ocular complications after kidney transplantation: a case report and review of literature. *Int Urol Nephrol* 2014;**46**:665–8.