

Available online at www.sciencedirect.com

ScienceDirect

journal homepage: www.elsevier.com/locate/radcr

Case Report

Spontaneous ruptured pyomyoma: A rare yet critical postpartum complication: A case report[☆]

Tze Hui Soo^{a,*}, Mogana Subramaniam^b, Woon Kian Chai^c, Wei Sheun Ee^d^a Radiology Department, Faculty of Medicine and Health Sciences University Putra Malaysia, Serdang 43400, Malaysia^b Radiology Department, Hospital Kajang, Jalan Semenyih, Bandar Kajang, Kajang, Selangor 43000, Malaysia^c Family Medicine Department of University of Malaya, Kuala Lumpur 50603, Malaysia^d Medical Department, Klinik Kesihatan Bandar Baru Air Itam, Pulau Pinang, Ayer Itam 11500, Malaysia

ARTICLE INFO

Article history:

Received 23 May 2024

Revised 9 July 2024

Accepted 11 July 2024

Keywords:

Infected leiomyoma

Pyomyoma

Ruptured pyomyoma

Acute puerperal endometritis

ABSTRACT

Pyomyoma, a rare complication of leiomyoma, presents a unique clinical challenge due to its infrequency with potentially fatal complications. Herein, we report the case of a 44-year-old Para 3+1 woman with red degeneration of uterine fibroids during pregnancy, who experienced worsening abdominal pain and foul smelling vaginal discharge 1 week post Caesarean section. Despite hemodynamic stability, her septic markers were markedly raised. A bedside ultrasound noted a pelvic complex cystic collection, further confirmed on CT scan as spontaneous ruptured of pyomyoma complicated by complex fistulas with surrounding organs. She underwent total abdominal hysterectomy and abdominal washout the next day, with intravenous antibiotic on-board. Histology examination confirmed acute suppurative inflammation of the uterine fibroid with endometritis. This case report contributes to the existing medical literature by shedding light on a rare and potentially life-threatening leiomyoma complication. Its potential to mimic acute puerperal endometritis, makes its diagnosis especially challenging, necessitating a high index of suspicion.

© 2024 The Authors. Published by Elsevier Inc. on behalf of University of Washington.

This is an open access article under the CC BY-NC-ND license (<http://creativecommons.org/licenses/by-nc-nd/4.0/>)

Introduction

Uterine leiomyomas or fibroids are the most common benign smooth muscle uterine neoplasms among reproductive age groups women. They are often asymptomatic and discovered incidentally. When they substantially increase in size,

they may be associated with a palpable mass, dysmenorrhea, menorrhagia, and infertility. Dreadful complications include malignant transformation into leiomyosarcoma and torsion. Among these rare complications, pyomyoma stands out as a remarkable yet infrequently reported phenomenon [1]. It was first described in 1945, pyomyoma involves the infrequent occurrence of pyogenic infection within a leiomyoma, leading to

[☆] Competing Interests: The authors declare that they have no known competing financial interests or personal relationships that could have appeared to influence the work reported in this paper.

* Corresponding author.

E-mail address: suzyhui88@upm.edu.my (T.H. Soo).

<https://doi.org/10.1016/j.radcr.2024.07.044>

1930-0433/© 2024 The Authors. Published by Elsevier Inc. on behalf of University of Washington. This is an open access article under the CC BY-NC-ND license (<http://creativecommons.org/licenses/by-nc-nd/4.0/>)

the formation of a pus-filled cavity within the uterine mass [2]. Its pathogenesis remains a subject of debate, with proposed mechanisms involving vascular compromise leading to infarction and subsequent infection. Possible routes of infection include direct spread from the endometrial cavity during Caesarean sections or other gynecological interventions, adjacent bowel or adnexa and haematogenous or lymphatic spread from infection elsewhere in the body [2,3]. In some cases, pyomyoma can progress insidiously, leading to fulminant sepsis and a fatal course, underscoring the potential severity of this condition [4]. Although pyomyoma is exceptionally rare, it can result in uterine rupture, intra-abdominal abscesses, and even toxic shock syndrome, emphasizing the importance of prompt recognition and management [1,5,6]. This case report highlights the nonspecific clinical presentation, diagnostic challenges, and therapeutic approaches employed in a case of spontaneous rupture of pyomyoma following a Caesarean section. This report seeks to contribute to the limited body of literature on its rare complication and provide insights for improving patient outcomes alongside to raise the awareness of this disease.

Case report

A 44-years-old Para 3+1 woman with underlying gestational diabetes mellitus and uterine fibroids had multiple visit to the emergency department (ED) throughout her gestation due to unbearable right-sided abdominal pain. A bedside ultrasound (USG) during her second trimester noted multiple rapidly enlarging uterine fibroids with signs of degeneration. An elective Caesarean Section was planned at term due to a macrosomic baby. The operation was uneventful, and she was discharged in good condition. However, 1 week after discharge, she returned to the ED complaining of worsening abdominal pain and foul smelling vaginal discharge, without any concomitant fever. She was hemodynamically stable, but her septic parameters were raised, with a leucocyte count of $18.3 \times 10^9/L$ and C-reactive protein at 163.5 mg/L. The rest of her blood parameters and renal function were within normal limit. On speculum examination, a copious amount of foul smelling pus was observed oozing from the cervix. A bedside USG conducted by the obstetrics and gynecology team noted a complex cystic collection with intralesional moving echogenic debris in the pelvis.

Thereafter, an urgent contrasted computed tomogram (CT) of the abdomen was requested to rule out an intra-abdominal abscess that require emergent surgical intervention. The CT scan revealed 2 large wall-enhancing complex cystic collections with intralesional air locules occupying the mid-abdomen and pelvis regions (Fig. 1), measures $8.7 \times 11.0 \times 9.8$ cm and $7.9 \times 9.0 \times 9.2$ cm (AP \times W \times CC) respectively. Mild hydrometra and air locules were noted within the endometrium (Fig. 2). A small communication track was seen between the largest mid-abdominal collection with the endometrial cavity (Fig. 3), while the smaller pelvic collection (Fig. 4) showed a suspicious tiny communication track with the collections located within the rectus abdominis muscles anteriorly. Additionally, extensive mesenteric fat streakiness was noted, along

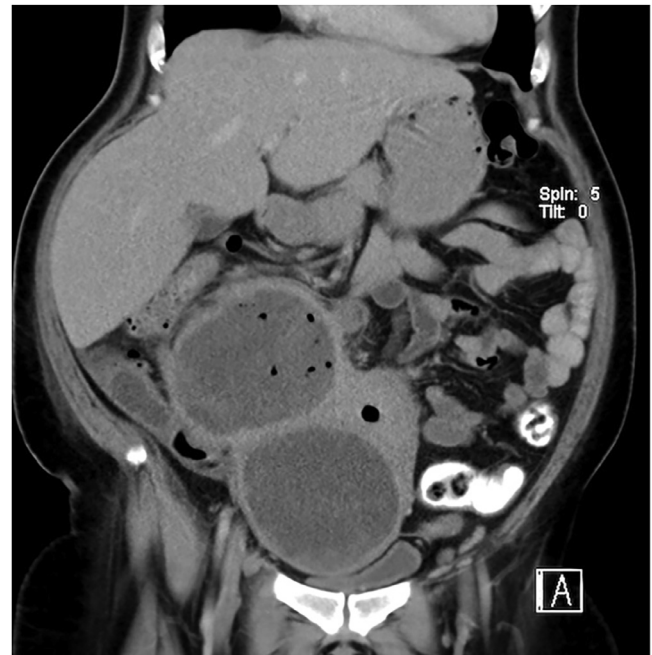


Fig. 1 – Coronal reformatted contrasted CT Abdomen showed 2 large well-defined wall enhancing complex cystic collections with intralesional air locules occupying the mid-abdomen and pelvis measures $8.7 \times 11.0 \times 9.8$ cm and $7.9 \times 9.0 \times 9.2$ cm (AP \times W \times CC) respectively.

with multiple enlarged pelvic, bilateral inguinal, para-aortic and aortocaval lymph nodes. The diagnosis of a ruptured pyomyoma complicated by complex fistulas with surrounding organs was made, correlating with a history of underlying uterine fibroids. Subsequently, the patient underwent a total abdominal hysterectomy and abdominal washout the following day, with intravenous broad spectrum antibiotic administered in order to halt full blown septicaemia.

Intraoperatively, copious amounts of malodorous pus drained before entering the rectus sheath from the incision site. The uterus was found rotated 180 degrees, and the anterior part of the uterus and bowel loops adhered densely to the anterior abdominal wall. A large fundal subserosa fibroid filled with necrotic material and pus centrally was seen. A cut section of the uterus revealed a sudden gush of copious greenish, thickened, and foul-smelling purulent discharge. Histology examination confirmed the presence of a subserosa uterine fibroid with acute suppurative inflammation and endometritis. However, tissue culture did not yield any organism except for few pus cells. The patient was discharged well after 1 week course of intravenous antibiotics postoperatively.

Discussion

Leiomyomas are the commonest benign smooth muscle uterine neoplasms, consisting of variable degree of fibrous connective tissue. They typically occur within the myometrium but can also be found in the cervix, broad ligament or ovaries.

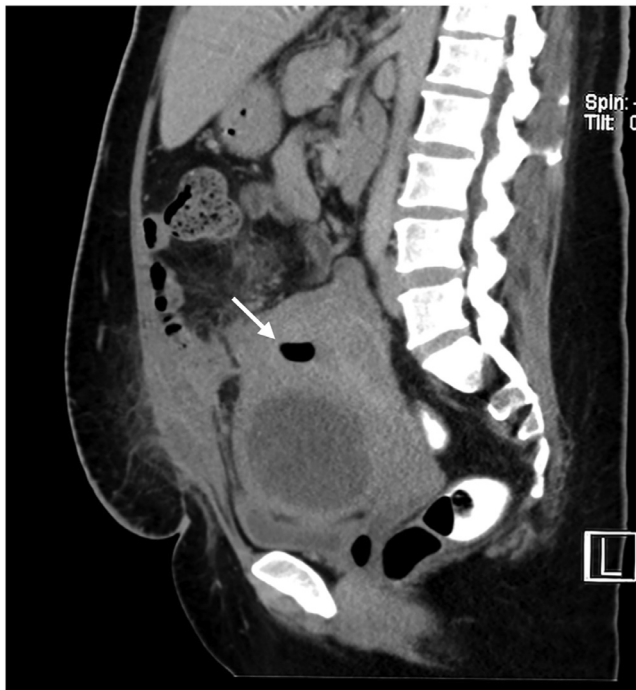

Fig. 2 – Sagittal reformatted contrasted CT abdomen revealed mild hydrometra and air locules (white arrow) within the uterine cavity. Additionally, there is a rim-enhancing collection along the anterior uterine body, along with intramuscular collections within the rectus abdominis muscles and subcutaneous fat stranding, suggestive of an active infection.

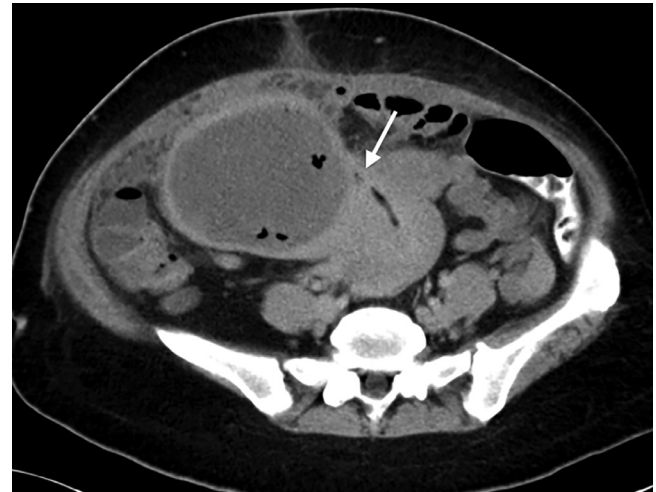

Fig. 3 – Axial reformatted contrasted CT Abdomen demonstrated a small communication track (white arrow) between the largest rim-enhancing mid-abdomen collection with the endometrial cavity indicative of a ruptured pyomyoma with fistula formation.

It can be multiple in up to 84% of women. Fibroids are hormonal dependent responsive to both oestrogen and progesterone. Their size can rapidly increase during pregnancy and generally shrinks after menopause. There is a high likelihood of red degeneration during pregnancy due to hemorrhagic infarction. Hyaline, cystic and myxoid degeneration are others known complication. Pyomyoma is a rare complication following a Caesarean section, and literature searches up to 2016 revealed only <100 reported cases since 1945 [7]. Pregnancy, the postpartum period, and uterine instrumentation procedures such as dilatation and curettage and Caesarean section have

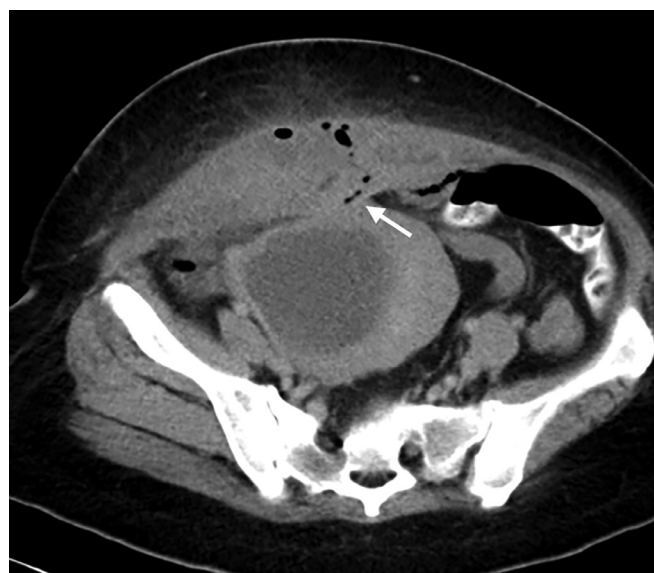


Fig. 4 – Axial reformatted contrasted CT Abdomen showed another smaller pelvic collection which has a suspicious tiny communication track (white arrow) connecting it to the collections within both rectus abdominis muscles anteriorly. There are associated subcutaneous fat stranding.

been identified as significant risk factors for direct inoculation, accounting for a substantial portion of reported pyomyoma cases [7–9]. Additionally, factors such as submucosal leiomyomas, advanced age, pre-existing infections, intravenous drug use, presence of intrauterine devices, diabetes, hypertension, and immunocompromised conditions have been associated with an increased risk of pyomyoma development [10,11].

The precise aetiology of pyomyoma remains unclear. Theories suggest vascular compromise is a primary factor, leading to compromised blood supply to the uterine fibroid leading to necrosis, creating an environment conducive to infection [12–14]. The immunocompromised state during the postpartum period might also contribute to the susceptibility to such infections. The mortality rate ranges from 6% to 21% with antibiotic treatment alone. Pus cultures from pyomyoma generally yield polymicrobial organisms, most commonly *Staphylococcus* sp. *Streptococcus* sp, *E. coli* and *Pasteurella multocida* [15]. Despite no positive results from blood or resected specimen cultures in our index case, broad-spectrum antibiotics remain mandatory and beneficial. While the triad of sepsis, underlying leiomyoma, and the absence of another apparent source of infection has been described as a concerning clinical presentation for pyomyoma [16], its nonspecific presentation may lead to delayed diagnosis and treatment. The presentation of pyomyoma can range from a painful abdominal or pelvic mass to symptoms of bacteremia of unknown origin or an acute abdomen due to the rupture of the infected leiomyoma [17]. In some cases, pyomyoma may mimic other clinical entities such as tuberculosis or ovarian cancer, further complicating its diagnosis [3].

Diagnostic challenges of uterine pyomyoma stem from its rarity, non-specific symptoms, and overlapping clinical features with other conditions. The condition is often difficult to diagnose promptly, leading to potential serious complications if not recognized early [18]. The differential diagnosis of pyomyoma is extensive and includes conditions such as pyometra, tubo-ovarian abscess, and malignancy, further complicating the diagnostic process. In postpartum cases, differentiating between pyomyoma and acute puerperal endometritis is not always straightforward. Imaging plays a pivotal role in the diagnosis and management of pyomyoma, particularly in differentiating it from other pelvic pathologies. Ultrasound is often the first-line imaging modality, revealing a heterogeneous mass with mixed echogenicity due to the presence of solid and cystic components, which may indicate abscess formation [1,19] or infected hematomas, especially in post Caesarean section patients. While non-complicated fibroids exhibit variable contrast enhancement and may appear isodense, hypodense, or hyperdense compared to the myometrium, degenerated fibroid generally do not enhance on CT scans. They may exhibit a cystic-like appearance, indicative of interrupted blood supply, suggesting fibroid degeneration or infarction [20]. From a radiological imaging standpoint, Abulafia et al. (2010) suggested that the presence of an anechoic halo of normal myometrium surrounding the mass may be highly suggestive or even pathognomonic for pyomyoma on ultrasound [21]. The presence of gas locules and debris within the uterine fibroid, along with the breakage of fibroid wall and pneumoperitoneum, raises suspicion of ruptured pyomyoma especially when accompanied by clinical signs of infection

[2,10,16,17] as shown in our case. On the other hands, endometritis is an infection of the uterine lining, shares similar symptoms with pyomyoma. Unlike the rare occurrence of pyomyoma, endometritis is relatively common after childbirth. Whilst pyomyoma may present as a heterogeneous mass with intralesional air locules on imaging, endometritis might exhibit diffuse enhancing endometrial lining thickening or hydrometra with gas locules within. To further complicate the diagnostic dilemma, presence of gas locules can be a normal finding in postpartum patient up to 3 weeks after delivery. Distinguishing between the 2 conditions based solely on clinical presentation is almost always impossible. Magnetic resonance imaging (MRI) offers superior soft tissue contrast and can delineate the extent of the lesion and its relationship with adjacent pelvic structures, facilitating surgical planning [22]. Diffusion-weighted MRI, in particular, has been highlighted for its utility in identifying pyomyoma by demonstrating restricted diffusion in the abscessed areas, aiding in the differentiation from benign fibroid degeneration [23]. However, its use is limited in acute gynecology settings [20].

The clinical management of pyomyoma involves a multifaceted approach, integrating surgical and medical therapies to address the infection and prevent severe complications. Antibiotic therapy is critical to eradicate the underlying infection, with broad-spectrum antibiotics initially administered and subsequently tailored based on culture results [4,24]. Empirical antibiotic regimens often include coverage for anaerobes and gram-negative organisms, which are commonly implicated in pyomyoma [16]. Surgical intervention is often required for definitive treatment, with procedures ranging from abscess drainage to hysterectomy, depending on the severity and extent of the disease [10,17]. Myomectomy may be performed in cases where fertility preservation is desired, although this is contingent on the absence of extensive infection and the patient's overall clinical stability [22]. Hysterectomy, on the other hand, is typically indicated in more severe cases particularly when fertility preservation is not a concern or when there is significant tissue necrosis [2] such as peritonitis due to ruptured pyomyoma where conservative measures are insufficient [25]. The advent of minimally invasive surgical techniques, such as laparoscopic myomectomy and hysterectomy, has improved recovery times and reduced postoperative morbidity in these patients [13,19]. In cases where surgical intervention is not immediately feasible, image-guided percutaneous drainage of abscesses may provide temporary relief and control of infection [5]. The specific management plan depends on various factors including the patient's clinical condition, the extent of infection, fertility considerations, and the expertise available at the healthcare facility. It often requires a multidisciplinary approach involving gynecologists, radiologists, infectious disease specialists, and sometimes surgeons to provide comprehensive care in optimizing patient outcomes.

Conclusion

Pyomyoma rarity and nonspecific presentation make its diagnosis particularly challenging, while endometritis, albeit

more common, require prompt recognition and treatment to prevent chronic sequelae and preserve fertility. Understanding the nuances of these conditions is crucial for healthcare providers to facilitate accurate diagnosis, timely intervention, and optimal management, ultimately ensuring better outcomes and reproductive health for the patients. In conclusion, spontaneous ruptured of pyomyoma post-Caesarean section is an uncommon yet clinically significant complication that warrants attention due to its potential morbidity and mortality.

Patient consent

The authors certify that we have obtained all appropriate patient consent forms. In the form, the patient has given her consent for her images and other clinical information to be reported in the journal. The patient understand that her name and initials will not be published and due efforts will be made to conceal her identity, but anonymity cannot be guaranteed.

REFERENCES

- [1] Krynytska I, Firket C. Genital tuberculosis in postmenopausal patients. *J Obstet Gynaecol* 2007;27(4):444–5. doi:10.1080/01443610701359837.
- [2] Hartman R. Uterine rupture secondary to pyomyoma, leading to intra-abdominal abscesses following an uncomplicated vaginal delivery. *Case Rep Obstetr Gynecol* 2023;1–5 2023:3306687. doi:10.1155/2023/3306687.
- [3] Rezai S, Hastings A, Ferreira K, Folterman C, Astill N, Kolade O, et al. Pyomyoma following uterine artery embolization (UAE): dual case report and review of literature. *Obstetr Gynecol Int J* 2016;4(1):2. doi:10.15406/ogij.2016.04.00097.
- [4] Ogawa T. A rare case of fulminant sepsis secondary to postpartum pyomyoma caused by *Prevotella Bivia*: a case report. *Ann Med Surg* 2023;85(3):606–10. doi:10.1097/ms9.0000000000000287.
- [5] Wang J, Li Z, Sun Y. Prolapsed submucosal pyomyoma postpartum, a rare complication of fibroids. *BMC Pregnancy Childbirth* 2021;21(1):4. doi:10.1186/s12884-021-03619-6.
- [6] Wasinghon P, Huang K, Lai S. Total laparoscopic hysterectomy of an endocervical pyomyoma over previous cesarean section wound. *Gynecol Minimally Invas Ther* 2020;9(2):101. doi:10.4103/gmit.gmit_103_18.
- [7] Iwahashi N, Mabuchi Y, Shiro M, Yagi S, Minami S, Ino K. Large uterine pyomyoma in a perimenopausal female: a case report and review of 50 reported cases in the literature. *Mol Clin Oncol* 2016;5(5):527–31. doi:10.3892/mco.2016.1005.
- [8] Bechay K, Thomas M, Le T, Beck R, Vuu K, Quinn B. Large pyomyoma after an urgent uterine artery embolization (UAE). *J Clin Images Med Case Rep* 2022;3(10):2128. doi:10.52768/2766-7820/2128.
- [9] Wasinghon P, Huang K, Lai S. Total laparoscopic hysterectomy of an endocervical pyomyoma over previous Cesarean Section wound. *Gynecol Minimally Invas Ther* 2020;9(2):101. doi:10.4103/gmit.gmit_103_18.
- [10] Vulasala S, Gopireddy D, Mohamed K, Lall C. Ruptured pyomyoma – rare complication of post-uterine artery embolization: a case report. *J Clin Imaging Sci* 2021;11:67. doi:10.25259/jcis_188_2021.
- [11] Borgo C, Maneschi F, Belvisi V, Morelli F, Vetica A, Marocco R, et al. Postpartum fever in the presence of a fibroid: sphingomonas paucimobilis sepsis associated with pyomyoma. *BMC Infect Dis* 2013;13(1):4. doi:10.1186/1471-2334-13-574.
- [12] Wynn A. Prolapse of a large degenerating uterine leiomyoma: a case report. *Cureus* 2024;16(5):e60622. doi:10.7759/cureus.60622.
- [13] Oshina K, Ozaki R, Kumakiri J, Murakami K, Kawasaki Y, Kitade M, et al. Pyomyoma mimicking tubo-ovarian abscess: two case reports. *Case Rep Women's Health* 2022;33:e00372. doi:10.1016/j.crwh.2021.e00372.
- [14] Read S, Mullins J. Spontaneous ruptured pyomyoma in a nulligravid female: a case report and review of the literature. *Case Rep Obstetr Gynecol* 2018(1):1–6. doi:10.1155/2018/1026287.
- [15] Bagga R, Rai R, Kalra J, Saha PK, Singh T. An unusual cause of postabortal fever requiring prompt surgical intervention: a pyomyoma and its imaging features. *Oman Med J* 2017;32(1):73–6. doi:10.5001/omj.2017.14.
- [16] Obele C, Dunham S, Bennett G, Pagan J, Charles H. A case of pyomyoma following uterine fibroid embolization and a review of the literature. *Case Rep Obstetr Gynecol* 2016;2016:1–5 9835412. doi:10.1155/2016/9835412.
- [17] DeMaio A, Doyle M. Pyomyoma as a rare source of postpartum sepsis. *Case Rep Obstetr Gynecol* 2015;2015:1–2 263518. doi:10.1155/2015/263518.
- [18] Mirzamoradi M, Saleh M, Pournajaf E, Esmaeili S. Pyomyoma as a rare source of post-abortion sepsis: a case report. *Med Case Rep* 2017;201703(04):03. doi:10.21767/2471-8041.100073.
- [19] Yu Q, Gabriel G, Hoffman M, Sanampudi S, Jassim T, Raissi D. Uterine-sparing management of pyomyoma after uterine fibroid embolization. *Radiol Case Rep* 2019;14(8):1031–5. doi:10.1016/j.radcr.2019.05.009.
- [20] Foti PV, Tonolini M, Costanzo V, Mammino L, Palmucci S, Cianci A, et al. Cross-sectional imaging of acute gynaecologic disorders: CT and MRI findings with differential diagnosis-part II: uterine emergencies and pelvic inflammatory disease. *Insights Imaging* 2019;20(1):118. doi:10.1186/s13244-019-0807-6.
- [21] Abulafia O, Shah T, Salame G, Miller MJ, Serur E, Zinn HL, et al. Sonographic features associated with post-uterine artery embolization pyomyoma. *J Ultrasound Med* 2010;29(5):839–42. doi:10.7863/jum.2010.29.5.839.
- [22] Gabidullina RI, Mingazetdinov MA, Druzhkova EB, Sirmatova LI. Experience of pyomyoma treatment. *Gynecology* 2020;22(5):81–3. doi:10.26442/20795696.2020.5.200399.
- [23] Oshina K, Ozaki R, Kumakiri J, Murakami K, Kawasaki Y, Kitade M, et al. Pyomyoma mimicking tubo-ovarian abscess: two case reports. *Case Rep Women's Health* 2021;33:e00372. doi:10.1016/j.crwh.2021.e00372.
- [24] Kaler M, Gailer R, Iskaros J, David AL. Postpartum pyomyoma, a rare complication of sepsis associated with chorioamnionitis and massive postpartum haemorrhage treated with an intrauterine balloon. *Case Rep Obstetr Gynecol* 2015;2015:609205. doi:10.1155/2015/609205.
- [25] Suzuki E, Kuroda H, Saito T, Shinjo A, Iwasaki S, Hasegawa A. Emergency laparoscopic myomectomy for peritonitis secondary to perforated pyomyoma: a case report. *Japan J Gynecol Obstetr Endosc* 2021;37(1):141–8. doi:10.5180/jsgoe.37.1_141.