

# Kinetic patterns of liver enzyme elevation with COVID-19 in the USA

Ben L. Da, Robert A. Mitchell, Brian T. Lee, Ponni Perumalswami, Gene Y. Im, Ritu Agarwal, Thomas D. Schiano, Douglas Dieterich and Behnam Saberi

COVID-19 is a global pandemic that started in Wuhan, China. COVID-19 related liver enzyme elevations have been described however the clinical presentation, enzyme kinetics, and associated laboratory abnormalities of these patients have not been well described. Five cases of COVID-19 associated liver enzyme elevations are reported here. We found that COVID-19 related liver enzyme elevations occurred in a hepatocellular pattern and persisted throughout the initial hospitalization in all patients. Abnormalities in lactate dehydrogenase and ferritin levels were seen in all five cases. In conclusion, abnormalities in aminotransferase, lactate dehydrogenase, and ferritin levels are commonly seen in COVID-19 related liver injury. Elevated aminotransferase levels often persist throughout the entire hospitalization. However, the clinical course of COVID-19 related liver injury appears benign. *Eur J Gastroenterol Hepatol* XXX: 00–00  
Copyright © 2020 Wolters Kluwer Health, Inc. All rights reserved.

## Introduction

Severe acute respiratory syndrome coronavirus 2 (SARS-CoV-2), a novel coronavirus, is the responsible pathogen for the coronavirus disease 2019 (COVID-19) [1]. COVID-19 most commonly presents with a variety of upper and lower respiratory symptoms, fevers, digestive symptoms, laboratory findings suggestive of lymphopenia or thrombocytopenia, and abnormalities on chest CT imaging [2]. COVID-19 can range in severity from mild disease, which occurs in the majority of cases, to severe/critical disease resulting in respiratory failure, septic shock, and multi-organ failure [3].

Severe acute respiratory syndrome (SARS) and Middle East respiratory syndrome (MERS) are two other highly syndromes caused by pathogenic human coronaviruses. Previous studies have shown that SARS and MERS can both cause liver dysfunction and current observations show that SARS-CoV-2 can similarly cause liver injury [4]. Liver enzyme elevations in the setting of COVID-19 have been reported in cohort studies, occurring more often in patients with severe disease [5]. Patients display a hepatocellular pattern of injury with elevations in aspartate aminotransferase (AST) and alanine aminotransferase (ALT); these elevations are reported to occur in 16.1–53.0% and 21.3–32.0% of COVID-19 patients, respectively (Table 1) [2,6–8]. Abnormalities in other hepatic parameters such as total bilirubin, gamma-glutamyl transferase, prothrombin time, and albumin have also been noted (2, 5, 8, and 11) [2,5,7].

Despite previous reports from China, information is sparse regarding the clinical course of COVID-19 patients with liver dysfunction, especially in the USA. This is important because it is now known that there are two major strains (L and S) of SARS-CoV-2 that may have different clinical disease severity with the L strain being more prevalent early in the initial outbreak in China [9]. In this study, we report the clinical presentation, course, and liver enzyme kinetics of five patients with COVID-19 related liver injury seen in the USA.

## Cases

Five patients diagnosed with COVID-19 with PCR testing (Roche cobas SARS-CoV-2 assay) obtained via nasopharyngeal swab were included in this case series. All patients were ruled out for common etiologies of hepatitis, such as viral and autoimmune. Clinical characteristics and laboratory data for all five patients are shown in Table 2. Daily trends of AST and ALT are shown in Fig. 1a and b.

Patient 1 was a 26-year-old male with a history of childhood asthma who presented with fevers, cough, sore throat, and mild dyspnea for approximately 1 week before the diagnosis of COVID-19 on admission. Patient 2 was a 62-year-old male with a history of cerebrovascular disease, non-insulin dependent diabetes mellitus, and metabolic syndrome who presented from his nursing facility with fevers and dyspnea for 1 week before the diagnosis of COVID-19 on admission. He was briefly treated with hydroxychloroquine (day of admission to 3 days after admission); however, treatment was stopped due to QTc prolongation. Patient 3 was a 46-year-old male with a history of non-insulin dependent diabetes mellitus who presented with fevers, cough, and diffuse abdominal pain for 4 days before diagnosis of COVID-19 on admission. Patient 4 was a 46-year-old female who presented with a newly diagnosed deep venous thrombosis, admitted for thrombolysis, thrombectomy, and inferior vena cava filter

*European Journal of Gastroenterology & Hepatology* 2020, XXX:00–00

**Keywords:** COVID-19, hepatitis, pandemics, viral hepatitis

Division of Liver Diseases, Icahn School of Medicine at Mount Sinai, New York, NY, USA

Correspondence to Behnam Saberi, MD, Division of Liver Diseases, Icahn School of Medicine at Mount Sinai, Box 1123, 1425 Madison Ave, Room 11-73, New York, NY 10029, USA

Tel: +212 659 9219; fax: +212 849 2574; e-mail: behnam.saberi@mssm.edu

**Received** 9 April 2020 **Accepted** 22 April 2020

**Table 1.** Summary of available evidence on the prevalence of aspartate aminotransferase/alanine aminotransferase elevations in COVID-19 patients

	Country of origin	Number of COVID-19 patients	Type of patients	Underlying liver disease (%)	Patients with elevated liver tests
Arentz <i>et al.</i> [14]	USA	21	ICU	4.8%	14.3% elevation of AST or ALT >3x ULN
Chen <i>et al.</i> [7]	China	99	All	N/A	28% elevated ALT 35% elevated AST 18% elevated TB 76% elevated LDH
Guan <i>et al.</i> [2]	China	1099	All	2.1% (HBV)	21.3% elevated ALT 22.2% elevated AST 10.5% elevated TB
Huang <i>et al.</i> [6]	China	41	All	2%	37% elevated AST 73% elevated LDH
Shi <i>et al.</i> [15]	China	81	All	9%	53% elevated AST
Xu <i>et al.</i> [8]	China	62	All	11%	16.1% elevated AST 27% elevated LDH
Yang <i>et al.</i> [13]	China	52	ICU	N/A	29% evidence of liver dysfunction
Zhang <i>et al.</i> [5]	China	56	All	N/A	28.6% evidence of liver dysfunction

ALT, alanine aminotransferase; AST, aspartate aminotransferase; HBV, hepatitis B virus; LDH, lactate dehydrogenase; N/A, not available; TB, total bilirubin.

**Table 2.** Summary of available evidence on the prevalence of aspartate aminotransferase/alanine aminotransferase elevations in COVID-19 patients

	Patient 1	Patient 2	Patient 3	Patient 4	Patient 5	Lab reference range
Age	26	62	46	46	29	-
Sex	Male	Male	Male	Female	Female	-
PMH	Childhood asthma	CVA; NIDDM; hypertension; hyperlipidemia	NIDDM; hypertension	Deep vein thrombosis	Pregnant (10 weeks)	-
COVID-19 directed treatments	None	Hydroxychloroquine	Azithromycin	None	Hydroxychloroquine	-
Peak AST (U/L)	452	501	316	339	487	1–35
Peak ALT (U/L)	484	563	397	251	403	1–45
Peak ALP (U/L)	79	156	96	77	69	38–126
Peak TB (mg/dl)	1.0	0.8	0.4	0.6	1.2	0.1–1.2
Peak LDH (U/L)	1037	619	696	1178	439	100–220
Albumin (g/dl)	3.0	2.1	2.9	2.5	3.7	3.5–4.5
Ferritin (ng/ml)	2134	2017	2190	457	4332	30–400
Total IgG immunoglobulins	1819	1201	1279	Not done	1282	700–1600
CRP	38.7	275	14.5	Not done	39.2	0–5
ANA	Pending	Negative	Negative	Not done	Negative	Negative
Hepatitis A/B/C serologies	Negative	Negative	Negative	Negative	Negative	Negative
Chest CT findings	Not done	Large unilateral pleural effusion	Not done	Not done	Not done	-
Liver imaging	Ultrasound – normal	Ultrasound – echogenic and enlarged liver	Ultrasound – normal contour	Ultrasound – normal echotexture	Ultrasound – mildly enlarged, increased echogenicity	-
LOS	11 days	13 days	5 days	8 days	4 days	-
Maximum oxygen requirements	10 L/min NRB	6 L/min NC	Room air	Room air	Room air	-
Outcome	Discharged home	Discharged to nursing facility	Discharged home	Discharged home	Discharged home	-

ALP, alkaline phosphatase; ALT, alanine aminotransferase; ANA, antinuclear antibodies; AST, aspartate aminotransferase; COVID-19, coronavirus 2019; CRP, c-reactive protein; CVA, cerebrovascular accident; LDH, lactate dehydrogenase; LOS, length of stay; NC, nasal cannula; NIDDM, non-insulin dependent diabetes mellitus; NRB, non-rebreather; PMH, past medical history; TB, total bilirubin.

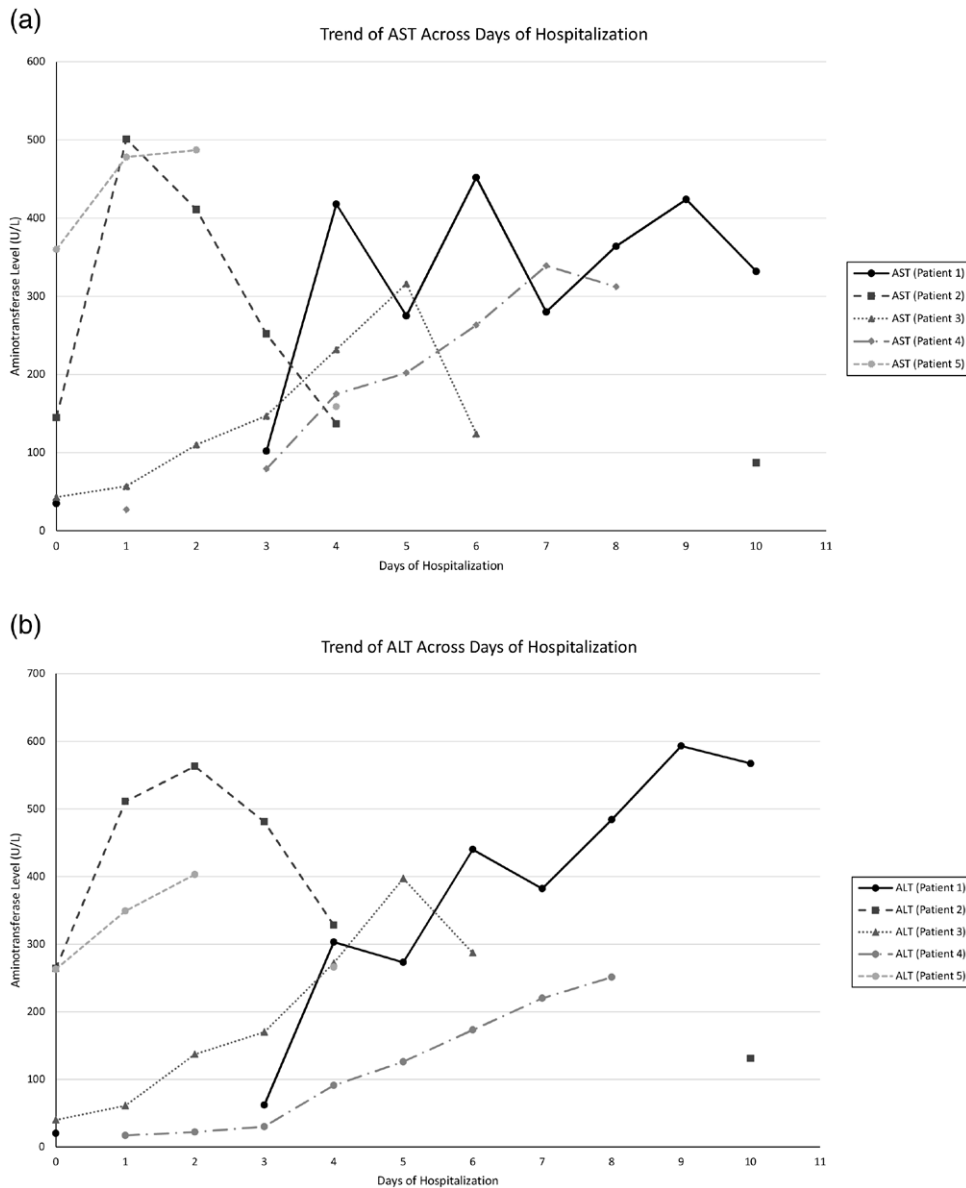
placement. Five days after admission, she was noted to have chest CT findings of ground-glass opacities despite a lack of respiratory symptoms, and a COVID-19 test was sent and resulted positive. Patient 5 was a 29-year-old pregnant female at 10 weeks of gestation who presented with fever, sore throat, and congestion for 2 days before the diagnosis of COVID-19 on admission. She was started on hydroxychloroquine therapy.

**Discussion**

Herein, we report the clinical presentation and the kinetics of liver enzymes elevations during the hospitalization

of five COVID-19 patients with COVID-19 related liver injury. The pattern of liver injury in all patients was primarily hepatocellular with elevated AST and ALT levels that persisted throughout the entire hospital course except in cases of patient 2 and patient 3, where enzyme levels significantly decreased by the end of the hospitalization. Significant elevations in serum lactate dehydrogenase (LDH) and ferritin levels were seen in all patients. None of the patients developed any signs of acute liver failure.

There are several hypotheses regarding the mechanism of action of COVID-19 and liver test abnormalities [4,5]. The first hypothesis is that COVID-19 can trigger an immune-mediated liver injury in certain individuals who develop severe



**Fig. 1.** (a) AST enzyme pattern of COVID-19 patients. Trends of AST of patients since admission. (b) ALT enzyme pattern of COVID-19 patients. Trends of ALT of patients since admission. AST, aspartate aminotransferase; ALT, alanine aminotransferase.

liver dysfunction related to an exaggerated cytokine storm, ultimately resulting in multi-organ failure and acute respiratory distress syndrome [10]. On histological examination, evidence of over-activation of T cells and increased Th17 and high cytotoxicity of CD8 T cells has been reported [11]. Another possible mechanism is via direct insult by SARS-CoV-2 akin to SARS-CoV. Finally, a third hypothesis is injury via an ischemic process related to hypoxia. Reports from China suggest a higher rate of AST compared to ALT elevation consistent with ischemic liver injury due to hepatic zone 3 coagulative necrosis. Our data did show significantly elevated LDH levels in all five patients [2].

It is currently unclear how long COVID-19 related liver dysfunction will persist or whether the presence of liver dysfunction affects survival. Yao *et al.* [12] reported 40 cases of COVID-19-related liver injury with recovery within 1 week after treatment for COVID. In a study of only critically ill COVID-19 patients from China, liver dysfunction was present in six of 20 (30%) survivors and nine of 32 (28%) non-survivors [13]. The findings from this study

suggest that the presence of liver dysfunction does not affect survival. Additional long-term follow-up will be helpful to assess presence or absence of persistent liver injury.

In summary, we report a single-center experience in the USA of five cases of COVID-19 related liver injury. Injury in all cases occurred in a hepatocellular pattern with concomitant derangements in other tests such as LDH and ferritin noted. There are potentially multiple mechanisms for liver injury including immune-mediated hepatitis, viral insult, or ischemic injury related to COVID-19 pneumonia. Although isolated liver failure due to COVID-19 has not yet been reported, further studies are needed to elucidate the short- and long-term clinical impact of COVID-19 related liver dysfunction.

**Acknowledgements**

Guarantor of the article: B.S. Concept and design: B.D. and B.S. Acquisition of data: B.D., R.M., B.L., and B.S. Statistical analysis and interpretation of data: B.D. and B.S.

Drafting and revision of the manuscript: B.D., R.M., B.L., P.P., G.I., R.A., T.S., D.D., and B.S. All authors approve the final version of the article.

### Conflicts of interest

D.D.: Participates on the advisory board and received research grants from Gilead and Abbvie. For the remaining authors, there are no conflicts of interest.

### References

- Gorbalenya AE, Baker SC, Baric RS, de Groot RJ, Drosten C, Gulyaeva AA, *et al.* <em>Severe acute respiratory syndrome-related coronavirus</em>: the species and its viruses – a statement of the Coronavirus Study Group. *bioRxiv* 2020:2020.2002.2007.937862.
- Guan WJ, Ni ZY, Hu Y, Liang WH, Ou CQ, He JX, *et al.* Clinical characteristics of coronavirus disease 2019 in China. *N Engl J Med* 2020; 382:1708–1720.
- Wu Z, McGoogan JM. Characteristics of and important lessons from the coronavirus disease 2019 (COVID-19) outbreak in China: summary of a report of 72314 cases from the Chinese Center for Disease Control and Prevention. *JAMA* 2020; 323:1239–1242.
- Xu L, Liu J, Lu M, Yang D, Zheng X. Liver injury during highly pathogenic human coronavirus infections. *Liver Int* 2020; 40:998–1004.
- Zhang C, Shi L, Wang FS. Liver injury in COVID-19: management and challenges. *Lancet Gastroenterol Hepatol* 2020; 5:428–430.
- Huang C, Wang Y, Li X, Ren L, Zhao J, Hu Y, *et al.* Clinical features of patients infected with 2019 novel coronavirus in Wuhan, China. *Lancet* 2020; 395:497–506.
- Chen N, Zhou M, Dong X, Qu J, Gong F, Han Y, *et al.* Epidemiological and clinical characteristics of 99 cases of 2019 novel coronavirus pneumonia in Wuhan, China: a descriptive study. *Lancet* 2020; 395:507–513.
- Xu XW, Wu XX, Jiang XG, Xu KJ, Ying LJ, Ma CL, *et al.* Clinical findings in a group of patients infected with the 2019 novel coronavirus (SARS-CoV-2) outside of Wuhan, China: retrospective case series. *BMJ* 2020; 368:m606.
- Tang X, Wu C, Li X, Song Y, Yao X, Wu X, *et al.* On the origin and continuing evolution of SARS-CoV-2. *National Sci Review* 2020; nwa036.
- Mehta P, McAuley DF, Brown M, Sanchez E, Tattersall RS, Manson JJ; HLH Across Speciality Collaboration, UK. COVID-19: consider cytokine storm syndromes and immunosuppression. *Lancet* 2020; 395:1033–1034.
- Xu Z, Shi L, Wang Y, Zhang J, Huang L, Zhang C, *et al.* Pathological findings of COVID-19 associated with acute respiratory distress syndrome. *Lancet Respir Med* 2020; 8:420–422.
- Yao N, Wang SN, Lian JQ, Sun YT, Zhang GF, Kang WZ, Kang W. [Clinical characteristics and influencing factors of patients with novel coronavirus pneumonia combined with liver injury in Shaanxi region]. *Zhonghua Gan Zang Bing Za Zhi* 2020; 28:234–239.
- Yang W, Cao Q, Qin L, Wang X, Cheng Z, Pan A, *et al.* Clinical characteristics and imaging manifestations of the 2019 novel coronavirus disease (COVID-19): a multi-center study in Wenzhou city, Zhejiang, China. *J Infect* 2020; 80:388–393.
- Arentz M, Yim E, Klaff L, Lokhandwala S, Riedo FX, Chong M, *et al.* Characteristics and outcomes of 21 critically ill patients with COVID-19 in Washington State. *JAMA* 2020; 323:1612–1614.
- Shi H, Han X, Jiang N, Cao Y, Alwalid O, Gu J, *et al.* Radiological findings from 81 patients with COVID-19 pneumonia in Wuhan, China: a descriptive study. *Lancet Infect Dis* 2020; 20:425–434.