

# Fifteen-degree clavicular hook plate achieves better clinical outcomes in the treatment of acromioclavicular joint dislocation

Journal of International Medical Research  
2018, Vol. 46(11) 4547–4559  
© The Author(s) 2018  
Article reuse guidelines:  
sagepub.com/journals-permissions  
DOI: 10.1177/0300060518786910  
journals.sagepub.com/home/imr



Guanghui Li<sup>1,2</sup>, Tuoen Liu<sup>3</sup> , Xianfang Shao<sup>2</sup>,  
Zhijun Liu<sup>2</sup>, Jianhui Duan<sup>2</sup>, Raji Akileh<sup>3</sup>,  
Shousong Cao<sup>4</sup> and Dadi Jin<sup>1</sup>

## Abstract

**Objective:** Clavicular hook plate application is one of the most commonly used treatment methods for acromioclavicular (AC) joint dislocation, although it may cause multiple postoperative complications. We modified the regularly used 0° hook plate to 15° and compared the clinical outcomes of these two hook plates for treatment of AC joint dislocation.

**Methods:** Forty-three patients with acute AC joint dislocation were randomly enrolled (0° hook plate, 20 patients; 15° hook plate, 23 patients). The American Shoulder and Elbow Surgeons (ASES) and visual analog scale for pain (VASP) scores were evaluated preoperatively and at 3 days and 1, 2, 3, and 6 months postoperatively and compared between the two groups.

**Results:** Compared with the preoperative scores, the 6-month postoperative ASES score gradually increased but the VASP score decreased in both groups. Furthermore, the ASES and VASP scores were significantly different between the two groups at every postoperative time point.

**Conclusion:** The 15° hook plate is superior to the 0° hook plate in reducing shoulder pain and improving postoperative recovery in the treatment of AC joint dislocation.

**Level of evidence:** Level III; Treatment study (retrospective comparative study).

<sup>1</sup>Department of Orthopedic Surgery, The Third Affiliated Hospital, Southern Medical University, Guangzhou, Guangdong, China

<sup>2</sup>Department of Orthopedic Surgery, The First Traditional Chinese Medical Hospital of Hunan Changde, Changde, Hunan, China

<sup>3</sup>Department of Biomedical Sciences, West Virginia School of Osteopathic Medicine, Lewisburg, WV, United States

<sup>4</sup>Department of Pharmacology, School of Pharmacy, Southwest Medical University, Luzhou, Sichuan, China

## Corresponding author:

Dadi Jin, Department of Orthopedic Surgery, The Third Affiliated Hospital, Southern Medical University, 183 Zhongshan West Avenue, Tianhe District, Guangzhou, Guangdong Province 510630, China.  
Email: dadijin@yahoo.com



## Keywords

Acromioclavicular joint dislocation, 0-degree clavicular hook plate, 15-degree clavicular hook plate, hook plate angle, American Shoulder and Elbow Surgeons (ASES) score, visual analog scale for pain (VASP) score

Date received: 14 January 2018; accepted: 25 May 2018

## Introduction

Acromioclavicular (AC) joint dislocation is a very common injury and often results from trauma directed to the shoulder joint. The AC joint not only participates in shoulder-related activities but also serves an important structural role in the connection of the shoulder blade and trunk. AC joint dislocation is often accompanied by pain, discomfort, and dysfunction of the shoulder. Various approaches are currently used to treat AC joint dislocation; among them, the hook plate is a commonly used method.<sup>1,2</sup> Despite its popularity in the surgical treatment of acute AC joint dislocation, studies have shown that hook plate treatment is associated with various postoperative complications such as shoulder pain and limited joint movement.<sup>3,4</sup> Therefore, we evaluated the clinical effectiveness of 0° and 15° hook plates in the treatment of AC joint dislocation to improve the effectiveness and reduce postoperative complications of this procedure.

In the present study, patients with AC joint dislocation were treated with either the commonly used 0° angle hook plate or a 15° angle hook plate to compare the clinical outcomes of postoperative shoulder pain and functional recovery.<sup>5</sup> This study will be helpful for surgeons to decide which type of clavicular hook plate to use in the surgical treatment of patients with AC joint dislocation.

## Materials and methods

### *Ethical approval of study protocol and patient consent*

The study protocol (reference number: 20080115) was reviewed and approved by the Medical Ethics Committee of the First Traditional Chinese Medicine Hospital of Hunan Changde (Changde, Hunan, China). The study was carried out in strict accordance with the Declaration of Helsinki and amendments, and informed written consent was obtained from all patients prior to enrollment.

### *Patients*

The patient inclusion criteria were (1) acute AC joint dislocation, (2) closed Rockwood types III and V dislocation, and (3) unilateral dislocation. The patient exclusion criteria were (1) concurrent scapular fractures; (2) concurrent ipsilateral distal clavicle fractures; (3) concurrent trauma involving the brain, abdomen, chest, skin, or other sites; and (4) infection. The patients were randomly divided into two groups based on their hospital admission number: those treated with the regularly used 0° hook plate and those treated with the 15° hook plate.


### *Preoperative preparation*

Prior to surgery, conventional shoulder anteroposterior radiographs were obtained

to determine the type of dislocation. Rockwood type III or V AC joint dislocation was confirmed by the radiograph and physical examination findings. To obtain a correct diagnosis of Rockwood type II and III/V dislocations, an additional anteroposterior radiograph was obtained with a weighed stress view. Some patients originally diagnosed with type III dislocation were found to have type V. Three-dimensional shoulder computed tomography or magnetic resonance imaging scans were warranted to exclude other injuries of the shoulder joint. Patients enrolled in the study included those with both type III and type V injuries that were treated with clavicular hook plates (Trauson Medical Instrument Company, Changzhou, Jiangsu, China or Tianjin Zhengtian Medical Instrument Company, Tianjin, China).

### Surgical procedure

The patients in the 0° hook plate group (Figure 1(a)) underwent a brachial plexus musculocutaneous nerve block or general anesthesia (tracheal intubation). A shoulder pad was placed to elevate the position of the shoulder, while the head was positioned contralateral to the affected shoulder. An approximately 8-cm incision was made starting about 2 cm behind the distal end of the clavicle, parallel to the clavicle on the lateral side, and the distal end of the incision was made across the AC joint. The distal clavicle, AC joint, and acromion process were fully exposed to the orthopedic surgeons. Any AC joint hematomas or broken joint discs or cartilage were carefully removed. The AC joint dislocation was then reset and temporarily fixed with a 2.0 Kirschner wire. The hook plate was properly inserted under the acromion process and fixed to the clavicle using a Kocher's clamp. The screws were placed after holes had been drilled for proper fitting of screws. The Kirschner wire was then removed.



**Figure 1.** Comparison of the regularly used 0° hook plate and the 15° hook plate. (a) The 0° plate is shown on the top, and the 15° plate is shown on the bottom. (b) The 0° plate is measured by a goniometer. (c) The 15° plate is measured by a goniometer. The angle of the hook plate is the angle formed by the direction of the hook relative to the plate (horizontal) level. The direction of the hook is parallel to the direction of the plate (parallel to the horizontal level) in the 0° hook plate. A 15° angle is present between the direction of the hook and plate in the 15° hook plate.

Finally, the coracoclavicular ligament was probed, and depending on the fracture type, the ligament was either directly sutured or rebuilt by implanting an anchor in the coracoid process. The patients in the 15° hook plate group (Figure 1(b)) underwent the same surgical procedure as those in the 0° hook plate group.

### Postoperative treatment

Movement of the AC joint was facilitated with a neck wrist strap brake for 2 weeks after surgery, and joint function-improvement exercises including shoulder flexion, abduction, and external rotation

were initiated and assessed 3 days after surgery. Anti-resistance exercises were initiated 2 weeks after surgery. Shoulder movements were performed 3 weeks after surgery.

### Evaluation index

Postoperative radiographs were performed to determine the reduction of the AC joint dislocations by the same physicians who performed the preoperative radiographs. Shoulder function was assessed using the American Shoulder and Elbow Surgeons (ASES) score, and the degree of local pain was assessed using the visual analog scale for pain (VASP) score. The follow-up data collection was completed via either face-to-face questionnaires or telephone calls. Postoperative data were collected at 3 days and 1, 2, 3, and 6 months after surgery (a total of five times). All patients were followed up for at least 2 years postoperatively.

### Statistical analysis

Continuous variables with normal distributions are expressed as mean  $\pm$  standard deviation. The two-sample t-test, chi-square test, and Fisher's exact test were used for the statistical analysis. The statistical analysis was performed using the SPSS version 19.0 (IBM Corp., Armonk, NY, USA). Significance levels were set at  $p < 0.05$ ,  $p < 0.01$ , and  $p < 0.001$ .

## Results

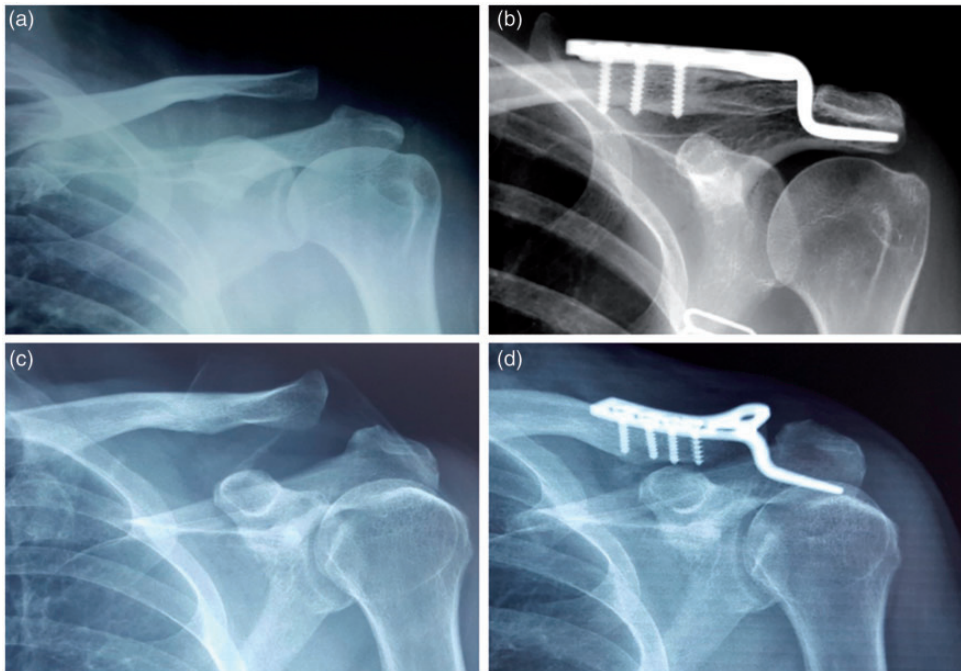
On the basis of the inclusion and exclusion criteria, 43 patients with closed Rockwood types III or V AC joint dislocations were enrolled in the study (25 men, 18 women; age range, 18–50 years; mean, 30.9 years; 23 left-side dislocations, 20 right-side dislocations). Of the 43 patients, 20 were treated with the regular 0° hook plate (Figure 1(a)) and 23 were treated with the 15° hook plate (Figure 1(b)). The patients in the 0° hook plate group comprised 11 men and 9 women aged 20 to 50 years (mean, 30.70  $\pm$  9.65 years); 10 were injured on the left side and 10 on the right side. The mean waiting time from hospital admission to surgery was 1.85  $\pm$  0.81 days. The patients in the 15° hook plate group comprised 14 men and 9 women aged 20 to 50 years (mean, 31.70  $\pm$  8.17 years); 13 were injured on the left side and 10 on the right side. The mean waiting time from hospital admission to surgery was 1.78  $\pm$  0.85 days. There were no significant differences in age, sex, side of injury, or waiting time from injury to surgery between the two groups of patients (Table 1).

The radiographs obtained preoperatively (day 1) and postoperatively (day 3) showed good fixation and reduction of the AC joint in patients of both the 0° hook plate group (Figure 2(a) and (b)) and the 15° hook plate group (Figure 2(c) and (d)), suggesting that patients treated with either the 0° or

**Table 1.** Characteristics of enrolled patients with acromioclavicular joint dislocation treated by 0° or 15° hook plates.

Group	Sex		Injury side		Waiting time* (days)	Age (years)
	Male	Female	Left	Right		
0° hook plate (n = 20)	11	9	10	10	1.85 $\pm$ 0.81	30.70 $\pm$ 9.65
15° hook plate (n = 23)	14	9	13	10	1.78 $\pm$ 0.85	31.70 $\pm$ 8.17
t/x <sup>2</sup> (0° vs. 15°)		0.151		0.183	0.265	-0.366
p-value (0° vs. 15°)		0.697		0.669	0.793	0.716

\*Waiting time from hospital admission to surgery. Waiting time and age are presented as mean  $\pm$  standard deviation.



**Figure 2.** Representative preoperative and postoperative radiographs in patients with acromioclavicular joint dislocation. (a) Representative 1-day preoperative anteroposterior (AP) radiograph of a patient treated with a 0° hook plate. (b) Representative 3-day postoperative AP radiograph of a patient treated with a 0° hook plate. (c) Representative 1-day preoperative AP radiograph of a patient treated with a 15° hook plate. (d) Representative 3-day postoperative AP radiograph of a patient treated with a 15° hook plate.

15° hook plate had good fixation and reduction. In addition, the surgical incisions were well healed without infection and the integrity of the hook plate remained without postoperative complications in all patients. All patients were followed up for at least 2 years postoperatively. The internal fixation device was removed within 6 to 12 months postoperatively depending on the patient's status of recovery. After removing the internal fixation device, one patient from each group developed shoulder subluxation. Neither of these patients had uncomfortable symptoms or other complications; thus, no further treatment was given.

The ASES scores were assessed to evaluate shoulder function in both groups of patients before and after surgery, and the

results are summarized in Table 2. The ASES score in patients in the 0° hook plate group increased gradually postoperatively, with significant improvement starting from 1 month after the surgery ( $p < 0.001$  vs. preoperative). Similarly, the ASES score in patients in the 15° hook plate group also gradually increased after the surgery. However, the significant improvement in the ASES score in these patients was observed as early as day 3 postoperatively ( $p < 0.001$  vs. preoperative). These findings suggest that the patients treated with the 15° hook plate experienced earlier postoperative improvement of shoulder function than patients treated with the 0° hook plate.

The VASP scores were also assessed for the degree of local pain in patients before

**Table 2.** Comparison of American Shoulder and Elbow Surgeons scores before and after surgery between patients treated with 0° and 15° hook plates.

Group	Preoperative	Postoperative				
		3 days	1 month	2 months	3 months	6 months
0° hook plate	39.52 ± 3.30	41.66 ± 4.27	56.86 ± 6.38	64.61 ± 6.08	70.57 ± 4.91	76.05 ± 4.86
<i>p</i> -value (pre- vs. postoperative in 0° group)		0.184	<0.001	<0.001	<0.001	<0.001
15° hook plate	37.84 ± 2.94	46.03 ± 4.19	69.86 ± 6.73	80.26 ± 5.17	85.61 ± 2.92	88.83 ± 2.23
<i>p</i> -value (pre- vs. postoperative in 15° group)		<0.001	<0.001	<0.001	<0.001	<0.001
<i>t</i> / <i>x</i> <sup>2</sup> (0° vs. 15°)	1.763	-3.385	-6.469	-9.119	-12.386	-11.253
<i>p</i> -value (0° vs. 15°)	0.085	0.002	<0.001	<0.001	<0.001	<0.001

Data are presented as mean ± standard deviation unless otherwise indicated.

**Table 3.** Comparison of visual analog scale for pain scores before and after surgery between patients treated with 0° and 15° hook plates.

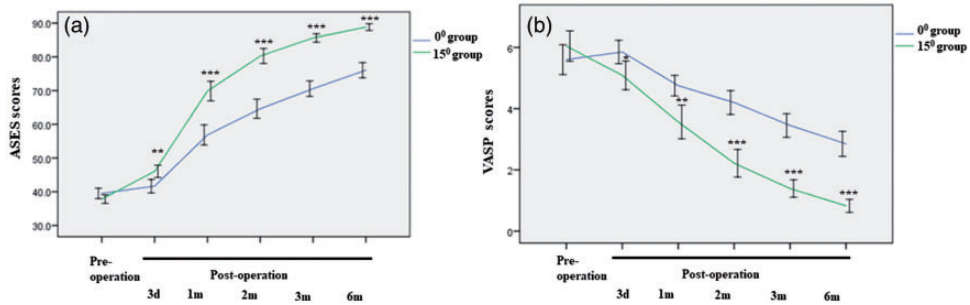
Group	Preoperative	Postoperative				
		3 days	1 month	2 months	3 months	6 months
0° hook plate	5.60 ± 1.05	5.85 ± 0.81	4.75 ± 0.72	4.20 ± 0.83	3.45 ± 0.83	2.85 ± 0.88
<i>p</i> -value (pre- vs. postoperative in 0° group)		0.358	0.002	<0.001	<0.001	<0.001
15° hook plate	6.04 ± 1.15	5.09 ± 1.08	3.57 ± 1.27	2.22 ± 1.04	1.39 ± 0.66	0.83 ± 0.49
<i>p</i> -value (pre- vs. postoperative in 15° group)		0.001	<0.001	<0.001	<0.001	<0.001
<i>t</i> / <i>x</i> <sup>2</sup> (0° vs. 15°)	-1.317	2.580	3.628	6.816	9.104	9.513
<i>p</i> -value (0° vs. 15°)	0.195	0.014	0.001	<0.001	<0.001	<0.001

Data are presented as mean ± standard deviation unless otherwise indicated.

and after the surgery, and the results are summarized in Table 3. The VASP scores were significantly reduced in patients treated with the 0° hook plate starting 1 month postoperatively (4.75 ± 0.72) compared with the preoperative period (5.60 ± 1.05; *p* < 0.01); the scores then gradually decreased with time until reaching 2.85 ± 0.88 at 6 months postoperatively. However, the VASP scores in patients treated with the 15° hook plate significantly decreased much more rapidly; an obvious score reduction occurred as early as 3 days

postoperatively (*p* < 0.001 vs. preoperative) (Table 3).

The detailed statistical results of the ASES and VAS scores were compared between the patients treated with the 0° and 15° hook plates (Tables 2 and 3). There were no significant differences in the preoperative ASES and VASP scores between the 0° and 15° hook plate groups (39.52 ± 3.30 vs. 37.84 ± 2.94 and 5.60 ± 1.05 vs. 6.04 ± 1.15, respectively; *p* > 0.05). However, significant differences (*p* < 0.01 or *p* < 0.001) in the ASES and



**Figure 3.** Comparison of the (a) American Shoulder and Elbow Surgeons (ASES) and (b) visual analog scale for pain (VASP) scores between the patients treated with the 0° hook plate and 15° hook plate. There was no statistically significant difference in the preoperative ASES and VASP scores; however, the postoperative ASES and VASP scores were significantly different at every time point between the patients in the 0° and 15° groups. Statistical significance is indicated by \* $p < 0.05$ , \*\* $p < 0.01$ , and \*\*\* $p < 0.001$  versus the 0° hook plate by the two-sample t-test, chi-square test, and Fisher's exact test.


VASP scores were observed at each time point of the subsequent postoperative evaluations (3 days and 1, 2, 3, and 6 months after surgery) between the two groups of patients (Figure 3). These data suggest that patients treated with the 15° hook plate had less pain and better postoperative recovery than those treated with the 0° hook plate.

## Discussion

The hook plate is one of the most common methods used in the treatment of AC joint dislocation. The hook is placed under the acromion and can form a leverage-like structure when the plate is placed on top of the distal clavicle during surgery. Use of this leverage helps to push the plate downward and allows the distal hook to produce sustained and stable upward pressure, assisting in fixing the dislocated AC joint as well as providing a stable environment for the healing of ligaments and joint capsules.<sup>6</sup> Use of the hook plate is also helpful for early functional improvement exercises to avoid muscle atrophy and shoulder joint adhesion caused by long-term fixation. The hooked end of the hook plate is located close to the acromion

bone and is inserted into the back of the acromion to decrease its impact on the rotator cuff and decrease the incidence of subacromial impingement syndrome. In addition, the hook plate allows the AC joint freedom of micromovement during shoulder joint abduction, which provides uniformity with the corresponding biomechanics of the shoulder joint.<sup>7</sup>

Hook plates have been widely used in the surgical treatment of patients with AC joint dislocation because of their advantages in improving AC joint reduction. However, the use of hook plates can also cause multiple postoperative complications, among which shoulder pain is a major problem. Previous authors have described a variety of factors that can cause shoulder pain after internal fixation using a clavicular hook plate.<sup>8-10</sup> In summary, there are four major causes of shoulder pain after surgery, as follows. (1) Pressure on the shoulder induced by the hook plate: The principle role of the hook plate is to form a lever that provides balance between the plate (placed on the clavicle) and the hook (placed under the acromion) (Figure 4). After the hook plate is implanted into patients with AC joint dislocation, it can produce sustained pressure on the distal



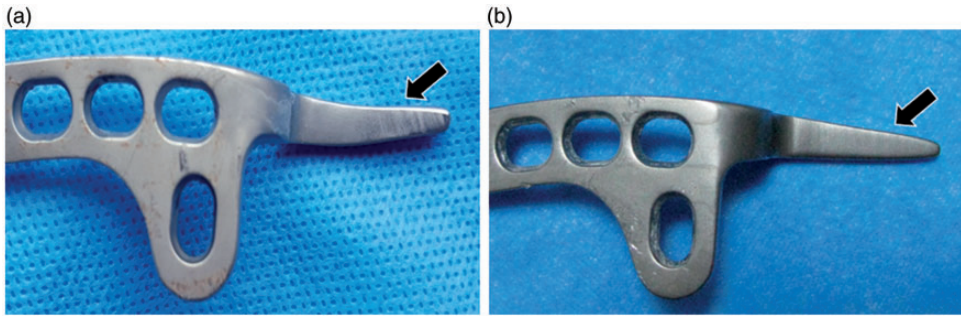
**Figure 4.** Comparison of the clavicle angle between the (a) 0° hook plate and (b) 15° hook plate in the clavicle of a shoulder joint model. The clavicle angle is about 14° with application of the 0° hook plate (indicated by green arrow) and about 9° with application of the 15° hook plate (indicated by green arrow).

clavicle, leading to reduction through the uplift of the acromion by the hook. However, excessive pressure on the acromion induced by the hook can cause unbearable pain in these patients after surgery.<sup>11,12</sup> (2) Accidental dislocation of the distal clavicle: When the steel plate is implanted during the surgery, the hook plate and clavicle cannot be naturally matched and fixed. Thus, screws must be implemented to fix the plate to the clavicle. In the present study, the plate and clavicle were adhered together with screws using a Kocher's clamp by external force, which may lead to iatrogenic dislocation of the distal clavicle, resulting in shoulder pain.<sup>13-15</sup> (3) Post-traumatic arthritis caused by fragmented tissues (such as fragmented bones, articular discs, cartilage, and ligaments) remaining in the AC joint after the surgery.<sup>16-18</sup> (4) Stimulation of peripheral nerves in soft tissues between the hook of the hook plate and the acromion.<sup>19,20</sup>

As described above, postoperative pain was induced by employing the commonly used 0° hook plate (Figure 1(a)) in the surgical treatment of patients with AC joint dislocation. In the present study, we modified the hook plate to improve the clinical outcome of patients with AC dislocation. The 15° hook plate was pre-bent to form

a 15° angle between the hook and plate (Figure 1(b)). The modified 15° hook plate was first tested and applied to shoulder joint models prior to use in patients clinically. The 0° hook plate forms a larger angle between the plate and clavicle compared with the 15° hook plate, suggesting that the 0° hook plate places greater pressure on the clavicle. Moreover, the clavicle angle is about 14° with application of the 0° hook plate (Figure 4(a)), while the clavicle angle is about 9° with application of the 15° hook plate (Figure 4(b)). The decrease in the clavicle angle indicates that the force needed to press the hook plate for adherence with the clavicle will be much less with the 15° than 0° hook plate. This also suggests that the 15° hook plate would cause much less compression on the clavicle than the 0° hook plate, resulting in better reduction of postoperative shoulder pain.<sup>21,22</sup> Because the hook of the hook plate is placed under the acromion during surgery, movement of the shoulder joint postoperatively can produce friction between the hook and acromion. According to basic physical principles, the standard friction equation indicates that the greater the pressure applied at the acromion, the greater the friction force will develop between the hook and the acromion. Thus, the friction





**Figure 5.** Comparison of friction traces at the end of the hook between the (a) 0° hook plate and (b) 15° hook plate. Friction traces (indicated by arrows) were observed at the end of the hook after removal of the hook plates from the patients.

between the hook and acromion can stimulate sensory nerve endings in the acromion, which may be one cause of postoperative pain.<sup>23</sup> Friction was observed and confirmed as traces after the hook was removed from the patients about 6 to 12 months postoperatively (Figure 5). As shown in Figure 5, the traces caused by friction were much more obvious with the 0° hook plate (Figure 5(a)) than with the 15° hook plate (Figure 5(b)), suggesting that the 15° hook plate could better reduce the friction than the 0° hook plate, resulting in more efficient reduction of postoperative pain.

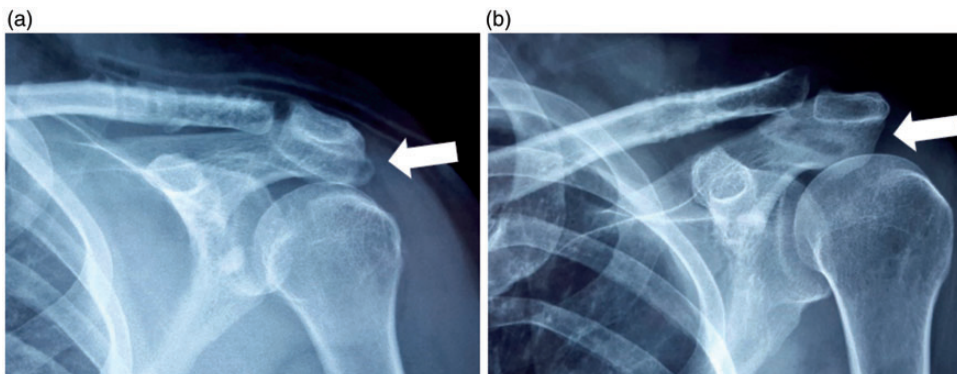
After demonstration that the 15° hook plate has advantages over the regularly used 0° hook plate in shoulder joint models, we then compared the clinical effectiveness of the 15° versus regular 0° hook plate by assessment of the ASES and VASP scores preoperatively and at different time points postoperatively. The ASES scores in the patients treated with the 15° hook plate were significantly higher than those in the patients treated with 0° hook plate at every time point after surgery (Figure 3(a) and Table 2), indicating that patients treated with the 15° hook plate had better postoperative recovery than those treated with the 0° hook plate. Meanwhile, the VASP score in the patients treated with 15° hook plate was significantly lower

than that in the patients treated with 0° hook plate at every time point after surgery (Figure 3(b) and Table 3), indicating that patients treated with the 15° hook plate had less postoperative pain than those treated with the 0° hook plate. Therefore, patients treated with the 15° hook plate were able to more actively perform the postoperative functional exercises because of less postoperative pain, which further helped them to achieve better recovery of shoulder function than patients treated with the 0° hook plate. Furthermore, there were no significant differences in the ASES or VASP scores between the preoperative period and 3 days postoperatively in patients treated with the 0° hook plate (Table 2), suggesting no significant postoperative recovery or reduction of pain during the first 3 days after surgery in those patients. This is probably due to excessive stress in the acromion and excess pressure of the clavicle by the 0° hook plate. In contrast, patients treated with the 15° angle hook plate had significantly lower pressure on the acromion, avoiding excessive compression of the clavicle and facilitating better postoperative recovery and pain relief. This was confirmed by the better ASES and VASP scores 3 days postoperatively than preoperatively ( $p < 0.001$ ) in these patients (Tables 2 and 3).

In the present study, the surgical procedures were consistent in all patients, and all operations were performed by the same group of orthopedic surgeons to avoid procedure bias and outcome bias. Specifically, the hook was closely attached to the surface of the acromion of each patient during the operation to avoid embedding soft tissues between the two structures. Fragmented tissues such as joint hematomas and broken articular discs and cartilage were carefully cleaned and removed to prevent postoperative complications. Previous studies have shown that the hook of a hook plate can cause subacromion injury by collision, possibly resulting in postoperative shoulder pain.<sup>24-27</sup> According to the testing of our model, however, the hook of the hook plate is located at the subacromion approximate to the spine of the scapula; thus, the impact of the hook on joint motion is very limited based on this anatomic relationship. If a collision injury of the subacromion by hook plate were present, some collision traces would be evident underneath the hook after its removal from the patient. However, no obvious collision traces were found below the hook in the patients treated with both types of hook plates in our study, suggesting that the main cause

of postoperative pain induced by hook plates is compression and excessive friction between the hook and acromion, not collision between the hook and subacromion.

In theory, it may be better to use pre-bent hook plates with different hook angles in different patients based on the specific injury type and anatomic relationship in each patient. In the present study, we pre-bent the proximal side of the hook to prevent excessive pressure induced by the hook plate. However, it is difficult to accurately control the specific degree of pre-bending in clinical practice; thus, it is relatively easy to use the pre-bent 15° hook plate. In the present study, the 15° hook plate resulted in better rehabilitation of the shoulder joint and more effective reduction of the postoperative shoulder pain in patients with AC joint dislocation than the more commonly used 0° hook plate. A frequently reported complication of hook plates is induction of bone dissolution and bone resorption in the acromion caused by the long-term friction between the hook and acromion.<sup>3,28,29</sup> Consistent with previous reports,<sup>30,31</sup> we also observed bone dissolution in patients treated with both the 0° and 15° hook plates as shown in Figure 6. On the basis of the 1-year postoperative



**Figure 6.** Comparison of bone dissolution in patients treated with the (a) 0° hook plate and (b) 15° hook plate by postoperative radiographic examination. The results showed the occurrence of bone dissolution (indicated by arrow) in the acromion caused by long-term friction between the hook and acromion.

radiograph findings, the 15° hook plate (Figure 6(b)) caused less bone dissolution than did the 0° hook plate (Figure 6(a)) in certain patients. Although the use of a 15° hook plate provides a better clinical outcome with less bone dissolution compared with a 0° hook plate, we still recommend removal of the hook plate in the early postoperative stage to prevent the probable occurrence of bone dissolution. The ligament damage would have been initially repaired 3 months postoperatively; thus, the hook plate can possibly be removed as early as 6 months postoperatively. We also suggest application of a surface lubricant coating to the top and the tip parts of the hook to reduce the friction between the hook and acromion. This will minimize pain and reduce the incidence of osteolysis.

## Conclusions

In the present study, we compared the clinical outcome of 0° and 15° clavicular hook plates in the treatment of patients with AC joint dislocation. We found that both types of hook plates provided good fixation and reduction, but the 15° hook plate achieved more promising clinical outcomes with better reduction of shoulder pain and improvement of early postoperative recovery than the regularly used 0° hook plate.

## Acknowledgements

We thank Prof. Christopher K. Daniels for providing valuable comments and a critical review of the manuscript.

## Authorship and contributorship

Designed the research: Guanghui Li, Dadi Jin.  
Performed the research: Guanghui Li, Guang Li, Xianfang Shao, Zhijun Liu, Jianhui Duan, Dadi Jin.  
Collected the data: Guanghui Li, Guang Li, Xianfang Shao, Zhijun Liu, Jianhui Duan, Dadi Jin.

Analyzed and interpreted the data: Guanghui Li, Guang Li, Xianfang Shao, Zhijun Liu, Jianhui Duan, Dadi Jin, Tuoan Liu.

Performed the statistical analysis: Guanghui Li, Dadi Jin.

Wrote the manuscript: Guanghui Li, Dadi Jin, Tuoan Liu, Raji Akileh, Shousong Cao.

## Data availability

The datasets generated and/or analyzed during the current study are available from the corresponding author on reasonable request.

## Declaration of conflicting interest

The authors declare that there is no conflict of interest.

## Funding

This research received no specific grant from any funding agency in the public, commercial, or not-for-profit sectors.

## ORCID iD

Tuoan Liu  <http://orcid.org/0000-0001-9000-2736>

## References

1. Chen CH, Dong QR, Zhou RK, et al. Effects of hook plate on shoulder function after treatment of acromioclavicular joint dislocation. *Int J Clin Exp Med* 2014; 7: 2564–2570.
2. Steinbacher G, Sallent A, Seijas R, et al. Clavicular hook plate for grade-III acromioclavicular dislocation. *J Orthop Surg (Hong Kong)* 2014; 22: 329–332. doi: 10.1177/230949901402200312.
3. von Heideken J, Boström Windhamre H, Une-Larsson V, et al. Acute surgical treatment of acromioclavicular dislocation type V with a hook plate: superiority to late reconstruction. *J Shoulder Elbow Surg* 2013; 22: 9–17. doi: 10.1016/j.jse.2012.03.003.
4. Yoon JP, Lee BJ, Nam SJ, et al. Comparison of results between hook plate fixation and ligament reconstruction for acute unstable acromioclavicular joint

- dislocation. *Clin Orthop Surg* 2015; 7: 97–103. doi: 10.4055/cios.2015.7.1.97.
5. Hung LK, Su KC, Lu WH, et al. Biomechanical analysis of clavicle hook plate implantation with different hook angles in the acromioclavicular joint. *Int Orthop* 2017; 41: 1663–1669. doi: 10.1007/s00264-016-3384-z.
  6. Dou Q and Ren X. Clinical therapeutic effects of AO/ASIF clavicle hook plate on distal clavicle fractures and acromioclavicular joint dislocations. *Pak J Med Sci* 2014; 30: 868–871.
  7. Lee CH, Shih CM, Huang KC, et al. Biomechanical analysis of implanted clavicle hook plates with different implant depths and materials in the acromioclavicular joint: a finite element analysis study. *Artif Organs* 2016; 40: 1062–1070. doi: 10.1111/aor.12679.
  8. Arirachakaran A, Boonard M, Piyapittayanun P, et al. Post-operative outcomes and complications of suspensory loop fixation device versus hook plate in acute unstable acromioclavicular joint dislocation: a systematic review and meta-analysis. *J Orthop Traumatol* 2017; 18: 293–304. doi: 10.1007/s10195-017-0451-1.
  9. Modi CS, Beazley J, Zywił MG, et al. Controversies relating to the management of acromioclavicular joint dislocations. *Bone Joint J* 2013; 95-B: 1595–1602. doi: 10.1302/0301-620X.95B12.31802.
  10. Yoon JP, Lee YS, Song GS, et al. Morphological analysis of acromion and hook plate for the fixation of acromioclavicular joint dislocation. *Knee Surg Sports Traumatol Arthrosc* 2017; 25: 980–986. doi: 10.1007/s00167-016-3987-3.
  11. Domos P, Sim F, Dunne M, et al. Current practice in the management of Rockwood type III acromioclavicular joint dislocations- National survey. *J Orthop Surg (Hong Kong)* 2017; 25: 2309499017717868. doi: 10.1177/2309499017717868.
  12. Mah JM. General health status after non-operative versus operative treatment for acute, complete acromio-clavicular joint dislocation: results of a multicenter, randomized clinical trial. *J Orthop Trauma* 2017; 31: 485–490. doi: 10.1097/BOT.0000000000000881.
  13. Cai L, Wang T, Lu D, et al. Comparison of the tight rope technique and clavicular hook plate for the treatment of Rockwood type III acromioclavicular joint dislocation. *J Invest Surg* 2017; 12: 1–8. doi: 10.1080/08941939.2017.1305022.
  14. McKee MD. Operative fixation of chronic acromioclavicular joint dislocation with hook plate and modified ligament transfer. *J Orthop Trauma* 2016; 30(Suppl 2): S7–S8. doi: 10.1097/BOT.0000000000000580.
  15. Natera Cisneros LG and Sarasquete Reiriz J. Acute high-grade acromioclavicular joint injuries: quality of life comparison between patients managed operatively with a hook plate versus patients managed non-operatively. *Eur J Orthop Surg Traumatol* 2017; 27: 341–350. doi: 10.1007/s00590-016-1862-z.
  16. Arirachakaran A, Boonard M, Piyapittayanun P, et al. Comparison of surgical outcomes between fixation with hook plate and loop suspensory fixation for acute unstable acromioclavicular joint dislocation: a systematic review and meta-analysis. *Eur J Orthop Surg Traumatol* 2016; 26: 565–574. doi: 10.1007/s00590-016-1797-4.
  17. Erdle B, Izadpanah K, Jaeger M, et al. Comparative analysis of locking plate versus hook plate osteosynthesis of Neer type IIB lateral clavicle fractures. *Arch Orthop Trauma Surg* 2017; 137: 651–662. doi: 10.1007/s00402-017-2645-7.
  18. Natera-Cisneros L, Sarasquete-Reiriz J, Escola-Benet A, et al. Acute high-grade acromioclavicular joint injuries treatment: arthroscopic non-rigid coracoclavicular fixation provides better quality of life outcomes than hook plate ORIF. *Orthop Traumatol Surg Res* 2016; 102: 31–39. doi: 10.1016/j.otsr.2015.10.007.
  19. Jafary D, Keihan Shokouh H, Najd Mazhar F, et al. Clinical and radiological results of fixation of acromioclavicular joint dislocation by hook plates retained for more than five months. *Trauma Mon* 2014; 19: e13728. doi: 10.5812/traumamon.13728.
  20. Kumar N and Sharma V. Hook plate fixation for acute acromioclavicular dislocations

- without coracoclavicular ligament reconstruction: a functional outcome study in military personnel. *Strategies Trauma Limb Reconstr* 2015; 10: 79–85. doi: 10.1007/s11751-015-0228-0.
21. Nuchtern JV, Sellenschloh K, Bishop N, et al. Biomechanical evaluation of 3 stabilization methods on acromioclavicular joint dislocations. *Am J Sports Med* 2013; 41: 1387–1394. doi: 10.1177/0363546513484892.
  22. Wang Y and Zhang J. Acromioclavicular joint reconstruction by coracoid process transfer augmented with hook plate. *Injury* 2014; 45: 949–954. doi: 10.1016/j.injury.2013.12.013.
  23. Boström Windhamre HA, von Heideken JP, Une-Larsson VE, et al. Surgical treatment of chronic acromioclavicular dislocations: a comparative study of Weaver-Dunn augmented with PDS-braid or hook plate. *J Shoulder Elbow Surg* 2010; 19: 1040–1048. doi: 10.1016/j.jse.2010.02.006.
  24. Cox CL. Hook-plate fixation in patients with acute acromioclavicular joint dislocation improved radiographic but not clinical outcomes compared with nonoperative treatment. *J Bone Joint Surg Am* 2016; 98: 1405. doi: 10.2106/JBJS.16.00582.
  25. Drijfhout van Hooff CC, Haverlag R and Willems WJ. Evaluation of the use of the hook plate in Neer type 2 lateral clavicle fractures and Rockwood types 3–5 acromioclavicular joint dislocations. *Eur J Trauma Emerg surg* 2013; 39: 619–626. doi: 10.1007/s00068-013-0303-5.
  26. Jensen G, Katthagen JC, Alvarado LE, et al. Has the arthroscopically assisted reduction of acute AC joint separations with the double tight-rope technique advantages over the clavicular hook plate fixation? *Knee Surg Sports Traumatol Arthrosc* 2014; 22: 422–430. doi: 10.1007/s00167-012-2270-5.
  27. Lin HY, Wong PK, Ho WP, et al. Clavicular hook plate may induce subacromial shoulder impingement and rotator cuff lesion—dynamic sonographic evaluation. *J Orthop Surg Res* 2014; 9: 6. doi: 10.1186/1749-799X-9-6.
  28. Canadian Orthopaedic Trauma Society. Multicenter randomized clinical trial of nonoperative versus operative treatment of acute acromio-clavicular joint dislocation. *J Orthop Trauma* 2015; 29: 479–487. doi: 10.1097/BOT.0000000000000437.
  29. Good DW, Lui DF, Leonard M, et al. Clavicle hook plate fixation for displaced lateral-third clavicle fractures (Neer type II): a functional outcome study. *J Shoulder Elbow Surg* 2012; 21: 1045–1048. doi: 10.1016/j.jse.2011.07.020.
  30. Chiang CL, Yang SW, Tsai MY, et al. Acromion osteolysis and fracture after hook plate fixation for acromioclavicular joint dislocation: a case report. *J Shoulder Elbow Surg* 2010; 19: e13–e15. doi: 10.1016/j.jse.2009.12.005.
  31. Eschler A, Gradl G, Gierer P, et al. Hook plate fixation for acromioclavicular joint separations restores coracoclavicular distance more accurately than PDS augmentation, however presents with a high rate of acromial osteolysis. *Arch Orthop Trauma Surg* 2012; 132: 33–39. doi: 10.1007/s00402-011-1399-x.