



## Case Report

# Progressive superficial siderosis from Chronic CSF leak as a long-term complication of cervical anterior corpectomy: A case report and review of the literature

Pierce W. McMahon<sup>1</sup>, Joshua Loewenstern<sup>1</sup>, Peter Girgis<sup>2</sup>, Apostolos John Tsiouris<sup>1</sup>, Matthew Fink<sup>2</sup>, Roger Härtl<sup>3</sup>, Gayle Salama<sup>1</sup>

Departments of <sup>1</sup>Radiology, <sup>2</sup>Neurology and <sup>3</sup>Neurosurgery, Weill Cornell Medicine, New York City, New York, United States.

E-mail: \*Pierce W. McMahon - pwm4001@med.cornell.edu; Joshua Loewenstern - jnl9006@nyp.org; Peter Girgis - pmg9008@nyp.org; Apostolos John Tsiouris - apt9001@med.cornell.edu; Matthew Fink - mfink@med.cornell.edu; Roger Härtl - roh9005@med.cornell.edu; Gayle Salama - gkr9002@med.cornell.edu



### \*Corresponding author:

Pierce W. McMahon,  
Department of Radiology, Weill  
Cornell Medicine, New York  
City, New York, United States.

pwm4001@med.cornell.edu

Received : 24 May 2022

Accepted : 19 July 2022

Published : 05 August 2022

### DOI

10.25259/SNI\_493\_2022

### Quick Response Code:



## ABSTRACT

**Background:** Superficial siderosis of the central nervous system (SSCNS) is a rare progressive neurological disorder resulting from chronic subarachnoid hemorrhage and subsequent subpial hemosiderin deposition. A prolonged cerebrospinal fluid (CSF) leak is a known cause of SSCNS. We present a novel case where progressive SSCNS resulted from a chronic CSF leak related to an anterior cervical corpectomy.

**Case Description:** A 73-year-old man presented with gait ataxia and progressive hearing loss. Thirteen years before, he had undergone a combined anterior-posterior cervical decompression for symptomatic ossification of the posterior longitudinal ligament (OPLL). The presenting MR imaging showed extensive superficial siderosis and focal spinal cord herniation at the site of a ventral dural defect at the corpectomy site. A CT myelogram showed extensive CSF leakage into the corpectomy surgical site and a communicating pseudomeningocele in the anterior neck.

**Conclusion:** This is the first reported case of progressive SSCNS as a long-term complication of an anterior cervical corpectomy for OPLL. Clinicians should be aware of SSCNS secondary to a chronic CSF leak in patients with a prior corpectomy.

**Keywords:** Anterior corpectomy, CSF leak, superficial siderosis, Ossified posterior longitudinal ligament, Pseudomeningocele, Spinal cord herniation

## INTRODUCTION

Ossification of the posterior longitudinal ligament (OPLL) is a known cause of myelopathy that may necessitate surgical decompression for spinal cord decompression.<sup>[12,14,15]</sup> Surgery typically occurs through either an anterior or posterior approach. The anterior approach directly decompresses the spinal canal by exposing and then resecting the OPLL, followed by fusion of the affected levels.<sup>[11]</sup> OPLL often affects the adjacent dura, fusing the two structures into one and increasing the chance of an iatrogenic dural defect leading to a cerebrospinal fluid (CSF) leak.<sup>[15,16]</sup> The anterior approach is associated with superior outcomes when the OPLL occupies >50% of

This is an open-access article distributed under the terms of the Creative Commons Attribution-Non Commercial-Share Alike 4.0 License, which allows others to remix, transform, and build upon the work non-commercially, as long as the author is credited and the new creations are licensed under the identical terms.

©2022 Published by Scientific Scholar on behalf of Surgical Neurology International

the spinal canal. The posterior approach involves either laminectomy or laminoplasty. The decompression provided is indirect by enlarging the effective space available for the spinal cord posteriorly. The posterior approach is generally preferred when more than 2–3 cervical levels are involved because of the technical ease and reduced complication rate compared to the anterior approach. However, when the OPLL occupies >50% of the spinal canal and the spinal canal stenosis involves more than three levels, patients may benefit from the combination of an anterior and posterior decompression.<sup>[1]</sup>

The incidence of dural tears after anterior decompression varies from 0% to 3%; however, in studies specifically reporting on anterior corpectomy with an OPLL, the incidence of a dural tear is as high as 32%.<sup>[9]</sup> Hannallah *et al.* report the presence of OPLL increases the likelihood of a CSF leak after anterior corpectomy by 13.7 fold.<sup>[7]</sup> Perioperative CSF leaks have been managed by a variety of techniques, such as repair with gelatin sponge, dural substitutes, fibrin glue, lumbar drain, lumboperitoneal and wound-peritoneal shunts, ventriculostomy, laser techniques, and microdural stapling.<sup>[5,9-11]</sup> In a retrospective study of CSF leaks in corpectomy patients for OPLL, Joseph *et al.* found a 6.3% CSF leak rate using an operating microscope to reduce the risk of a dural tear. To repair the dural tears that occurred, an onlay graft of muscle and fascia harvested from a bone graft donor site was applied during the surgery and a lumbar drain was placed postoperatively. None of the 144 patients in the study required a repeat operation to repair the CSF leak or developed any of the typical CSF leak related complications such as pseudomeningocele or meningitis.<sup>[9]</sup>

Superficial siderosis of the central nervous system (SSCNS) is an uncommon progressive neurological disorder that is the consequence of hemosiderin deposition in the subpial layer due to recurrent chronic subarachnoid hemorrhage. SSCNS typically presents with gait ataxia, hearing loss, and other cranial neuropathies. The cause of bleeding remains unknown in many cases, although dural tears are one of the most common etiologies.<sup>[13]</sup> Takai and Taniguchi demonstrate that dural tears can induce micro-bleeding from epidural veins of the internal vertebral venous plexus. CSF leak pulsations through the dural defect continuously wash the damaged veins and prevent proper clot formation, leading to chronic microhemorrhage, hemosiderin deposition, and the eventual onset of SSCNS symptoms.<sup>[20]</sup>

In addition to SSCNS, spinal cord herniation (SCH) is another problematic long-term postoperative complication of CSF leak following an anterior corpectomy that has been scarcely described in the literature.<sup>[6,12,15]</sup> Guppy and Silverthorn hypothesize that the CSF leak creates a pressure gradient across the dural defect, particularly with the exterior retropharyngeal space in the anterior cervical region of

the lower pressure relative to the intrathecal space. As the hydrostatic pressure of the CSF at the dural defect builds up, it can create a CSF fistula at the dural defect. As CSF flows through the fistula, a pressure gradient across the dura creates a “vortex,” which pulls the spinal cord into the fistula like a drain plug. If left untreated long enough, the spinal cord can herniate through the dura and cause additional neurological symptoms.<sup>[6]</sup>

In addition, in rare occasions, iatrogenic cervical pseudomeningoceles may occur in the postoperative period after anterior cervical procedures, especially anterior corpectomy, as a consequence of an inadvertent tear of the dura mater and resultant CSF leakage into the anterior compartment of the neck.<sup>[17]</sup> Bertalnavy and Eggert reported the first case of cervical pseudomeningocele following anterior corpectomy, with several other cases subsequently reported.<sup>[2,4,8,19]</sup> In one case, a chronic CSF leak was identified over the course of the next months following surgery, but none have been reported in the literature to occur in the subsequent years postoperatively.<sup>[17]</sup>

In this report, we discuss the case of a patient who developed classic neurologic symptoms of SSCNS years after an anterior corpectomy for symptomatic OPLL. Further workup of the supratentorial and infratentorial superficial siderosis, which was identified on brain MRI imaging, led to the discovery of the surgical site CSF leak, anterior neck pseudomeningocele, and mild SCH.

## CASE REPORT

### Presenting history and examination

A 73-year-old man who reported chronic gait impairment and progressive hearing loss presented with worsening balance and weakness in his arms and legs over the past 2 years. Neurologic physical examination demonstrated that the range of motion of his neck was severely impaired on extension and lateral rotation. He had hearing loss, motor weakness, abnormal coordination and gait, and poor balance. He had also noted loss of sense of smell and diminished sense of taste. He had difficulty walking on his toes and heels without assistance. Upper extremity weakness was noted especially at the triceps, bilaterally, with distal muscles relatively normal, but poor fine motor movements. Reflexes were diminished at the biceps and brachioradialis muscles and absent at the triceps. He had decreased perception of pin prick and light touch in fingers of both hands. Of note, he denied current neck or back pain.

### Surgical history

His initial symptoms of gait ataxia began in 2008, when he was diagnosed with cervical spinal stenosis due to

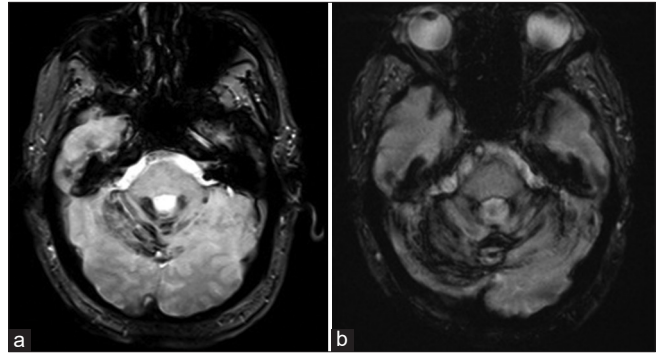
marginal disc osteophytosis and OPLL. He subsequently underwent a combined anterior-posterior surgery at an outside medical center including anterior decompression of the spinal cord with corpectomy, removal of bone spurs, and placement of a vertebral titanium mesh cage. In the same operation, he also had posterior decompression with bilateral laminectomy from C2 to C4. He suffered extensive postoperative complications, including a lower extremity deep vein thrombosis, pneumothorax, and residual weakness in his arms and legs. He was hospitalized for several weeks after his operation, and eventually made a full recovery and went home with improved neurological symptoms compared to before the operation.

### Imaging

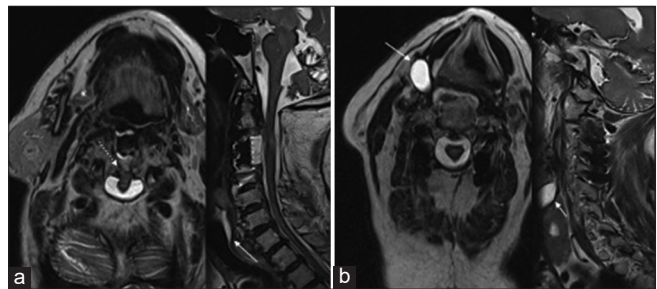
MRI demonstrated extensive superficial siderosis over the cerebral hemispheres, cerebellar hemispheres, and the spinal cord extending from the foramen magnum down into the thoracic spinal cord. Prior imaging at an outside medical center did reveal evidence of mild superficial siderosis 5 years postoperatively [Figure 1], with worsening of the superficial siderosis seen approximately 13 years after the initial surgery (present day). The cervical spine imaging shows significant arachnoiditis at the level of the surgery with adherence of the dura to the surgical corpectomy site with marked distortion of the spinal cord [Figure 2]. There is focal partial SCH at the site of the dural defect. The same MR shows a fluid collection anterolateral to the right of the surgical site in the soft tissue of the neck, originally diagnosed as a thyroid nodule on an outside hospital report [Figure 2].

During evaluation at our medical center, the patient underwent a total spine CT myelogram due to concern for a CSF leak which may be contributing to the progressive SSCNS findings [Figure 3]. Pre-injection CT imaging of the lumbar spine was performed and the L3-L4 interspace was chosen as an appropriate entry point. Under local anesthesia, a 20-gauge standard 6-inch Quincke spinal needle (Becton Dickinson, Franklin Lakes, NJ, USA) was used to access the subarachnoid space under intermittent CT guidance. Initially, 0.5 mL of Omnipaque 300 (GE Healthcare, Marlborough, MA, USA) was injected with confirmation of intrathecal contrast by intraprocedural CT. After confirmation, an additional 9.5 mL of Omnipaque 300 were injected intrathecally. The patient was then moved to a stretcher and placed in Trendelenburg position with intermittent full-body rotations for intrathecal contrast mixing. Final patient positioning was prone to provoke an anterior leak. After approximately 20 min, the patient was placed back on the scanner table for conventional CT imaging in supine positioning.

At the C3 level, there was a large ventral dural defect with extrathecal contrast completely opacifying the corpectomy surgical site [Figure 3]. At the C2-C3 level, the cord was



**Figure 1:** Representative axial MR GRE sequences from 5 years after surgery (a) and 13 years after surgery (b) shows low intensity signal in the superior cerebellum, indicative of hemosiderin deposition compatible with superficial siderosis. The superficial siderosis is expanding in area from 5 years to 13 years after initial anterior corpectomy and fusion.



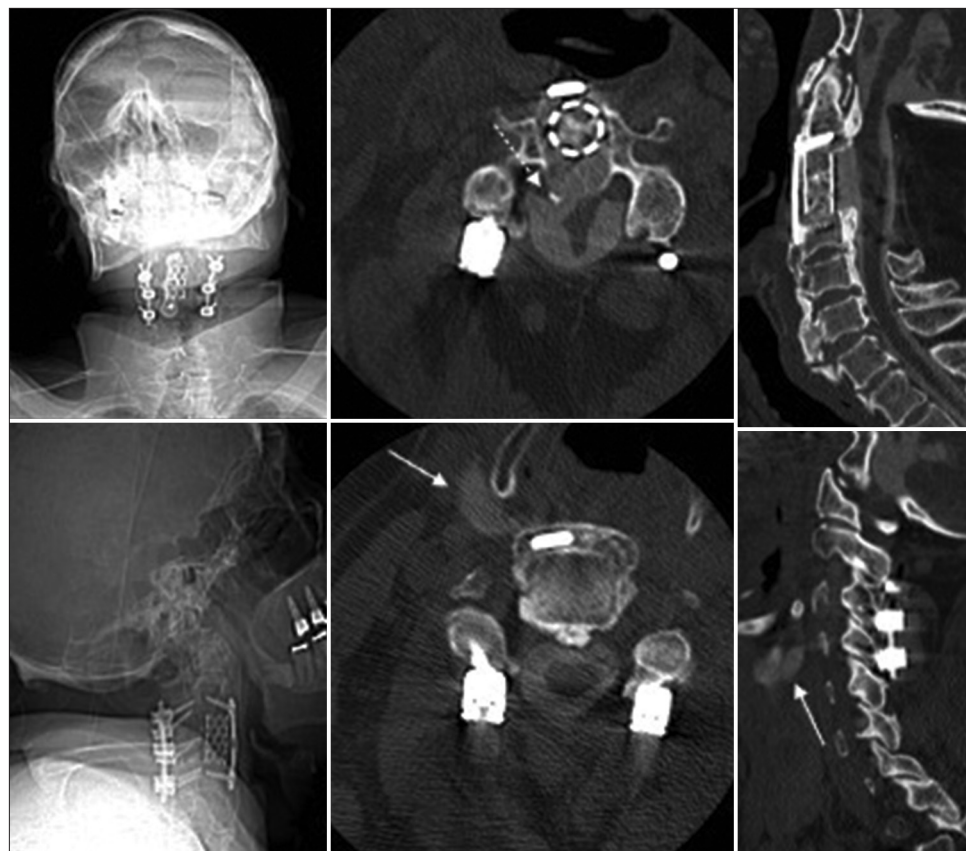**Figure 2:** (a) Representative axial (left) and sagittal (right) T2-weighted fast spin echo images from 13 years after surgery demonstrating a ventral dural defect (dotted-line arrow) at approximately level C2 and CSF extending from the corpectomy site around the titanium mesh cage (solid-line arrow). (b) Additional axial (left) and sagittal (right) slices demonstrating a fluid collection (solid-line arrows) in the right anterolateral soft tissues of the neck extending from corpectomy site at approximately level C4.

anteriorly displaced and markedly deformed, appearing inseparable from the OPLL as well as tethered to the partially intact ventral dura at the mid C3 level, suspicious for a dural defect with borderline SCH [Figure 3]. In the prevertebral soft tissues, at the right anterior C4 level, there was a tract of extrathecal contrast extending into the right neck from C4 through C5-C6 levels, located along the right lateral aspect of the thyroid cartilage [Figure 3].

### Clinical course

Shortly after CT myelogram was performed, the patient had a mechanical fall as a result of his progressive impaired balance and weakness, sustaining a hip fracture requiring repair. Given his age, clinical condition, and comorbidities, the likelihood of life-threatening complications was deemed prohibitive to justify a revision and repair operation at the corpectomy site.





**Figure 3:** Coronal (upper left) and sagittal (lower left) scout images of the intact anterior corpectomy with titanium mesh cage, anterior plate and screw construct from C2-C4, and posterior laminectomy and fusion with transpedicular screws and interconnecting rods from C2-C4. Axial (upper middle) and sagittal (upper right) post-injection CT myelogram images demonstrating a ventral dural defect (dotted-line arrow) at level C2 with borderline spinal cord herniation and CSF throughout the corpectomy site and within the titanium mesh cage. Axial (lower middle) and sagittal (lower right) postinjection CT myelogram images showing a fluid collection in the right anterolateral soft tissues of the neck extending from the corpectomy site (solid-line arrows) at level C4.

## DISCUSSION

Anterior corpectomy for OPLL related spinal canal stenosis is associated with an increased risk of creating a ventral dural tear because of adhesion between the OPLL and dura.<sup>[14]</sup> While a CSF leak is a well-known complication in the intraoperative and perioperative periods, long-term CSF leak as a postoperative complication of anterior cervical corpectomy should be considered as a cause of chronic progressive neurologic symptoms, especially when manifested as worsening SSCNS on imaging. A small dural tear, possibly occurring during resection of this patient's OPLL or in the postoperative period, allowed for chronic CSF leakage into the corpectomy site, and eventually into the anterior neck. The chronic CSF leak also induced recurrent chronic microhemorrhage, leading to the deposition of hemosiderin and eventual development of SSCNS symptoms.

Hemosiderin deposition from chronic subarachnoid hemorrhage in patients with SSCNS deposits in the subpial layers of the brain and spine, most typically superficially along the cerebellum, brainstem, and spinal cord; this results in the symptomology seen in this patient including gait ataxia, progressive loss of hearing and smell, and bilateral extremity weakness.<sup>[3]</sup> Three theories have been proposed for the cause of bleeding in patients with SSCNS associated with a dural defects. First, brain sagging due to intracranial hypotension may lead to chronic bleeding from bridging veins on the surface of the cerebellum.<sup>[18]</sup> The second theory is that the bleeding source may be fragile vessels around the dural defect.<sup>[13,18,22]</sup> Bremilla *et al.* posit a third theory, that osteophyte protrusion into the subarachnoid space can introduce bleeding through a ruptured perforating artery.<sup>[3]</sup> Takai and Taniguchi provide evidence that the second theory is the most likely cause of CSF leak induced bleeding leading to SSCNS.<sup>[20]</sup> Although there is no one definitive treatment

for SSCNS, therapies have focused on iron chelation, surgery for specific etiologies such as dural defects, or symptom management.<sup>[13]</sup> For example, Wipplinger *et al.* demonstrated improvement of SSCNS after surgical repair of identified CSF leaks.<sup>[21]</sup>

SCH through an iatrogenic dural defect following anterior corpectomy with postoperative CSF leak is another complication that can produce neurological symptoms.<sup>[6,12,15]</sup> Guppy and Silverthorn hypothesize that CSF leakage through the dural defect can create a powerful enough pressure gradient to tug the spinal cord into and potentially through the dural defect, resulting in neurological symptoms.<sup>[6]</sup> This patient suffered a borderline SCH, with the spinal cord plugging the dural defect. Despite the associated spinal cord distortion, the neurological symptoms are most consistent with the SSCNS.

In rare occasions, iatrogenic cervical pseudomeningoceles may occur after anterior corpectomy procedures, likely as a consequence of an inadvertent tear of the dura mater with breach into the subarachnoid space or a lack of closure of the dural tear with resultant CSF leakage into the anterior compartment of the neck. The dural defects permit CSF egress to the surrounding tissues through a fistula when the CSF pulse pressure exceeds the interstitial pressure of the surrounding tissue, therefore, leading to pseudomeningocele formation, typically in the anterior compartment of the neck.<sup>[17]</sup> This patient's dural defect at the corpectomy site created a passageway for CSF to leak out of the subarachnoid space into the corpectomy site and the soft tissue of the anterior neck. One additional case has been reported by Rahimizadeh *et al.* in which the leakage was also chronic and persisted over a number of months.<sup>[17]</sup>

Typically, SCH and CSF leak is repaired through anterior approach by removing the titanium cage and associated scarring and adhesions and then repairing the dural tear with replacement of the herniated spinal cord.<sup>[6]</sup> A new cage is positioned in the corpectomy site with additional plate and screw construct, and a lumbar drain is placed to allow for appropriate recovery. However, given the age, clinical condition, and comorbidities, the likelihood of life-threatening complications from such extensive corrective surgery was deemed prohibitive in this patient.

## CONCLUSION

This case highlights the importance of identifying a CSF leak as a long-term postoperative complication of an anterior corpectomy for OPLL. Clinicians should consider a CSF leak in their differential when patients present with neurological symptoms and imaging findings consistent with SSCNS following an anterior corpectomy, even if the surgery was remote. Therefore, patients can be immediately referred

to myelography, resulting in earlier CSF leak diagnosis, which can lead to targeted intervention and symptom amelioration.<sup>[21]</sup>

## Declaration of patient consent

Patient's consent not required as patient's identity is not disclosed or compromised.

## Financial support and sponsorship

Nil.

## Conflicts of interest

There are no conflicts of interest.

## REFERENCES

1. An HS, Al-Shihabi L, Kurd M. Surgical treatment for ossification of the posterior longitudinal ligament in the cervical spine. *J Am Acad Orthop Surg* 2014;22:420-9.
2. Bertalanffy H, Eggert HR. Complications of anterior cervical discectomy without fusion in 450 consecutive patients. *Acta Neurochir (Wien)* 1989;99:41-50.
3. Brembilla C, Lanterna LA, Bonito V, Gardinetti M, Dorelli G, Rampini AD, *et al.* Updating superficial siderosis of the central nervous system: Bleeding of a dorsal osteophyte into the subarachnoid space from a perforating artery. *J Neurosurg Spine* 2018;30:106-10.
4. Fountas KN, Kapsalaki EZ, Johnston KW. Cerebrospinal fluid fistula secondary to dural tear in anterior cervical discectomy and fusion: Case report. *Spine (Phila Pa 1976)* 2005;30:E277-80.
5. Foyt D, Johnson JP, Kirsch AJ, Bruce JN, Wazen JJ. Dural closure with laser tissue welding. *Otolaryngol Head Neck Surg* 1996;115:513-8.
6. Guppy KH, Silverthorn JW. Spinal cord herniation after cervical corpectomy with cerebrospinal fluid leak: Case report and review of the literature. *World Neurosurg* 2017;100:711.e7-711.e12.
7. Hannallah D, Lee J, Khan M, Donaldson WF, Kang JD. Cerebrospinal fluid leaks following cervical spine surgery. *J Bone Joint Surg Am* 2008;90:1101-5.
8. Horowitz SW, Azar-Kia B, Fine M. Postoperative cervical pseudomeningocele. *AJNR Am J Neuroradiol* 1990;11:784.
9. Joseph V, Kumar GS, Rajshekhar V. Cerebrospinal fluid leak during cervical corpectomy for ossified posterior longitudinal ligament: Incidence, management, and outcome. *Spine (Phila Pa 1976)* 2009;34:491-4.
10. Kala M. Cerebrospinal fluid pseudocyst after anterior stabilization for cervical spine injury treated by ventricular drainage: Case report. *Surg Neurol* 1996;45:293-5.
11. Kitchel SH, Eismont FJ, Green BA. Closed subarachnoid drainage for management of cerebrospinal fluid leakage after an operation on the spine. *J Bone Joint Surg Am* 1989;71:984-7.
12. Kizilay Z, Yilmaz A, Ismailoglu O, Coskun ME. Anterior spinal cord herniation after multilevel anterior cervical corpectomy:

- A case report. *Neurol Neurochir Pol* 2016;50:190-4.
13. Kumar N. Neuroimaging in superficial siderosis: An in-depth look. *AJNR Am J Neuroradiol* 2010;31:5-14.
  14. Mazur M, Jost GF, Schmidt MH, Bisson EF. Management of cerebrospinal fluid leaks after anterior decompression for ossification of the posterior longitudinal ligament: A review of the literature. *Neurosurg Focus* 2011;30:E13.
  15. Min JH, Jung BJ, Jang JS, Kim SK, Jung DJ, Lee SH. Spinal cord herniation after multilevel anterior cervical corpectomy and fusion for ossification of the posterior longitudinal ligament of the cervical spine. *J Neurosurg Spine* 2009;10:240-3.
  16. Nakase H, Park YS, Kimura H, Sakaki T, Morimoto T. Complications and long-term follow-up results in titanium mesh cage reconstruction after cervical corpectomy. *J Spinal Disord Tech* 2006;19:353-7.
  17. Rahimizadeh A, Soufiani H, Rahimizadeh S. Remote cervical pseudomeningocele following anterior cervical corpectomy and fusion: report of a case and review of the literature. *Int J Spine Surg* 2016;10:36.
  18. Schievink WI, Maya MM, Nuño M. Chronic cerebellar hemorrhage in spontaneous intracranial hypotension: Association with ventral spinal cerebrospinal fluid leaks: Clinical article. *J Neurosurg Spine* 2011;15:433-40.
  19. Smith MD, Bolesta MJ, Leventhal M, Bohlman HH. Postoperative cerebrospinal-fluid fistula associated with erosion of the dura. Findings after anterior resection of ossification of the posterior longitudinal ligament in the cervical spine. *J Bone Joint Surg Am* 1992;74:270-7.
  20. Takai K, Taniguchi M. Superficial siderosis of the central nervous system associated with ventral dural defects: Bleeding from the epidural venous plexus. *J Neurol* 2021;268:1491-4.
  21. Wiplinger C, Simian A, Hernandez RN, Navarro-Ramirez R, Kim E, Kirnaz S, *et al.* Superficial siderosis of central nervous system as primary clinical manifestation secondary to intradural thoracic disk herniation. *World Neurosurg* 2018;119:40-4.
  22. Yokosuka J, Takai K, Komori T, Taniguchi M. Superficial siderosis: Bleeding from the bone marrow after laminectomy for spinal tumor removal. *J Neurosurg Spine* 2014;21:905-8.

**How to cite this article:** McMahon PW, Loewenstern J, Girgis P, Tsiouris AJ, Fink M, Härtl R, *et al.* Progressive superficial siderosis from Chronic CSF leak as a long-term complication of cervical anterior corpectomy: A case report and review of the literature. *Surg Neurol Int* 2022;13:341.