



Case report

First report of spondylodiscitis caused by *Bacillus circulans* in an immunocompetent patient: Clinical case and review of the literature



Alessandro Russo^{a,*,1}, Umberto Tarantino^b, Gabriella d'Ettorre^a, Carlo Della Rocca^c, Giancarlo Ceccarelli^a, Elena Gasbarra^b, Mario Venditti^a, Riccardo Iundusi^{b,1}

^a Policlinico "Umberto I", Department of Public Health and Infectious Diseases, "Sapienza" University of Rome, Italy

^b Department of Orthopaedics and Traumatology, University of Rome "Tor Vergata", "Policlinico Tor Vergata" Foundation, Rome, Italy

^c Department of Medico-Surgical Sciences and Biotechnology, Polo Pontino, "Sapienza" University of Rome, Italy

ARTICLE INFO

Article history:

Received 8 December 2020

Received in revised form 22 January 2021

Accepted 22 January 2021

Keywords:

Bacillus circulans

Spondylodiscitis

Biopsy

First case

ABSTRACT

Bacillus circulans is mainly considered an opportunistic pathogen in immunocompromised patients. However, many different infections have been described in the literature: bacteremia, abscesses, meningitis, endophthalmitis, and wound infections.

We observed a spondylodiscitis caused by *Bacillus circulans* in an immunocompetent patient. To date, this is the first case reported in literature. Vertebral osteomyelitis represents for clinicians a challenging infection to manage and treat, because of its insidious and indolent course. The diagnosis is frequently difficult and can often be delayed for several months and initially be misdiagnosed and mismanaged. For this reason, the clinical case was described and all published cases of infection caused by *Bacillus circulans* were reviewed.

© 2021 The Author(s). Published by Elsevier Ltd. This is an open access article under the CC BY license (<http://creativecommons.org/licenses/by/4.0/>).

Introduction

Bacillus circulans is a gram-positive, rod-shaped organism. It is motile via peritrichous flagella and produces endospores. *Bacillus circulans* is found in soil, sewage, food, and infant bile. This bacterium is also isolated from gut of bee larvae [1].

In the literature, few cases of infection caused by *Bacillus circulans* are described. It is mainly considered as an opportunistic pathogen in immunocompromised patients. However, many different infections have been reported: bacteremia, abscesses, meningitis, endophthalmitis, and wound infections.

Recently, we observed a spondylodiscitis caused by *Bacillus circulans* in an immunocompetent patient. To date, this is the first case reported in literature. For this reason, we described the clinical case and reviewed all published cases of infection caused by *Bacillus circulans*.

Case report

A 65-year-old Caucasian man with a history of hypertension, was evaluated in February 2020 for prolonged lower back pain. Before the evaluation, the patient reported a history of low-grade fever for 1 month associated with severe diarrhea for 2 weeks in the previous 2 months. At the visit, blood exams showed a C-reactive protein (CRP) of 15 mg/l (normal value <5.0). He underwent a lumbar spine magnetic resonance imaging (MRI) that highlighted a suspected spondylodiscitis at L5-S1. Empirical antibiotic therapy with amoxicillin/clavulanate plus minocycline was started after percutaneous bone biopsy, without any improvement of symptoms and reduction of CRP value. After biopsy, blood cultures were collected. All other possible etiologies of spondylodiscitis were excluded (i.e., *Mycobacterium tuberculosis*, *Brucella* spp). A transthoracic echocardiography was performed, excluding the presence of endocarditis. Bone culture resulted sterile and patient was treated for 6 weeks with the same antibiotic regimen.

On the third month, clinical symptoms did not improve. Worsening lower back pain and a repeat increment of CRP required a new infectious diseases consultation. A new lumbar spine MRI was performed, showing the persistence of heterogeneous lesions in L5 and S1 with increased signal in T2-weighted (Fig. 1-b,e), STIR-weighted images (Fig. 1-c), hypo-signal in T1-weighted images (Fig. 1-a,d). The changes were registered at L5 and S1 vertebral

* Corresponding author at: Department of Public Health and Infectious Diseases, "Sapienza" University of Rome, P.le Aldo Moro 5, 00185, Rome, Italy.

E-mail address: a.russo@policlinicoumberto1.it (A. Russo).

¹ These authors contributed equally to the manuscript

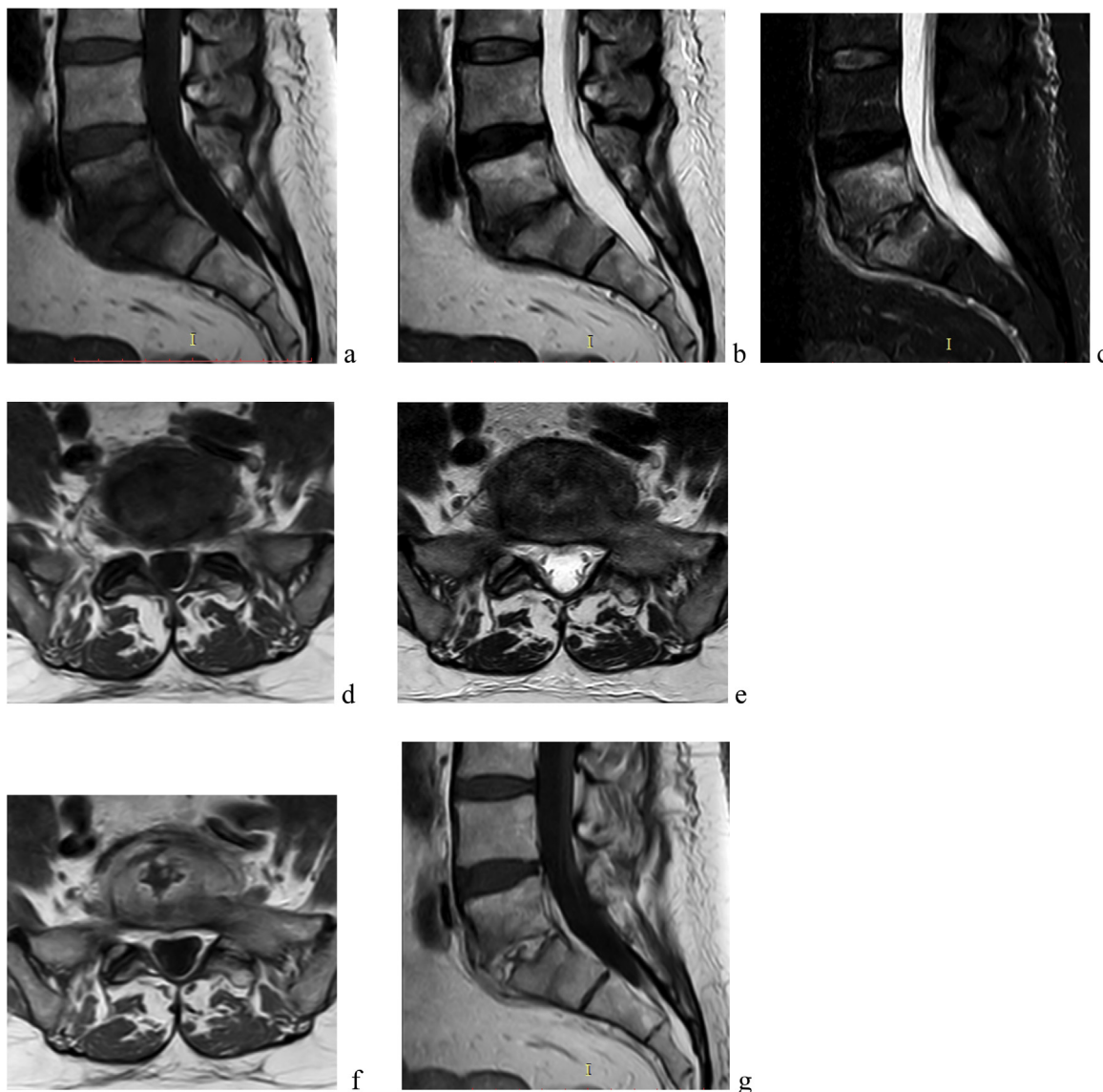


Fig. 1. Lumbar spine MRI at time of *Bacillus circulans* isolation.

bodies as bone edema and L5-S1 intervertebral disc as increased water content. After contrast administration, the images were highly suggestive for spondylodiscitis L5-S1 (Fig. 1-f,g). No findings of inflammatory purulent process of the iliopsoas muscles and/or paraspinal or subdural/epidural phlegmon or abscess were detected.

Considering the clinical, radiological and laboratoristic findings, it was decided to perform another vertebral and disc biopsy. The patient was positioned in the prone position on the radiological table with the spine extended to increase the disc space in L5-S1. Two small skin incisions were made: one access for both L5 and S1 pedicles and the other, more lateral, for L5-S1 trans-foraminal disc

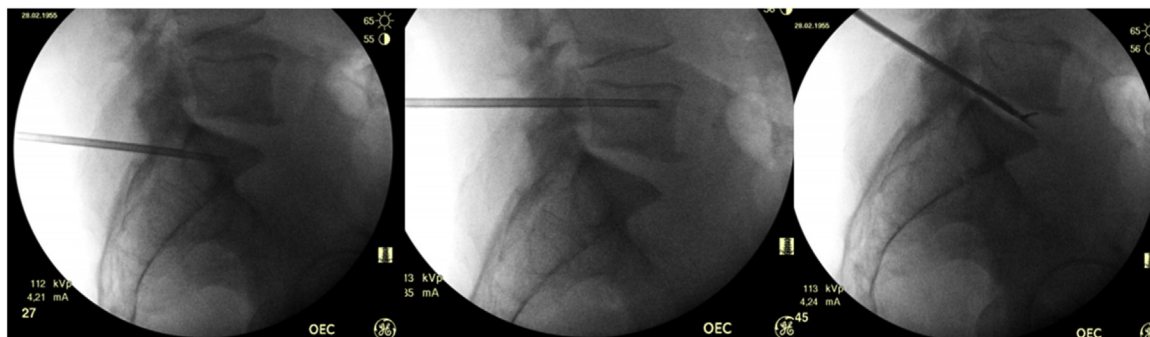


Fig. 2. Intra-operative fluoroscopy of bone and disc biopsy.

approach. Unilateral transpedicular approach was performed with a 13-gauge bone biopsy needle under fluoroscopical guidance (OEC Brivo Plus, GE Healthcare, USA). The needle was introduced first into L5 body through the left pedicle and bone biopsy was performed; another sterile needle was introduced into S1 body always through the left pedicle and a bone biopsy was obtained. At last, transforaminal L5-S1 disc biopsy was performed using percutaneous endoscopic forceps through an 11-gauge working cannula on the left side (Fig. 2). No intra- or post-procedure complications occurred. Left approaches were chosen because of previous L5 at the right side transpeduncular biopsy 3 months before, that resulted negative. The duration of the whole procedure was about 70 min. Patient was discharged the day after.

Cultures of bone and disc showed the growth of *Bacillus circulans*. The organism was identified using MALDI-TOF mass spectrometry (MS) (Bruker Daltonics) and the Vitek 2 automated system (bioMérieux, Marcy l'Etoile, France) for antimicrobial susceptibility testing. Minimum inhibitory concentrations (MICs) were established according to the European Committee on Antimicrobial Susceptibility Testing (EUCAST) breakpoints. The strain showed susceptibility to erythromycin, vancomycin, chloramphenicol, gentamicin and levofloxacin. It showed resistance to penicillin, clindamycin, tetracycline, cefazolin and cefotaxime.

After 2-week treatment with intravenous teicoplanin, the patient completed 4 weeks of oral levofloxacin, 750 mg once daily. At the end of therapy, the CRP value normalized with a complete resolution of clinical symptoms. A ¹⁸F-Fluorodeoxyglucose positron emission tomography/computed tomography (FDG-PET/CT), after 1 month, resulted negative.

Discussion and review of literature

To our knowledge, this is the first case described in the literature of vertebral osteomyelitis (VO) caused by *Bacillus circulans*.

Bacillus circulans is considered as an opportunistic pathogen [1]; in the described cases it was also recognized as the etiology of endocarditis, abscesses, endophthalmitis, and meningitis in humans as reported in Table 1. Moreover, a case of sepsis of unknown origin in an immunocompromised patient was described in 2011, which later led to patients' death. Finally, it was also associated with wound infection in 1985. In the literature there are reported 12 cases of documented infection caused by *Bacillus circulans* [2–13], and 3 cases in which *Bacillus circulans* was considered a possible etiology of infection [14].

Of importance, *Bacillus* spp are rarely implicated in infections and are frequently isolated as a culture contaminant. However, spores are found ubiquitously including in the hospital environment. The production of toxins and tissue invasion contribute to a range of diseases. Of interest, the spectrum of infections and susceptibility to antibiotics result similar to *Bacillus cereus* [1]. For this reason, a careful clinical evaluation is crucial to assess the significance of the isolation of a *Bacillus* organism from cultures. Clinical infections caused by *Bacillus* spp can mainly be categorized into gastrointestinal and non-gastrointestinal diseases; the latter are usually the etiology of local or systemic infections [1]. Although *Bacillus* spp. have not been recognized as major human pathogens, with recent advances in medical technology and an increased number of immunosuppressed patients they have been increasingly recognized as opportunistic pathogens especially in the

Table 1
Patients with *Bacillus circulans* infections reported in the literature.

| First Author, year | Age, sex | Underlying conditions | Type of infection | Complications | Therapy | Outcome |
|--------------------|------------------|---|---|---|--|-------------|
| Boyette, 1952 | 5 days, male | – | Meningitis | Septic shock | Penicillin | Death |
| Logan, 1985 | 78 years, female | Ovarian carcinoma | Surgical wound infection | – | Cotrimoxazole | Cure |
| Roncoroni, 1985 | N/A | N/A | Cerebrospinal fluid ventriculo-atrial shunt infection | <i>Bacillus larvae</i> infection | Cefotaxime, cotrimoxazole and rifampicin | Improvement |
| Banerjee, 1988 | N/A | N/A (acute leukemia and metastatic breast cancer) | Suspected catheter-related bacteremia | N/A | N/A | N/A |
| Banerjee, 1988 | N/A | N/A (acute leukemia and metastatic breast cancer) | Suspected catheter-related bacteremia | N/A | N/A | N/A |
| Banerjee, 1988 | N/A | N/A (acute leukemia and metastatic breast cancer) | Suspected catheter-related bacteremia | N/A | N/A | N/A |
| Wilde, 1988 | N/A | N/A | Early prosthetic knee infection (1 month) | – | Tobramycin/Gentamicin (3 weeks) | Cure |
| Gatermann, 1991 | 58 years, male | Alcohol abuse | Native aortic valve endocarditis | Heart failure, aortic valve replacement | Penicillin G + tobramycin | Cure |
| Goudswaard, 1995 | 48 years, male | Human bite wound | Proximal interphalangeal joint | – | Clindamycin | Cure |
| Castagnola, 1997 | Unknow, children | Neuroblastoma | Catheter-related bacteraemia | – | – | Cure |
| Krause, 1999 | 56 years, Female | Prosthetic valve | Late endocarditis (15 months) | – | Teicoplanin + gentamicin (1 week) followed by trimethoprim + ciprofloxacin (6 weeks) | Cure |
| Fraco, 2001 | 80 years, female | Cataract surgery | Endophthalmitis | Recurrent uveitis | Intravitreal vancomycin and gentamicin | Improvement |
| Berry, 2004 | 62 years, male | Continuous ambulatory peritoneal dialysis, diabetes | Peritonitis | – | Intraperitoneal vancomycin + and gentamicin | Cure |
| Alebouyeh, 2011 | 62 years, male | End- stage renal disease | Bacteremia | Septic shock | Metronidazole and piperacillin-tazobactam | Death |
| Sanyal, 2015 | 60 years, male | Malnutrition | Cellulitis | – | Imipenem | Cure |
| Russo, 2020 | 65 years, male | Hypertension | Lumbar vertebral column | – | Moxifloxacin | Cure |

Legend. N/A: not available.

hospitalized patient. Our patient reported a severe diarrhea for 2 weeks in the previous 2 months before diagnosis of spondylodiscitis. Probably, gastrointestinal inflammation with translocation of *Bacillus circulans* was favored to be the source of the lumbar osteomyelitis.

In the literature, in immunocompetent patients were described few cases of acute and chronic osteomyelitis caused by *Bacillus cereus*, the most important pathogen for humans among *Bacillus* spp. Interestingly, Fritzell and coworkers reported an experience about the detection of bacterial DNA in painful degenerated spinal discs. This in turn may be in patients without signs of clinical infection. One patient with disc hernia harbored DNA homologous to *Bacillus cereus*, and the authors concluded that 16S rRNA PCR can be a useful tool in search of bacterial DNA in degenerated discs, which in turn may be indicative of low-grade infection, manifesting itself only as pain rather than as clinical infection [15].

In conclusion, this clinical case represents a step toward a better knowledge of *Bacillus* spp, including *Bacillus circulans* and its related infections. As reported in the literature, *Bacillus* spp may be associated with indolent and/or chronic infections, also involving bone and causing osteomyelitis. Most cases of *Bacillus circulans* infection are associated with hospitalization in immunodeficient patients as reported in Table 1; however, we reported here a first case observed in immunocompetent patients from the community using a high-standard quality methodology for bone and disc biopsy.

Author statement

On behalf of all authors, I declare no conflict of interest for the manuscript "First report of spondylodiscitis caused by *Bacillus circulans* in an immunocompetent patient: clinical case and review of the literature".

Funding

No funding.

Consent

Consent: Written informed consent was obtained from the patient for publication of this case report and accompanying images. A copy of the written consent is available for review by the Editor-in- Chief of this journal on request

Ethical approval

None.

Author contribution

Please specify the contribution of each author to the paper, e.g. study design, data collections, data analysis, writing, others, who have contributed in other ways should be listed as contributors. Alessandro Russo and Riccardo Iundusi collected data and wrote the paper; Umberto Tarantino, Gabriella d'Ettoire, Carlo Della Rocca, Giancarlo Ceccarelli, Elena Gasbarra, Mario Venditti wrote and revised the paper.

Declaration of Competing Interest

The authors report no declarations of interest.

References

- [1] Drobniowski FA. *Bacillus cereus* and related species. Clin Microbiol Rev 1993;6:324–38.
- [2] Boyett DP, Rights FL. Heretofore undescribed aerobic spore forming bacillus in child with meningitis. J Am Med Assoc 1952;148:1223–4.
- [3] Castagnola E, Conte M, Venzano P, Garaventa A, Viscoli C, Barretta MA, et al. Broviac catheter-related bacteraemias due to unusual pathogens in children with cancer: case reports with literature review. J Infect 1997;34:215–8.
- [4] Krause A, Gould FK, Forty J. Prosthetic heart valve endocarditis caused by *Bacillus circulans*. J Infect 1999;39:160–2.
- [5] Berry N, Hassan I, Majumdar S, Vardhan A, McEwen A, Gokal R. *Bacillus circulans* peritonitis in a patient treated with CAPD. Perit Dial Int 2004;24:488–9.
- [6] Sanyal SK, Karmaker M, Sultana M, Hossain MA. Association of *Bacillus circulans* with non-diabetic foot infection in Bangladeshi patient. Indian J Med Microbiol 2015;33:606–8.
- [7] Gatermann S, Mitusch R, Djonlagic H, Hollandt H, Marre R. Endocarditis caused by *Bacillus circulans*. Infection 1991;19:445.
- [8] Goudswaard WB, Dammer MH, Hol C. *Bacillus circulans* infection of a proximal interphalangeal joint after a clenched-fist injury caused by human teeth. Eur J Clin Microbiol Infect Dis 1995;14:1015–6.
- [9] Alebouyeh M, Gooran Orimi P, Azimi-Rad M, et al. Fatal sepsis by *Bacillus circulans* in an immunocompromised patient. Iran J Microbiol 2011;3:156–8.
- [10] Tandon A, Tay-Kearney ML, Metcalf C, McAllister L. *Bacillus circulans* endophthalmitis. Graefes Arch Clin Exp Ophthalmol 2001;29:92–3.
- [11] Logan NA, Old DC, Dick HM. Isolation of *Bacillus circulans* from a wound infection. J Clin Pathol 1985;38:838–9.
- [12] Wilde AH, Ruth JT. Two-stage reimplantation in infected total knee arthroplasty. Clin Orthop Relat Res 1988;(236):23–35.
- [13] Roncoroni A, Rivas M, Smayevsky J, Bianchini H, Zucarro G. Infection of a cerebrospinal fluid shunt system by *Bacillus circulans* and *Bacillus larvae*. Rev Argent Microbiol 1985;17:157–63.
- [14] Banerjee C, Bustamante CI, Wharton R, Talley E, Wade JC. *Bacillus* infections in patients with cancer. Arch Intern Med 1988;148:1769–74.
- [15] Fritzell P, Bergström T, Welinder-Olsson C. Detection of bacterial DNA in painful degenerated spinal discs in patients without signs of clinical infection. Eur Spine J 2004;13:702–6.