



# A Tertiary Care Centre Experience on the Management of Paediatric Tracheobronchial Foreign Body During the COVID 19 Pandemic

Shaul Hameed<sup>1</sup> · Mounika Reddy Y<sup>1</sup>

Received: 3 August 2021 / Accepted: 18 September 2021  
© Association of Otolaryngologists of India 2021

**Abstract** Tracheobronchial foreign body aspiration (FBA) is a life threatening emergency most commonly seen among paediatric age group that requires immediate therapeutic intervention. The purpose of this study is to report our experience on management of these aspirated foreign body (FB) with rigid bronchoscopy during the COVID 19 pandemic. This is a retrospective study which included 100 children less than 17 years of age, diagnosed with suspected FBA and underwent rigid bronchoscopy for its removal between March 2020 and March 2021. Guardians of all female children with history of FBA, had to go through medicolegal enquiry considering the possibility of female infanticide. Analysis of data was made of the demographic details, characteristics and location of the aspirated FB, treatment modalities and difficulties encountered. Among the 100 patients included in the study, 67% were under 3 years of age. The male to female ratio was 2.23:1. 69% of the FB's were most frequently found in the right main bronchus. 63 cases of the removed FB were organic materials such as nuts. Tracheobronchial FB's should be suspected in children who have sudden onset of cough and respiratory distress, even when physical and radiographic evidence is absent. Mortality due to FBA is preventable by early intervention with bronchoscopy. During the Covid 19 pandemic before performing any emergency procedure, prior preoperative planning and use of personal protective equipment is important, considering

the very high risk of transmission of the virus due to aerosol generation.

**Keywords** Tracheobronchial foreign body · Paediatric · Rigid bronchoscopy · Pig bronchus

## Introduction

Foreign body aspiration (FBA) is a dangerous life threatening emergency most commonly seen among paediatric age group that requires immediate therapeutic intervention [1]. It has been reported to be the significant reason for mortality in 7% of the children less than or equal to 3 years of age [2–4]. FBA is more common in boys with proportion between males to females to be 1.2–2.6: 1 [3]. These FB's can get lodged and cause partial or complete occlusion at any site from the supraglottis to the terminal bronchioles in the tracheobronchial tree. Sudden onset cough, respiratory distress and wheeze are the most common symptoms which can occur due to FBA. The COVID 19 (novel coronavirus 2019) pandemic due to the said Wuhan virus has placed the entire medical profession into several challenging and troublesome circumstances. The management of these FBA during the COVID 19 pandemic has put otolaryngologists to several difficult situations as they are associated with a very high risk of transmission of the virus due to aerosol generation. This necessitated the routine use of personal protective equipment (PPE) in all areas of the hospitals, from out-patient clinics to operating theatres because of the risk of aerosol generation during intubation and extubation of most ENT procedures. This article is based on the management of emergencies due to FBA, regarding the challenges encountered during the management of these

---

✉ Mounika Reddy Y  
mounika304@yahoo.com

<sup>1</sup> Department of Otorhinolaryngology, Head and Neck Surgery, Govt. ENT hospital, Osmania Medical College, Hyderabad 500095, India

cases and precautionary measures which were taken during COVID 19 pandemic.

## Material and Methods

This study included 100 children less than 17 years of age, who were diagnosed with suspected tracheobronchial FBA and underwent rigid bronchoscopy for its removal between March 2020 and March 2021. Guardians of all female children with history of FBA, had to go through medico-legal enquiry considering the possibility of female infanticide. Patient charts with anaesthetic and operation details were reviewed, and retrospective analysis was made of the demographic details regarding age and gender of the patient, characteristics and location of the aspirated FB, treatment modalities and difficulties encountered.

### Initial Assessment

Patients with symptoms of sudden onset cough and respiratory distress were included in the study. Patients were additionally screened for symptoms of COVID 19, including history of travel and contact with positive patients. In our hospital, precautions were taken for all procedures irrespective of the patient's COVID 19 status, because of the majority number of asymptomatic patients and false negative Polymerase Chain Reaction (PCR). Initial assessment of the patient was done with PPE (Personal protective equipment), on out patient department (OPD) basis, children with suspicion of FBA underwent a detailed physical examination and imaging techniques. Posteroanterior and lateral view radiographs of the neck and chest were taken in all the cases (Fig. 1) to identify a radio opaque FB (Fig. 1b) in the tracheobronchial tree. The duration after aspiration, size and shape in particular, site of occlusion, organic and inorganic properties of the FB are of great importance and were taken into consideration. In cases where the FB was identified, rigid bronchoscopy was performed under general anaesthesia and FB was removed. In situations where radiographs were normal (Fig. 1a) and yet there was a significant degree of suspicion of FBA, patients were planned for diagnostic bronchoscopy under general anaesthesia. COVID 19 rapid antigen test was done in most of the cases prior to taking the patient for general anaesthesia.

### Therapeutic Intervention

The procedure was performed in an operating room with negative pressure. Only essential personnel were permitted into the operating room and all staff including the anaesthetists wore PPE which comprised of N95 mask (Venus

V-44 respirator N95 mask; Venus Safety & Health, Navi Mumbai, India), gown, gloves, shoe cover, eye protection and face shield (polycarbonate). Further, the anaesthetic team proposed that during intubation and extubation, the surgeons team were asked to stay out to minimise the risk of aerosol exposure. Rapid sequence induction with 2 mg/kg propofol injection was applied and then maintained with 2% sevoflurane in a 50% oxygen and 50% air combination and then the operation was proceeded with controlled ventilation. Pre-oxygenation was followed prior to induction for 5 min with 100% fraction of inspired oxygen (FiO<sub>2</sub>), to avoid manual ventilation of patients lungs and potential aerosolization of virus from the airways. All patients were given prophylactic antiemetics in view of decreasing the risk of vomiting and possible viral spread. Continuous monitoring of electrocardiography, pulse rate, blood pressures, and peripheral oxygen saturation was followed. Depending upon the size, shape and other properties, FB was removed out from the respiratory tract using different sizes of grasping forceps, alligator forceps and basket forceps. Parenteral antibiotics amoxicillin with clavulanic acid (20 mg/kg body weight) was given intra-operatively and continued every 8th hourly postoperatively. Postoperative assessment was made with chest X-ray and physical examination. All the children were monitored in hospital for at least 24 h in the ICU after the procedure.

## Results

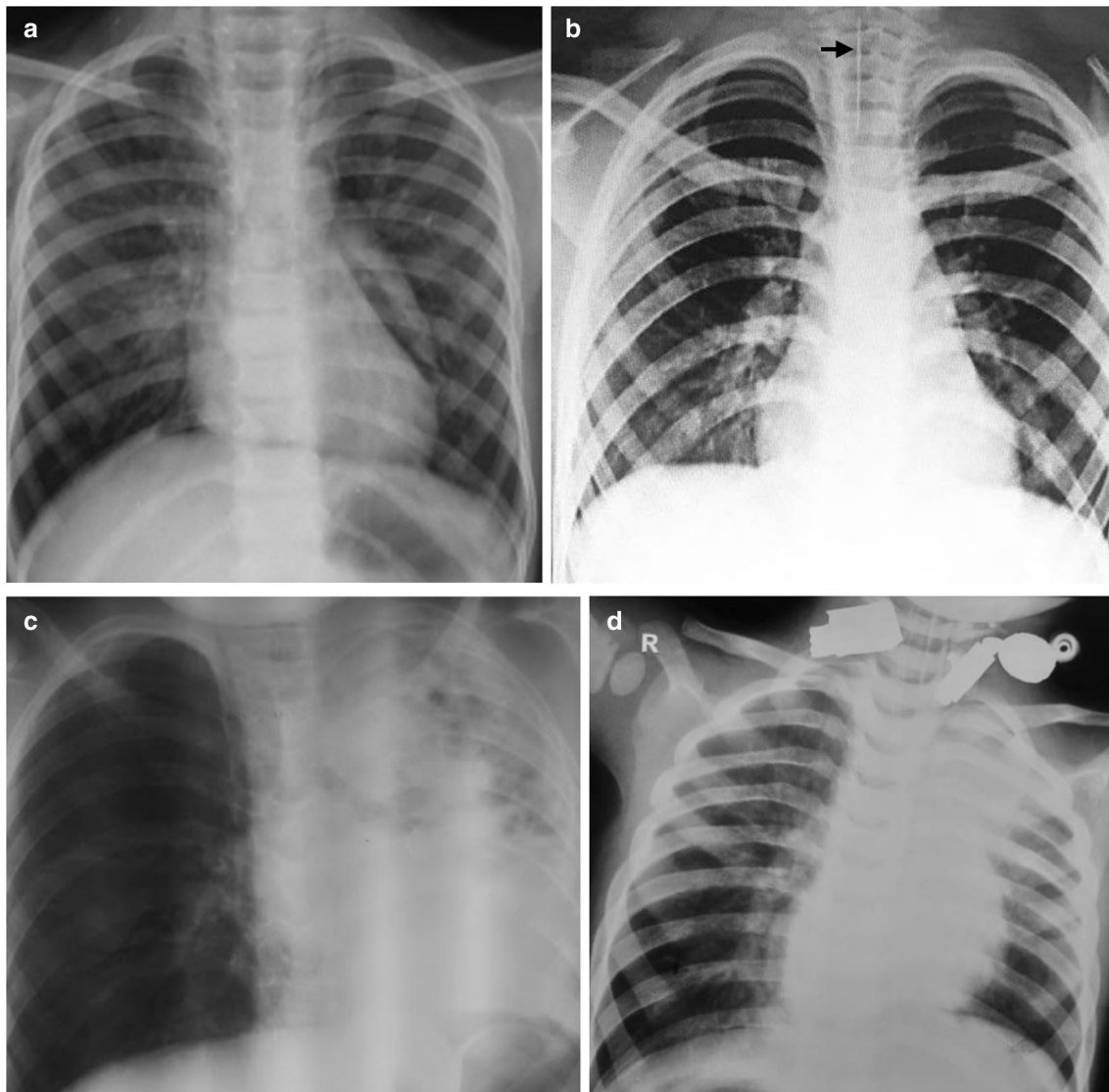
### Demographics

Among the 100 paediatric patients, majority 67(67%) cases were children less than or equal to 3 years of age, of which 47 were males and 20 were females, 17 males and 6 females were in the age group of more than 3 years to 10 years and 5 females and 5 males were between the age group more than 10—17 years of age (Table 1). Majority of the patients 69 cases were males and 31 cases were females. The male:female ratio was 2.23:1.

### Analysis

Among the 100 patients with suspected tracheobronchial FBA after clinical or radiological evidence, FB was seen and removal was successful in 90 (90%) cases and mucous plug were seen in 10 (10%) cases which was suctioned out successfully.

Table 2 summarises the analysis based on the site of localisation of FB. Rigid Bronchoscopy revealed FB localized in the right main bronchus in majority 60(60%) of the cases, other sites of occlusion included left main



**Fig. 1** Plain radiographs of the chest posteroanterior view showing (a) Normal chest (b) Radioopaque linear FB seen in the trachea (c) Collapse of the entire left lung and (d) Consolidation of the left upper lobe of the lung

bronchus, right secondary bronchus, trachea and at the carina. There were 2 cases of double FB, where the first was seen at the carina and the second FB was seen in the right main bronchus. During Bronchoscopy a pig bronchus variant (Fig. 3e) was seen in one of the case. Table 3 summarises the characteristics of FB (Figs. 2 and 3). Most of the FB's removed were organic (63 cases) which included peanuts (42 cases). 13 cases were metallic FB and 14 were other FB such as stone, whistle and pebbles.

Amongst those cases, who presented with delayed presentation, intra-operatively there was congestion, edema of the bronchial walls and granulation tissue with purulent discharge around the FB. Additionally surgeon also faced challenges of fogging due to PPE which restricted the

vision. Hence multiple attempts were made to remove the FB successfully. Post operatively, these patients were started on broad spectrum antibiotics and a chest X-ray taken to look for complication and lung status.

## Discussion

Foreign-body aspirations (FBA) are a leading cause of mortality in children. Emergency intervention is necessary as any delay in diagnosis and treatment may be fatal. FBA can be seen at any age, however it is more common in children up to the age of 3 years. FBA has been reported as the cause of child mortality in 7% of paediatric population

**Table 1** Distribution of Cases with Suspicion of FBA, according to Age

Age	Number of cases(n)
Equal or less than 3 years	67% (n = 67)
More than 3 years to 10 years	23% (n = 23)
More than 10 years to 17 years	10% (n = 10)
Total number of cases less than 17 years	100% (n = 100)

**Table 2** Distribution of Cases according to characteristics of FB

Type of FB	Number
Organic FB	63
Peanut	42
Custard apple seed	9
Tamarind seed	5
Piece of carrot	1
Betel nut	1
Corn seed	1
Pulse grain	3
Leaf twig	1
Metallic FB	13
Scarf pin	6
Bolt	1
Ball pin	2
Plug point pin	1
Sewing needle	2
Iron pin	1
Others	14
Stone	4
Granite pebble	1
Whistle	5
Bone piece	3
Shirt button	1

between the age group of 0–3 years [2–4]. The main reason being, children in this age group would have developed pincer grip and thus tend to place objects in the mouth, increasing the risk of aspiration while playing. Actions such as laughing, crying, or running while eating also lead to a higher risk of aspiration [5].

Majority 67% of the children were less than 3 years in our study, which is consistent with previous reported literature. In our study, the incidence of FBA has been reported to be higher in boys than in girls with ratio in accordance with previous literature of male/female ratio of 1.2–2.6: 1 [3]. This could be explained by higher activity levels in boys than girls.

**Table 3** Distribution of Cases of FB according to the site of Occlusion

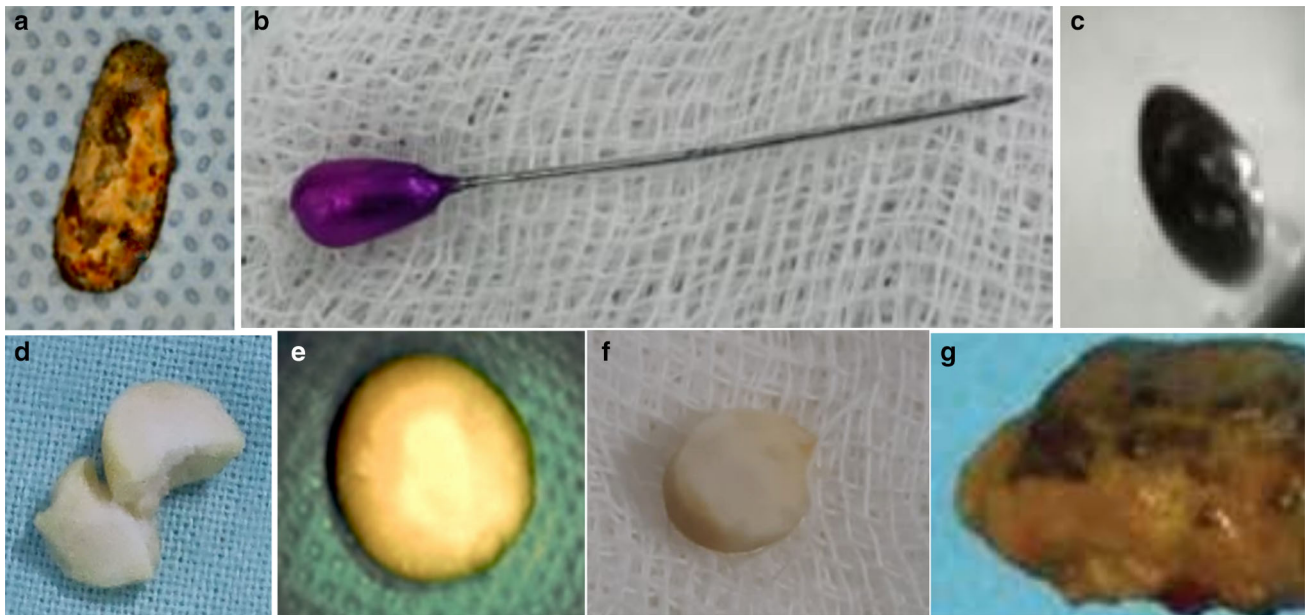
Site of Foreign Body Occlusion	Number
Right main bronchus	69% (n = 62)
Left main bronchus	22% (n = 20)
Right secondary bronchus	3% (n = 3)
Carina	3% (n = 3)
Trachea	2% (n = 2)
Total Number of FB	100% (n = 90)

FBA may be asymptomatic at onset, but very serious symptoms can develop in a short period. In many cases, the aspirated object migrates into the tracheobronchial tree. The most common symptoms were sudden onset cough, respiratory distress and wheeze. However, it has been reported in literature that although approximately 90% of children have a similar history of early onset, approximately 1% of patients are brought to hospital 1 month or later after aspiration [6, 7]. The posteroanterior and lateral plain radiographs of the neck and chest are the most commonly used imaging technique in suspected cases of FBA [8]. The most common radiological finding on the chest x-ray in FBA is pneumonia, emphysema or atelectasis. Emphysema is caused by the air which gets trapped in the lobe of lung during expiration [9, 10]. According to a study done by Oguz et al. [5], radiographs taken on patients who presented earlier than 24 h were normal and those who had a late presentation than 24 h had pneumonia and atelectasis were the most common findings.

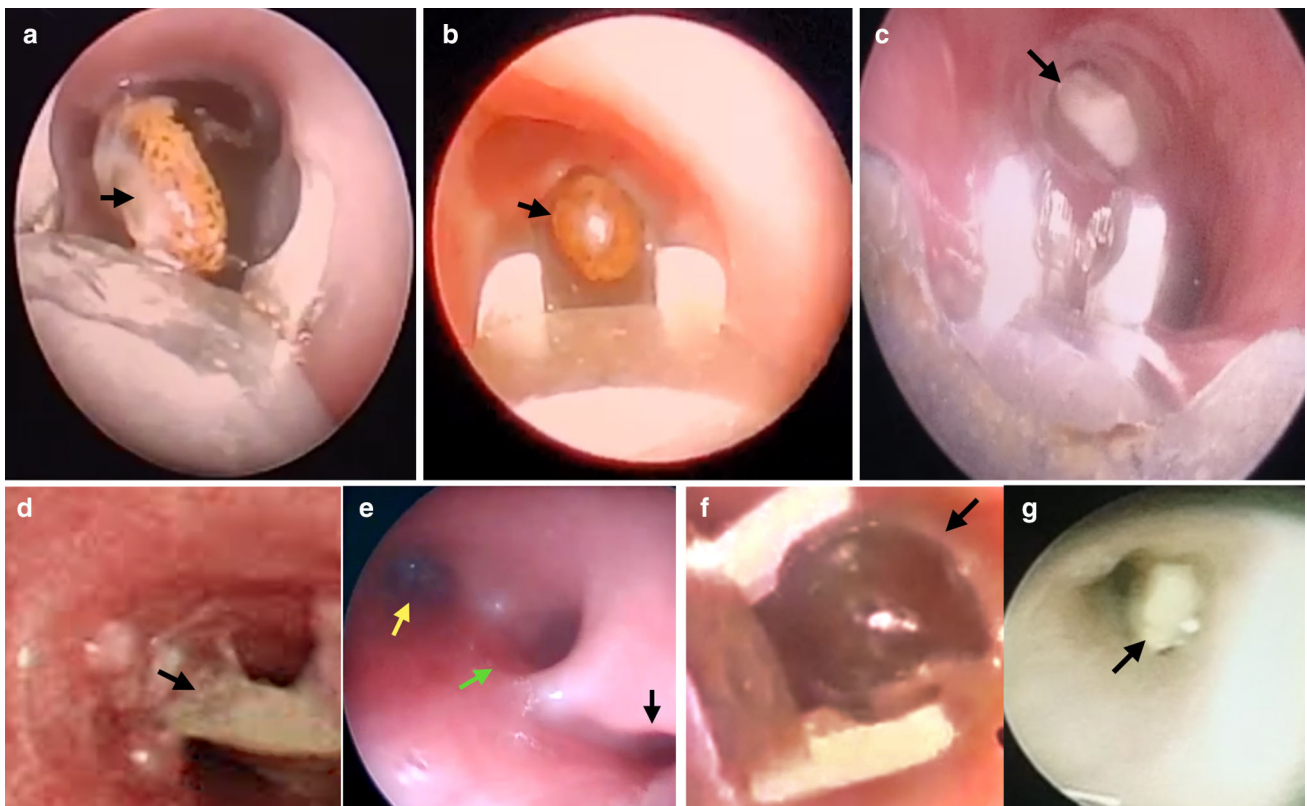
Chest CT can also be performed in selected cases but avoided due to the exposure to high dose of radiation. It should not be applied in delayed cases or when there are definite bronchoscopy indications. The sensitivity of thoracic CT in FBA is close to 100% and specificity is 66–100% [11]. The main treatment modality in suspected FBA is bronchoscopy. Bronchoscopy can be applied flexibly or rigidly. Rigid bronchoscopy is successfully used in all the cases in our hospital setup.

Otolaryngologists, anaesthetists and operating staff are a high risk group for COVID 19 infection, since they are particularly exposed to viral transmission directly through mucus and aerosolized particles during clinical examination, surgeries, or other interventions in the head and neck area. [12, 13]. It is documented that the viral load appears to be the highest in the nasopharynx and thus also contributes to the aerosolized transmission of the virus [13]. It is important to categorise the procedures according to their degree of urgency. Assess the risks and benefits of all ENT surgical procedures according to the prevalence of COVID 19 [14].





**Fig. 2** showing various Tracheobronchial FBA. (a) Custard apple seed, (b) Needle (c) Metal bead (d) Pieces of Groundnut seed (e) Pea seed (f) Groundnut and (g) Piece of stone



**Fig. 3** Bronchoscope view of various aspirated FB. (a) Tamarind seed, (b) Pea seed (c) Groundnut (d) Bone piece, (e) Pig bronchus (yellow arrow—left bronchus, green arrow—right bronchus, and black arrow—Pig bronchus i.e., variant of right bronchus), (f) Metal bead and (g) Mucous plug

Due to the availability of testing kits, preoperative workup for COVID 19 with a nasopharyngeal swab with RT PCR (Reverse transcription polymerase chain reaction) was performed in high risk procedures, which included bronchoscopy. Systematic precautions should be taken for all procedures irrespective of the COVID 19 status of the patient. The various precautionary measure taken during bronchoscopy are outlined below.

### Intraoperative Measures

All Otolaryngologists were supposed to wear a full Personal Protective Equipment (PPE) consisting of FFP2 (Filtering facepiece) mask, surgical gown, cap and protective glasses. These should be thrown into dedicated infected waste bins in the examination room following the procedure except for the protection glasses that can be decontaminated and reused [12].

It is very much essential to follow the COVID 19 recommendations during intubation and extubation to prevent the risk of aerosolisation of viral particles. Experienced individuals should perform the procedures with the fewest assistants possible, thus minimizing exposure time. The procedure should be performed in negative pressure operating rooms, with air filtration system. Amongst many challenges in using PPE, fogging is a commonly encountered problem which hampers the visualization of the surgeon while operating on delicate structures. Additionally, the low temperature of the operating room contributes to faster fogging. Hence, these procedures should be attempted by only skilled personnel trained in handling the above situations.

It has been emphasized in the literature that bronchoscopy must be chosen in all cases of FBA to prevent morbidity. Rigid bronchoscopy is a diagnostic and therapeutic procedure with a success rate close to 100% when applied by experienced hands. A rigid bronchoscope provides good ventilation while removing the foreign body. In pediatric cases, complications have been reported at a low rate of 2–8% [10, 11, 15, 16]. In a study by Annigeri and Patil [16], it was recommended that in all children undergoing rigid bronchoscopy for FBA, controlled ventilation should be maintained with propofol and sevoflurane during the bronchoscopy to lower the risk of pulmonary complications. In accordance with this recommendation, controlled ventilation was performed with propofol and sevoflurane in this study. This significantly facilitated the procedure, and successful results were obtained despite challenging bronchoscopic manoeuvres.

Foreign bodies aspirated into the tracheobronchial tree mainly get localized in the right bronchial system which was also seen in majority of the cases in our study. The reason being the right main bronchus is shorter, wider, and

closer to the trachea than the left. In the current study, the bronchoscopy results showed that the foreign body was seen more often in the right main bronchus, but localization in both bronchial branches were recorded. A pig bronchus variant was visualised in one of the case. Initially described by Sandifort in 1785, a pig bronchus is a rare tracheal anomaly in which an accessory bronchial branch originates superior to the tracheal bifurcation with its incidence ranging between less than 0.001–2% [17]. However, more recent literature in the late twentieth century defines it as an ectopic bronchus that originates 2–6 cm above the carina [18]. A pig bronchus is when the entire right upper lobe bronchus arises from the trachea. It is rarely seen with a reported frequency of 0.2% [19]. Tracheal bronchi on the right side are more prevalent than left, with a prevalence of 0.1–2% and 0.3–1%, respectively [19]. This anomaly is most commonly asymptomatic, however, patients might present with recurrent chest infections, retained secretions, stridor, and to a lesser degree, FBA.

The characteristics and properties of the aspirated object may depend on the social and cultural factors and the eating habits of the child. In developed countries, plastic toy parts and metal pieces are the most frequently aspirated objects [14, 20]. In underdeveloped countries, the most commonly aspirated foreign objects in childhood are food such as peanuts, hazelnuts, chickpeas and corn kernels. The most important features of these food items are that they expand in volume by absorption of bronchial secretions and disintegrate easily over time. The most commonly aspirated objects in the current study were peanuts, hazelnuts, and seeds, which are frequently found in homes in India as snacks.

The complication rate of bronchoscopy is very low when it is performed by an experienced team along with the appropriate equipment. The complication rate is known to increase after 24 h in misdiagnosed cases. Complications that may be encountered during procedure include hypoxia, hypercarbia, bronchospasm, vocal cord injury, laryngeal edema, post-operative infection, hemorrhage, pneumothorax, pneumomediastinum, tracheal and bronchial rupture, bradycardia, and cardiac arrest. Using the appropriate diameter of bronchoscope and keeping the bronchoscopy time short will reduce the risk of edema, and bronchospasm. The use of steroids before and after the procedure is also beneficial. In literature, residual foreign bodies, especially degraded organic matter, have been reported at the rate of 10%. If there is a suspicion of residual matter, the bronchoscopy should be repeated [21, 22]. In the current study, no repeat bronchoscopy was required in any patient and no complications occurred during the bronchoscopy procedures.

## Conclusion

Tracheobronchial Foreign bodies are one of the most common emergencies encountered in the department of otorhinolaryngology and a reason for increased morbidity and mortality. Childhood aspiration of foreign bodies is preventable by early intervention with bronchoscopy. There is a need to focus on prevention strategies by encouraging community education and raising awareness. It has been reported that FBA incidence can be reduced by 35% with public health education programs [21]. Risks can be reduced at home by keeping the children under the age of 3 years away from nuts and all other small items. During the Covid 19 pandemic before performing any emergency procedure, prior preoperative planning and use of PPE is important, considering the very high risk of transmission of the virus due to aerosol generation. Operating teams should try to minimize aerosol generating procedures and limit the length of these procedures whenever possible. Only trained personnel with experience should perform the procedures so that the resources are utilised efficiently.

**Acknowledgements** The authors would like to gratefully acknowledge and thank the medical superintendent and faculty for accepting for publication.

**Funding** The author(s) received no financial support for the research, authorship, and/or publication of this article.

## Declaration

**Conflict of interest** The author(s) declared no potential conflicts of interest with respect to the research, authorship, and/or publication of this article.

**Informed Consent** Informed consent was obtained from all the attendants of the patients.

## References

- Zhijun C, Fugao Z, Niankai Z, Jingjing C (2008) Therapeutic experience from 1428 patients with pediatric tracheobronchial foreign body. *J Pediatr Surg* 43(4):718–721. <https://doi.org/10.1016/j.jpedsurg.2007.10.010>
- Rizk H, Rassi S (2011) Foreign body inhalation in the pediatric population: lessons learned from 106 cases. *Eur Ann Otorhinolaryngol Head Neck Dis* 128(4):169–174. <https://doi.org/10.1016/j.anorl.2011.01.004>
- Paksu S, Paksu MS, Kilic M, Guner SN, Baysal K, Sancak R, Ozturk F (2012) Foreign body aspiration in childhood: evaluation of diagnostic parameters. *Pediatr Emerg Care* 28(3):259–264. <https://doi.org/10.1097/PEC.0b013e3182494eb6>
- Adjeso T, Damah MC, Murphy JP, Anyomih T (2017) Foreign body aspiration in Northern Ghana: a review of pediatric patients. *Int J Otolaryngol* 2017:1478795. <https://doi.org/10.1155/2017/1478795>
- Oğuz F, Citak A, Ünüvar E, Sidal M (2000) Airway foreign bodies in childhood. *Int J Pediatr Otorhinolaryngol* 52(1):11–16. [https://doi.org/10.1016/s0165-5876\(99\)00283-9](https://doi.org/10.1016/s0165-5876(99)00283-9)
- Bittencourt PF, Camargos PA, Scheinmann P, de Blic J (2006) Foreign body aspiration: clinical, radiological findings and factors associated with its late removal. *Int J Pediatr Otorhinolaryngol* 70(5):879–884. <https://doi.org/10.1016/j.ijporl.2005.09.024>
- Gang W, Zhengxia P, Hongbo L, Yonggang L, Jiangtao D, Shengde W, Chun W (2012) Diagnosis and treatment of tracheobronchial foreign bodies in 1024 children. *J Pediatr Surg* 47(11):2004–2010. <https://doi.org/10.1016/j.jpedsurg.2012.07.036>
- Saki N, Nikakhlagh S, Heshmati SM (2015) 25-Year review of the abundance and diversity of radiopaque airway foreign bodies in children. *Indian J Otolaryngol Head Neck Surg Off Publ Assoc Otolaryngol India* 67(3):261–266. <https://doi.org/10.1007/s12070-014-0817-0>
- Brown JC, Chapman T, Klein EJ, Chisholm SL, Phillips GS, Osincup D, Sakchalathorn P, Bittner R (2013) The utility of adding expiratory or decubitus chest radiographs to the radiographic evaluation of suspected pediatric airway foreign bodies. *Ann Emerg Med* 61(1):19–26. <https://doi.org/10.1016/j.annemergmed.2012.05.026>
- Roda J, Nobre S, Pires J, Estêvão MH, Félix M (2008) Foreign bodies in the airway: a quarter of a century's experience. *Rev Port Pneumol* 14(6):787–802
- Ozkurt H, Bahadır E, Ucgul A, Altuna C, Basak M, Cevizci NM, Dokucu AI (2008) Comparison of multidetector computed tomography-virtual bronchoscopy and conventional bronchoscopy in children with suspected foreign body aspiration. *Emerg Radiol*. <https://doi.org/10.1007/s10140-008-0779-1>
- Zou L, Ruan F, Huang M, Liang L, Huang H, Hong Z, Yu J, Kang M, Song Y, Xia J, Guo Q, Song T, He J, Yen HL, Peiris M, Wu J (2020) SARS-CoV-2 viral load in upper respiratory specimens of infected patients. *N Engl J Med* 382(12):1177–1179. <https://doi.org/10.1056/NEJMc2001737>
- Liu Y, Liao W, Wan L, Xiang T, Zhang W (2020) Correlation between relative nasopharyngeal virus RNA load and lymphocyte count disease severity in patients with COVID-19. *Viral Immunol*. Advanceonlinepublication.doi: <https://doi.org/10.1089/vim.2020.0062>
- Wright CC, Closson FT (2013) Updates in pediatric gastrointestinal foreign bodies. *Pediatr Clin North Am* 60(5):1221–1239. <https://doi.org/10.1016/j.pcl.2013.06.007>
- Cevizci N, Dokucu AI, Baskin D, Karadağ CA, Sever N, Yalçın M, Bahadır E, Başak M (2008) Virtual bronchoscopy as a dynamic modality in the diagnosis and treatment of suspected foreign body aspiration. *Eur J Pediatric Surg Off J Aust Assoc Pediatric Surg* 18(6):398–401
- Annigeri RV, Patil RS (2017) A retrospective analysis on anesthetic management during rigid bronchoscopy in children with foreign body aspiration: propofol and sevoflurane with controlled ventilation. *Anesth Essays Res* 11(4):871–874. [https://doi.org/10.4103/aer.AER\\_154\\_17](https://doi.org/10.4103/aer.AER_154_17)
- Doolittle AM, Mair EA (2002) Tracheal bronchus: classification, endoscopic analysis, and airway management. *Otolaryngol Head Neck Surg* 126(3):240–243. <https://doi.org/10.1067/mhn.2002.122703> (PMID: 11956531)
- Siegel MJ, Shackelford GD, Francis RS, McAlister WH (1979) Tracheal bronchus. *Radiology* 130(2):353–355. <https://doi.org/10.1148/130.2.353>
- Ghaye B, Szapiro D, Fanchamps JM, Dondelinger RF (2001) Congenital bronchial abnormalities revisited. *Radiographics: a review publication of the Radiological Society of North America, Inc*, 21(1):105–119

20. Macpherson RI, Hill JG, Othersen HB, Tagge EP, Smith CD (1996) Esophageal foreign bodies in children: diagnosis, treatment, and complications. *AJR Am J Roentgenol* 166(4):919–924. <https://doi.org/10.2214/ajr.166.4.8610574>
21. Sinha V, Chhaya V, Barot DS, Mehta K, Patel P, Patil S, Parmar V, Pashanth CD, Modi N, Patel R (2010) Foreign body in tracheobronchial tree. *Indian J Otolaryngol Head Neck Surg* 62(2):168–170. <https://doi.org/10.1007/s12070-010-0044-2>
22. Sheehan CC, Lopez J, Elmaraghy CA (2018) Low rate of positive bronchoscopy for suspected foreign body aspiration in infants. *Int J Pediatr Otorhinolaryngol* 104:72–75. <https://doi.org/10.1016/j.ijporl.2017.10.030>

**Publisher's Note** Springer Nature remains neutral with regard to jurisdictional claims in published maps and institutional affiliations.