

Growth hormone replacement therapy improves hypopituitarism-associated hypoxemia in a patient after craniopharyngioma surgery

A case report

Wenting Qi, MD, Feng Gu, MD*, Chuyue Wu, MD

Abstract

Rationale: There are some reports about hypoxemia related to hypopituitarism. However, little is known about the relationship between growth hormone deficiency (GHD) and hypoxemia.

Patients concerns: A 23-year-old female presented with severe hypoxemia after the operations of craniopharyngioma. Laboratory tests found that serum growth hormone (GH) levels were extremely low.

Diagnosis: She was diagnosed with growth hormone deficiency-related hypoxemia.

Interventions: In addition to oxygenation, low doses of GH replacement therapy was conducted for 3-month.

Outcomes: After 3-month r-hGH replacement therapy, hypoxemia was improved significantly and the level of serum GH was elevated.

Lessons: We've already known that hypopituitarism may induce hypoxemia owing to multiple possible mechanisms according to previous literature. But little is known about growth hormone deficiency-related hypoxemia. Our case shows that GH replacement therapy is an effective treatment, and it's significant to examination the level of GH in serum for hypoxemia patients especially when the cause of hypoxemia is unknown.

Abbreviations: CTPA = computed tomographic pulmonary angiography, DLco = diffusion capacity for carbon monoxide, FEV₁ = forced expiratory volume in 1 second, FVC = forced vital capacity, GH = growth hormone, GHD = growth hormone deficiency, IGF-1 = insulin-like growth factors-1, IGFBP-2 = insulin-like growth factors binding protein-2, IGFBP-3 = insulin-like growth factors binding protein-3, r-hGH = recombinant human growth hormone, RV = residual volume, TLC = total lung capacity.

Keywords: craniopharyngioma, diffusion dysfunction, growth hormone deficiency, hypopituitarism, hypoxemia

1. Introduction

There are no studies on hypoxemia after the surgery for craniopharyngioma although it's known that the patients with

hypopituitarism could suffer small lung and respiratory failure.^[1] However, the relationship between hypoxemia and GHD has not been clearly clarified. Herein we reported a rare case that a young woman developed severe hypoxemia after 2 operations of craniopharyngioma and was improved by 3-month recombinant human growth hormone (r-hGH) replacement therapy. Therefore, GH may play an important role in the hypoxemia after surgery for craniopharyngioma and there are several possible mechanisms.

Editor: N/A.

Ethical review: The authors state that this study does not involve ethical committee approval.

Patient consent statement: The patient had approved to submit this case report to the journal.

The authors have no conflicts of interest to disclose.

Department of Endocrinology, Peking Union Medical College Hospital, Chinese Academy of Medical Sciences and Peking Union Medical College, Shuaifuyuan 1, Dong Cheng District, Beijing 100730, China.

* Correspondence: Feng Gu, Department of Endocrinology, Peking Union Medical College Hospital, Chinese Academy of Medical Sciences and Peking Union Medical College, Shuaifuyuan 1, Dong Cheng District, Beijing 100730, China (e-mail: gufeng@gusmedsci.cn).

Copyright © 2019 the Author(s). Published by Wolters Kluwer Health, Inc. This is an open access article distributed under the terms of the Creative Commons Attribution-Non Commercial License 4.0 (CCBY-NC), where it is permissible to download, share, remix, transform, and buildup the work provided it is properly cited. The work cannot be used commercially without permission from the journal.

Medicine (2019) 98:3(e14101)

Received: 8 September 2018 / Received in final form: 14 December 2018 /

Accepted: 18 December 2018

<http://dx.doi.org/10.1097/MD.0000000000014101>

2. Case report

A 23-year-old woman was referred to the Department of Endocrinology in our hospital due to severe hypoxemia in January 2018 who had craniopharyngioma and suffered two craniotomy operations. Symptoms related to hypopituitarism and hypothalamic dysfunction presented after the operations and she received multiple hormonal replacement therapies (prednisone, levothyroxine and estrogen) after the second surgery in 2013 except for GH.

Physical examination revealed that SpO₂ was 90% under the condition of inhaled oxygen concentration of 3–4L/min. Results of blood gas analyses in January 2018 were pCO₂ 27.6mm Hg, pO₂ 44.8mm Hg, SaO₂ 81.6%, A–a 73.3mm Hg (oxygen inhalation was 3.5 L/min). Pulmonary function test showed mild ventilation dysfunction but severe diffuse dysfunction of the

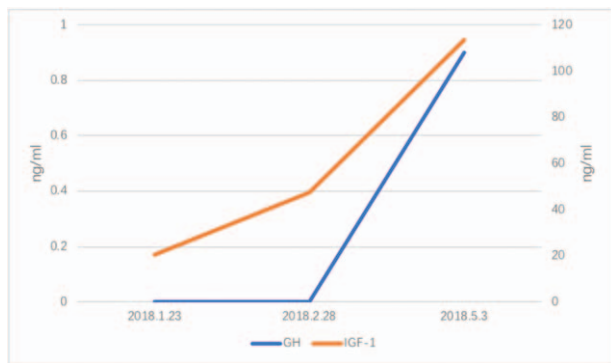


Figure 1. Changes in the serum levels of GH and IGF-1 over time under the GH replacement therapy. GH = growth hormone, IGF = insulin-like growth factors-1.

lungs, and there was no abnormal in total lung capacity, residual volume and functional residual capacity. Chest X-ray, computed tomographic pulmonary angiography (CTPA) and polysomnography were all normal. Hormonal examination showed no deficiency in thyroid hormone and cortisol under the condition of replacement therapies but significantly low levels of serum GH and sex hormone.

Considering that she has no demand for growth and high dose of r-hGH may increase the risk of cancer recurrence, we started with a low-dose of r-hGH of 1.5IU every other day (qod) through hypodermic injection (ih) since January 2018 under the agreement of patient, increased the dosage to 2IU qod ih a month later, and added estrogen and progesterone replacement therapy in March 2018. The dose of r-hGH was finally increased to 3IU qod ih since May 25, 2018. Since the r-hGH replacement therapy, oxygen concentrations were reduced from 4L/min to 2L/min and the duration of home oxygen therapy were also gradually reduced from 24h/day to 12h/day in March 2018, and finally stopped on 2018-4-20. There was a notable improvement in the level of serum insulin-like growth factors-1 (IGF-1) during the treatment (Fig. 1). Pulmonary function test in May 2018 showed little change compared with that 3 months ago. (Forced expiratory volume in 1 second [FEV₁] 2.38L, forced vital capacity [FVC] 2.81L, FEV₁/FVC 84.2%, total lung capacity [TLC] 3.52L, residual volume [RV] 0.76L, diffusion capacity for carbon monoxide [DLco] 2.83mmol/min/kPa).

3. Discussion

It has been reported that severe hypothyroidism may result in respiratory failure in some cases,^[1-3] in which the respiratory muscle strength is weakened, and the volume of lung becomes small in the hypothyroidism and pulmonary function is significantly improved after thyroid hormone replacement therapy especially FEV₁, FVC, and VC.^[1,4] Differently, in our case the patient had already practiced to substitute hydrocortisone, thyroid hormone and estrogen, and the plasma level of thyroid hormone was within normal range during severe hypoxemia. It has been reported that growth hormone replacement therapy can improve hypoxemia,^[5,6] but little is known of the hypoxemia in patients with GHD related to craniopharyngioma. It has also been reported that the patients with GHD developed restrictive pulmonary dysfunctions but no diffuse dysfunction of the lungs, however, different from previous reports, our case shows significantly lower DLco but no significant changes in FEV₁/FVC, TLC, and RV, which shows

decreased diffusing capacity. Based on previous reports and our observation, we hypothesized that the hypoxemia could be caused by GHD, and r-hGH replacement therapy is effective for improving respiratory function.

It's widely accepted that GH plays an important role in muscle synthesis.^[7,8] Nass's research shows that r-hGH replacement in GHD patients helps to improve oxygen uptake and exercise capacity greatly, which could result in the increase in respiratory muscle strength and lungs volume.^[7] There was a case that a patient failed to stop long-term mechanical ventilation for end-stage chronic obstructive pulmonary disease. After 20 days r-hGH (27 IU/day, 0.3 IU/kg body weight/day) treatment through a subcutaneous injection, his respiratory muscular strength was increasing gradually and the patient was extubated finally on day 75.^[5] It is well established that GH influences somatic growth by increasing the expression of IGF-1, which has effects on improving pulmonary ventilation function in the long-term.^[8] Studies have also confirmed that the lung is a target of GH^[9] and thus GHD could induces physiological and anatomical changes in the lung^[10,11] and decreased muscle strength. Maximum inspiratory and expiratory pressure reduction is related to GHD.^[9] Unfortunately, our patient refused to accept the performance of respiratory muscle strength assessment.

Secondly, differently from previous reports, our case showed notable diffusion dysfunction but normal ventilation function. In other words, GHD may not only influence the size of lung but also the gas exchange. A possible explanation could be that hypopituitarism-associated hormone deficiencies affected the elastic recoil of the lung. It's well accepted that thyroxine is essential for surfactant, thus, we supposed that GH may have similar function as thyroxine in the synthesis of pulmonary surfactant. Such a deficiency in surfactant synthesis may induce the increase of surface forces and lung elastic recoil, leading to the decrease of lung volumes.^[1,12]

Moreover, GH mRNA has been found increased in rat lung proteome during alveorization, supporting the hypothesis that GH may be a regulation of lung growth and differentiation through autocrine or paracrine actions.^[9] While further study is needed on the specific mechanism of diffuse dysfunction of GHD. In some cases that acromegaly usually has an increase in TLC,^[13] so we hypothesized that the lack of growth hormone can lead to a decrease in TLC, which in turn causes hypoxemia. However, in terms of that our case, there is no significant decrease in TLC but diffused dysfunction. Therefore, we suggested that the decrease of diffused function may be the main cause of hypoxemia of GHD. The GHD is also closely related to obesity, which regulates the expression of adipokines, affects the growth and differentiation of tissues, and causes the appearance of large adipocytes, which in turn could cause hypoxic and inflammatory reactions.^[14-17] The GHD can also cause a decrease in insulin-like growth factors binding protein-3/2 (IGFBP-3/IGFBP-2), while IGF-1 mainly acts through IGFBP-3, leading to the reduction of IGF-1 bioavailability in adipose tissue.^[18-20]

Although the symptoms of hypoxia improved significantly, the pulmonary function in May 2018 showed no apparent change in the diffusion function compared with that before treatment in January 2018. We consider that it may be due to the shorter treatment cycle or the impacts of other hormones on respiratory function.

4. Conclusion

In conclusion, GHD could cause severe respiratory failure especially hypoxemia which can produce irreversible damage to

the optic nerve, brain cells, etc.^[21] We should pay attention to examine the levels of pituitary hormones for patients with hypopituitarism after craniopharyngioma surgery when the cause of respiratory dysfunction is unclear. Patients could benefit from timely and effective GH replacement therapy by improving respiratory functions. The underlying mechanisms of hypoxemia caused by GHD have not been clearly clarified, thus further studies are highly demanded.

Author contributions

Conceptualization: Wenting Qi, Chuyue Wu.

Methodology: Wenting Qi, Chuyue Wu.

Supervision: Wenting Qi, Gu Feng, Chuyue Wu.

Visualization: Wenting Qi.

Writing – original draft: Wenting Qi.

Writing – review & editing: Wenting Qi.

Gu Feng orcid: 0000-0003-2084-3518.

References

- [1] Jain BP, Brody JS, Fisher AB. The small lung of hypopituitarism. *Am Rev Respir Dis* 1973;108:49–55.
- [2] Siafakas NM, Bouros D. Respiratory muscles in endocrinopathies. *Respir Med* 1993;87:351–8.
- [3] Behnia M, Clay AS, Farber MO. Management of myxedematous respiratory failure: review of ventilation and weaning principles. *Am J Med Sci* 2000;320:368–73.
- [4] Siafakas NM, Salesiotou V, Filaditaki V, et al. Respiratory muscle strength in hypothyroidism. *Chest* 1992;102:189–94.
- [5] Felbinger TW, Suchner U, Goetz AE, et al. Recombinant human growth hormone for reconditioning of respiratory muscle after lung volume reduction surgery. *Crit Care Med* 1999;27:1634–8.
- [6] Sato I, Yokoyama Y, Ryuge M, et al. Respiratory failure was improved by growth hormone substitution in a patient with hypopituitarism. *BMJ Case Rep* 2010;2010.
- [7] Nass R, Huber RM, Klauss V, et al. Effect of growth hormone (hGH) replacement therapy on physical work capacity and cardiac and pulmonary function in patients with hGH deficiency acquired in adulthood. *J Clin Endocrinol Metab* 1995;80:552–7.
- [8] Saaresranta T, Irjala K, Polo-Kantola P, et al. IGF-I and ventilation after short-term progesterin in postmenopausal women with chronic respiratory insufficiency. *Respir Med* 2000;94:909–16.
- [9] Beyea JA, Olson DM, Harvey S. Growth hormone-dependent changes in the rat lung proteome during alveolarization. *Mol Cell Biochem* 2009;321:197–204.
- [10] Merola B, Sofia M, Longobardi S, et al. Impairment of lung volumes and respiratory muscle strength in adult patients with growth hormone deficiency. *Eur J Endocrinol* 1995;133:680–5.
- [11] Merola B, Longobardi S, Sofia M, et al. Lung volumes and respiratory muscle strength in adult patients with childhood- or adult-onset growth hormone deficiency: effect of 12 months' growth hormone replacement therapy. *Eur J Endocrinol* 1996;135:553–8.
- [12] Knobil E, Hotchkiss J. Growth hormone. *Annu Rev Physiol* 1964;26:47–74.
- [13] Stormann S, Gutt B, Roemmler-Zehrer J, et al. Assessment of lung function in a large cohort of patients with acromegaly. *Eur J Endocrinol* 2017;177:15–23.
- [14] Eden Engstrom B, Burman P, Holdstock C, et al. Effects of growth hormone (GH) on ghrelin, leptin, and adiponectin in GH-deficient patients. *J Clin Endocrinol Metab* 2003;88:5193–8.
- [15] Ukropec J, Penesova A, Skopkova M, et al. Adipokine protein expression pattern in growth hormone deficiency predisposes to the increased fat cell size and the whole body metabolic derangements. *J Clin Endocrinol Metab* 2008;93:2255–62.
- [16] Trayhurn P. Hypoxia and adipose tissue function and dysfunction in obesity. *Physiol Rev* 2013;93:1–21.
- [17] Ye J, Gao Z, Yin J, et al. Hypoxia is a potential risk factor for chronic inflammation and adiponectin reduction in adipose tissue of ob/ob and dietary obese mice. *American journal of physiology. Endocrinol Metab* 2007;293:E1118–1128.
- [18] Grimberg A, Coleman CM, Burns TF, et al. p53-Dependent and p53-independent induction of insulin-like growth factor binding protein-3 by deoxyribonucleic acid damage and hypoxia. *J Clin Endocrinol Metab* 2005;90:3568–74.
- [19] Glaser S, Friedrich N, Ewert R, et al. Association between serum insulin-like growth factor (IGF) I and IGF binding protein-3 and lung function. *J Clin Endocrinol Metab* 2009;94:2452–8.
- [20] Green CJ, Holly JM, Bolton CE, et al. Role of IGF-I, IGF-II and IGFBP-3 in lung function of males: the Caerphilly Prospective Study. *Int J Mol Epidemiol Genet* 2014;5:112–9.
- [21] Lin S, Fan LW, Pang Y, et al. IGF-1 protects oligodendrocyte progenitor cells and improves neurological functions following cerebral hypoxia-ischemia in the neonatal rat. *Brain Res* 2005;1063:15–26.